Cureus
Part of SPRINGER NATURE

Open Access Review Article

The Skin as a Window to Diabetes: A Narrative Review of Cutaneous Manifestations

Review began 11/02/2026
Review ended 11/16/2026
Published 11/24/2026

© **Copyright** 2026
Berrocal et al. This is an open access article distributed under the terms of the Creative Commons Attribution License CC-BY 4.0., which permits unrestricted use, distribution, and reproduction in any medium, provided the original author and source are credited.

DOI: 10.7759/cureus.120200

Carlos Berrocal [1], Andrés David Sastre Martinez [1], Cesar Ivan Varela Hernández [2], Isabella Rodríguez Niño [3], Luisa Fernanda Amaya Machado [4], María Alejandra Benavides Cañola [5], Jhon Herney Quintana Ospina [6], Andrés Felipe García Ramos [7]

1. Internal Medicine, Hospital Universitario del Valle Evaristo García/Universidad del Valle, Cali, COL 2. Dermatology, Hospital Universitario del Valle Evaristo García/Universidad del Valle, Cali, COL 3. General Medicine, Universidad Libre, Cali, COL 4. General Medicine, Empresa Social del Estado (ESE) Hospital La Misericordia, Yalí, COL 5. General Medicine, Hospital Universitario del Valle Evaristo García Sede Cartago, Cartago, COL 6. Internal Medicine, Clínica de Occidente, Cali, COL 7. Endocrinology, Hospital Universitario del Valle Evaristo García/Universidad del Valle, Cali, COL

Corresponding author: Carlos Berrocal, carlos.berrocal@correounivalle.edu.co

Abstract

Diabetes mellitus (DM) has systemic effects that extend to the skin, and cutaneous findings may precede diagnosis, reflect microvascular damage, or signal neurologic and infectious complications.

This study aimed to provide a narrative synthesis of clinically relevant cutaneous manifestations of DM, organized by predominant pathophysiologic mechanism, with emphasis on the diabetic foot and to propose a practical approach that links skin findings to assessment and referral.

A literature search was conducted in PubMed/MEDLINE using Medical Subject Headings (MeSH) terms and free-text keywords related to diabetes and skin disease, combined with Boolean operators. English-language publications from January 2016 through October 23, 2026 (date of the last search), were considered, prioritizing clinical practice guidelines, systematic reviews and meta-analyses, and larger observational studies.

Hyperglycemia, insulin resistance, and chronic inflammation converge to produce a spectrum of dermatoses. Some are markers of insulin resistance (acanthosis nigricans) or of severe hypertriglyceridemia (eruptive xanthomas) and are not specific to DM. Others are diabetes-associated findings related to microangiopathy and neuropathy (diabetic dermopathy, bullosis diabeticorum), collagen and dermal matrix alterations (necrobiosis lipoidica, scleredema diabeticorum), pruritic perforating dermatoses, and increased susceptibility to cutaneous infection. Granuloma annulare shows a modest, nonspecific association with DM that warrants careful clinical contextualization. The strength of the evidence differs markedly across entities and is graded in this review. The diabetic foot represents the most consequential manifestation, driven by neuropathy and peripheral arterial disease, for which off-loading remains the cornerstone of ulcer healing and recurrence prevention. A mechanism-based algorithm links each skin finding to first-line assessment and referral. Recognizing these dermatoses supports early screening for systemic complications and guides interdisciplinary management, particularly for diabetic foot disease, where prevention and timely intervention critically influence outcomes.

Categories: Internal Medicine, Endocrinology/Diabetes/Metabolism, Dermatology
Keywords: acanthosis nigricans, diabetes mellitus (dm), diabetic foot, necrobiosis lipoidica, peripheral neuropathy, skin manifestations

Introduction And Background

Diabetes mellitus (DM) is a chronic metabolic disease with systemic impact extending beyond glycemic control to multiple organs, including the skin. Cutaneous manifestations are common and may precede the diagnosis of DM or insulin resistance, serve as markers of sustained hyperglycemia and microvascular damage, or arise alongside neurologic, infectious, and immune complications of the disease [1,2].

Not all of these findings carry the same meaning. Some are diabetes-associated dermatoses that occur more often in people with DM but are not exclusive to it; others are markers of insulin resistance or of other metabolic disorders, such as severe hypertriglyceridemia, that may or may not coexist with DM; and others are adverse effects of diabetes treatments and devices. Distinguishing among these categories helps clinicians avoid both missed diagnoses and premature diagnostic assumptions.

The pathophysiology of these lesions is multifactorial, involving insulin resistance, oxidative stress, accumulation of advanced glycation end-products (AGEs), microangiopathy, peripheral neuropathy, immune dysregulation, and impaired tissue repair [1,3]. Their recognition has direct clinical implications: acanthosis nigricans (AN) should prompt cardiometabolic screening, diabetic dermopathy should prompt

review of microvascular and cardiovascular status, and plantar lesions should trigger a structured assessment of neuropathy and peripheral arterial disease (PAD), because these factors drive ulceration risk [4].

The reported prevalence of skin disease among people with DM varies widely across studies, reflecting differences in setting, population, diabetes type and duration, and case definitions; many lesions are also nonspecific or underrecognized in routine care [1,3]. Skin findings are nevertheless clinically useful because they are visible and accessible to examination, and they can reveal metabolic risk (insulin resistance, dyslipidemia), microvascular and neuropathic complications, or treatment-related problems before systemic complications become evident [1,2,5].

This narrative review describes clinically relevant cutaneous manifestations in people with DM, grouped by predominant pathophysiologic mechanism and graded by the strength of their association with DM. Emphasis is placed on AN, necrobiosis lipoidica (NL), granuloma annulare (GA), hyperkeratotic lesions, and the diabetic foot disease spectrum, alongside other entities relevant to a comprehensive dermatologic assessment [1,2]. It is intended for primary care physicians, internists, endocrinologists, and dermatologists, as well as other clinicians involved in the care of people with DM, to help them recognize these cutaneous clues and act on them.

The aims of this review are to (1) summarize the pathophysiologic mechanisms linking DM to skin dysfunction; (2) describe the clinical features, diagnostic approach, differential diagnosis, and management of the principal cutaneous manifestations; (3) address the diabetic foot as the most consequential cutaneous-neurovascular complication; (4) outline the cutaneous adverse effects of diabetes treatments and devices; and (5) propose a practical, mechanism-based approach that links skin findings to assessment and referral.

Review

Methods

Search Strategy

A literature search was conducted in PubMed/MEDLINE for English-language publications from January 1, 2016, through October 23, 2026, the date of the last search. Medical Subject Headings (MeSH) and free-text title/abstract terms were combined using the Boolean operators AND and OR in three concept blocks: (1) diabetes, (2) cutaneous manifestations, and (3) diabetic foot. The general search combined blocks 1 and 2, and the diabetic foot search combined blocks 1 and 3. The complete strategy is provided in the Appendix.

Study Selection

Titles and abstracts were screened for relevance to cutaneous disease in DM, and the full text of potentially relevant articles was reviewed. Screening and selection were performed by one author. Reference lists of key reviews were also consulted for additional relevant publications. To support the strength-of-association categories used in this review, additional targeted searches were performed in PubMed on November 15, 2026, for guidelines, systematic reviews, and large cohort studies on selected entities; these were not part of the primary search strategy.

Prioritization of Evidence and Strength of Association

Evidence was prioritized in the following order: (1) clinical practice guidelines; (2) systematic reviews and meta-analyses; (3) larger cohort, case-control, and cross-sectional studies; and (4) case reports and small series, used mainly for rare entities (e.g., bullosis diabeticorum and acquired perforating dermatosis (APD)) for which higher-level evidence is scarce. This hierarchy was used to classify the strength of association with DM as strong (consistent findings in guidelines, systematic reviews or meta-analyses, or large cohort studies), moderate (observational studies with variable effect sizes or heterogeneity across populations), or limited/inconsistent (conflicting results or evidence restricted to small series and case reports). Entities were also grouped by the nature of their relationship with DM, which is distinct from the strength of the evidence.

This work is a narrative rather than a systematic review: no protocol was registered, and no formal risk-of-bias assessment was performed. Only PubMed/MEDLINE was searched; Embase and the Cochrane Library were not, so relevant publications indexed only in those databases may have been missed. Findings were synthesized qualitatively and organized by predominant pathophysiologic mechanism.

Pathophysiology of cutaneous manifestations in DM

Cutaneous manifestations of DM arise from the convergence of chronic hyperglycemia, insulin resistance, and systemic inflammation, which reprogram skin homeostasis and explain both "marker" dermatoses and impaired repair. Hyperglycemia promotes the accumulation of AGEs and activates metabolic pathways such

as the hexosamine/O-GlcNAcylation route, whereas insulin resistance and hyperinsulinemia hyperactivate trophic signaling axes (e.g., PI3K/Akt/mTOR, insulin-like growth factor 1 (IGF-1)), contributing to hyperproliferative phenotypes such as AN. Together, these pathways impair keratinocyte, fibroblast, and endothelial cell function, with defective migration and proliferation, disrupted angiogenesis, and dysfunctional immune responses, perpetuating an inflammatory microenvironment that favors delayed wound healing and chronic ulcers [5-7].

Hyperglycemia and Advanced Glycation

Chronic hyperglycemia promotes non-enzymatic glycation of long-lived dermal proteins, particularly collagen. Glycated, cross-linked collagen is stiffer and more resistant to remodeling, which is relevant to the thickened skin of scleredema and other "thickened skin" markers, while signaling through the receptor for AGEs (RAGE) amplifies oxidative stress and nuclear factor kappa B (NF-κB)-dependent inflammation [5,6,8].

Microangiopathy and Neuropathy

Dermal microvascular dysfunction, characterized by endothelial dysfunction and capillary basement-membrane changes, reduces nutritive perfusion and the ability to mount a hyperemic response to injury and has been proposed as a substrate for diabetic dermopathy, bullosis diabeticorum, and NL [1,3]. Peripheral neuropathy contributes through three routes: loss of protective sensation (LOPS) (unrecognized trauma), motor imbalance (deformity and abnormal plantar loading), and autonomic dysfunction (reduced sweating, xerosis, and altered skin blood flow) [4].

Immune Dysregulation and Impaired Repair

Hyperglycemia impairs innate immune function (neutrophil chemotaxis, phagocytosis, and intracellular killing), which increases susceptibility to bacterial and fungal infection [1,3]. In diabetic wounds, oxidative stress and persistent inflammatory signaling keep healing arrested in the inflammatory phase [6], and interleukin-17A (IL-17A) is increased in diabetic wounds and impairs keratinocyte function through the histone demethylase Jumonji domain-containing protein-3 (JMJD3) [7], illustrating how cytokine pathways may become therapeutic targets. These mechanisms overlap and interact, which explains why a given patient may present with several cutaneous markers at once and why skin findings often track with systemic complications [1,5].

Cutaneous manifestations of DM

The manifestations below are grouped by the nature of their relationship with DM: complications of diabetes (diabetic foot ulcer and hyperkeratotic lesions); diabetes-associated dermatoses that are frequent in DM but not exclusive to it; markers of insulin resistance or of other metabolic disorders that are not specific to DM; nonspecific associations (GA); and effects of treatments and devices. The strength of association is also graded (strong, moderate, or limited/inconsistent) using the criteria described in Methods. Figure *1* illustrates selected findings, and Figure *2* summarizes how each finding maps onto first-line assessment and referral.



FIGURE 1: Representative cutaneous manifestations associated with diabetes mellitus and insulin resistance

(A) Acanthosis nigricans on the posterior neck: hyperpigmented, velvety plaques with accentuated skin folds, a marker of insulin resistance. (B) Necrobiosis lipoidica on the pretibial region: yellowish plaque with an erythematous-violaceous border and an atrophic central zone. (C) Granuloma annulare: grouped dermal papules in an annular configuration with central clearing, on an extensor surface. (D) Hyperkeratotic lesion/plantar keratoderma in a person with diabetes, a pre-ulcerative finding that warrants assessment of neuropathy, plantar pressure, and ulcer risk. (E) Plantar neuropathic ulcer (mal perforant du pied): deep ulcer with a hyperkeratotic halo at a plantar pressure point.

Panels A, C, and D are original photographs by the authors. Panels B and E were from Varela Hernández [9] and reproduced under a Creative Commons Attribution-NonCommercial-NoDerivatives 4.0 International License (CC BY-NC-ND 4.0 Deed).

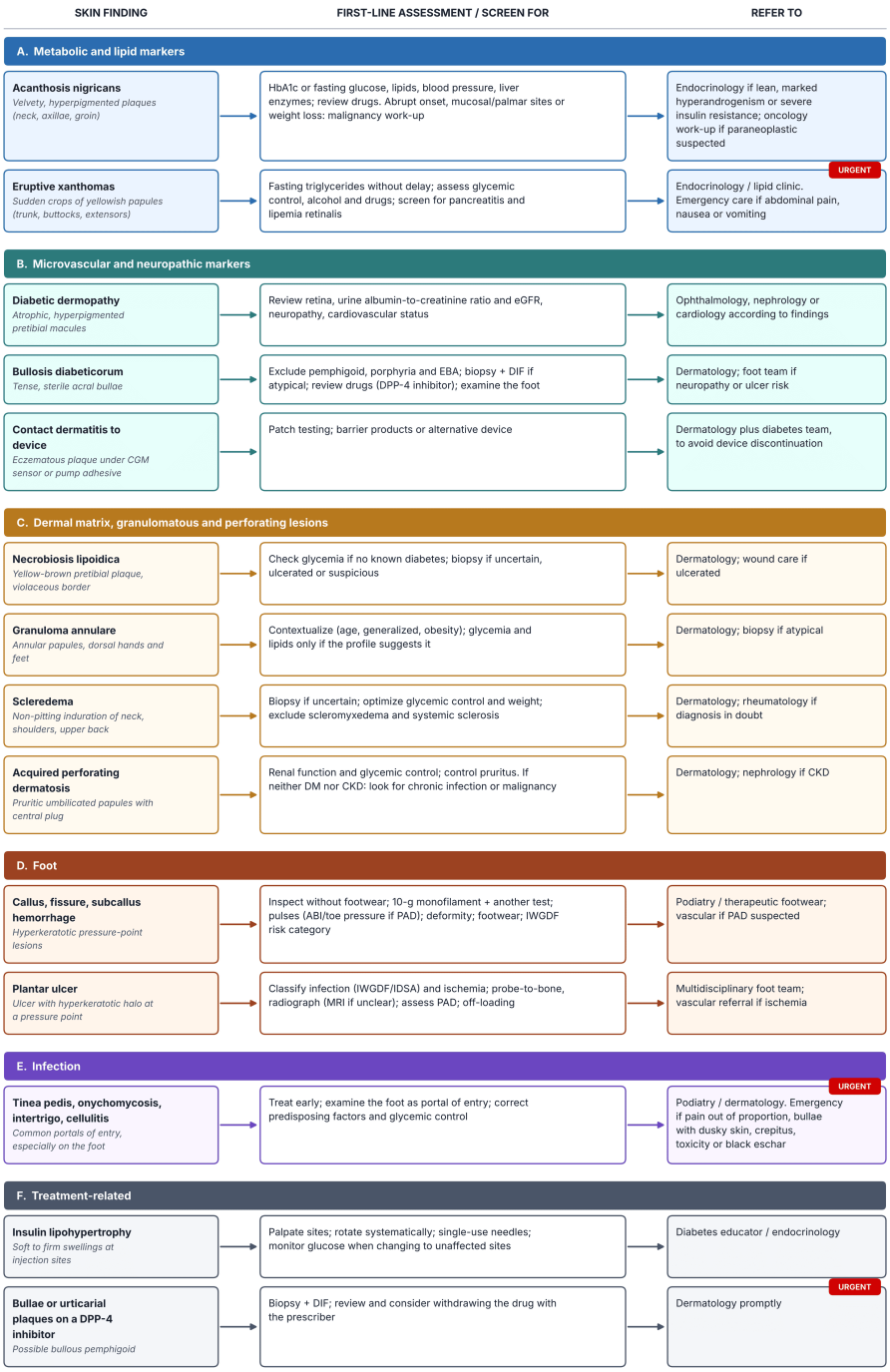

FIGURE 2: Mechanism-based approach linking skin findings to assessment and referral in people with DM

Each row links a cutaneous finding to its first-line assessment or screening and to the suggested referral. Findings are grouped by predominant mechanism: (A) metabolic and lipid markers, (B) microvascular and neuropathic markers, (C) dermal matrix, granulomatous, and perforating lesions, (D) foot, (E) infection, and (F) treatment-related effects. "Urgent" flags findings that require prompt evaluation. This figure is a practical synthesis of the cited literature and does not replace clinical judgment or local protocols.

ABI: ankle-brachial index; CGM: continuous glucose monitoring; CKD: chronic kidney disease; DIF: direct immunofluorescence; DM: diabetes mellitus; EBA: epidermolysis bullosa acquisita; eGFR: estimated glomerular filtration rate; IDSA: Infectious Diseases Society of America; IWGDF: International Working Group on the Diabetic Foot; PAD: peripheral arterial disease

Acanthosis Nigricans

AN presents as hyperpigmented, velvety, thickened plaques mainly on the neck, axillae, groin, and other flexures. It is a classic cutaneous marker of insulin resistance; hyperinsulinemia-driven mitogenic signaling "spillover" (including IGF-1R activation and PI3K/AKT/mTOR pathways) promotes epidermal and dermal proliferation, explaining its hyperkeratotic/papillomatous pattern (Figure *1A*) [5,10]. The association with insulin resistance and type 2 diabetes mellitus (T2DM) is strong, but AN is not specific to either.

In T2DM, obesity, or metabolic syndrome, AN should prompt cardiometabolic evaluation and screening for insulin resistance-related comorbidities. In children, AN is a recognized sign of insulin resistance that is included among the risk factors used to decide whom to test for T2DM [11]. However, AN must be distinguished from non-obesity/T2DM forms, including the following: (a) drug-induced AN, (b) endocrinopathies with disproportionate insulin resistance (e.g., severe insulin resistance syndromes), and (c) genetic/metabolic syndromes (e.g., lipodystrophies), particularly in relatively lean patients with marked hyperandrogenism, disproportionate fatty liver, hypertriglyceridemia, or difficult-to-control hyperglycemia [12-14].

Beyond cosmetic concern, AN can cause pruritus, malodor from maceration in flexures, and psychosocial distress. Its presence in a young patient with obesity, a family history of T2DM, or features of polycystic ovary syndrome should prompt the evaluation of glycemia (hemoglobin A1c (HbA1c) or fasting glucose), lipids, blood pressure, and liver enzymes [1,2,12]. Abrupt onset, rapid progression, unusual sites (palms, mucosae), or concomitant weight loss should raise suspicion of paraneoplastic AN, particularly in older adults, and warrant age-appropriate malignancy evaluation (Figure *2*). Management is directed at the underlying cause: weight reduction, physical activity, and, when indicated, insulin-sensitizing therapy such as metformin may improve both metabolic parameters and skin appearance, whereas topical keratolytics or retinoids and procedural options are adjunctive and often give only partial or temporary improvement [1,2].

Eruptive Xanthomas and Hypertriglyceridemia

Eruptive xanthomas are a sentinel sign of severe hypertriglyceridemia or chylomicronemia, typically visible at triglyceride (TG) levels ⩾1000 mg/dL, though pancreatitis risk rises from ⩾500 mg/dL. They present as sudden crops of yellowish, sometimes pruritic papules on the trunk, buttocks, and extensor surfaces, warranting urgent fasting TG confirmation and targeted screening for lipemia retinalis and pancreatitis symptoms (abdominal pain, nausea, vomiting) [15,16]. Their association is strong with severe hypertriglyceridemia rather than with DM itself, and uncontrolled DM is one of the several precipitating factors.

In diabetic patients, these xanthomas typically reflect multifactorial chylomicronemia driven by hyperglycemia/insulinopenia or insulin resistance, which impairs TG-rich lipoprotein clearance via lipoprotein lipase (LPL) dysfunction. Obesity and alcohol use frequently coexist as aggravating factors [17,18].

Initial management targets ruling out pancreatitis and lowering TG: fasting lipid profile, glycemic control assessment, and review of alcohol and concomitant medication use. TG ⩾1000 mg/dL warrants a very-low-fat diet with elimination of alcohol and simple sugars; TG ⩾500 mg/dL warrants considering TG-lowering therapy (e.g., fibrates or prescription omega-3s) alongside optimized metabolic control. Lesions resolve once TG levels normalize [16,19].

Necrobiosis Lipoidica

NL is a chronic granulomatous dermatosis with predilection for the legs (particularly pretibial), presenting as well-demarcated plaques with an erythematous-violaceous border and a center that progresses to a yellow-brown, atrophic, telangiectatic appearance, with ulceration as a relevant complication (Figure *1B*) [20,21]. Although clinically associated with DM, it is not exclusive to diabetic patients; in a multicenter retrospective cohort of 236 cases, 58.5% of NL patients had diabetes [22]. Because this cohort was drawn from specialized centers, the proportion with diabetes may overestimate that of NL in the general population. Lower-extremity involvement is highly consistent (97.8% in the same cohort [22]), supporting its descriptive value in clinical characterization. In a single-center primary care study, NL was also associated with microangiopathy (OR: 9.7) [23]. Taken together, the association with DM is moderate.

Pathogenesis remains incompletely understood; current evidence supports a multifactorial model involving microangiopathic changes, possible immune complex deposition, and autoimmune/inflammatory phenomena with collagen degeneration and granuloma formation, where trauma may precipitate ulceration in established plaques [24,25]. Diagnosis is typically clinical and dermoscopic in typical presentations, but biopsy is recommended when the presentation is uncertain, ulceration is present, or features suggestive of malignant transformation arise (rare but reported in chronic ulcerated NL). Key differential diagnoses include GA, cutaneous sarcoidosis, and necrobiotic xanthogranuloma, among other granulomatous dermatoses; distinction relies on clinicopathologic correlation and, when needed, histology [26].

Because NL plaques may precede the diagnosis of DM, glycemia should be assessed in patients with NL and

no known diabetes, in view of the high proportion of diabetic patients in published cohorts [22]. The course is chronic and unpredictable, and NL activity does not reliably track glycemic control, although metabolic optimization remains part of comprehensive care [1,2]. Therapeutic evidence derives mainly from small series and case reports: potent topical or intralesional corticosteroids (used cautiously because of the risk of atrophy and avoided on ulcerated or markedly atrophic areas), topical calcineurin inhibitors, and phototherapy are commonly used for active plaques, whereas refractory or ulcerated disease may require wound care, compression when venous disease coexists, and systemic immunomodulatory therapy under specialist guidance [24,25].

Granuloma Annulare

GA is a benign inflammatory dermatosis typically presenting as firm papules in an annular configuration (Figure *1C*), usually asymptomatic, with predilection for the dorsal hands/feet and extensor surfaces. Localized, generalized, subcutaneous, and perforating variants are recognized, with distinct implications for extent, recurrence, and treatment approach [27].

The association between GA and DM is modest and nonspecific. In a large population-based cohort, people with GA had higher odds of prevalent diabetes (adjusted OR: 1.67; 95% CI: 1.55-1.80) and of incident diabetes (adjusted OR: 1.31; 95% CI: 1.10-1.57) than matched controls [28], and a systematic review and meta-analysis of nine studies also reported a significant association with T2DM (pooled OR: 1.53; 95% CI: 1.18-2.00; I^2: 55.1%) [29]. However, another case-control study found a higher diabetes prevalence in GA that was not significant after multivariable adjustment [30]. The association is more frequently reported in generalized or adult-onset GA, and the overall evidence, with its modest effect size and heterogeneity across studies, does not support the use of GA as a specific marker of the disease. Accordingly, GA findings should be contextualized (age, phenotype, especially if generalized, presence of obesity/metabolic syndrome, or other risk factors), with metabolic evaluation warranted when the clinical profile justifies it, rather than assuming a direct link to diabetes [27-31].

Localized GA often resolves spontaneously over months to years, and recurrence is common; treatment is therefore individualized to symptoms, cosmesis, and extent. Potent topical or intralesional corticosteroids are commonly used first for localized disease, while generalized or refractory GA may require phototherapy or systemic agents, with supporting evidence limited largely to small studies [27,31]. Biopsy helps to distinguish GA from NL, sarcoidosis, and necrobiotic xanthogranuloma when the clinical pattern is atypical. Recent spatial transcriptomic work has shown organized and distinct immune activation across cutaneous granulomatous disorders [26], and updated molecular reviews [31] suggest that pathway-directed therapies may become available, although this remains investigational.

Hyperkeratotic Lesions and Keratoderma

Calluses are the most common pre-ulcerative lesion of the diabetic foot (Figure *1D*); the framework for risk stratification and ulcer care is presented in the Diabetic Foot section. Callus identification warrants targeted assessment to stratify risk and rule out occult ulceration: inspection with footwear and socks removed, evaluation of pressure points, deformities, subcallus hemorrhage or fissures, LOPS testing with a 10-g monofilament (ideally combined with another neurologic test), peripheral vascular assessment (pulses, with further evaluation if PAD is suspected), and footwear and fit review [4,32,33].

Preventive management focuses on reducing plantar pressure and treating excess callus. The International Working Group on the Diabetic Foot (IWGDF) guidelines recommend treating callus and pre-ulcerative lesions to prevent ulceration (strong recommendation, very-low-certainty evidence), based on indirect evidence that callus debridement reduces this biomechanical driver of ulceration [34]. Hyperkeratotic lesions are therefore a strong risk factor for ulceration in guidelines, although the evidence for callus treatment itself is of very low certainty and the lesion is not a DM-specific dermatosis. Callus on a foot with LOPS should be debrided by trained personnel, and patients should be advised against self-treatment with blades or chemical corn removers [4,34]. Patients with deformities or concomitant PAD should be referred for podiatry/therapeutic footwear services and close monitoring [35].

Other relevant cutaneous manifestations

Diabetic Dermopathy

Diabetic dermopathy presents as hyperpigmented, atrophic macules/papules ("shin spots"), oval or round, predominantly pretibial. It is generally asymptomatic and requires no specific treatment. Its clinical relevance lies in its association with vascular complications: observational data, including a single-center primary care study of 213 patients in which dermopathy was associated with macroangiopathy (OR: 1.86), link it with microvascular, cardiovascular, and renal complications (retinopathy, nephropathy, neuropathy) [23,36]. This supports a low threshold to review retinal, renal (urine albumin-to-creatinine ratio and estimated glomerular filtration rate (eGFR)), neurologic, and cardiovascular status in patients with extensive lesions or poor metabolic control [23,36-38]. The association is moderate and rests on observational studies.

Lesions typically appear in crops over months and resolve over one to two years, leaving shallow atrophic, hyperpigmented scars. The main differential includes stasis changes, post-traumatic scars, and, when plaques or ulceration is present, NL.

Bullosis Diabeticorum

Bullosis diabeticorum presents as tense, sterile, spontaneous, non-inflammatory, typically painless bullae with predilection for acral areas (feet and legs; less commonly hands/forearms). It has been linked to neuropathy and microangiopathy (thickened capillaries within lesions), with an incompletely established mechanism, and the evidence derives mainly from case reports and small series. Clinically, it matters due to superinfection risk and potential progression to chronic diabetic foot ulcers. Diagnosis requires excluding bullous pemphigoid, porphyria/pseudoporphyria, and epidermolysis bullosa acquisita; biopsy with direct immunofluorescence may help rule out autoimmune bullous disease in atypical presentations [38-41].

Bullae usually heal spontaneously within a few weeks, often leaving little or no scarring. Management is conservative: protecting the lesion, leaving the blister roof intact where possible, aspirating large tense bullae under sterile conditions, applying non-adherent dressings and, if needed, topical antiseptics, and treating secondary infection promptly. Pressure and friction from footwear should be minimized, and the foot should be examined for neuropathy, deformity, and vascular insufficiency, given the risk of progression to chronic ulceration [38-41].

Acquired Perforating Dermatosis

APD (including reactive perforating collagenosis) presents as intensely pruritic, umbilicated, hyperkeratotic papules or nodules with a central plug, predominantly on the extremities. It is especially common in patients with DM and chronic kidney disease (CKD), where pruritus and scratching (Koebner phenomenon) appear to contribute to transepidermal elimination of dermal material. In a systematic review of mostly case reports and small series, about 58% of the patients had DM and about 29% had chronic renal failure [42], and a single-center series reached similar conclusions [43,44]. The evidence is therefore limited. In patients with neither DM nor CKD, APD has also been reported with other systemic conditions, and a search for chronic infection or occult malignancy is reasonable [42,44].

Diagnosis is confirmed histologically (transepidermal elimination), with dermoscopy supporting clinical recognition. Management focuses on controlling pruritus/scratching and treating comorbidities (DM/CKD), as treatment response is variable and evidence derives mainly from case series and reports [43,45]. Reported treatments include emollients, topical keratolytics and corticosteroids, narrowband ultraviolet B (UVB) phototherapy, and systemic agents such as allopurinol or doxycycline, but the supporting evidence is of low quality and responses are heterogeneous [45]. Because the lesions are driven by scratching and often by uremic or diabetic pruritus, addressing the itch (e.g., with emollients and optimization of renal and metabolic control) is as important as lesion-directed therapy [43,45].

Scleredema Diabeticorum

Scleredema diabeticorum (DM-associated Buschke's scleredema) is characterized by symmetric, non-pitting thickening and induration, typically of the posterior neck, shoulders, and upper back, more common in long-standing T2DM and obesity. It relates to collagen and dermal matrix alterations driven by advanced glycation and may coexist with other "thickened skin" markers in DM [8]. Screening studies in small cohorts of people with diabetes have reported prevalences between 2.5% and 14% [46], and a recent scoping review found that the available evidence consists mainly of case reports and case series [47]; the evidence for this association is therefore limited.

In contrast to scleroderma, Raynaud phenomenon, sclerodactyly, and systemic organ involvement are absent, and the induration is non-pitting without a sharp margin. When the diagnosis is uncertain, biopsy shows thickened collagen bundles with widened fenestrations, and the differential includes scleromyxedema and systemic sclerosis. Scleredema may impair neck and shoulder mobility and chest expansion, and its course does not reliably follow glycemic control. Reported treatments, supported mainly by small series, include phototherapy (ultraviolet A1 (UVA1) or psoralen plus ultraviolet A (PUVA)), methotrexate, and physical therapy, in addition to metabolic optimization [1,8,47].

Cutaneous Infections

People with DM show increased susceptibility to bacterial and fungal infections due to immune dysfunction, microangiopathy, neuropathy, hyperglycemia, and impaired tissue repair. In a large matched cohort from primary care, people with type 1 and type 2 diabetes had higher rates of infection than matched controls, with cellulitis among the infections showing the highest rate ratios [48]; evidence for fungal infections derives mainly from reviews [49]. The association is therefore strong for bacterial skin and soft-tissue infection. Clinically, prompt identification and treatment of tinea pedis/onychomycosis (given their role as entry points), candidiasis/intertrigo, erythrasma, cellulitis, and soft-tissue infections is essential,

particularly when affecting the foot [49].

Bacterial infections include impetigo, folliculitis, furunculosis, erysipelas, and cellulitis, most commonly caused by *Staphylococcus aureus* and beta-hemolytic streptococci, whereas erythrasma (*Corynebacterium minutissimum*) characteristically involves the intertriginous areas. Fungal infections include candidal intertrigo, balanitis, and vulvovaginitis, as well as dermatophyte infections such as tinea pedis, tinea cruris, and onychomycosis. In the foot, interdigital maceration and tinea pedis are portals of entry for cellulitis, so treating them is part of ulcer prevention [4,49]. Severe pain out of proportion to the findings, dusky discoloration with bullae, crepitus, or systemic toxicity should prompt emergency evaluation for necrotizing soft-tissue infection, and black eschar in a patient with ketoacidosis should raise concern for invasive mucormycosis [1,49].

Other Common Cutaneous Findings

Several additional findings are common but less specific. Acrochordons (skin tags) of the neck, axillae, and groin cluster with AN and are markers of insulin resistance. Xerosis and pruritus are frequent, partly reflecting autonomic neuropathy with reduced sweating and impaired barrier function; generalized pruritus should also prompt consideration of renal, hepatic, and thyroid causes, whereas localized genital pruritus suggests candidiasis. Limited joint mobility with thick, waxy skin of the dorsal hands (digital sclerosis or diabetic cheiroarthropathy), detected with the "prayer sign," tracks with disease duration and microvascular complications and may coexist with scleredema. In type 1 diabetes, autoimmune dermatoses such as vitiligo are more frequent than in the general population, reflecting shared autoimmune predisposition, and should prompt attention to coexisting thyroid autoimmunity [1,2,49].

Diabetic foot

Burden and Risk Factors

The diabetic foot is a multisystem complication of DM (not merely cutaneous), characterized by ulceration, infection, and/or deep tissue destruction, generally associated with peripheral neuropathy and/or PAD. Risk of diabetic foot in primary care populations is associated with identifiable clinical factors, and cross-sectional analyses of foot ulcers underscore the value of structured risk-factor management [50,51]. Nearly 50% of people with foot ulcers have concomitant PAD, increasing the risk of adverse events and amputation [33,52]. Diabetic foot ulcers affect an estimated 18.6 million people worldwide each year [33]. Outcomes are poor: about 30% of patients with a diabetic foot ulcer die within five years, a figure that exceeds 70% after major amputation, and only 30-40% of ulcers heal by 12 weeks [33]. Even after healing, ulcer recurrence is estimated at 42% at one year and 65% at five years [33], which is why remission-focused prevention is emphasized in current guidelines [4,34].

Pathophysiology

The diabetic foot combines the following: (1) sensory neuropathy, causing unnoticed trauma from loss of protective pain sensation; (2) motor neuropathy, causing deformities (claw toes) and abnormal pressure redistribution; (3) autonomic neuropathy, causing xerosis, fissures, and skin barrier damage; and (4) PAD, causing hypoperfusion, poor healing, and increased necrosis and infection risk. Neuropathic involvement may also progress to active Charcot neuro-osteoarthropathy, for which dedicated IWGDF guidance addresses diagnosis and treatment [53]. The resulting lesion typically reflects repetitive mechanical stress on a foot with LOPS and deformity, classically presenting as a plantar neuropathic ulcer (mal perforant plantar) with a surrounding hyperkeratotic halo at a pressure point (Figure *1E*); accordingly, IWGDF guidelines emphasize off-loading as central to healing and recurrence prevention [4,33].

Risk Stratification and Assessment

Foot examination should follow the IWGDF risk-stratification framework, which links LOPS, PAD, foot deformity, prior ulceration, or amputation to the frequency of foot screening: from annually for very-low-risk feet (no LOPS and no PAD) to every 1-3 months for the highest-risk category (LOPS or PAD plus prior ulcer, amputation, or end-stage renal disease) [4]. The examination should identify pre-ulcerative lesions and modifiable risk factors (calluses, fissures, subcallus hemorrhage, deformities, interdigital maceration/tinea pedis, nail changes, and occult ulcers), alongside LOPS testing and PAD signs (pedal/tibial pulses; referral for ankle-brachial index (ABI)/toe pressures if suspected) [34].

Once an ulcer is present, assessment should be systematic, since tissue loss, infection, and ischemia determine prognosis and the need for referral [33]. Soft-tissue infection is diagnosed clinically from local or systemic signs of inflammation and graded with the IWGDF/Infectious Diseases Society of America (IDSA) classification, with inflammatory markers considered when the clinical diagnosis is uncertain; osteomyelitis should be suspected in deep, long-standing, or probe-to-bone ulcers and evaluated with plain radiography, with MRI when uncertainty persists [54]. In parallel, PAD should be assessed, and vascular referral considered when ischemia is suspected, because revascularization may be required for healing [35,52].

Prevention

Prevention integrates structured education (daily inspection, hygiene and hydration avoiding interdigital spaces, avoiding barefoot walking), management of pre-ulcerative lesions, therapeutic footwear with demonstrated plantar pressure reduction in high-risk patients, and follow-up by specialized teams (podiatry, vascular, rehabilitation, wound care) in moderate- to high-risk cases. Per IWGDF, plantar temperature monitoring reduces ulcer recurrence (five RCTs; RR: 0.51; 95% CI: 0.31-0.84), while combined integrated preventive foot care shows an inconclusive effect (three RCTs; RR: 0.78; 95% CI: 0.58-1.06) [34].

Off-Loading and Ulcer Treatment

In established ulcers, off-loading is the intervention with the strongest evidence for healing: in a systematic review, non-removable devices achieved higher healing rates than removable devices (14 studies; n=1083; RR: 1.24; 95% CI: 1.09-1.41) [55]. The choice of device, however, depends on the type and location of the ulcer, the severity of infection and ischemia, and the patient's tolerance [56]. For neuropathic plantar forefoot and midfoot ulcers, the IWGDF 2023 guideline recommends a non-removable knee-high device (a total contact cast or a removable knee-high walker rendered non-removable) as the first choice. If it is contraindicated or not tolerated, a removable knee-high or ankle-high device is the second choice, and when no device is available, appropriately fitting footwear combined with felted foam may be considered as a third choice [56]. If non-surgical off-loading fails, surgical off-loading (e.g., Achilles tendon lengthening, metatarsal head resection, joint arthroplasty, or metatarsal osteotomy) can be considered for plantar forefoot ulcers, and digital flexor tendon tenotomy is recommended for plantar or apex ulcers of the lesser toes secondary to flexible toe deformity [56].

Non-removable devices are therefore not appropriate for every ulcer. Ulcers complicated by infection or ischemia, plantar heel ulcers, and non-plantar ulcers each have separate IWGDF recommendations; with increasing severity of infection or ischemia, removable devices are favored, and treating the infection or ischemia takes priority [56]. In practice, three questions guide the choice: where is the ulcer (plantar forefoot or midfoot, heel, or non-plantar); how severe are infection and ischemia; and can the patient tolerate and adhere to a non-removable device?

Beyond off-loading, ulcer care includes sharp debridement of nonviable tissue and surrounding callus, appropriate dressings, infection control, and treatment of ischemia, with early referral to a multidisciplinary team [33]. These measures target the impaired-repair mechanisms discussed above, namely, persistent inflammation, oxidative stress, and defective keratinocyte migration [6,7].

Cutaneous adverse effects of diabetes therapy and devices

Insulin-induced lipohypertrophy is the most common cutaneous complication of insulin therapy. A meta-analysis of studies including more than 26,000 participants estimated its prevalence at 41.8% (95% CI: 35.9-47.6), with higher prevalence in those with longer insulin exposure [57]. It presents as soft-to-firm, rubbery subcutaneous swellings at injection or infusion sites, which are often detected more reliably by palpation than by inspection. Repeated injection into the same site and needle reuse are the principal modifiable risk factors [58]. Its consequences extend beyond appearance: insulin absorption from lipohypertrophic tissue is erratic, and a meta-analysis found that affected patients had more unexplained hypoglycemia, greater glycemic variability, higher HbA1c (mean difference: 0.55 percentage points), and higher daily insulin requirements (mean difference: 7.68 IU) than those without lipohypertrophy [59]. Routine palpation of injection sites, systematic site rotation, single use of needles, and glucose monitoring when changing to unaffected sites are therefore standard preventive measures [58,59]. Insulin lipoatrophy has become uncommon with modern insulins [1,2].

Adhesives and components of continuous glucose monitoring (CGM) sensors and insulin infusion sets can cause irritant or allergic contact dermatitis. CGM is used by people of all ages with type 1 or type 2 diabetes, not only by children and adolescents with type 1 diabetes: the current American Diabetes Association (ADA) Standards of Care recommend that CGM be offered to adults and youth with diabetes treated with insulin and encourage the early consideration of diabetes technology [60]. Device-related skin reactions are therefore relevant across age groups and diabetes types. In a systematic review of 54 studies, cutaneous complications occurred at a rate of about one event per eight weeks of sensor wear, with severe reactions in about 1.5% [61], and a systematic review including both children and adults with type 1 diabetes found that dermatitis is common but that the skin diagnosis is rarely specified [62]. Acrylates, especially isobornyl acrylate, are the most commonly implicated allergens, followed by cyanoacrylates, colophonium, epoxy resin, and nickel; repeated occlusion and maceration also disrupt the skin barrier and contribute to lesions [63]. Because reactions may lead patients to abandon devices that improve glycemic control, a dermatologic evaluation including patch testing with an appropriate series, and close collaboration between dermatology and diabetes teams, is advisable [63].

Glucose-lowering drugs may also produce cutaneous effects. The best characterized is bullous pemphigoid associated with dipeptidyl peptidase-4 (DPP-4) inhibitors. A meta-analysis of case-control studies found an

increased risk with these agents (pooled OR: 1.92; 95% CI: 1.55-2.38) [64], and a meta-analysis of randomized trials found significantly increased odds (Mantel-Haenszel OR: 4.44; 95% CI: 1.31-15.00), although this estimate is imprecise because it rests on few events and the absolute risk is low [65]. In a patient with DM who develops tense bullae or intensely pruritic urticarial plaques while taking a DPP-4 inhibitor, biopsy with direct immunofluorescence and review of the drug are warranted, and the condition should be distinguished from bullosis diabeticorum (Table *1*) [39-41,65].

Entity	Key clinical finding	Association with DM (strength; basis of evidence)	Management/what to screen	Reference
A. Diabetes complications (neuropathic/vascular)				
Diabetic foot ulcer	Plantar ulcer (often with hyperkeratotic halo), infection ± ischemia; deformity may coexist	Strong (clinical practice guidelines). Defining complication; commonly coexists with LOPS and/or PAD (~50% of ulcers)	Prevention: education, inspection, management of calluses/pre-ulcerative lesions, footwear. Ulcer: classify infection/ischemia; off-loading (non-removable devices for neuropathic plantar forefoot/midfoot ulcers)	[4,33,50-52,55,56]
Hyperkeratotic lesions/plantar callus	Calluses, fissures, subcallus hemorrhage at pressure points; possible occult ulcer	Strong as a pre-ulcerative risk factor (guidelines); evidence for callus treatment is of very low certainty; not a DM-specific dermatosis	Inspection without footwear; 10-g monofilament + another test; PAD screening; debridement by trained personnel	[4,32-34]
B. Diabetes-associated dermatoses (frequent in DM, not exclusive)				
Cutaneous infections	Tinea pedis/onychomycosis, intertrigo, erythrasma, cellulitis	Strong for bacterial skin/soft-tissue infection (large matched cohort); fungal infections supported mainly by a narrative review	Early treatment; foot as entry point; correct predisposing factors	[48,49]
Diabetic dermopathy	Atrophic, hyperpigmented pretibial macules/papules ("shin spots")	Moderate (observational studies); associated with vascular complications (single-center primary care study: OR 1.86 with macroangiopathy)	No specific treatment; evaluate microvascular and cardiovascular status	[23,36-38]
Necrobiosis lipoidica	Yellow-brown pretibial plaque with erythematous-violaceous border and central atrophy	Moderate: 58.5% with DM, 97.8% on the legs (n=236; specialized-center cohort); OR 9.7 with microangiopathy (single primary care study)	Clinical/dermoscopic diagnosis; biopsy if uncertain or ulcerated; stepwise treatment	[20-25]
Acquired perforating dermatosis	Umbilicated, pruritic, hyperkeratotic papules with central plug; Koebner phenomenon	Limited (single-center series; systematic review of case reports and small series); most often with DM and/or CKD	Confirm histology if uncertain; control pruritus/scratching; optimize DM/renal function	[42-45]
Scleredema diabeticorum	Non-pitting induration of the neck, shoulders, and upper back	Limited (case reports/series; prevalence 2.5-14% in small screening cohorts); long-standing T2DM, obesity	Biopsy if diagnostic uncertainty; optimize metabolic control and weight	[8,46,47]
Bullosis diabeticorum	Tense, sterile, spontaneous bullae, acral distribution	Limited (case reports and small series); mechanism uncertain (neuropathy/microangiopathy)	Prevent superinfection; rule out pemphigoid/EBA/porphyria; biopsy + DIF if atypical	[38-41]
C. Markers of insulin resistance or of other metabolic disorders (not DM-specific)				
Acanthosis nigricans	Hyperpigmented, velvety plaques in flexures (neck, axillae, groin)	Strong for insulin resistance/T2DM (guideline-recognized marker); not specific (drugs, endocrinopathies, genetic syndromes)	Cardiometabolic evaluation; broaden work-up if abrupt onset, mucosal involvement, or weight loss	[5,10-14]
Eruptive xanthomas	Sudden-onset yellowish papules on the trunk/buttocks	Strong for severe hypertriglyceridemia; not DM-specific (multifactorial chylomicronemia; uncontrolled DM is one precipitant)	Urgent fasting TG; rule out pancreatitis; very-low-fat diet + triglyceride-lowering agents	[15-19]
D. Nonspecific association				
		Moderate (modest effect size): baseline DM		

Granuloma annulare	Annular papules, dorsal hands/feet	aOR 1.67 in a large cohort, not significant after adjustment in another study; not a specific marker	Dermatologic management by extent; metabolic evaluation only if the phenotype suggests it	[27-31]
E. Treatment- and device-related (not disease-intrinsic)				
Insulin lipohypertrophy	Soft-to-firm, rubbery subcutaneous swellings at injection/infusion sites, best detected by palpation	Treatment-related; pooled prevalence ~42% in insulin-treated DM; associated with glycemic variability and unexplained hypoglycemia	Palpate injection sites; rotate sites; single-use needles; monitor glucose when changing to unaffected sites	[57-59]
Contact dermatitis to CGM sensors/insulin pump adhesives	Eczematous, sharply demarcated plaque beneath the adhesive; pruritus; may lead to device discontinuation	Device-related; relevant across age groups and diabetes types in device users (~1 event per 8 weeks of sensor wear, ~1.5% severe); acrylates (e.g., isobornyl acrylate) most frequent allergens	Patch testing; barrier products or alternative devices; dermatology-diabetes team collaboration	[60-63]
DPP-4 inhibitor-associated bullous pemphigoid	Tense bullae ± urticarial, pruritic plaques in a patient taking a gliptin	Drug-related; pooled OR 1.92 (95% CI: 1.55-2.38) in case-control meta-analysis; OR 4.44 (1.31-15.00) in RCT meta-analysis (few events); absolute risk low	Biopsy + DIF; review/withdraw the drug; distinguish from bullosis diabeticorum	[39-41,64,65]

TABLE 1: Main dermatologic manifestations of DM: relationship with DM, strength of association, and clinical management

Entities are grouped by the nature of their relationship with DM, which is distinct from the strength of the evidence. Strength of association was assigned by the authors according to the highest level of evidence among the cited references, following the hierarchy described in Methods: strong = consistent findings in clinical practice guidelines, systematic reviews/meta-analyses, or large cohort studies; moderate = findings from observational studies with variable effect sizes or heterogeneity across populations; and limited/inconsistent = conflicting results or evidence restricted to small series and case reports. Strength categories were not assigned to treatment- and device-related entities, which are defined by exposure rather than by association with the disease. Prevalence and effect estimates derive from the specific populations and designs of the cited studies and should not be generalized beyond them.

DM: diabetes mellitus; T2DM: type 2 diabetes mellitus; PAD: peripheral arterial disease; LOPS: loss of protective sensation; CKD: chronic kidney disease; TG: triglycerides; EBA: epidermolysis bullosa acquisita; DIF: direct immunofluorescence; CGM: continuous glucose monitoring; aOR: adjusted odds ratio; OR: odds ratio; RCT: randomized controlled trial

Conclusions

Diabetes leaves a distinct signature on the skin, spanning insulin-resistance markers such as AN to microangiopathy-, neuropathy-, and collagen-related lesions, heightened infectious susceptibility, and impaired wound healing. The strength of association with DM varies widely: diabetic foot disease and bacterial skin infection are strongly linked, NL, diabetic dermopathy, and GA show moderate or modest associations, and bullosis diabeticorum, scleredema, and APD rest on limited evidence. Because several findings, including eruptive xanthomas and AN, are not specific to DM, they should be interpreted alongside their differential diagnoses rather than treated as pathognomonic. Recognizing these manifestations early can prompt timely screening for systemic microvascular complications and metabolic derangement. Among them, the diabetic foot stands out for its disproportionate morbidity, amputation risk, and mortality burden, warranting a dedicated diagnostic and preventive approach within any dermatologic assessment of diabetes. A systematic, mechanism-based approach to these cutaneous clues can strengthen early diagnosis, guide interdisciplinary referral, and ultimately improve outcomes in this population.

Appendices

Appendix A

PubMed Search Strategy (Last Search: October 23, 2026)

Block 1 (diabetes): “Diabetes Mellitus”[MeSH Terms] OR diabetes[Title/Abstract] OR “diabetes mellitus”[Title/Abstract] OR diabetic[Title/Abstract]

Block 2 (cutaneous manifestations): “Skin Diseases”[MeSH Terms] OR “Skin Manifestations”[MeSH Terms] OR “Acanthosis Nigricans”[MeSH Terms] OR “Necrobiosis Lipoidica”[MeSH Terms] OR “Granuloma Annulare”[MeSH Terms] OR “Diabetic Angiopathies”[MeSH Terms] OR “Hyperkeratosis”[MeSH Terms] OR “Keratoderma, Palmoplantar”[MeSH Terms] OR “Skin Diseases, Infectious”[MeSH Terms] OR “cutaneous manifestations”[Title/Abstract] OR “skin diseases”[Title/Abstract] OR “acanthosis nigricans”[Title/Abstract]

OR “necrobiosis lipoidica”[Title/Abstract] OR “granuloma annulare”[Title/Abstract] OR “diabetic dermopathy”[Title/Abstract] OR “bullosis diabeticorum”[Title/Abstract] OR “diabetic bullae”[Title/Abstract] OR “scleredema diabeticorum”[Title/Abstract] OR “scleredema”[Title/Abstract] OR “acquired perforating dermatosis”[Title/Abstract] OR “cutaneous infection*”[Title/Abstract] OR “skin infection*”[Title/Abstract] OR hyperkeratosis[Title/Abstract] OR keratoderma[Title/Abstract]

Block 3 (diabetic foot): “Diabetic Foot”[MeSH Terms] OR “Diabetic Neuropathies”[MeSH Terms] OR “Peripheral Arterial Disease”[MeSH Terms] OR “diabetic foot”[Title/Abstract] OR “diabetic foot ulcer*”[Title/Abstract] OR neuropath*[Title/Abstract] OR “peripheral arterial disease”[Title/Abstract] OR “peripheral artery disease”[Title/Abstract] OR prevention[Title/Abstract] OR guideline*[Title/Abstract]

Final searches: (Block 1) AND (Block 2) for the general search, and (Block 1) AND (Block 3) for the diabetic foot search. Filters: publication date “2016/01/01”[Date - Publication] : “2026/10/23”[Date - Publication]; language: English.

Additional Information

Author Contributions

All authors have reviewed the final version to be published and agreed to be accountable for all aspects of the work.

Concept and design: Carlos Berrocal, Andrés David Sastre Martinez, Cesar Ivan Varela Hernández, Isabella Rodríguez Niño, Luisa Fernanda Amaya Machado, María Alejandra Benavides Cañola, Jhon Herney Quintana Ospina, Andrés Felipe García Ramos

Acquisition, analysis, or interpretation of data: Carlos Berrocal, Cesar Ivan Varela Hernández

Drafting of the manuscript: Carlos Berrocal

Critical review of the manuscript for important intellectual content: Carlos Berrocal, Andrés David Sastre Martinez, Cesar Ivan Varela Hernández, Isabella Rodríguez Niño, Luisa Fernanda Amaya Machado, María Alejandra Benavides Cañola, Jhon Herney Quintana Ospina, Andrés Felipe García Ramos

Supervision: Carlos Berrocal, Cesar Ivan Varela Hernández

Disclosures

Conflicts of interest: In compliance with the ICMJE uniform disclosure form, all authors declare the following: **Payment/services info:** All authors have declared that no financial support was received from any organization for the submitted work. **Financial relationships:** All authors have declared that they have no financial relationships at present or within the previous three years with any organizations that might have an interest in the submitted work. **Other relationships:** All authors have declared that there are no other relationships or activities that could appear to have influenced the submitted work.

References

1. Lima AL, Illing T, Schliemann S, Elsner P: Cutaneous manifestations of diabetes mellitus: a review . Am J Clin Dermatol. 2017, 18:541-53. 10.1007/s40257-017-0275-z
2. Hines A, Alavi A, Davis MD: Cutaneous manifestations of diabetes. Med Clin North Am. 2021, 105:681-97. 10.1016/j.mcna.2021.04.008
3. de Macedo GM, Nunes S, Barreto T: Skin disorders in diabetes mellitus: an epidemiology and physiopathology review. Diabetol Metab Syndr. 2016, 8:63. 10.1186/s13098-016-0176-y
4. Schaper NC, van Netten JJ, Apelqvist J, et al.: Practical guidelines on the prevention and management of diabetes-related foot disease (IWGDF 2023 update). Diabetes Metab Res Rev. 2024, 40:e3657. 10.1002/dmrr.3657
5. Fuentes-Mendoza JM, Concepción-Zavaleta MJ, Villanueva-De La Cruz JP, et al.: Skin as a mirror of endocrine diseases: emerging biomarkers and targeted therapies. Curr Med Res Opin. 2026, 42:723-38. 10.1080/03007995.2026.2682580
6. Deng L, Du C, Song P, Chen T, Rui S, Armstrong DG, Deng W: The role of oxidative stress and antioxidants in diabetic wound healing. Oxid Med Cell Longev. 2021, 2021:8852759. 10.1155/2021/8852759
7. Moon JY, Wolf SJ, Joshi AD, et al.: IL-17A is increased in diabetic wounds and impairs keratinocyte function via histone demethylase JMJD3. Nat Commun. 2025, 17:780. 10.1038/s41467-025-67456-3
8. Svoboda SA, Shields BE: Cutaneous manifestations of nutritional excess: pathophysiologic effects of hyperglycemia and hyperinsulinemia on the skin. Cutis. 2021, 107:74-8. 10.12788/cutis.0173
9. Varela Hernández CI: Huellas. Lesiones elementales de la piel . Programa Editorial Universidad del Valle, Cali, Colombia; 2022. 10.25100/peu.7523708
10. Angelidi AM, Filippaios A, Mantzoros CS: Severe insulin resistance syndromes. J Clin Invest. 2021, 131:e142245. 10.1172/JCI142245
11. 14. Children and adolescents: standards of care in diabetes-2026 . Diabetes Care. 2026, 49:S297-320.

10.2337/dc26-S014
12. Elhassan YS, Hawley JM, Cussen L, et al.: Society for Endocrinology clinical practice guideline for the evaluation of androgen excess in women. Clin Endocrinol (Oxf). 2025, 103:540-66. 10.1111/cen.15265
13. Bonnefond A, Semple RK: Achievements, prospects and challenges in precision care for monogenic insulin-deficient and insulin-resistant diabetes. Diabetologia. 2022, 65:1782-95. 10.1007/s00125-022-05720-7
14. Mosbah H, Donadille B, Vatier C, et al.: Dunnigan lipodystrophy syndrome: French National Diagnosis and Care Protocol (PNDS; Protocole National de Diagnostic et de Soins). Orphanet J Rare Dis. 2022, 17:170. 10.1186/s13023-022-02308-7
15. Berberich AJ, Hegele RA: A modern approach to dyslipidemia. Endocr Rev. 2022, 43:611-53. 10.1210/endrev/bnab037
16. Blumenthal RS, Morris PB, Gaudino M, et al.: 2026 ACC/AHA/AACVPR/ABC/ACPM/ADA/AGS/APhA/ASPC/NLA/PCNA guideline on the management of dyslipidemia: a report of the American College of Cardiology/American Heart Association Joint Committee on clinical practice guidelines. J Am Coll Cardiol. 2026, 87:2624-757. 10.1016/j.jacc.2025.11.016
17. Hegele RA: Approach to the adult patient with chylomicronemia. J Clin Endocrinol Metab. 2026, 111:845-59. 10.1210/clinem/dgaf701
18. Ginsberg HN, Bornfeldt KE: Triglyceride-rich lipoprotein metabolism and cardiovascular risk in diabetes: bedside to bench to bedside. Circ Res. 2026, 138:e327267. 10.1161/CIRCRESAHA.125.327267
19. Virani SS, Morris PB, Agarwala A, et al.: 2021 ACC Expert Consensus Decision Pathway on the management of ASCVD risk reduction in patients with persistent hypertriglyceridemia: a report of the American College of Cardiology Solution Set Oversight Committee. J Am Coll Cardiol. 2021, 78:960-93. 10.1016/j.jacc.2021.06.011
20. Elouarradi N, Ansari NE: Necrobiosis lipoidica: a rare complication of diabetes . Pan Afr Med J. 2018, 29:214. 10.11604/pamj.2018.29.214.15550
21. Liu MJ, Li J: Necrobiosis lipoidica. N Engl J Med. 2024, 390:70. 10.1056/NEJMicm2304653
22. Hashemi DA, Brown-Joel ZO, Tkachenko E, et al.: Clinical features and comorbidities of patients with necrobiosis lipoidica with or without diabetes. JAMA Dermatol. 2019, 155:455-9. 10.1001/jamadermatol.2018.5635
23. Trihan JE, Lanéelle D, Metcalfe N, Perez Martin A, Frances P: Diabetes-associated dermatological manifestations in primary care and their association with vascular complications. J Diabetes Metab Disord. 2020, 19:989-96. 10.1007/s40200-020-00594-1
24. Erfurt-Berge C, Renner R, Peckruhn M, Tittelbach J, Terhorst-Molawi D, Kauer F, Dissemond J: S1-guideline for diagnosis and therapy of necrobiosis lipoidica. J Dtsch Dermatol Ges. 2026, 24:429-36. 10.1111/ddg.15943
25. Naumowicz M, Modzelewski S, Macko A, Łuniewski B, Baran A, Flisiak I: A breakthrough in the treatment of necrobiosis lipoidica? Update on treatment, etiopathogenesis, diagnosis, and clinical presentation. Int J Mol Sci. 2024, 25:3482. 10.3390/ijms25063482
26. Daccache J, Park E, Junejo M, et al.: Spatial transcriptomics reveals organized and distinct immune activation in cutaneous granulomatous disorders. J Allergy Clin Immunol. 2024, 154:1216-31. 10.1016/j.jaci.2024.07.021
27. Joshi TP, Duvic M: Granuloma annulare: an updated review of epidemiology, pathogenesis, and treatment options. Am J Clin Dermatol. 2022, 23:37-50. 10.1007/s40257-021-00636-1
28. Barbieri JS, Rosenbach M, Rodriguez O, Margolis DJ: Association of granuloma annulare with type 2 diabetes, hyperlipidemia, autoimmune disorders, and hematologic malignant neoplasms. JAMA Dermatol. 2021, 157:817-23. 10.1001/jamadermatol.2021.1805
29. Joshi TP, Tran T, Kelly BC: Association of granuloma annulare with dyslipidemia, hypertension, and type 2 diabetes mellitus: a systematic review and meta-analysis. Int J Dermatol. 2024, 63:376-8. 10.1111/ijd.16999
30. Leasure AC, Damsky W, Cohen JM: Comorbidities associated with granuloma annulare: a case-control study in the All of Us research program. J Am Acad Dermatol. 2022, 87:197-9. 10.1016/j.jaad.2021.07.033
31. Foroohar T, Berk-Krauss J, Caplan AS, et al.: Granuloma annulare: an updated review of epidemiology, molecular pathogenesis, and management. J Am Acad Dermatol. 2026, 95:1757-73. 10.1016/j.jaad.2026.06.070
32. Gorelik S, Leos A, Kuah A, Desai S, Namous A, Onica A, Vlahovic TC: Cutaneous manifestations of the diabetic foot. Clin Podiatr Med Surg. 2021, 38:569-76. 10.1016/j.cpm.2021.06.010
33. Armstrong DG, Tan TW, Boulton AJ, Bus SA: Diabetic foot ulcers: a review . JAMA. 2023, 330:62-75. 10.1001/jama.2023.10578
34. van Netten JJ, Raspovic A, Lavery LA, et al.: Prevention of foot ulcers in persons with diabetes at risk of ulceration: a systematic review and meta-analysis. Diabetes Metab Res Rev. 2024, 40:e3652. 10.1002/dmrr.3652
35. Gornik HL, Aronow HD, Goodney PP, et al.: 2024 ACC/AHA/AACVPR/APMA/ABC/SCAI/SVM/SVN/SVS/SIR/VESS guideline for the management of lower extremity peripheral artery disease: a report of the American College of Cardiology/American Heart Association Joint Committee on clinical practice guidelines. Circulation. 2024, 149:e1313-410. 10.1161/CIR.0000000000001251
36. Marinescu M, Botnariu GE, Vâță D, et al.: Diabetic dermopathies as predictive markers of cardiovascular and renal complications: a narrative review. J Clin Med. 2025, 14:7719. 10.3390/jcm14217719
37. Mauricio D, Gratacòs M, Franch-Nadal J: Diabetic microvascular disease in non-classical beds: the hidden impact beyond the retina, the kidney, and the peripheral nerves. Cardiovasc Diabetol. 2023, 22:314. 10.1186/s12933-023-02056-3
38. Naik PP, Farrukh SN: Clinical significance of diabetic dermatopathy. Diabetes Metab Syndr Obes. 2020, 13:4823-7. 10.2147/DMSO.S286887
39. Wagner G, Meyer V, Sachse MM: Bullosis diabeticorum: two case studies [Article in German] . Hautarzt. 2018, 69:751-5. 10.1007/s00105-018-4132-7
40. Chiriac A, Costache I, Podoleanu C, Naznean A, Stolnicu S: Bullosis diabeticorum in a young child: case

report of a very rare entity and a literature review. Can J Diabetes. 2017, 41:129-31. 10.1016/j.jcjd.2016.10.005
41. Swoboda L: Blistering disorders of the foot . Adv Skin Wound Care. 2024, 37:429-33. 10.1097/ASW.0000000000000190
42. Hu QJ, Chen JJ, Yao X: Literature-based clinical retrospective analysis of acquired reactive perforating collagenosis. Int J Dermatol Venereol. 2025, 8:158-65. 10.1097/JD9.0000000000000336
43. Edek YC, Aypek Y, Öğüt B, Erdem Ö, Adışen E: Acquired perforating dermatosis: clinical and histopathological analysis of 95 patients from one center. Dermatol Pract Concept. 2024, 14:e2024100. 10.5826/dpc.1402a100
44. Garrido PM, Queirós C, Borges-Costa J, Soares-Almeida L, Filipe P: Acquired perforating dermatosis: clinicopathologic study of a 10-year period at a tertiary teaching hospital. Int J Dermatol. 2020, 59:445-50. 10.1111/ijd.14760
45. Lukács J, Schliemann S, Elsner P: Treatment of acquired reactive perforating dermatosis - a systematic review. J Dtsch Dermatol Ges. 2018, 16:825-42. 10.1111/ddg.13561
46. Csonka V, Bódis B, Kovács D, Farkas N, Kálmán E, Czirják L, Varjú C: Screening for the presence of scleroedema adultorum of Buschke in patients with diabetes mellitus: newly diagnosed patients had a high prevalence of dyslipidaemia. Lipids Health Dis. 2021, 20:47. 10.1186/s12944-021-01473-1
47. Tawanwongsri W, Eden C: Management and clinical outcomes of scleredema diabeticorum: a scoping review. Diseases. 2025, 13:346. 10.3390/diseases13100346
48. Carey IM, Critchley JA, DeWilde S, Harris T, Hosking FJ, Cook DG: Risk of infection in type 1 and type 2 diabetes compared with the general population: a matched cohort study. Diabetes Care. 2018, 41:513-21. 10.2337/dc17-2131
49. Abate MC, Aroucha PM, Nóbrega DV, et al.: Cutaneous manifestations of diabetes mellitus: a narrative review. Einstein (Sao Paulo). 2025, 23:eRW1193. 10.31744/einstein_journal/2025RW1193
50. Lira JA, Nogueira LT, Oliveira BM, Soares DD, Santos AM, Araújo TM: Factors associated with the risk of diabetic foot in patients with diabetes mellitus in primary care. Rev Esc Enferm USP. 2021, 55:e03757. 10.1590/S1980-220X2020019503757
51. Shamsudeen MA, Gopinath SC, Zulkiple MZ: A cross-sectional clinical analysis on diabetic foot ulcer and associated risk management. Indian J Pharmacol. 2026, 58:131-6. 10.4103/ijp.ijp_644_24
52. Fitridge R, Chuter V, Mills J, et al.: The intersocietal IWGDF, ESVS, SVS guidelines on peripheral artery disease in people with diabetes and a foot ulcer. Diabetes Metab Res Rev. 2024, 40:e3686. 10.1002/dmrr.3686
53. Wukich DK, Schaper NC, Gooday C, et al.: Guidelines on the diagnosis and treatment of active Charcot neuro-osteoarthropathy in persons with diabetes mellitus (IWGDF 2023). Diabetes Metab Res Rev. 2024, 40:e3646. 10.1002/dmrr.3646
54. Senneville É, Albalawi Z, van Asten SA, et al.: IWGDF/IDSA guidelines on the diagnosis and treatment of diabetes-related foot infections (IWGDF/IDSA 2023). Diabetes Metab Res Rev. 2024, 40:e3687. 10.1002/dmrr.3687
55. Lazzarini PA, Armstrong DG, Crews RT, et al.: Effectiveness of offloading interventions for people with diabetes-related foot ulcers: a systematic review and meta-analysis. Diabetes Metab Res Rev. 2024, 40:e3650. 10.1002/dmrr.3650
56. Bus SA, Armstrong DG, Crews RT, et al.: Guidelines on offloading foot ulcers in persons with diabetes (IWGDF 2023 update). Diabetes Metab Res Rev. 2024, 40:e3647. 10.1002/dmrr.3647
57. Wang K, Zhang S, Liu C, Chen Y: A meta-analysis and meta-regression on the prevalence of lipohypertrophy in diabetic patients on insulin therapy. Therapie. 2021, 76:617-28. 10.1016/j.therap.2021.04.002
58. Mader JK, Fornengo R, Hassoun A, et al.: Risk factors for lipohypertrophy in people with insulin-treated diabetes: a systematic meta-analysis. J Diabetes Sci Technol. 2026, 20:1342-52. 10.1177/19322968251325569
59. Mader JK, Fornengo R, Hassoun A, et al.: Relationship between lipohypertrophy, glycemic control, and insulin dosing: a systematic meta-analysis. Diabetes Technol Ther. 2024, 26:351-62. 10.1089/dia.2023.0491
60. 7. Diabetes technology: standards of care in diabetes-2026 . Diabetes Care. 2026, 49:S150-65. 10.2337/dc26-S007
61. Asarani NA, Reynolds AN, Boucher SE, de Bock M, Wheeler BJ: Cutaneous complications with continuous or flash glucose monitoring use: systematic review of trials and observational studies. J Diabetes Sci Technol. 2020, 14:328-37. 10.1177/1932296819870849
62. von Kobyletzki LB, Ulriksdotter J, Sukakul T, et al.: Prevalence of dermatitis including allergic contact dermatitis from medical devices used by children and adults with type 1 diabetes mellitus: a systematic review and questionnaire study. J Eur Acad Dermatol Venereol. 2024, 38:1329-46. 10.1111/jdv.19908
63. Cichoń M, Trzeciak M, Sokołowska-Wojdyło M, Nowicki RJ: Contact dermatitis to diabetes medical devices . Int J Mol Sci. 2023, 24:10697. 10.3390/ijms241310697
64. Liu SD, Chen WT, Chi CC: Association between medication use and bullous pemphigoid: a systematic review and meta-analysis. JAMA Dermatol. 2020, 156:891-900. 10.1001/jamadermatol.2020.1587
65. Silverii GA, Dicembrini I, Nreu B, Montereggi C, Mannucci E, Monami M: Bullous pemphigoid and dipeptidyl peptidase-4 inhibitors: a meta-analysis of randomized controlled trials. Endocrine. 2020, 69:504-7. 10.1007/s12020-020-02272-x