Cureus
Part of SPRINGER NATURE

Open Access Review Article

Published via Dr. Kiran C. Patel College of Allopathic Medicine (NSUMD)

Pediatric Ring Avulsion Injuries: A Systematic Review of Surgical and Functional Outcomes and Gaps in Cosmetic and Psychosocial Reporting

Diana Ghisa [1], Ivan Kliuikov [1], Ann Mathew [1], Claudia Ghisa [2], Gary Schwartz [1]

1. Medical Education, Nova Southeastern University Dr. Kiran C. Patel College of Allopathic Medicine, Fort Lauderdale, USA 2. Orthopedics, Orthopedic Surgeon LA, Burbank, USA

Corresponding author: Diana Ghisa, dg2097@mynsu.nova.edu

Received 08/26/2026
Review began 09/10/2026
Review ended 10/18/2026
Published 10/25/2026

© Copyright 2026
Ghisa et al. This is an open access article distributed under the terms of the Creative Commons Attribution License CC-BY 4.0., which permits unrestricted use, distribution, and reproduction in any medium, provided the original author and source are credited.

DOI: 10.7759/cureus.118572

Abstract

Pediatric ring avulsion injuries are rare but potentially devastating injuries that may result in degloving, vascular compromise, or complete digital amputation. Existing literature primarily focuses on surgical management and functional outcomes, while the cosmetic and psychosocial impact of these injuries remains poorly characterized.

A systematic literature review was conducted using PubMed, Embase, and Google Scholar to identify published reports of pediatric ring avulsion injuries through October 2026. Search terms incorporated “ring avulsion,” “digital avulsion,” “finger avulsion,” “digital degloving,” and related terms combined with pediatric age-related terms. Studies were included if patients were younger than 19 years and sufficient information was available to confirm the injury mechanism and extract relevant clinical data. Studies were not excluded solely because injury classification or individual outcomes were incompletely reported. Nineteen publications met the final inclusion criteria. Data collected included demographics, mechanism and extent of injury, injury classification, management, functional outcomes, and reporting of cosmetic and psychosocial outcomes.

The 19 included studies described at least 40 pediatric patients with ring avulsion injuries. Injury severity ranged from preserved circulation to complete degloving or amputation and was characterized using the Urbaniak, modified Kay, and other classification systems when reported. Microsurgical revascularization or replantation was frequently attempted for severe injuries, although some patients required primary amputation or subsequent revision following unsuccessful salvage. Lower-grade injuries generally required less extensive reconstruction. Functional recovery varied with injury severity and the extent of vascular, tendon, nerve, and skeletal damage. Although successful replantation was reported in several severe cases, digit survival did not consistently translate to restoration of normal function. Reported outcomes included digit survival, range of motion, grip strength, sensory recovery, cold intolerance, and cosmetic appearance. Patient-centered outcomes were inconsistently assessed, with limited reporting of cosmetic satisfaction and psychological recovery and little to no formal assessment of body image or health-related quality of life.

Pediatric ring avulsion literature remains limited to case reports and small case series, with substantial variability in injury severity, management, and outcome reporting. Although microsurgical techniques have enabled successful digit salvage in selected patients, functional recovery remains variable. Despite the potential psychological impact of visible hand deformity during childhood and adolescence, cosmetic and psychosocial outcomes remain underreported. Future studies should incorporate standardized functional measures, patient-reported outcomes, and psychosocial assessments to better characterize the long-term effects of these injuries.

Categories: Trauma, Pediatrics, Orthopedics
Keywords: cosmetic outcome pediatric hand trauma, digital avulsion, digital microsurgery, digital replantation, hand digit amputation, pediatric digital avulsion, pediatric orthopaedic trauma, pediatric ring avulsion, pediatric trauma, psychosocial outcomes pediatric trauma

Introduction And Background

Ring avulsion injuries occur when traction applied to a ring produces circumferential injury to the digit. Depending on the magnitude and direction of force, injury can range from soft-tissue laceration with preserved circulation to extensive degloving, neurovascular and tendon disruption, fracture, and complete digital amputation [1,2]. Although uncommon, these injuries can be functionally and aesthetically devastating and may require complex microsurgical reconstruction [3].

The incidence of ring avulsion injuries in the pediatric population is not well established. Population-level data specific to pediatric ring avulsion are limited, and the available literature consists predominantly of case reports and small case series [1,2,4]. More broadly, avulsion injuries have been estimated to account for

approximately 2.9% of finger injuries presenting to emergency departments in the United States, although this estimate is not specific to pediatric ring avulsion injuries [3].

Several classification systems have been developed to characterize ring avulsion injury severity and guide management. The Urbaniak classification consists of three classes based primarily on circulatory status: Class I injuries have adequate circulation, Class II injuries have inadequate circulation requiring vascular repair, and Class III injuries consist of complete degloving or amputation. The Kay classification further distinguishes injuries with inadequate circulation according to the presence or absence of skeletal injury and designates complete degloving or amputation as Class IV. Subsequent modifications further subdivided Class IV injuries according to the level of injury relative to the flexor digitorum superficialis insertion [3,5-7]. Additional classification systems encountered in the pediatric literature include the Carroll classification, which incorporates the degree of skin, neurovascular, tendon, bone, and joint injury, and the Tamai classification, which describes the anatomical level of amputation [8,9]. The Sturzenegger modification further distinguishes severe injuries according to proximal versus distal neurovascular injury [4,10-12]. Carroll Classes I-IV are summarized in Crosby et al., while Lefèvre et al. explicitly used Tamai zones III-V in their pediatric cohort [4,11]. Hyza et al. describe Sturzenegger Type IIIp and IIId injuries according to proximal versus distal neurovascular injury [12].

This distinction is clinically relevant because pediatric digit replantation has demonstrated more favorable short-term outcomes than adult replantation, while severe pediatric hand injuries may also have important psychosocial and aesthetic consequences [13-15]. Consequently, focused evaluation of pediatric ring avulsion injuries is warranted to characterize management strategies, functional outcomes, and the less frequently reported cosmetic and psychosocial consequences of these injuries.

Previous publications have reviewed ring avulsion injuries predominantly in adult populations [1]. The present study specifically reviews ring avulsion injuries in the pediatric population. The aim of this review is to characterize pediatric ring avulsion injuries with respect to injury mechanism and severity, treatment strategies, digit survival, functional and sensory outcomes, cosmetic outcomes, and psychosocial outcomes.

Review

Methods

Search Strategy and Study Identification

A systematic review was conducted to identify published reports of pediatric ring avulsion injuries. PubMed, Embase, and Google Scholar were searched on October 5, 2026, without a lower publication-year restriction. The search strategy combined terms related to ring avulsion, digital avulsion, amputation, and degloving injuries with pediatric age-related terms. The review was reported with reference to the Preferred Reporting Items for Systematic Reviews and Meta-Analyses (PRISMA) 2020 guidelines [16].

The PubMed search was: ("ring avulsion"[Title/Abstract] OR "ring avulsion injury"[Title/Abstract] OR "ring avulsion injuries"[Title/Abstract] OR "ring avulsion amputation"[Title/Abstract] OR "digital avulsion"[Title/Abstract] OR "digit avulsion"[Title/Abstract] OR "finger avulsion"[Title/Abstract] OR "avulsion amputation"[Title/Abstract] OR "digital degloving"[Title/Abstract] OR "finger degloving"[Title/Abstract] OR "degloving injury"[Title/Abstract]) AND ("Child"[Mesh] OR "Adolescent"[Mesh] OR pediatric[Title/Abstract] OR paediatric[Title/Abstract] OR child*[Title/Abstract] OR adolescen*[Title/Abstract] OR teen*[Title/Abstract] OR youth[Title/Abstract] OR "young patient"[Title/Abstract] OR "young patients"[Title/Abstract]).

The Embase search was: ('ring avulsion':ti,ab OR 'ring avulsion injury':ti,ab OR 'ring avulsion injuries':ti,ab OR 'ring avulsion amputation':ti,ab OR 'digital avulsion':ti,ab OR 'digit avulsion':ti,ab OR 'finger avulsion':ti,ab OR 'avulsion amputation':ti,ab OR 'digital degloving':ti,ab OR 'finger degloving':ti,ab OR 'degloving injury':ti,ab) AND ('child'/exp OR 'adolescent'/exp OR pediatric:ti,ab OR paediatric:ti,ab OR child*:ti,ab OR adolescen*:ti,ab OR teen*:ti,ab OR youth:ti,ab OR 'young patient':ti,ab OR 'young patients':ti,ab).

Google Scholar was searched using the terms "ring avulsion" (child OR adolescent OR pediatric). Approximately 425 results were displayed, of which 240 records were retrieved for screening using Harzing's Publish or Perish software.

Because pediatric age is not consistently reported in article titles or abstracts, a supplementary age-unrestricted PubMed search was also performed for publications from January 1, 2022, through October 6, 2026: ("ring avulsion"[Title/Abstract] OR "ring avulsion injury"[Title/Abstract] OR "ring avulsion injuries"[Title/Abstract] OR "ring avulsion amputation"[Title/Abstract]) AND ("2022/01/01"[Date - Publication] : "2026/10/06"[Date - Publication])

Records were imported into Zotero and duplicates were removed before final eligibility assessment.

Eligibility Criteria

Studies were eligible if they reported original clinical data involving at least one patient younger than 19 years with a hand digital ring avulsion injury. Eligible reports were required to provide sufficient clinical information to establish pediatric age eligibility and the nature of the injury. Specific treatment, functional outcome, cosmetic outcome, psychosocial outcome, and follow-up data were extracted when available but were not required to be reported for every case.

Reports were retained when the original authors identified the injury as a ring avulsion even if the precise mechanism of entrapment or traction was not described. In these instances, the mechanism was recorded as not reported. Similarly, formal injury classification was not required for inclusion. Urbaniak, Kay/modified Kay, Carroll, Tamai, Sturzenegger, and other classifications were recorded only when explicitly reported by the original authors; classifications were not retrospectively assigned by the reviewers.

Studies containing mixed pediatric and adult populations were eligible when at least one patient younger than 19 years could be identified. Patient-level pediatric information was extracted whenever available. When outcomes were reported only for the overall mixed-age cohort, these data were identified as aggregate study-level findings and were not attributed specifically to pediatric patients. Missing patient-level variables were recorded as not reported.

Studies were excluded if they contained no identifiable patient younger than 19 years, described injuries unrelated to ring avulsion, or lacked sufficient clinical information to establish eligibility. Reviews, systematic reviews, narrative reviews, biomechanical or cadaveric studies, textbooks, and other publications without original eligible clinical cases were excluded. Only reports containing sufficient English-language information for eligibility assessment and data extraction were included, regardless of the database through which they were identified. Non-English reports without sufficient English-language information were excluded at full-text assessment.

Study Selection and Data Extraction

After deduplication, titles and abstracts were screened for potential eligibility. Records for which pediatric involvement, injury mechanism, or clinical relevance could not be confidently excluded were retained for full-text review. Full-text eligibility decisions and extracted data were subsequently checked by a second reviewer, with discrepancies resolved through discussion.

For each included study, data were extracted at the individual-patient level whenever possible. Extracted variables included study author and publication year; patient age and sex; injury mechanism; affected digit; injury classification; extent of soft tissue, vascular, nerve, tendon, joint, and osseous injury; operative and nonoperative management; replantation or revascularization success; secondary procedures; follow-up duration; range of motion; total active motion; sensory recovery; grip strength; cold intolerance; digit survival; amputation or ray resection; and other reported anatomic or functional outcomes.

Cosmetic and psychosocial findings were also extracted when reported, including aesthetic appearance, satisfaction with appearance or treatment, emotional distress, psychological therapy, body-image concerns, social consequences, and other patient-reported observations. General author commentary regarding potential cosmetic or psychosocial effects was distinguished from outcomes actually documented in the reported patient.

For studies containing multiple pediatric cases, each identifiable patient was extracted separately when sufficient information was available. When only aggregate pediatric data were reported, those findings were marked in the table as not individually reported.

The study identification, screening, eligibility assessment, and inclusion process is summarized in the PRISMA flow diagram shown in Figure *1* [16].

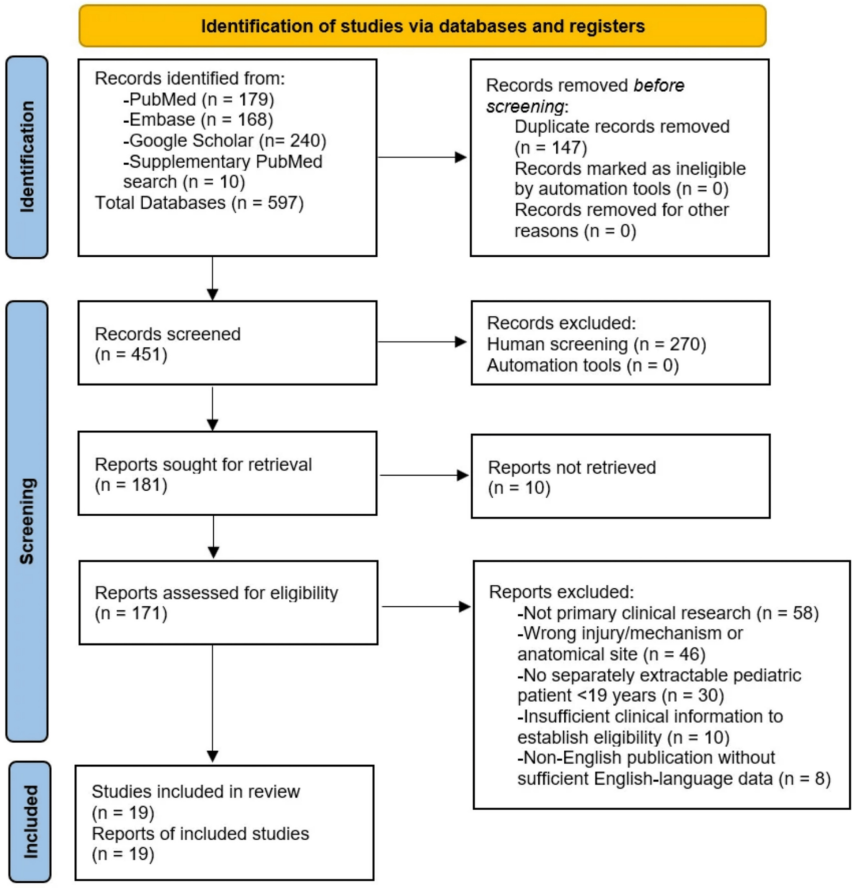

FIGURE 1: PRISMA Flow Diagram of Study Identification and Selection for Pediatric Ring Avulsion Injuries

Preferred Reporting Items for Systematic Reviews and Meta-Analyses (PRISMA) flow diagram summarizing study identification, screening, eligibility assessment, and final inclusion of 19 studies. Adapted from the PRISMA 2020 flow diagram template. The PRISMA 2020 flow diagram is distributed under the Creative Commons Attribution 4.0 International (CC BY 4.0) license [16].

Potential overlap between publications was assessed by comparing authorship, treating institution, study period, patient age, injury characteristics, and treatment details. When the same patient was determined to have been reported in more than one publication, the publications were retained as relevant reports when appropriate, but the patient was not intended to be counted more than once in patient-level summaries.

Methodological Quality Assessment

Methodological quality of the included studies was assessed using the JBI critical appraisal tools appropriate to each study design. Case reports were evaluated using the eight-item JBI Critical Appraisal Checklist for Case Reports, and case series were evaluated using the 10-item JBI Critical Appraisal Checklist for Case Series [17,18]. Each criterion was rated as "Yes" (Y), "No" (N), "Unclear" (U), or "Not applicable" (NA), as appropriate. Results were summarized by individual appraisal domain rather than combined into an overall quality score.

The methodological appraisal of the eight included case reports is summarized in Table *1*, and the appraisal of the 11 included case series is summarized in Table *2*.

Authors (year)	Q1	Q2	Q3	Q4	Q5	Q6	Q7	Q8
Pynn et al. (1997) [19]	Y	Y	Y	Y	Y	Y	Y	Y
Levy (1999) [20]	Y	Y	Y	Y	Y	Y	Y	Y
Hankin et al. (2000) [21]	Y	Y	Y	U	N	N	U	Y
Huemer & Dunst (2005) [22]	Y	Y	Y	U	Y	Y	Y	N
Hamzan et al. (2020) [2]	Y	Y	Y	Y	Y	Y	Y	Y
Zhu & Currie (2021) [23]	Y	Y	Y	Y	Y	Y	Y	Y
Oukhouya & Cherrabi (2022) [24]	Y	Y	Y	U	Y	Y	Y	N
Yassin et al. (2022) [25]	Y	Y	Y	Y	Y	Y	Y	Y

TABLE 1: Case reports; JBI eight-item checklist

Critical appraisal of included case reports using the JBI eight-item Critical Appraisal Checklist for Case Reports [17]. Q1, patient demographics clearly described; Q2, patient history and timeline clearly described; Q3, current clinical condition clearly described; Q4, diagnostic tests or assessment methods and results clearly described; Q5, intervention or treatment clearly described; Q6, post-intervention clinical condition clearly described; Q7, adverse or unanticipated events identified and described; Q8, takeaway lessons provided. Y, Yes; N, No; U, Unclear; NA, Not applicable.

Authors (year)	Q1	Q2	Q3	Q4	Q5	Q6	Q7	Q8	Q9	Q10
Bevin & Chase (1963) [26]	N	N	Y	U	U	N	Y	N	Y	NA
Flagg et al. (1977) [27]	N	N	Y	U	U	Y	Y	Y	Y	NA
Tsai et al. (1984) [28]	Y	Y	Y	N	N	Y	Y	Y	Y	Y
Beris et al. (1994) [29]	Y	Y	Y	U	Y	Y	Y	Y	Y	Y
Scerri & Ratcliffe (1994) [30]	N	Y	Y	U	U	Y	Y	N	Y	NA
Hyza et al. (2007) [12]	Y	Y	Y	U	Y	Y	Y	Y	Y	Y
Lefèvre et al. (2011) [4]	Y	Y	Y	U	Y	Y	Y	Y	Y	Y
Özaksar et al. (2012) [31]	Y	Y	Y	U	U	Y	Y	Y	Y	Y
Adani et al. (2013) [7]	Y	Y	Y	U	Y	Y	Y	Y	Y	Y
Crosby et al. (2014) [11]	Y	Y	Y	U	Y	Y	Y	Y	Y	Y
Manoukov et al. (2022) [32]	Y	Y	Y	U	Y	Y	Y	U	Y	Y

TABLE 2: Case series; JBI 10-item checklist

Critical appraisal of included case series using the JBI 10-item Critical Appraisal Checklist for Case Series [8]. Q1, clear inclusion criteria; Q2, condition measured in a standard and reliable manner; Q3, valid methods used for identification of the condition; Q4, consecutive inclusion of participants; Q5, complete inclusion of participants; Q6, participant demographics clearly reported; Q7, clinical information clearly reported; Q8, outcomes or follow-up results clearly reported; Q9, presenting site(s) or clinic demographic information clearly reported; Q10, appropriate statistical analysis. Y, Yes; N, No; U, Unclear; NA, Not applicable.

Data Synthesis

Because the available literature consisted primarily of case reports and small case series with substantial heterogeneity in injury severity, classification systems, treatment approaches, outcome definitions, and duration of follow-up, quantitative meta-analysis was not performed. Findings were synthesized descriptively. Temporal differences in microsurgical techniques and reporting practices across the included literature were considered when interpreting the findings.

No review protocol was prospectively registered.

Results

Injury Characteristics and Classification

Injuries ranged from soft-tissue injuries with preserved circulation to vascular compromise, complete circumferential degloving, tendon and nerve avulsion, skeletal injury, and complete digital amputation. Reported mechanisms included rings caught on objects during sports, falls, playground activities, and machinery use. When an exact mechanism was not reported but the authors identified the injury as a ring avulsion, the mechanism was recorded as not reported.

Multiple classification systems were represented. Urbaniak Classes I-III were reported across several studies, while other reports used the Kay or modified Kay classification. Both pediatric patients reported by Tsai et al. were classified as Urbaniak Class III and Carroll Class IV [28]. Lefèvre et al. additionally used the Tamai anatomical classification; among the 15 eligible ring-related pediatric cases, four were Tamai zone III, nine zone IV, and two zone V [4]. Hyza et al. classified the included 17-year-old as Urbaniak Class III with proximal arterial injury according to the Sturzenegger modification [12]. When authors did not provide a formal classification, classification was recorded as not reported rather than retrospectively assigned.

Surgical Management and Digit Survival

Management varied according to injury severity and the structures involved. Lower-grade injuries were generally managed with irrigation, debridement, soft-tissue repair, and repair of associated nerve injury when indicated [19]. Pynn et al. described a 16-year-old basketball player with an Urbaniak Class I injury: near-complete degloving, radial digital nerve avulsion, and preserved circulation [19]. Following microscopic nerve repair, wound closure, and postoperative hand therapy, the patient achieved near-normal range of motion and ultimately recovered normal sensation [19].

Severe injuries involving vascular compromise or complete amputation were frequently managed with microsurgical revascularization or replantation [2,4,7,12,23,28,29,31]. Several patients required additional procedures for vascular complications, soft-tissue defects, tendon dysfunction, or joint stiffness. When conventional replantation was not feasible, reconstructive strategies included regional, groin, abdominal, or free-flap reconstruction [24,25,32].

Lefèvre et al. reported the largest exclusively pediatric series, consisting of 23 children with digital avulsion injuries [4]. Fifteen patients had ring-related mechanisms meeting the inclusion criteria of this review; three sustained Urbaniak Class II injuries and 12 sustained Class III injuries. Revascularization or replantation was attempted in 11 of these patients, while four Class III injuries underwent primary stump revision without attempted replantation. In the full 23-patient cohort, the authors reported that replantation was abandoned in seven cases because severe distal vascular injury prevented identification of an arterial stump suitable for anastomosis; a separate operative rationale was not provided for each of the four eligible ring-avulsion cases. Three of the 15 eligible patients achieved complete survival, including two Class II injuries and one Class III injury; one additional Class II injury had partial survival [4].

Functional and Sensory Outcomes

Functional and sensory recovery appeared related to injury severity and associated tendon, joint, skeletal, and neurovascular damage. Lower-grade injuries generally demonstrated favorable outcomes. The 16-year-old basketball player reported by Pynn et al. regained near-normal range of motion by two months and normal sensation by two years [19].

Several complete amputations were successfully replanted with useful subsequent function [7,12,22,28,31]. Hyza et al. reported a 17-year-old with a severe Urbaniak Class III injury involving the neurovascular structures, extensor apparatus, and flexor tendon [12]. At 28 months, total active motion was 190° (73% of normal), grip strength was 34 kg compared with 41 kg in the contralateral hand, and moving and static two-point discrimination (2-PD) were 9 mm and 11 mm, respectively, with no reported cold intolerance [12].

However, digit survival did not uniformly correspond to complete functional recovery. Zhu and Currie reported successful replantation in a 14-year-old with a complete amputation and extensive tendon and neurovascular injury; sensation and full passive proximal interphalangeal (PIP) joint motion were preserved, but active flexion remained limited and further surgery was planned [23]. Hamzan et al. similarly reported residual interphalangeal stiffness despite survival of a severely avulsed and reconstructed thumb [2].

Cosmetic and Psychosocial Outcomes

Cosmetic outcomes were reported less consistently than digit survival and functional outcomes. Favorable appearance or satisfaction was described in several reports [2,12,19,20,23,24]. Manoukov et al. reported aesthetic outcomes following ultra-thinned groin-flap reconstruction, but these results were reported for the mixed-age cohort and could not be attributed specifically to the identifiable pediatric patient [32]. Hyza

et al. reported satisfaction scores for all six included patients, with 1 representing the highest level of satisfaction and 5 representing the lowest [12]. The 17-year-old pediatric patient extracted from the Hyza et al. cohort had a satisfaction score of 1/5, indicating the highest level of satisfaction with the functional and aesthetic result [12]. Hankin et al. discussed the potential for permanent disfigurement and associated social consequences but did not report a measured cosmetic outcome in their patient [21]. No included study used a validated pediatric cosmetic or body-image instrument.

Psychosocial outcomes were even less frequently reported. Zhu and Currie described ongoing psychological therapy following the injury and emotional relief associated with preservation of the digit and its appearance [23]. Hankin et al. discussed the increasing popularity of rings as an “attractive and stylish” trend encouraged by social influences. Although no specific patient-level psychosocial outcomes were reported, the authors noted the potential for psychological impairment, family guilt, permanent disfigurement, and unwanted peer attention following digital amputation, and cautioned against children wearing rings during active play [21]. However, no included study used a validated measure of psychological distress, body image, emotional recovery, or health-related quality of life. Study-level data for mechanism, classification, and extent of injury, as well as the repair and management, anatomic and functional outcomes, and any cosmetic or psychosocial commentary from the literature can be reviewed at either the study-level in Table *3* or at a patient-level in Table *4*.

Authors (year)	Pediatric cases / age / sex	Mechanism of injury	Classification	Extent of injury	Repair / management	Anatomic / functional outcome	Cosmetic / psychosocial comments
Bevin & Chase (1963) [26]	1 / young child (exact age NR) / M	Accidental traction on a ring while playing	NR (pre-Urbaniak report)	Left ring finger: complete soft-tissue avulsion; no viable functional tissue; no sensation or dynamic function present.	Primary digit amputation; later fifth digit/metacarpal transfer to close fourth-ray gap	Digit not salvaged; later hand reconstruction restored symmetry; quantitative function NR.	Authors describe improved symmetry s/p metacarpal transfer, with a more acceptable hand functionally and cosmetically, in general; no other reported outcomes.
Flagg et al. (1977) [27]	1 / 17 y / M	Ring caught on school door hinge when patient tripped	NR (authors did not assign class)	Dominant left little finger: circumferential avulsion from web to middle third of middle phalanx; cold, white, insensate; both arteries, all veins, radial nerve severed, extensor disruption distal to central tendon; partly disarticulated DIP	DIP arthrodesis using distal phalanx as bone graft; deltopectoral flap cover (allowing PIP −10° to 40°); delayed (10 mo) neurovascular island flap from adjacent ring finger due to poor sensibility, arthrodesis demineralization and displacement	Salvaged digit; at 10 mo acceptable contour and movement; at 6 and 27 mo s/p island flap static 2-PD 3 mm with cortical sensibility retrained; at 2 yr s/p injury, natural contour, dynamic function, stable pinch, sensibility in pinch and ulnar border, cold sensitivity	Acceptable contour specifically described; patient happy to have little finger and uses for all but heavy lifting
Tsai et al. (1984) [28]	2 / 6–14 y / 1 F, 1 sex NR	Ring avulsion; exact mechanisms NR	Urbaniak III; Carroll IV (2)	Both had complete amputations with skin avulsed from the proximal phalanx, DIP disarticulation, and arterial/venous/nerve disruption. One had middle-phalanx condyle avulsion; the other had extensor and FDP disruption.	Both underwent microsurgical replantation with DIP fixation/fusion, vascular reconstruction using multiple vein grafts, nerve repair, and STSG. The 14-year-old patient additionally underwent extensor repair and FDP fixation to the middle-phalanx sheath.	Both replants were successful. Both had PIP ROM 0–95° and normal MCP motion; 2-PD was 4 mm and 6 mm. DIP was fixed at 10° in one and fused at 0° in the other.	Return to school the day after discharge reported for the 14-y patient; otherwise NR.
Beris et al. (1994) [29]	4 / 22 mo–17 y / 3 F, 1 M	Ring avulsion; exact mechanism NR in 3; one involved an elevator	Urbaniak IIIa (2), IIIb (2)	IIIa injuries were distal amputations through the DIP with intact PIP/FDS. IIIb injuries involved complete skin avulsion and amputation at the PIP with avulsion/severance of both flexors. Digits involved included ring, middle, and index fingers.	All underwent successful microvascular replantation with 1 arterial repair and 1–2 venous repairs; nerve repair varied. IIIa cases underwent DIP arthrodesis. IIIb cases underwent staged FDP reconstruction, with one secondary reconstruction failing because of silicone-rod infection.	All 4 digits survived. Both IIIa patients had full PIP and MCP ROM. IIIb outcomes were poorer: one had limited postoperative motion, while the 22-mo patient had no active ROM but full passive ROM; 2-PD was not assessable in that patient at age 3 y.	NR
Scerri & Ratcliffe (1994) [30]	2 / 15–18 y / 2 M	Goalkeeper’s ring snagged on hook attaching soccer goal net	Urbaniak II (1), III (1)	Class III: complete degloving/amputation of the non-dominant ring finger with distal phalanx/skin avulsion, exposed middle phalanx, and FDP avulsion. Class II: incomplete degloving of the dominant ring finger with middle-phalanx fracture, circumferential skin loss, and bilateral neurovascular transections; tendons intact.	Class III patient declined replantation and underwent terminalization through the proximal phalanx with primary closure. Class II patient underwent bone excision, K-wire DIP arthrodesis, radial digital artery and 2 dorsal venous repairs, and nerve repairs.	Class III digit was amputated; follow-up function NR. Class II digit was salvaged with good function; 2-PD no better than 15 mm.	Class III patient declined prolonged replantation/absence from manual work; treatment preference. Otherwise NR.
Pynn et al. (1997)	1 / 16 y / M	Ring caught in basketball-net mesh during a	Urbaniak I	Right ring finger: near-total degloving distal to PIP; cyanotic distal flap with absent sensation; radial digital nerve avulsion; ulnar neurovascular bundle	Irrigation/debridement, microsurgical radial digital nerve coaptation (9-0 nylon), loose	Near-normal ROM at 2 mo; normal ROM and sensation at 2 y	Scar judged acceptable in clinical report

[19]		slam dunk		and tendon sheaths intact	closure, physiotherapy		
Levy (1999) [20]	1 / 13 y / M	Ring avulsion; exact mechanism NR	Urbaniak III	Dominant right ring finger: complete soft-tissue degloving at mid proximal phalanx with neurovascular and flexor/extensor loss; partial distal-phalanx amputation	Initial debridement/abdominal flap, flap division at 3 wk, debridements and FTSG; poor function led to ray resection at 5 mo	25 y later full pain-free hand ROM; grip 120 lb injured vs 140 lb other, grip strength decrease only noticed with prolonged tennis; 5 mm gap between 3rd and 5th digit, rare mild web-space paresthesia; patient is surgeon without technical limitations	Authors describe excellent cosmetic result, often unnoticed; mild difficulty carrying small change; occupational satisfaction evident
Hankin et al. (2000) [21]	1 / 11 y / F	Ring snagged on swing-set frame while jumping from moving swing	NR	Left little finger: amputation with proximal-phalanx-level circumferential soft-tissue degloving; skeletonized digit	Replantation judged impossible; definitive amputation/reconstruction not described	Digit not replanted; postoperative condition, function and follow-up NR	Authors discuss potential psychological impairment, family guilt and peer attention, and increased jewelry-wearing by children generally; not measured or reported for this patient
Huemer & Dunst (2005) [22]	1 / 17 y / M	Ring caught on fence while jumping over it	NR	Right little finger: amputation through DIP; FDP tendon pulled out entirely; FDS insertion intact (patient could flex stump)	Torn-out FDP resected; microsurgical replantation, aspirin and IV heparin 7 d	Successful healing; at 7 wk active PIP flexion 50°, DIP 30°	NR
Hyza et al. (2007) [12]	1 / 17 y / M	Glove caught in rotating machine pulled ring off finger	Urbaniak III; Sturzenegger: proximal arterial injury	Left little finger: complete ring avulsion with distal avulsion, tendon/neurovascular damage and disrupted DIP	Replantation, extensive vascular debridement, vein graft for 1 arterial inflow, 2 venous repairs, DIP arthrodesis	Digit survived; at 28 mo TAM 190° (73%), grip 34 vs 41 kg, static 2-PD 11 mm, moving 9 mm, no cold intolerance	Patient satisfaction 1/5 (1 = most satisfied); cosmetic outcomes not separately scored
Lefèvre et al. (2011) [4]	15 / mean 13.3 y (10–15 y) / sex NR	Ring avulsion; exact mechanisms NR	Urbaniak II (3), III (12); Tamai III (4), IV (9), V (2)	Severe injuries involving ring, middle, and little fingers, including complete degloving and bone-level amputations from the DIP/PIP to proximal phalangeal levels. Skin loss extended variably to P1, PIP, or MCP levels; tendon injury ranged from none to FDP, FDS, and/or extensor disruption, with extensive arterial and nerve injury.	4 underwent primary stump revision without attempted replantation. Revascularization/replantation was attempted in 11 using direct arterial repair, crossed arterial anastomosis, and/or arterial vein grafts; venous repair varied from none to 2 repaired veins.	3 complete survivals, 1 partial survival, 7 failures/revision amputations after attempted revascularization, and 4 primary amputations/no salvage. Functional measures were reported for successful survivors but were not consistently linked to individual identifiers.	NR
Özaksar et al. (2012) [31]	3 / 15–18 y / 2 F, 1 M	Ring avulsion; exact mechanisms NR	Modified Kay IVd (2), IVp (1)	All 3 had complete right-sided ring-avulsion amputations; digit NR. Two amputations were distal to the FDS insertion and one was proximal to the FDS insertion.	All underwent replantation with end-to-end arterial repair, 2 end-to-end venous repairs, and digital nerve repair. One required secondary artery transfer and one required secondary skin grafting.	All 3 replants were successful. One had no individual quantitative sensory/motion data. The other 2 had MP/PIP/DIP ROM of 90°/60°/10° and 100°/90°/0°, with 2-PD of 11 mm and 7 mm, respectively.	NR
Adani et al. (2013) [7]	1 / 14 y / F	Ring avulsion; exact mechanism NR	Modified Kay IVd	Complete ring finger amputation distal to FDS insertion	Replantation; 1 transfer of collateral ulnar digital artery from middle finger; 2 direct suturing of veins; direct ulnar digital nerve suture	Replant successful; TAM 195°, static 2-PD 9 mm, moving 2-PD 8 mm at 2 mo follow-up	NR
Crosby et al. (2014) [11]	1 / 16 y / F	Wearing a ring; finger caught in power-takeoff machinery	Urbaniak III	Left ring finger: complete degloving/amputation; specific involved tendons/vessels not reported for this case	Primary amputation revision at MCP level (cohort class III treatment description)	No digital salvage; individual ROM, sensation, appearance NR	NR
Hamzan et al. (2020) [2]	1 / 10 y / M	Ring caught while handling heavy sports equipment; exact mechanism NR	Urbaniak III	Dominant right thumb: complete amputation through distal aspect of proximal phalanx; FPL avulsed to musculotendinous junction, remained attached to amputated portion; 2 digital arteries damaged	K-wire replant; initial ulnar artery repair thrombosed from intimal damage; radial artery vein graft bridging 10 mm gap; 2 venous anastomoses, nerve coaptation, temporary allograft; FDMA flap at 1 mo; FDS-to-FPL tendon transfer at 2 mo; intensive physiotherapy	Thumb survived despite venous congestion, wound necrosis and delayed union; good opposition/CMC ROM, residual IP stiffness 3 mo s/p initial trauma; functional photos at 10 mo	Child reported satisfaction with functional and aesthetic result
Zhu & Currie (2021)	1 / 14 y / M	Ring snagged on metal spike jumping off	Modified Kay IVp	Right ring finger: complete amputation at head of proximal phalanx with bony fracture; FDP avulsed at insertion of distal phalanx, FDS proximally	K-wire replant, FDS-to-FDP Pulvertaft transfer; central-slip of FDS repaired; crossover radial to ulnar arterial/nerve	Viable digit and graft; at 1 mo PIPJ stiff; at 6 mo passive flexion of PIPJ to 70° with spongey end point; at 9 mo full passive PIP ROM and temperature	Undergoing therapy for trauma-related psychological effects; reports emotional relief

[23]		12-foot school fence		avulsed from forearm with muscle cuff; digital radial artery/nerve avulsed/nonviable	repairs; 2 venous repairs; SSG from thigh, formal BSSH hand therapy	sensation but poor active flexion; tenolysis/shortening planned	and satisfaction with digit's cosmetic preservation
Manoukov et al. (2022) [32]	1 individually identifiable / 18 y / M	Ring avulsion; cohort mechanism = ring caught on fence during a fall; patient-specific mechanism NR	Urbaniak III	Middle finger: complete degloving ring-avulsion injury; FDS, extensor apparatus, PIP joint reported intact for cohort, precise digit and anatomic extent for the 18-year-old NR	Ultra-thinned pedicled groin flap with flap division at 21 d with immediate active mobilization, as reported for cohort; pale skin graft from the hypothenar area used to mimic nail to improve the appearance of the finger dorsum	Fig. 4 depicts reconstructed finger at 14 mo; individual numeric ROM, sensation and survival data beyond depicted reconstruction NR; flap successful	Fig. 4 documents appearance; pale skin graft from hypothenar area simulated a fingernail. Cohort-wide satisfaction cannot be assigned to this patient.
Oukhouya & Cherrabi (2022) [24]	1 / 11 y / F	Ring on "fourth digit" caught nail fixed to wall during a jump	NR	"Fourth digit" (author-reported; figure appears to show 3rd digit): degloving with exposed bone/tendons; amputation of third phalanx	Emergency pedicled McGregor groin flap; tubularized coverage, division at 3 wk	Uncomplicated healing; authors report satisfactory result at 1 mo	Family and surgeons elected digit preservation for aesthetic/functional reasons; authors note satisfactory appearance
Yassin et al. (2022) [25]	1 / 17 y / M	Ring avulsion during football; exact mechanism NR	Urbaniak III	Left middle finger: circumferential amputation/degloving to PIP; amputation judged non-replantable	Digit temporarily buried in abdominal skin 2 wk; abdominal dorsal flap; reverse-flow shunt-restricted arterialized venous free flap for volar defect with artery/vein microsurgical anastomoses; aggressive therapy and Coban taping initiated at 2 wks	Viable coverage; protective sensation and nearly full ROM at 3 mo	Authors describe favorable aesthetic result; patient declined second-toe transfer due to his profession and also declined amputation

TABLE 3: Study-Level Characteristics, Management, and Outcomes of Pediatric Ring Avulsion Injuries Reported in the Literature

Study-level summary of 19 publications describing at least 40 pediatric ring avulsion cases, including injury mechanisms and classifications, extent of injury, surgical management, and reported anatomical, functional, cosmetic, and psychosocial outcomes, where available [2,4,7,11,12,19–32].

Abbreviations: 2-PD, two-point discrimination; BSSH, British Society for Surgery of the Hand; CMC, carpometacarpal; DIP, distal interphalangeal; FDMA, first dorsal metacarpal artery; FDP, flexor digitorum profundus; FDS, flexor digitorum superficialis; FPL, flexor pollicis longus; FTSG, full-thickness skin graft; IP, interphalangeal; IV, intravenous; K-wire, Kirschner wire; MCP, metacarpophalangeal; MP, metacarpophalangeal; NR, not reported; P1, proximal phalanx; PIP, proximal interphalangeal; PIPJ, proximal interphalangeal joint; ROM, range of motion; SSG, split-skin graft; STSG, split-thickness skin graft; TAM, total active motion; M, male; F, female; s/p, status post; d, days; wk, weeks; mo, months; y, years.

Authors (Year)	Patient ID in source / age / sex	Mechanism of injury	Classification (as reported)	Extent of injury	Repair / management	Anatomic / functional outcome	Cosmetic / psychosocial comments	Source location
Bevin & Chase (1963) [26]	Case 1 / young child (exact age NR) / M	Accidental traction on a ring while playing.	NR (pre-Urbaniak report)	Left ring finger: complete soft-tissue avulsion; no viable functional tissue; no sensation or dynamic function present.	Primary digit amputation; later fifth digit/metacarpal transfer to close fourth-ray gap.	Digit not salvaged; later hand reconstruction restored symmetry; quantitative function NR.	Authors describe improved symmetry s/p metacarpal transfer, with a more acceptable hand functionally and cosmetically, in general; no other reported outcomes.	p. 391, Case reports
Flagg et al. (1977) [27]	Case 3 / 17 y / M	Ring caught on school door hinge when patient tripped	NR (authors did not assign class)	Dominant left little finger: circumferential avulsion from web to middle third of middle phalanx; cold, white, insensate; both arteries, all veins, radial nerve severed, extensor disruption distal to central tendon; partly disarticulated DIP	DIP arthrodesis using distal phalanx as bone graft; deltopectoral flap cover (allowing PIP −10° to 40°); delayed (10 mo) neurovascular island flap from adjacent ring finger due to poor sensibility, arthrodesis demineralization and displacement	Salvaged digit; at 10 mo acceptable contour and movement; at 6 and 27 mo s/p island flap static 2-PD 3 mm with cortical sensibility retrained; at 2 yr s/p injury, natural contour, dynamic function, stable pinch, sensibility in pinch and ulnar border, cold sensitivity	Acceptable contour specifically described; patient happy to have little finger and uses for all but heavy lifting	pp. 243–244, Case 3
Tsai et al. (1984)	P.M. / 6 y /	Ring avulsion; exact	Urbaniak III;	Complete amputation; skin avulsed from proximal phalanx; DIP disarticulation with middle-phalanx	K-wire DIP fixation; palmar-plate/collateral repair; 2 arteries vein-	Successful replant; PIP 0–95°, DIP	NR	p. 71, Table I

[28]	sex NR	mechanism NR	Carroll IV	condyle avulsion; artery/vein/nerve disruption	grafted, 1 vein graft + 2 direct venous repairs; radial digital nerve repair; STSG	fixed 10°, MCP normal; 2-PD 4 mm		
Tsai et al. (1984) [28]	A.K. / 14 y / F	Ring avulsion; exact mechanism NR	Urbaniak III; Carroll IV	Complete amputation; skin avulsed from proximal phalanx; DIP disarticulation with extensor and FDP disruption; artery/vein/nerve disruption	DIP fusion, extensor tendon repair, FDP fixed to middle-phalanx sheath; 2 arterial + 3 venous vein graft repairs; 2 nerve repairs; STSG	Successful replant; PIP 0–95°, DIP fused 0°, MCP normal; 2-PD 6 mm; returned to school the day after discharge	Return to school reported	p. 71, Table I; p. 72
Beris et al. (1994) [29]	Case 2 (Table 1) / 17 y / F	Ring avulsion; exact mechanism NR	Urbaniak IIIa	Dominant right ring finger: distal amputation through DIP, intact PIP/FDS (subclass a definition)	Successful microvascular replantation; 1 artery + 2 veins, no nerve repaired; K-wire DIP arthrodesis	Digit survived; full PIP and MCP ROM; individual 2-PD NR	NR	pp. 460–462, Table I and Fig. I
Beris et al. (1994) [29]	Case 6 (Table 1) / 6 y / F	Ring avulsion involving elevator; exact mechanism NR	Urbaniak IIIa	Dominant right middle finger: distal amputation through DIP, intact PIP/FDS (subclass a definition)	Successful microvascular replantation; 1 artery, 2 veins, 1 nerve; K-wire DIP arthrodesis	Digit survived; full PIP and MCP ROM; individual 2-PD NR	NR	pp. 460–462, Table I
Beris et al. (1994) [29]	Case 4 (Table 1) / 8 y / M	Ring avulsion; exact mechanism NR	Urbaniak IIIb	Dominant right index finger: complete skin avulsion and amputation at level of PIP, avulsion/severance of both flexors (subclass b definition)	Successful microvascular replantation; 1 artery, 1 vein, 1 nerve; staged two-stage FDP reconstruction	Digit survived; individual active ROM and 2-PD not provided; IIIb subgroup had limited postoperative motion	NR	pp. 460–462, Table I and Results
Beris et al. (1994) [29]	Case 5 (Table 1) / 22 mo / F	Ring avulsion; exact mechanism NR	Urbaniak IIIb	Right middle finger: complete skin avulsion and amputation at level of PIP, avulsion/severance of both flexors (subclass b definition)	Successful microvascular replantation: 1 artery, 2 veins, no nerve repair; failed secondary FDP reconstruction due to implanted silicone rod infection	Digit survived; no active ROM; full passive ROM; sensory 2-PD not assessable at last examination (age 3 y)	NR	pp. 460–462, Table I and Results
Scerri & Ratcliffe (1994) [30]	Case 2 / 18 y / M	Goalkeeper's ring snagged on hook attaching soccer goal net	Urbaniak III	Non-dominant left ring finger: complete degloving/amputation; distal phalanx and skin avulsed, middle phalanx exposed; FDP avulsed from muscle belly	Replantation offered but declined; terminalization through neck of proximal phalanx and primary skin closure	Digit amputated; individual follow-up function NR	Patient declined prolonged replantation/absence from manual work; treatment preference	p. 459, Case 2
Scerri & Ratcliffe (1994) [30]	Case 3 / 15 y / M	Goalkeeper's ring snagged on hook attaching soccer goal net	Urbaniak II	Dominant right ring finger: incomplete degloving; middle-phalanx shaft fracture; circumferential skin loss ~2 cm; bilateral neurovascular transections, tendons intact	Excision of distal middle-phalanx segment, K-wire DIP arthrodesis; radial digital artery + 2 dorsal veins repaired, nerves repaired	Digit salvaged; described as good function; 2-PD no better than 15 mm	NR	pp. 459–460, Case 3
Pynn et al. (1997) [19]	Single case report / 16 y / M	Ring caught in basketball-net mesh during a slam dunk	Urbaniak I	Right ring finger: near-total degloving distal to PIP; cyanotic distal flap with absent sensation; radial digital nerve avulsion; ulnar neurovascular bundle and tendon sheaths intact	Irrigation/debridement, microsurgical radial digital nerve coaptation (9-0 nylon), loose closure, physiotherapy	Near-normal ROM at 2 mo; normal ROM and sensation at 2 y	Scar judged acceptable in clinical report	pp. 72–73
Levy (1999) [20]	Single case report / 13 y / M	Ring avulsion; exact mechanism NR	Urbaniak III	Dominant right ring finger: complete soft-tissue degloving at mid proximal phalanx with neurovascular and flexor/extensor loss; partial distal-phalanx amputation	Initial debridement/abdominal flap, flap division at 3 wk, debridements and FTSG; poor function led to ray resection at 5 mo	25 y later full pain-free hand ROM; grip 120 lb injured vs 140 lb other, grip strength decrease only noticed with prolonged tennis; 5mm gap between 3rd and 5th digit, rare mild web-space paresthesia; patient is surgeon without technical limitations	Authors describe excellent cosmetic result, often unnoticed; mild difficulty carrying small change; occupational satisfaction evident	pp. 359–360
Hankin et al. (2000) [21]	Single case report / 11 y / F	Ring snagged on swing-set frame while jumping from moving swing	NR	Left little finger: amputation with proximal-phalanx-level circumferential soft-tissue degloving; skeletonized digit	Replantation judged impossible; definitive amputation/reconstruction not described	Digit not replanted; postoperative condition, function and follow-up NR	Authors discuss potential psychological impairment, family guilt and peer attention, and increased jewellery-wearing by children generally; not measured or reported for this patient	pp. 635–637

Huemer & Dunst (2005) [22]	Single case report / 17 y / M	Ring caught on fence while jumping over it	NR	Right little finger: amputation through DIP; FDP tendon pulled out entirely; FDS insertion intact (patient could flex stump)	Torn-out FDP resected; microsurgical replantation, aspirin and IV heparin 7 d	Successful healing; at 7 wk active PIP flexion 50°, DIP 30°	NR	NEJM 352:e5, clinical vignette
Hyza et al. (2007) [12]	Case 3 / 17 y / M	Glove caught in rotating machine pulled ring off finger	Urbaniak III; Sturzenegger: proximal arterial injury	Left little finger: complete ring avulsion with distal avulsion, tendon/neurovascular damage and disrupted DIP	Replantation, extensive vascular debridement, vein graft for 1 arterial inflow, 2 venous repairs, DIP arthrodesis	Digit survived; at 28 mo TAM 190° (73%), grip 34 vs 41 kg, static 2-PD 11 mm, moving 9 mm, no cold intolerance	Patient satisfaction 1/5 (1 = most satisfied); cosmetic outcomes not separately scored	p. 164, Table II
Lefèvre et al. (2011) [4]	Kab / 10 y / sex NR	Ring avulsion; exact mechanism NR	Urbaniak III, Tamai III	Little finger: DIP-level bone section; skin loss section to level of phalange 1; FDP/extensor + 2 artery/2 nerve injuries	Primary stump revision; replantation not attempted	Amputation/no digital salvage	NR	p. 261, Table I; pp. 262–263
Lefèvre et al. (2011) [4]	Ma / 11 y / sex NR	Ring avulsion; exact mechanism NR	Urbaniak III, Tamai III	Ring finger: DIP-level bone section; skin loss section to level of phalange 1; FDP/extensor + 2 artery/2 nerve injuries	Primary stump revision; replantation not attempted	Amputation/no digital salvage	NR	p. 261, Table I; pp. 262–263
Lefèvre et al. (2011) [4]	Kal / 14 y / sex NR	Ring avulsion; exact mechanism NR	Urbaniak III, Tamai III	Ring finger: DIP-level bone section; skin loss section to level of phalange 1; FDP/extensor + 2 artery/2 nerve injuries	Primary stump revision; replantation not attempted	Amputation/no digital salvage	NR	p. 261, Table I; pp. 262–263
Lefèvre et al. (2011) [4]	Le / 15 y / sex NR	Ring avulsion; exact mechanism NR	Urbaniak III, Tamai V	Ring inger: phalange 3-level bone section; skin loss section to level of MCP; FDP/FDS/extensor + 2 artery/2 nerve injuries	Primary stump revision; replantation not attempted	Amputation/no digital salvage	NR	p. 261, Table I; pp. 262–263
Lefèvre et al. (2011) [4]	Be / 15 y / sex NR	Ring avulsion; exact mechanism NR	Urbaniak II; Tamai IV	Ring finger: complete degloving; skin loss section to level of PIP; extensor + 2 artery injuries; venous continuity present	Revascularization, 2 direct arterial anastomoses; venous drainage via continuous flap	Complete survival; functional measures in successful survivors only, not reliably linked by identifier	NR	p. 261, Table I; pp. 262–263
Lefèvre et al. (2011) [4]	Do / 13 y / sex NR	Ring avulsion; exact mechanism NR	Urbaniak II; Tamai IV	Ring finger: phalange 1-level bone section; skin loss section to level of phalange 1; FDP/FDS + 2 artery injuries; venous continuity present	Revascularization, 1 arterial vein graft; venous drainage via continuous flap	Complete survival; individual functional outcome NR	NR	p. 261, Table I; pp. 262–263
Lefèvre et al. (2011) [4]	Fo / 13 y / sex NR	Ring avulsion; exact mechanism NR	Urbaniak III, Tamai V	Ring finger: phalange 1-level bone section; skin loss section to level of MCP; FDP/FDS/extensor + 2 artery/2 nerve injuries	Revascularization, 2 arterial repairs (1 direct + 1 vein graft), 2 venous repairs	Complete survival; individual functional outcome NR	NR	p. 261, Table I; pp. 262–263
Lefèvre et al. (2011) [4]	As / 13 y / sex NR	Ring avulsion; exact mechanism NR	Urbaniak II; Tamai IV	Ring finger: phalange 1-level bone section; skin loss section to level of phalange 1; FDP/extensor + 2 artery/1 nerve injuries	Revascularization, 1 crossed arterial anastomosis, 1 vein repair	Partial survival; underwent later trans-phalanx 2 revision 6 d after initial operation	NR	p. 261, Table I; pp. 262–263
Lefèvre et al. (2011) [4]	Ak / 13 y / sex NR	Ring avulsion; exact mechanism NR	Urbaniak III, Tamai III	Ring finger: phalange 1-level bone section; skin loss section to level of phalange 2; FDP + 2 artery/2 nerve injuries	1 direct arterial repair, no vein repair	Revascularization attempted, final failure/revision amputation	NR	p. 261, Table I; pp. 262–263
Lefèvre et al. (2011) [4]	Lo / 14 y / sex NR	Ring avulsion; exact mechanism NR	Urbaniak III, Tamai IV	Middle finger: DIP-level bone section; skin loss section to level of PIP; FDP + 2 artery/2 nerve injuries	1 crossed arterial anastomosis, 1 vein repair	Revascularization attempted, final failure/revision amputation	NR	p. 261, Table I; pp. 262–263
Lefèvre et al. (2011) [4]	Fr / 15 y / sex NR	Ring avulsion; exact mechanism NR	Urbaniak III, Tamai IV	Ring finger: DIP level bone section; skin loss section to level of phalange 1; FDP/extensor + 2 artery/2 nerve injuries	1 vein-graft arterial repair, 2 veins repaired	Initial perfusion restored, later failure/revision amputation	NR	p. 261, Table I; pp. 262–263
Lefèvre et al. (2011) [4]	Na / 13 y / sex NR	Ring avulsion; exact mechanism NR	Urbaniak III, Tamai IV	Ring finger: phalange 3-level bone section; skin loss section to level of phalange 1; no tendon injury, 2 artery/2 nerve injuries	1 direct arterial repair; no veins repaired	No immediate perfusion; definitive failure/revision amputation	NR	p. 261, Table I; pp. 262–263

Lefèvre et al. (2011) [4]	Go / 13 y / sex NR	Ring avulsion; exact mechanism NR	Urbaniak III, Tamai IV	Middle finger: DIP level bone section; skin loss section to level of phalange 1; FDP/FDS/extensor + 2 artery/2 nerve injuries	1 arterial vein graft; no repaired veins	No immediate perfusion; definitive failure/revision amputation	NR	p. 261, Table I; pp. 262–263
Lefèvre et al. (2011) [4]	JC / 13 y / sex NR	Ring avulsion; exact mechanism NR	Urbaniak III, Tamai IV	Middle finger: complete degloving; skin loss section to level of phalange 1; no tendon injury, 2 artery/2 nerve injuries	1 direct arterial repair, 1 venous repair	Initial perfusion restored, delayed failure/revision amputation	NR	p. 261, Table I; pp. 262–263
Lefèvre et al. (2011) [4]	Pa / 14 y / sex NR	Ring avulsion; exact mechanism NR	Urbaniak III, Tamai IV	Middle finger: PIP level bone section; skin loss section to level of phalange 1; FDP/FDS/extensor + 2 artery/2 nerve injuries	1 crossed arterial anastomosis; no vein repaired	No immediate perfusion; final failure/revision amputation	NR	p. 261, Table I; pp. 262–263
Özaksar et al. (2012) [31]	Case 7 / 18 y / M	Ring avulsion; exact mechanism NR	Modified Kay IVd	Right (digit NR): complete ring avulsion amputation distal to FDS insertion	Replantation; end-to-end arterial repair, 2 end-to-end venous repairs, radial digital nerve repair; secondary artery transfer	Replant successful; individual quantitative sensory and motion measures NR	NR	p. 330, Table I
Özaksar et al. (2012) [31]	Case 29 / 15 y / F	Ring avulsion; exact mechanism NR	Modified Kay IVp	Right (digit NR): complete ring avulsion amputation proximal to FDS insertion	Replantation; end-to-end arterial repair, 2 end-to-end venous repairs, radial + ulnar nerve repair; secondary skin graft	Replant successful; MP/PIP/DIP 90°/60°/10°; 2-PD 11 mm; Semmes-Weinstein monofilament test (SW MT) 3.61	NR	p. 331, Table I
Özaksar et al. (2012) [31]	Case 35 / 15 y / F	Ring avulsion; exact mechanism NR	Modified Kay IVd	Right (digit NR): complete ring avulsion amputation distal to FDS insertion	Replantation; end-to-end arterial repair, 2 end-to-end venous repairs, radial digital nerve repair	Replant successful; MP/PIP/DIP 100°/90°/0°; 2-PD 7 mm; SW MT 2.83	NR	p. 331, Table I
Adani et al. (2013) [7]	Case 30 / 14 y / F	Ring avulsion; exact mechanism NR	Modified Kay IVd	Complete ring finger amputation distal to FDS insertion	Replantation; 1 transfer of collateral ulnar digital artery from middle finger; 2 direct suturing of veins; direct ulnar digital nerve suture	Replant successful; TAM 195°, static 2-PD 9 mm, moving 2-PD 8 mm at 2 mo follow-up	NR	p. 951, Table I
Crosby et al. (2014) [11]	Case 27 / 16 y / F	Wearing a ring; finger caught in power-takeoff machinery	Urbaniak III	Left ring finger: complete degloving/amputation; specific involved tendons/vessels not reported for this case	Primary amputation revision at MCP level (cohort class III treatment description)	No digital salvage; individual ROM, sensation, appearance NR	NR	p. 277, Table III and class III Results
Hamzan et al. (2020) [2]	Single case report / 10 y / M	Ring caught while handling heavy sports equipment; exact mechanism NR	Urbaniak III	Dominant right thumb: complete amputation through distal aspect of proximal phalanx; FPL avulsed to musculotendinous junction, remained attached to amputated portion; 2 digital arteries damaged	K-wire replant; initial ulnar artery repair thrombosed from intimal damage; radial artery vein graft bridging 10 mm gap; 2 venous anastomoses, nerve coaptation, temporary allograft; FDMA flap at 1 mo; FDS-to-FPL tendon transfer at 2 mo; intensive physiotherapy	Thumb survived despite venous congestion, wound necrosis and delayed union; good opposition/CMC ROM, residual IP stiffness3 mo s/p initial trauma; functional photos at 10 mo	Child reported satisfaction with functional and aesthetic result	pp. 96–98 and Fig. 3
Zhu & Currie (2021) [23]	Single case report / 14 y / M	Ring snagged on metal spike jumping off 12-foot school fence	Modified Kay IVp	Right ring finger: complete amputation at head of proximal phalanx with bony fracture; FDP avulsed at insertion of distal phalanx, FDS proximally avulsed from forearm with muscle cuff; digital radial artery/nerve avulsend/nonviable	K-wire replant, FDS-to-FDP Pulvertaft transfer; central-slip of FDS repaired; crossover radial to ulnar arterial/nerve repairs; 2 venous repairs; SSG from thigh, formal BSSH hand therapy	Viable digit and graft; at 1 mo PIPJ stiff; at 6 mo passive flexion of PIPJ to 70° with spongy end point; at 9 mo full passive PIP ROM and temperature sensation but poor active flexion; tenolysis/shortening planned	Undergoing therapy for trauma-related psychological effects; reports emotional relief and satisfaction with digit's cosmetic preservation	BMJ Case Rep 2021, pp. 1–2
Manoukov et al. (2022) [32]	Fig. 4 patient / 18 y / M	Ring avulsion; cohort mechanism = ring caught on fence during a fall; patient-specific mechanism NR	Urbaniak III	Middle finger: complete degloving ring-avulsion injury; FDS, extensor apparatus, PIP joint reported intact for cohort, precise digit and anatomic extent for the 18-year-old NR	Ultra-thinned pedicled groin flap with flap division at 21 d with immediate active mobilization, as reported for cohort; ipale skin graft from the hypothenar area used to mimic nail to improve the appearance of the finger dorsum	Fig. 4 depicts reconstructed finger at 14 mo; individual numeric ROM, sensation and survival data beyond depicted reconstruction NR; flap successful	Fig. 4 documents appearance; pale skin graft from hypothenar area simulated a fingernail. Cohort-wide satisfaction cannot be assigned to this patient.	p. 631, Fig. 4; pp. 626–632
Oukhouya		Ring on "fourth		"Fourth digit" (author-reported;			Family and surgeons	

& Cherrabi (2022) [24]	Single image case / 11 y / F	digit" caught nail fixed to wall during a jump	NR	figure appears to show 3rd digit): degloving with exposed bone/tendons; amputation of third phalanx	Emergency pedicled McGregor groin flap; tubularized coverage, division at 3 wk	Uncomplicated healing; authors report satisfactory result at 1 mo	elected digit preservation for aesthetic/functional reasons; authors note satisfactory appearance	pp. 1–3, English/French clinical text
Yassin et al. (2022) [25]	Single case report / 17 y / M	Ring avulsion during football; exact mechanism NR	Urbaniak III	Left middle finger: circumferential amputation/degloving to PIP; amputation judged non-replantable	Digit temporarily buried in abdominal skin 2 wk; abdominal dorsal flap; reverse-flow shunt-restricted arterialized venous free flap for volar defect with artery/vein microsurgical anastomoses; aggressive therapy and Coban taping initiated at 2 wks	Viable coverage; protective sensation and nearly full ROM at 3 mo	Authors describe favorable aesthetic result; patient declined second-toe transfer due to his profession and also declined amputation	pp. 1-3, PRS Global Open 2022;10:e4511, clinical case

TABLE 4: Patient-Level Characteristics, Management, and Outcomes of Pediatric Ring Avulsion Injuries Reported in the Literature

Patient-level characteristics of 40 pediatric ring avulsion cases identified across 19 studies, including patient demographics, injury mechanisms and classifications, extent of injury, surgical management, and reported anatomical, functional, cosmetic, and psychosocial outcomes [2,4,7,11,12,19–32]. Individual patient identifiers and source locations are provided where available. Outcomes and clinical details are presented as reported in the original publications.

Abbreviations: 2-PD, two-point discrimination; BSSH, British Society for Surgery of the Hand; CMC, carpometacarpal; DIP, distal interphalangeal; FDMA, first dorsal metacarpal artery; FDP, flexor digitorum profundus; FDS, flexor digitorum superficialis; FPL, flexor pollicis longus; FTSG, full-thickness skin graft; IP, interphalangeal; IV, intravenous; K-wire, Kirschner wire; MCP, metacarpophalangeal; MP, metacarpophalangeal; NR, not reported; PIP, proximal interphalangeal; PIPJ, proximal interphalangeal joint; ROM, range of motion; SSG, split-skin graft; STSG, split-thickness skin graft; SW MT, Semmes-Weinstein monofilament test; TAM, total active motion; M, male; F, female; s/p, status post; d, days; wk, weeks; mo, months; y, years.

Discussion

Injury Severity and Classification

The included studies demonstrate a broad spectrum of injury severity, ranging from injuries with preserved circulation to complete degloving and amputation. The Urbaniak and Kay classification systems provide a useful framework for describing injury severity and informing treatment decisions [3,5,6]. Carroll, Tamai, and Sturzenegger classifications provided complementary information regarding structural injury, anatomical amputation level, and the level of neurovascular injury, respectively [4,8-12]. Lower-grade injuries with preserved circulation generally required less extensive reconstruction and demonstrated favorable outcomes, whereas severe vascular compromise and complete amputations often required complex microsurgical repair. Preservation of the PIP joint and flexor digitorum superficialis (FDS) insertion may improve the potential for functional recovery, while more proximal injuries involving the flexor mechanism are associated with poorer functional prognosis [3,7,29]. Lefèvre et al. demonstrated substantially poorer survival among Class III injuries [4].

Microsurgical Complexity and Reconstruction

Severe ring avulsion injuries frequently require reconstruction beyond simple end-to-end vascular repair. Extensive arterial intimal damage may necessitate debridement to healthy vessels, interposition vein grafting, or arterial transfer and crossover anastomoses [7,12,28,29]. Several reports also described repair of multiple veins to improve venous drainage, as well as simultaneous or staged tendon, nerve, and soft-tissue reconstruction [2,12,23,28,29]. Hyza et al. particularly emphasized excision of damaged arterial segments and primary vein grafting because traction injury may extend beyond the visibly damaged vessel [12]. Secondary procedures such as tendon reconstruction, tenolysis, skin grafting, and flap coverage were required in several cases [2,23,32].

Pediatric Replantation and Functional Recovery

Pediatric digit replantation has traditionally been associated with broader indications and favorable functional recovery compared with adults [13,33]. Berlin et al. found better short-term outcomes in children than adults following replantation, including lower adjusted risks of complications and subsequent amputation [13].

Notably, Michalko and Bentz emphasized that restoration of digit viability does not guarantee restoration of useful function and noted that pediatric amputations commonly result from crush or avulsion mechanisms, which may compromise outcomes [33]. They also noted that less restrictive indications are generally used for replantation in children because of their greater healing potential [33]. These considerations are especially relevant to ring avulsion injuries, in which traction may damage vessels, nerves, tendons, and soft tissues

over a substantial length.

Lefèvre et al. similarly suggested that poorer survival in pediatric avulsion injuries may reflect attempts to salvage particularly severe injuries, due to lower threshold for attempting such replantations in children [4]. Therefore, the potential advantages of pediatric healing should not be assumed to overcome extensive ring-avulsion damage; decisions regarding salvage should consider both technical feasibility and anticipated function.

Functional Outcomes

Functional outcomes among successfully salvaged digits varied considerably. Some patients recovered substantial motion and sensation, whereas others experienced persistent stiffness, limited active flexion, or required additional reconstruction [2,7,12,22,23,28]. Reports by Tsai et al. and Hyza et al. demonstrate that meaningful motion and sensory recovery are possible following severe injuries, while Hamzan et al. and Zhu and Currie highlight limitations that may persist despite successful digit survival [2,12,23,28]. Levy described eventual ray amputation after unsuccessful salvage, followed by favorable long-term hand function and cosmetic appearance [20]. Together, these findings support evaluating successful treatment using active motion, sensation, strength, need for secondary procedures, and overall hand function rather than digit survival alone.

Cosmetic Outcomes

Cosmetic outcomes were inconsistently reported and were generally described qualitatively rather than assessed using standardized measures. Several authors reported acceptable appearance or patient satisfaction following reconstruction [2,12,19,20,23,24]. Other reports described reconstructive techniques intended to improve appearance, including flap coverage and simulated nail reconstruction [32]. However, favorable descriptions of postoperative appearance do not necessarily reflect patient-reported satisfaction or long-term cosmetic outcomes. No included study used a validated pediatric cosmetic or body-image measure.

Psychosocial Outcomes

Direct evidence regarding psychosocial outcomes was particularly limited. Zhu and Currie reported that their patient was undergoing psychological therapy and described emotional benefit associated with preservation of the digit's appearance [23]. Hankin et al. discussed the potential for psychological impairment, family guilt, permanent disfigurement, and unwanted peer attention following pediatric digit amputation, although these outcomes were not formally assessed in their patient [21]. Michalko and Bentz also noted more generally that successful replantation may reduce some of the emotional trauma associated with amputation in children, although this was not based on a formal psychosocial outcome assessment [33]. No included study used validated instruments to evaluate psychological distress, body image, emotional recovery, or quality of life. Existing literature also supports the broader psychological and social impact of severe hand injury [14,15].

Prevention

Preventive strategies may also be relevant, particularly because several reported injuries occurred during sports, recreational activities, or play. Although excluded from the clinical systematic-review cohort, Zetlitz et al. investigated ring design in a cadaveric study and found that rings modified with a transverse slot produced substantially less tissue injury than intact rings [34]. These findings suggest that breakaway or mechanically weakened ring designs may reduce the severity of ring avulsion injuries. The growing use of wearable ring technology provides additional contemporary relevance to preventive ring design [3].

Limitations

This review has several limitations. Despite the expanded evidence base, the available literature consists entirely of case reports and small case series, limiting the strength and generalizability of the findings. The predominance of case-based literature introduces a risk of publication bias, as unusual injuries, technically challenging reconstructions, and successful outcomes may be more likely to be reported. Additionally, consecutive and complete inclusion of patients was often unclear in case series, introducing potential selection bias that may overestimate treatment success.

Considerable heterogeneity existed in injury severity, classification systems, treatment approaches, outcome definitions, and follow-up durations. The included studies also span nearly six decades (1963-2022), during which microsurgical techniques, replantation indications, rehabilitation practices, and reporting standards changed substantially. These temporal differences likely influenced treatment strategies and reported outcomes, although the available literature is insufficient to determine an independent effect of treatment era on digit survival or function. Mixed-age cohorts did not consistently

provide pediatric-specific outcomes, while missing or incomplete follow-up data further limited comparisons. Cosmetic and psychosocial outcomes were particularly susceptible to reporting bias because they were rarely evaluated systematically or from the perspective of the patient.

Additional limitations include restriction to English-language publications and the absence of a prospectively registered review protocol. Given the small and heterogeneous evidence base, a descriptive synthesis was performed without meta-analysis. Because successful replantations may be preferentially reported and patient inclusion was frequently unclear, the observed digit-survival proportions may overestimate treatment success and have limited generalizability to the broader pediatric ring avulsion population. Accordingly, these proportions should not be interpreted as population-level estimates or definitive estimates of treatment efficacy.

Conclusions

Pediatric ring avulsion injuries encompass a wide spectrum of severity, and management and functional recovery appear closely related to the extent of vascular, skeletal, tendon, and soft-tissue injury. Microsurgical revascularization and replantation can preserve severely injured digits in selected pediatric patients, but successful survival does not uniformly translate to complete functional recovery and may require staged reconstruction and prolonged rehabilitation. The current evidence is limited by small, heterogeneous case reports and series with inconsistent long-term follow-up. Cosmetic and psychosocial outcomes remain particularly underreported. Given the visible nature of these injuries, the potential impact of hand deformity during childhood and adolescence, and existing evidence of psychosocial effects following severe pediatric hand injuries, future studies should incorporate standardized functional and cosmetic evaluations, patient-reported outcome measures, and validated psychosocial assessments to better characterize the long-term consequences of pediatric ring avulsion injuries.

Additional Information

Author Contributions

All authors have reviewed the final version to be published and agreed to be accountable for all aspects of the work.

Concept and design: Diana Ghisa, Ivan Kliuikov, Gary Schwartz

Acquisition, analysis, or interpretation of data: Diana Ghisa, Ivan Kliuikov, Ann Mathew, Gary Schwartz, Claudia Ghisa

Drafting of the manuscript: Diana Ghisa, Ivan Kliuikov, Ann Mathew, Gary Schwartz

Critical review of the manuscript for important intellectual content: Diana Ghisa, Gary Schwartz, Claudia Ghisa

Supervision: Gary Schwartz

Disclosures

Conflicts of interest: In compliance with the ICMJE uniform disclosure form, all authors declare the following: **Payment/services info:** All authors have declared that no financial support was received from any organization for the submitted work. **Financial relationships:** All authors have declared that they have no financial relationships at present or within the previous three years with any organizations that might have an interest in the submitted work. **Other relationships:** All authors have declared that there are no other relationships or activities that could appear to have influenced the submitted work.

References

1. Bamba R, Malhotra G, Bueno RA Jr, Thayer WP, Shack RB: Ring avulsion injuries: a systematic review . Hand (N Y). 2018, 13:15-22. 10.1177/1558944717692094
2. Hamzan MI, Jeffrey MJ, Halim AS, Mat Saad AZ: Against all odds: traumatic thumb amputation following ring avulsion injury. Pediatr Traumatol Orthop Reconstr Surg. 2020, 8:95-100. 10.17816/PTORS17926
3. Smith L, Immerman I, Schroeder N, Shapiro LM: Current concepts in ring avulsion injuries . J Hand Surg Am. 2026, 51:1029-33. 10.1016/j.jhsa.2026.01.020
4. Lefèvre Y, Mallet C, Ilharreborde B, et al.: Digital avulsion with compromised vascularization: study of 23 cases in children. J Pediatr Orthop. 2011, 31:259-65. 10.1097/BPO.0b013e31820fc620
5. Urbaniak JR, Evans JP, Bright DS: Microvascular management of ring avulsion injuries . J Hand Surg Am. 1981, 6:25-30. 10.1016/S0363-5023(81)80006-8
6. Kay S, Werntz J, Wolff TW: Ring avulsion injuries: classification and prognosis . J Hand Surg Am. 1989, 14:204-13. 10.1016/0363-5023(89)90008-7
7. Adani R, Pataia E, Tarallo L, Mugnai R: Results of replantation of 33 ring avulsion amputations . J Hand Surg Am. 2013, 38:947-56. 10.1016/j.jhsa.2013.02.014

8. Carroll RE: Ring injuries in the hand . Clin Orthop Relat Res. 1974, 175-82. 10.1097/00003086-197410000-00018
9. Tamai S: Twenty years' experience of limb replantation: review of 293 upper extremity replants . J Hand Surg Am. 1982, 7:549-56. 10.1016/S0363-5023(82)80100-7
10. Sturzenegger M, Büchler U, Frey HP: [Ring avulsion injuries: improved indications for replantation] . Handchir Mikrochir Plast Chir. 1988, 20:255-8.
11. Crosby N, Hood J, Baker G, Lubahn J: Ring injuries of the finger: long-term follow-up . Hand (N Y). 2014, 9:274-81. 10.1007/s11552-014-9651-9
12. Hyza P, Vesely J, Drazan L, Stupka I, Ranno R, Castagnetti F: Primary vein grafting in treatment of ring avulsion injuries: a 5-year prospective study. Ann Plast Surg. 2007, 59:163-7. 10.1097/01.sap.0000252717.88972.01
13. Berlin NL, Tuggle CT, Thomson JG, Au A: Digit replantation in children: a nationwide analysis of outcomes and trends of 455 pediatric patients. Hand (N Y). 2014, 9:244-52. 10.1007/s11552-014-9628-8
14. Buncke GM, Buntic RF, Romeo O: Pediatric mutilating hand injuries . Hand Clin. 2003, 19:121-31. 10.1016/S0749-0712(02)00076-8
15. Grob M, Papadopulos NA, Zimmermann A, Biemer E, Kovacs L: The psychological impact of severe hand injury. J Hand Surg Eur Vol. 2008, 33:358-62. 10.1177/1753193407087026
16. Page MJ, McKenzie JE, Bossuyt PM, et al.: The PRISMA 2020 statement: an updated guideline for reporting systematic reviews. BMJ. 2021, 372:n71. 10.1136/bmj.n71
17. Moola S, Munn Z, Tufanaru C, et al.: Systematic reviews of etiology and risk . JBI Manual for Evidence Synthesis. Aromataris E, Munn Z (ed): JBI, Adelaide; 2020. 10.46658/JBIMES-20-08.
18. Munn Z, Barker TH, Moola S, et al.: Methodological quality of case series studies: an introduction to the JBI critical appraisal tool. JBI Evid Synth. 2020, 18:2127-33. 10.11124/JBISRIR-D-19-00099
19. Pynn BR, Bartkiw TP, Clarke HM: Ring avulsion injuries and the basketball player . Br J Sports Med. 1997, 31:72-4. 10.1136/bjsm.31.1.72
20. Levy HJ: Ring finger ray amputation: a 25-year follow-up . Am J Orthop (Belle Mead NJ). 1999, 28:359-60.
21. Hankin FM, Janda DH, Wittenberg B: Playground equipment contributing to a ring avulsion injury . Injury. 2000, 31:635-7. 10.1016/S0020-1383(00)00060-7
22. Huemer GM, Dunst KM: Images in clinical medicine. Finger avulsion with pulled-out flexor tendon . N Engl J Med. 2005, 352:e5. 10.1056/NEJMicm030406
23. Zhu Y, Currie L: Reimplantation of ring avulsion amputation of finger: intraoperative challenges and rehabilitation outcomes. BMJ Case Rep. 2021, 14: 10.1136/bcr-2021-245994
24. Oukhouya MA, Cherrabi H: [Mac Gregor flap for injured ring finger in a child] . Pan Afr Med J. 2022, 41:151. 10.11604/pamj.2022.41.151.33501
25. Yassin AM, Kokkinos C, Gorman M, Gnanalingham S, Nikkhah D: Reverse flow shunt restricted free venous flap for a ring avulsion injury. Plast Reconstr Surg Glob Open. 2022, 10:e4511. 10.1097/GOX.0000000000004511
26. Bevin AG, Chase RA: The management of ring avulsion injuries and associated conditions in the hand . Plast Reconstr Surg. 1963, 32:391-400. 10.1097/00006534-196310000-00001
27. Flagg SV, Finseth FJ, Krizek TJ: Ring avulsion injury. Plast Reconstr Surg. 1977, 59:241-8. 10.1097/00006534-197759020-00011
28. Tsai TM, Manstein C, DuBou R, Wolff TW, Kutz JE, Kleinert HE: Primary microsurgical repair of ring avulsion amputation injuries. J Hand Surg Am. 1984, 9:68-72. 10.1016/S0363-5023(84)80188-4
29. Beris AE, Soucacos PN, Malizos KN, Xenakis TA: Microsurgical treatment of ring avulsion injuries . Microsurgery. 1994, 15:459-63. 10.1002/micr.1920150705
30. Scerri GV, Ratcliffe RJ: The goalkeeper's fear of the nets . J Hand Surg Br. 1994, 19:459-60. 10.1016/0266-7681(94)90210-0
31. Ozaksar K, Toros T, Sügün TS, Kayalar M, Kaplan I, Ada S: Finger replantations after ring avulsion amputations. J Hand Surg Eur Vol. 2012, 37:329-35. 10.1177/1753193411423877
32. Manoukov Y, Beauthier-Landauer V, Sautet A, Teboul F, Thumser J, Cambon-Binder A: An ultra-thinned groin flap for reconstruction of complete digital ring avulsion injuries. J Hand Surg Eur Vol. 2022, 47:626-32. 10.1177/17531934221078233
33. Michalko KB, Bentz ML: Digital replantation in children . Crit Care Med. 2002, 30:S444-7. 10.1097/00003246-200211001-00009
34. Zetlitz E, Scott JR, Shaw-Dunn J, Dabernig J: Prevention of paediatric ring avulsions - a cadaveric study . J Hand Surg Eur Vol. 2008, 33:373-6. 10.1177/1753193407087576