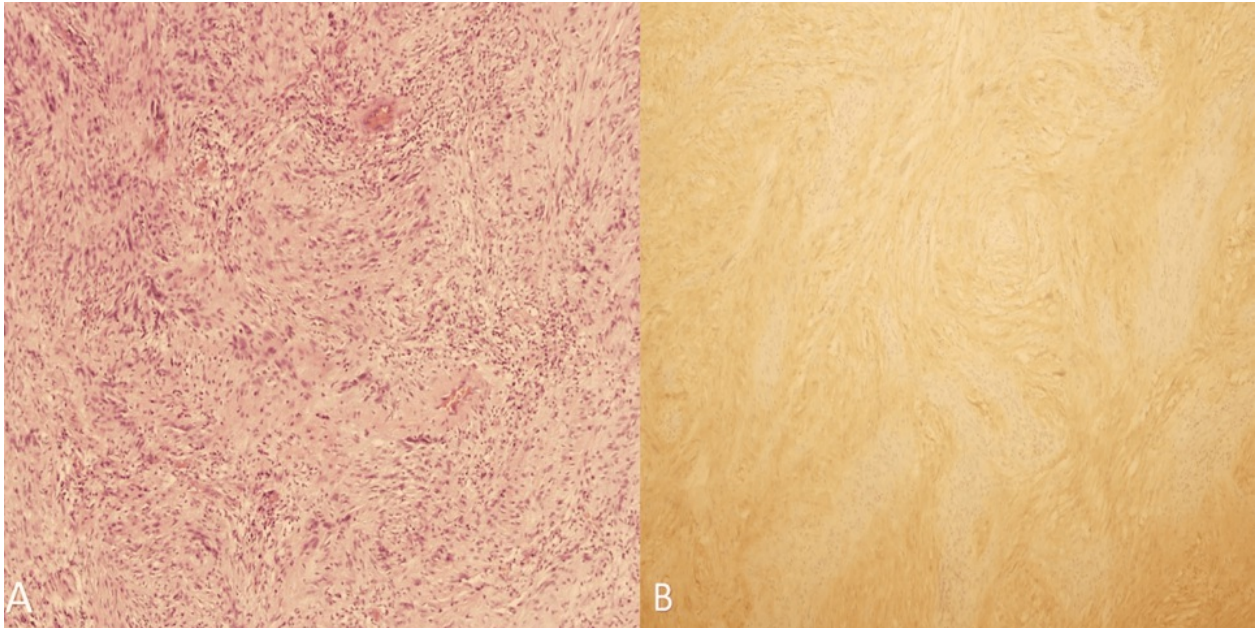


## Picture Prognosis



A 64-year-old male with a history of varicose veins, hypertension, and hyperlipidemia presented with severe central upper abdominal pain, nausea, vomiting, and a history of constipation and left lower quadrant pain. CT and MRI revealed a 5.5 cm rectal mass with adjacent lymph nodes. An exploratory laparotomy revealed a 10 x 5 cm exophytic bilobed mass in the distal sigmoid. The final histopathology report is shown in the picture. Diagnosis?

1. Gastrointestinal Stromal Tumor (GIST)
2. Carcinoid Tumor
3. Adenocarcinoma
4. Schwannoma



## Picture Prognosis

A 64-year-old male with a history of varicose veins, hypertension, and hyperlipidemia presented with severe central upper abdominal pain, nausea, vomiting, and a history of constipation and left lower quadrant pain. CT and MRI revealed a 5.5 cm rectal mass with adjacent lymph nodes. An exploratory laparotomy revealed a 10 x 5 cm exophytic bilobed mass in the distal sigmoid. The final histopathology report is shown in the picture. Diagnosis?

### **Answer: Schwannoma**

Schwannoma is a type of peripheral nerve sheath tumor that is often found in the head and neck. Schwannomas in the digestive system, particularly the colon and rectum, are exceptionally rare, and they are mostly non-malignant and asymptomatic although sometimes patients can present with symptoms similar to those observed in patients with other gastrointestinal tumors like abdominal pain, fullness, nausea, vomiting, and change in bowel habits.