Cureus
Part of SPRINGER NATURE

Open Access Original Article

Adnexal Torsion in a Tertiary Referral Center: Clinical Presentation, Surgical Management, and Challenges in Ovarian Preservation

Margarida Figueiredo [1], Marta Santos [2], Inês Tlemçani [2], Sílvia Serrano [2], Carla Nunes [2], Ana Luísa Ribeirinho [2]

1. Department of Gynecology and Obstetrics, Unidade Local de Saúde da Região de Aveiro, Aveiro, PRT 2. Department of Obstetrics, Gynecology, and Reproductive Medicine, Unidade Local de Saúde Santa Maria, Lisboa, PRT

Corresponding author: Margarida Figueiredo, margaridafigas95@gmail.com

Review began 10/27/2026
Review ended 11/19/2026
Published 11/23/2026

© **Copyright** 2026
Figueiredo et al. This is an open access article distributed under the terms of the Creative Commons Attribution License CC-BY 4.0., which permits unrestricted use, distribution, and reproduction in any medium, provided the original author and source are credited.

DOI: 10.7759/cureus.120146

Abstract

Background

Adnexal torsion is a gynecological emergency caused by rotation of the ovary and, frequently, the fallopian tube around their vascular pedicle, leading to compromised blood supply. Prompt recognition and surgical intervention are essential, as delayed diagnosis and treatment may result in loss of ovarian viability and impaired future fertility. Despite growing adoption of fertility-preserving surgical principles, ovarian preservation rates continue to vary widely across clinical settings, and contemporary data describing real-world management pathways, particularly at tertiary referral centers where case complexity and interhospital transfer are common, remain limited.

Objective

This study aimed to characterize the clinical presentation, diagnostic findings, surgical management, and ovarian preservation outcomes among patients undergoing surgical exploration for suspected adnexal torsion at a tertiary referral center, and to explore clinical and diagnostic characteristics associated with ovarian preservation.

Methods

This retrospective descriptive case series included all patients who underwent surgical exploration for suspected adnexal torsion at a tertiary referral center between January and December 2024. Demographic, clinical, imaging, surgical, and histopathological data were collected from electronic medical records. Exploratory comparisons between ovarian-preserving surgery and adnexectomy were performed using the Mann-Whitney U test for age and Fisher's exact test for categorical variables.

Results

Of 29 patients who underwent surgery for suspected adnexal torsion, 23 had intraoperative confirmation (79.3%). The mean age was 34.9 ± 8.5 years; all were premenopausal. Sudden-onset pelvic pain occurred in 15 of 23 (65.2%) and nausea and/or vomiting in 12 of 23 (52.2%). Ultrasound identified an adnexal mass in 22 of 23 (95.7%), while sonographic findings suggestive of torsion were present in nine of 23 (39.1%). Median admission-to-surgery time was 8.9 hours (range, 1.7-48). Laparoscopy was performed in 19 of 23 (82.6%). Ovarian preservation was achieved in 11 of 23 (47.8%), whereas 12 of 23 (52.2%) underwent adnexectomy. Patients undergoing ovarian preservation were younger than those undergoing adnexectomy (median age, 28 vs. 36.5 years; p=0.008). No other evaluated characteristic showed a statistically significant difference.

Conclusions

Ovarian preservation was achieved in fewer than half of patients with confirmed adnexal torsion. Younger age was associated with preservation in exploratory univariable analysis, but the small case series did not allow identification of independent predictors. Timely assessment, appropriate conservative management, and improved documentation of referral pathways and operative decision-making remain important.

Categories: Obstetrics/Gynecology
Keywords: adnexal torsion, fertility preservation, laparoscopy, ovarian preservation, pelvic pain

Introduction

Adnexal torsion is a time-sensitive gynecological emergency caused by the partial or complete rotation of the ovary, with or without the fallopian tube, around its supporting ligaments, resulting in progressive compromise of the adnexal vascular supply. Although relatively uncommon, with an estimated incidence of

approximately six cases per 100,000 women per year, it represents one of the most frequent gynecological surgical emergencies. The initial impairment of lymphatic and venous drainage leads to ovarian congestion and edema, while prolonged torsion may eventually compromise arterial inflow, resulting in ischemia, hemorrhagic infarction, and necrosis. Therefore, timely recognition and surgical intervention are crucial to preserve ovarian function and reproductive potential [1-4].

Although adnexal torsion can occur at any age, it predominantly affects women of reproductive age. The condition is particularly relevant in this population due to the potential impact of delayed treatment on future fertility. However, diagnosis remains challenging because clinical presentation is often nonspecific and overlaps with other causes of acute pelvic pain. A high index of suspicion is therefore required, particularly in patients presenting with sudden-onset pelvic pain, nausea and/or vomiting, or an associated adnexal mass [2-5].

The main predisposing factor for adnexal torsion is the presence of an ovarian or adnexal mass, which increases ovarian mobility and facilitates rotation around the vascular pedicle. More than 85% of patients with torsion have an associated adnexal lesion, most commonly benign ovarian cysts or neoplasms. Nevertheless, torsion may occur in normal ovaries, particularly in younger patients, and the absence of an identifiable mass does not exclude the diagnosis. Other recognized risk factors include previous torsion, pregnancy, and ovarian enlargement associated with assisted reproductive technologies [2-4].

The pathophysiological progression of adnexal torsion is determined by the extent and duration of vascular compromise. Due to the greater compressibility of veins and lymphatic vessels compared with arterial vessels, venous and lymphatic obstruction occurs initially, causing ovarian enlargement and stromal edema. Persistent torsion progressively compromises arterial perfusion, increasing the risk of ischemic injury and necrosis. This progression highlights the importance of minimizing delays between clinical suspicion and surgical intervention [2,4].

Ultrasonography is the first-line imaging modality in suspected adnexal torsion, although no single imaging finding is sufficiently sensitive to exclude the diagnosis. Common findings include ovarian enlargement, stromal edema, peripheral displacement of follicles, abnormal ovarian position, free pelvic fluid, and the presence of an adnexal mass. Doppler evaluation may provide additional information, but preserved ovarian blood flow does not rule out torsion due to dual ovarian vascular supply, collateral circulation, incomplete torsion, or intermittent torsion. Conversely, the whirlpool sign, reflecting twisting of the vascular pedicle, is considered one of the most specific ultrasonographic findings and may significantly increase diagnostic confidence [2,3,6,7].

Definitive diagnosis is established through direct visualization of a twisted adnexa during surgery. Laparoscopy is currently considered the preferred diagnostic and therapeutic approach whenever feasible, allowing confirmation of the diagnosis, detorsion, and conservative management with minimal surgical morbidity. Historically, the presence of a dark or enlarged ovary frequently led to oophorectomy due to concerns regarding necrosis and thromboembolic complications. However, current evidence supports ovarian preservation whenever malignancy is not suspected, as macroscopic discoloration often reflects reversible venous congestion rather than irreversible tissue damage. Detorsion, with or without cystectomy, is therefore recommended whenever technically possible [3,4,8,9].

Despite advances in diagnostic imaging and increasing awareness of conservative surgical management, adnexal torsion remains associated with significant variability in clinical practice, particularly regarding timing of surgery and the decision to preserve ovarian tissue. The rarity of the condition, together with the heterogeneity of published studies, limits the availability of robust contemporary data regarding clinical presentation, management strategies, and factors influencing ovarian salvage, particularly in tertiary referral settings [2,3,8].

The primary aim of this study was to characterize the demographic, clinical, imaging, surgical, and histopathological features of patients with suspected adnexal torsion managed at a tertiary referral center, with particular emphasis on surgical management and ovarian preservation outcomes. As a secondary exploratory objective, we sought to assess whether selected demographic, clinical, and diagnostic characteristics were associated with ovarian preservation versus adnexectomy among patients with surgically confirmed adnexal torsion. Given the retrospective design and limited sample size, these comparisons were intended to generate hypotheses rather than identify independent predictors of ovarian preservation.

Materials And Methods

Study design and setting

A retrospective descriptive case series was conducted at Hospital de Santa Maria, Unidade Local de Saúde de Santa Maria, Lisbon, Portugal, a tertiary referral center, including all consecutive patients who underwent surgical exploration for suspected adnexal torsion between January 1 and December 31, 2024. The study was designed and reported according to the Strengthening the Reporting of Observational Studies in

Epidemiology (STROBE) guidelines [10].

Study population

All consecutive patients who underwent surgical exploration because of clinical and/or radiological suspicion of adnexal torsion at Hospital de Santa Maria between January 1 and December 31, 2024, were eligible for inclusion, regardless of age or surgical approach. Patients were identified retrospectively through institutional surgical databases and electronic medical records. Surgical reports were reviewed to verify eligibility and confirm the diagnosis.

Adnexal torsion was considered surgically confirmed when intraoperative findings demonstrated rotation of the ovary and/or fallopian tube around its vascular pedicle. Patients in whom adnexal torsion was not confirmed during surgery were retained in the initial diagnostic population but excluded from analyses of clinical characteristics and surgical outcomes among confirmed cases. The final analytic sample comprised 23 patients with surgically confirmed adnexal torsion out of 29 patients undergoing surgical exploration for suspected torsion.

Data collection

Demographic, clinical, laboratory, imaging, surgical, and histopathological data were retrospectively collected from electronic medical records using a standardized data extraction form during the first quarter of 2025. Baseline characteristics included patient age and relevant clinical history. Clinical presentation was assessed according to presenting symptoms, including pelvic or abdominal pain, nausea and/or vomiting, and other associated symptoms.

Diagnostic evaluation included preoperative ultrasonographic findings, including the presence of an adnexal mass, ovarian enlargement, stromal edema, peripheral follicles, abnormal ovarian position, Doppler vascular findings, and other sonographic features suggestive of torsion. Laboratory parameters, including inflammatory markers when available, were also recorded. Data were retrospectively extracted from electronic medical records using a standardized data collection form. Information was obtained from the available clinical documentation, including preoperative assessments, imaging reports, operative records, and histopathological reports when available. Variables were recorded according to the information documented in the medical records. Missing or uncertain observations were not imputed and were excluded from the corresponding variable-specific analyses.

Surgical management and outcomes

Surgical variables included the time interval from hospital admission to surgery, surgical approach (laparoscopy or laparotomy), intraoperative findings, type of surgical procedure performed, and histopathological results. Surgical management was categorized as conservative treatment (detorsion with or without cystectomy) or adnexectomy.

The primary outcome was the ovarian preservation rate among patients with confirmed adnexal torsion, defined as the proportion of patients in whom ovarian tissue was preserved. Secondary outcomes included clinical presentation, diagnostic findings, surgical approach, and factors potentially associated with ovarian preservation.

Statistical analysis

Descriptive statistics were used to summarize demographic, clinical, imaging, and surgical characteristics. Continuous variables were expressed as mean ± standard deviation (SD) or median and interquartile range (IQR), as appropriate, and categorical variables as absolute frequencies and percentages.

Exploratory univariable comparisons were performed between patients undergoing ovarian-preserving surgery (n=11) and those undergoing adnexectomy (n=12). The variables assessed included age, first episode of adnexal torsion, sudden-onset pelvic pain, nausea and/or vomiting, presence of an adnexal mass on ultrasonography, sonographic findings suggestive of torsion, and elevated C-reactive protein levels.

The Mann-Whitney U test was used to compare age between groups, while Fisher's exact test was applied to categorical variables because of the small sample size. All statistical tests were two-sided, and p-values below 0.05 were considered statistically significant. The Mann-Whitney U statistic and odds ratios for categorical comparisons were reported alongside the corresponding p-values.

Missing or uncertain observations were excluded from the relevant variable-specific comparisons without imputation, and evaluable denominators were reported when they differed from the total group sizes.

Given the limited sample size and number of observations, no multivariable regression analysis or adjustment for potential confounding factors was performed. Therefore, the analyses were considered exploratory and hypothesis-generating, and the observed associations should not be interpreted as

independent predictors or causal relationships.

Admission-to-surgery time was not compared between treatment groups because individual-level interval data were incomplete.

Ethical approval

This retrospective study used anonymized data extracted from the hospital clinical database. According to the Institutional Review Board (Ethics Committee) of Hospital Santa Maria - Lisboa, formal ethical approval and informed consent were not required because no identifiable patient information was collected or reported.

Results

Study population and baseline characteristics

During the study period, 29 women underwent surgical exploration for suspected adnexal torsion. Intraoperative confirmation of adnexal torsion was established in 23 patients (79.3%), who constituted the final study population. The mean age of patients with confirmed torsion was 34.9 ± 8.5 years (range, 21-50 years), and all patients were premenopausal.

Clinical presentation

The most common presenting symptom was sudden-onset pelvic pain, followed by nausea and/or vomiting, as shown in Table *1*.

Presenting symptom	n	%
Sudden-onset pelvic pain	15	65.2
Nausea and/or vomiting	12	52.2

TABLE 1: Presenting symptoms of patients with surgically confirmed adnexal torsion (n=23)

Imaging findings

Preoperative ultrasonography identified an adnexal mass in 22 of 23 patients (95.7%). Sonographic findings considered suggestive of torsion were recorded in nine of 23 patients (39.1%); two entries were missing or uncertain for the between-group comparison (six of 10 vs. three of 11). The available analytic dataset did not consistently distinguish ovarian enlargement, stromal edema, peripheral follicles, abnormal position, and Doppler findings, so their individual frequencies cannot be reported.

Laboratory findings

Elevated serum C-reactive protein (CRP) was recorded in seven of 23 patients (30.4%); CRP status was unavailable in one patient (as shown in Table *2*). Other laboratory markers were not consistently captured in the available analytic dataset.

Imaging and laboratory finding	n	%
Adnexal mass identified on ultrasound	22	95.7
Ultrasound findings suggestive of torsion	9	39.1
Elevated C-reactive protein	7	30.4

TABLE 2: Preoperative imaging and laboratory findings in patients with confirmed adnexal torsion (n=23)

Timing of surgical intervention

The time intervals from hospital admission to surgery, from first medical assessment to surgery, and from the decision for surgical intervention to surgery are summarized in Table *3*. The median interval from

hospital admission to surgery was 8 hours and 54 minutes. The mean interval was 12.1 hours, influenced by a single case with a 48-hour delay. The mean interval from first medical assessment to surgery was 10.6 hours, with a median of 5.9 hours. Following the decision for surgical intervention, the median time to surgery was 2.5 hours (mean, 2.9 hours).

Time interval	Mean (hours)	Median (hours)	Range (hours)
Hospital admission to surgery	12.1	8.9	1.7-48
First medical assessment to surgery	10.6	5.9	0.97-47.3
Surgical decision to surgery	2.9	2.5	0.22-6

TABLE 3: Timing of diagnosis and surgical intervention

Surgical management and outcomes

Laparoscopy was performed in 19 of the 23 patients with confirmed adnexal torsion (82.6%). Three patients underwent primary laparotomy, and one required conversion to laparotomy. These surgical approaches were selected because of large adnexal masses, predominantly solid lesions, and/or suspicion of malignancy based on the preoperative assessment, as summarized in Figure *1*.

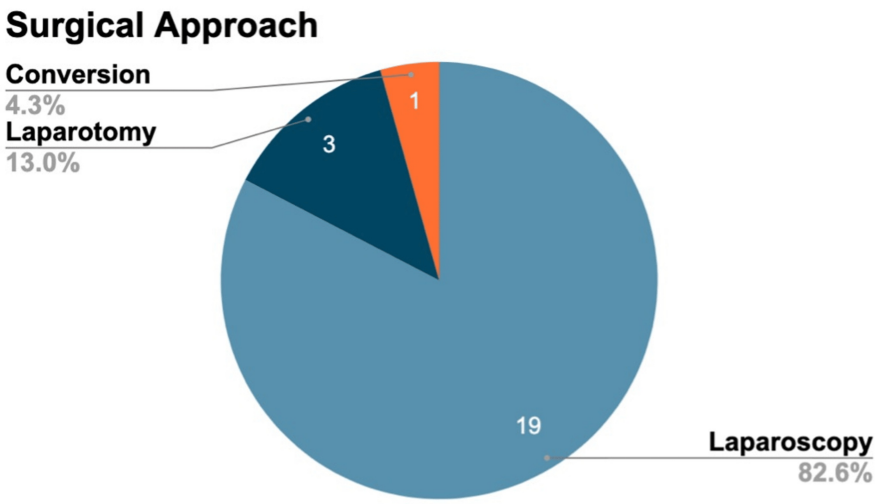

FIGURE 1: Distribution of surgical approaches (laparotomy vs. laparoscopy) among the study population.

Conservative surgical management, consisting of adnexal detorsion with or without cystectomy, was performed in 11 patients (47.8%). Adnexectomy was required in 12 patients (52.2%). No major intraoperative complications were recorded. One case required conversion from laparoscopy to laparotomy, as summarized in Figure *2*.

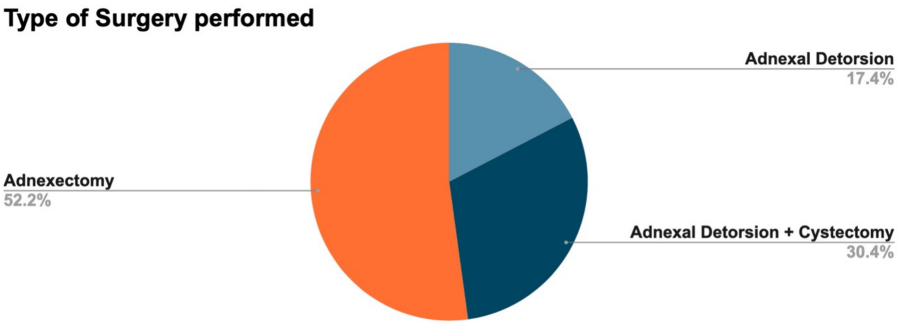

FIGURE 2: Type of surgery performed among the study population.

In exploratory univariable comparisons between ovarian preservation and adnexectomy (Table 4), patients undergoing ovarian preservation were younger (median age, 28 years (IQR, 24-35) vs. 36.5 years (IQR, 33.8-46); U=22.5; p=0.008). No statistically significant differences were detected in first episode, sudden-onset pain, nausea and/or vomiting, adnexal mass, or sonographic findings suggestive of torsion. Elevated CRP was recorded in one of 10 (10.0%) versus six of 12 (50.0%) patients, respectively (p=0.074). These exploratory comparisons do not establish independent predictors of treatment choice.

Variable	Preservation (n=11), n	Preservation, %	Adnexectomy (n=12), n	Adnexectomy, %	Test statistic	p-value
Age, median, years	28	-	36.5	-	U = 22.5	0.008
Age, IQR, years	24-35	-	33.8–46	-	-	-
First episode	9	81.8	11	91.7	OR = 0.41	0.590
Sudden-onset pain	8	72.7	7	58.3	OR = 1.90	0.667
Sonographic findings suggestive of torsion	6/10	60.0	3/11	27.3	OR = 4.00	0.198
Nausea and/or vomiting	5	45.5	7	58.3	OR = 0.60	0.684
Elevated CRP	1/10	10.0	6/12	50.0	OR = 0.11	0.074
Adnexal mass	10	90.9	12	100	OR = 0.00	0.478

TABLE 4: Exploratory comparison of clinical and diagnostic characteristics according to ovarian preservation

IQR, interquartile range; CRP, C-reactive protein. Fisher's exact test was used for categorical variables and the Mann-Whitney U test for age. Percentages for sonographic findings and CRP use evaluable denominators because of missing or uncertain data.

Discussion

This study provides a contemporary overview of the clinical presentation, diagnostic evaluation, surgical management, and ovarian preservation of patients with adnexal torsion managed at a tertiary referral center. Four principal findings emerged. First, adnexal torsion predominantly affected premenopausal women presenting with acute pelvic pain, gastrointestinal symptoms, and an associated adnexal mass. Second, although laparoscopy was the preferred surgical approach, ovarian preservation was achieved in fewer than half of patients. Third, younger age was associated with ovarian preservation in an exploratory univariable analysis. Fourth, the relatively low ovarian preservation rate may reflect referral pathways and the complexity of cases managed at a tertiary referral center, although these factors could not be formally tested.

The clinical characteristics observed in this series are consistent with previous reports describing adnexal torsion as a condition that primarily affects women of reproductive age and typically presents with sudden-onset pelvic pain accompanied by nausea and/or vomiting [1,2,4,5]. An adnexal mass was identified in almost all confirmed cases, reinforcing its role as the principal predisposing factor for torsion [2,4]. However,

clinicians should recognize that torsion may also occur in morphologically normal ovaries, particularly in younger patients, and therefore the absence of an adnexal mass should not exclude the diagnosis when clinical suspicion remains high [3].

Preoperative ultrasonography remains the imaging modality of choice in patients with suspected adnexal torsion [6]. In this study, sonographic findings suggestive of torsion were identified in approximately 40% of patients, consistent with the recognized limitations of ultrasound [6,7]. Imaging findings vary according to the degree and duration of vascular compromise, and preserved Doppler flow does not reliably exclude torsion [6,7]. Consequently, ultrasonographic findings should always be interpreted alongside the clinical presentation, and the absence of classical imaging features should not delay surgical exploration when clinical suspicion is high.

Exploratory comparison of the surgical groups identified an association between younger age and ovarian preservation (median 28 vs. 36.5 years; U=22.5; p=0.008). Age may be related to the underlying adnexal pathology, concern about malignancy, fertility considerations, or intraoperative decision-making; these potential explanations could not be tested in this small case series. The analysis was univariable and should not be interpreted as identifying an independent predictor. Other measured clinical and sonographic variables were not significantly different between groups; lack of significance does not establish equivalence.

Ovarian preservation was achieved in 11 of 23 patients (47.8%), lower than rates described in some contemporary series [11]. This difference warrants careful interpretation because patient selection, referral complexity, adnexal pathology, and operative indications may vary across studies. This tertiary referral center received patients from other institutions, so the recorded admission-to-surgery interval did not capture all pre-referral delays or the true duration of symptoms. Large or solid masses and concern for malignancy also influenced the surgical approach in some cases. The available dataset does not permit a reliable case-by-case attribution of why adnexectomy was chosen; therefore, the preservation rate should not be attributed solely to delayed intervention or presumed ovarian nonviability. A structured prospective record of symptom onset, transfer times, intraoperative appearance, mass characteristics, and reasons for adnexectomy would help clarify these decisions.

Beyond surgical technique, these findings emphasize that time remains one of the few modifiable determinants of ovarian salvage [12]. Although surgery was generally performed promptly once the decision to operate had been made, delays frequently occurred before surgical indication was established or during interhospital transfer [12]. These observations highlight the importance of maintaining a high index of suspicion, optimizing referral pathways, and ensuring timely access to emergency minimally invasive surgery. Improvements in these processes may increase ovarian preservation, particularly among women of reproductive age. Finally, reliable intraoperative assessment of ovarian viability remains challenging, highlighting the need for more objective methods to guide surgical decision-making [13].

This study has several limitations that should be acknowledged. First, its retrospective, single-center design and small sample size limit statistical power and the generalizability of the findings. Although consecutive surgically managed patients were included, the study was conducted at a tertiary referral center receiving patients from other institutions, introducing the potential for referral bias. Consequently, the study population may overrepresent patients with complex adnexal pathology or more challenging surgical presentations compared with those managed in non-referral settings.

Second, selection bias cannot be excluded, as the study included only patients undergoing surgical exploration for suspected adnexal torsion. Patients managed without surgery were not captured, and those without intraoperative confirmation of torsion were excluded from the analysis of ovarian preservation outcomes. Therefore, the findings may not be representative of all patients presenting with suspected adnexal torsion.

Third, the limited sample size and number of observations precluded reliable multivariable adjustment for potential confounding factors. The comparisons between ovarian preservation and adnexectomy were exploratory and unadjusted; consequently, the observed association between younger age and ovarian preservation should not be interpreted as an independent predictor or a causal relationship.

Additionally, missing or uncertain observations reduced the evaluable denominators for some variables. The recorded admission-to-surgery interval did not capture the complete duration of symptoms or delays occurring before transfer from referring institutions, and incomplete individual-level timing data prevented reliable comparisons between treatment groups. Possible inaccuracies in surgical coding may also have resulted in under-ascertainment of eligible cases. Finally, representative ultrasonographic and intraoperative images were unavailable for publication, and detailed frequencies of individual sonographic findings and histopathological diagnoses could not be reliably reconstructed from the available analytic dataset.

Despite these limitations, the study provides a descriptive overview of clinical presentation, diagnostic

findings, and surgical management of adnexal torsion in a tertiary referral setting, contributing real-world data that may inform future multicenter investigations.

Conclusions

This retrospective case series highlights the variability in the clinical presentation and diagnostic findings of adnexal torsion, reinforcing the importance of maintaining a high index of clinical suspicion. Although ultrasonography is an essential component of the diagnostic assessment, the absence of specific sonographic findings should not exclude adnexal torsion when clinical suspicion remains high.

Ovarian-preserving surgery was performed in a substantial proportion of patients, and younger age was associated with ovarian preservation in exploratory univariable analysis. However, this finding should not be interpreted as an independent predictor of surgical management.

These findings support the importance of individualized surgical decision-making and consideration of ovarian preservation whenever clinically appropriate. Given the retrospective design and incomplete information regarding pre-referral intervals and factors influencing treatment decisions, this study cannot establish whether referral delays affected surgical outcomes. Larger prospective multicenter studies are needed to investigate the relationship between referral pathways, treatment timing, surgical decision-making, and ovarian preservation.

Additional Information

Author Contributions

All authors have reviewed the final version to be published and agreed to be accountable for all aspects of the work.

Concept and design: Margarida Figueiredo, Marta Santos, Inês Tlemçani, Sílvia Serrano, Carla Nunes, Ana Luísa Ribeirinho

Acquisition, analysis, or interpretation of data: Margarida Figueiredo, Marta Santos, Inês Tlemçani, Sílvia Serrano

Drafting of the manuscript: Margarida Figueiredo

Critical review of the manuscript for important intellectual content: Margarida Figueiredo, Marta Santos, Inês Tlemçani, Sílvia Serrano, Carla Nunes, Ana Luísa Ribeirinho

Supervision: Carla Nunes, Ana Luísa Ribeirinho

Disclosures

Human subjects: Informed consent for treatment and open access publication was obtained or waived by all participants in this study. **Animal subjects:** All authors have confirmed that this study did not involve animal subjects or tissue. **Conflicts of interest:** In compliance with the ICMJE uniform disclosure form, all authors declare the following: **Payment/services info:** All authors have declared that no financial support was received from any organization for the submitted work. **Financial relationships:** All authors have declared that they have no financial relationships at present or within the previous three years with any organizations that might have an interest in the submitted work. **Other relationships:** All authors have declared that there are no other relationships or activities that could appear to have influenced the submitted work.

Acknowledgements

The authors would like to thank the Department of Obstetrics and Gynecology of Santa Maria Hospital for its support and contribution to the development of this study.

References

1. Houry D, Abbott JT: Ovarian torsion: a fifteen-year review . Ann Emerg Med. 2001, 38:156-9. 10.1067/mem.2001.114303
2. Huchon C, Fauconnier A: Adnexal torsion: a literature review . Eur J Obstet Gynecol Reprod Biol. 2010, 150:8-12. 10.1016/j.ejogrb.2010.02.006
3. Adnexal torsion in adolescents: ACOG committee opinion no. 783 . Obstet Gynecol. 2019, 134:e56-63. 10.1097/AOG.0000000000003373
4. Oelsner G, Shashar D: Adnexal torsion. Clin Obstet Gynecol. 2006, 49:459-63. 10.1097/00003081-200609000-00006
5. White M, Stella J: Ovarian torsion: 10-year perspective . Emerg Med Australas. 2005, 17:231-7. 10.1111/j.1742-6723.2005.00728.x

6. Chang HC, Bhatt S, Dogra VS: Pearls and pitfalls in diagnosis of ovarian torsion . Radiographics. 2008, 28:1355-68. 10.1148/rg.285075130
7. Vijayaraghavan SB: Sonographic whirlpool sign in ovarian torsion . J Ultrasound Med. 2004, 23:1643-9; quiz 1650-1. 10.7863/jum.2004.23.12.1643
8. Oelsner G, Cohen SB, Soriano D, Admon D, Mashiach S, Carp H: Minimal surgery for the twisted ischaemic adnexa can preserve ovarian function. Hum Reprod. 2003, 18:2599-602. 10.1093/humrep/deg498
9. Novoa M, Friedman J, Mayrink M: Ovarian torsion: can we save the ovary? . Arch Gynecol Obstet. 2021, 304:191-5. 10.1007/s00404-021-06008-8
10. von Elm E, Altman DG, Egger M, Pocock SJ, Gøtzsche PC, Vandenbroucke JP; STROBE Initiative: The Strengthening the Reporting of Observational Studies in Epidemiology (STROBE) statement: guidelines for reporting observational studies. PLoS Med. 2007, 4:296. 10.1371/journal.pmed.0040296
11. Mandelbaum RS, Smith MB, Violette CJ, et al.: Conservative surgery for ovarian torsion in young women: perioperative complications and national trends. BJOG. 2020, 127:957-65. 10.1111/1471-0528.16179
12. Adams K, Ballard E, Amoako A, Khalil A, Baartz D, Chu K, Tanaka K: When is it too late? Ovarian preservation and duration of symptoms in ovarian torsion. J Obstet Gynaecol. 2022, 42:675-9. 10.1080/01443615.2021.1929114
13. Nicholson K, Urh A, Demertzis K, et al.: Intraoperative indocyanine green dye use in ovarian torsion: a feasibility study. J Minim Invasive Gynecol. 2022, 29:738-42. 10.1016/j.jmig.2022.01.008