Cureus
Part of SPRINGER NATURE

Open Access Original Article

Off-Label Intravitreal Adalimumab in Extensive Macular Atrophy With Pseudodrusen-Like Appearance (EMAP): Ocular Safety and Exploratory Outcomes in a Prospective Single-Arm Study

Rubens C. Siqueira [1], Tainara S. Pinho [2], Thais Q. Brito [3], Cinara C. Brandao [2]

1. Postgraduate Department, Faculdade de Medicina de São José do Rio Preto (FAMERP), São José do Rio Preto, BRA 2. Immunogenetics Laboratory, Department of Dermatological, Infectious, and Parasitic Diseases, Faculdade de Medicina de São José do Rio Preto (FAMERP), São José do Rio Preto, BRA 3. Retinology, Rubens Siqueira Research Center, São José do Rio Preto, BRA

Corresponding author: Rubens C. Siqueira, siqueiraretina@gmail.com

Review began 10/30/2026
Review ended 11/20/2026
Published 11/24/2026

© **Copyright** 2026
Siqueira et al. This is an open access article distributed under the terms of the Creative Commons Attribution License CC-BY 4.0., which permits unrestricted use, distribution, and reproduction in any medium, provided the original author and source are credited.

DOI: 10.7759/cureus.120197

Abstract

Background/objectives: Extensive macular atrophy with pseudodrusen-like appearance (EMAP) is a rare, rapidly progressive degenerative macular disease with no established disease-modifying therapy. We evaluated the short-term ocular safety and exploratory functional outcomes of off-label intravitreal adalimumab in patients with EMAP. The intravitreal route and EMAP indication are not approved uses of adalimumab. The dose and regimen (2 mg/0.05 mL at baseline (M0), month 2 (M2), and month 4 (M4)) were selected based on our previously published prospective pilot experience in retinitis pigmentosa using the same regimen.

Methods: This prospective, exploratory, single-arm, investigator-initiated clinical study included patients with clinically diagnosed EMAP who received three intravitreal injections of adalimumab (2 mg/0.05 mL) at M0, M2, and M4, with follow-up at month 6. The protocol received ethics approval before enrollment and study intervention. Enrollment and treatment began in August 2025. The study was subsequently registered at ClinicalTrials.gov and remains ongoing for longer-term follow-up; the present report describes the completed six-month analysis. Outcomes included best-corrected visual acuity (BCVA, logMAR), automated perimetry, optical coherence tomography (OCT), and full-field electroretinography (ERG).

Results: Paired BCVA was available for 32 eyes from 16 of the 17 unique participants identified in the reconciled worksheet. Mean BCVA was 1.106 ± 0.714 logMAR at M0 and 0.991 ± 0.439 at month 6. The finite-cluster-corrected GEE yielded $p = 0.221$. No serious adverse events occurred during follow-up.

Conclusions: The analysis did not detect a statistically significant change in BCVA. The small cohort, six-month observation period, and uncontrolled design limit conclusions about ocular safety and preclude inference about functional preservation or disease modification.

Categories: Therapeutics, Pharmacology, Ophthalmology
Keywords: degenerative macular disease, emap, extensive macular atrophy with pseudodrusen-like appearance, intravitreal adalimumab, off-label use, optical coherence tomography, real-world evidence, retinal para-inflammation, tnf-α inhibition, visual field preservation

Introduction

Extensive macular atrophy with pseudodrusen-like appearance (EMAP) is an emerging and clinically aggressive macular degenerative phenotype characterized by early-onset bilateral atrophy, rapid progression, and severe functional impairment [1-4]. Unlike age-related macular degeneration (AMD) or inherited retinal dystrophies, EMAP often affects relatively younger individuals and leads to accelerated loss of both central and peripheral visual function [1-5]. Despite its distinct clinical and multimodal imaging features, EMAP remains an underrecognized condition with no established disease-modifying therapy, representing a critical unmet need in contemporary retinal practice [5-9]. Current management is largely limited to observation and supportive care, including monitoring for complications such as macular neovascularization, which may occur in a subset of patients during disease progression [10-14].

From a structural and functional perspective, EMAP is characterized by widespread outer retinal and retinal pigment epithelium (RPE) atrophy, early disruption of the ellipsoid zone (EZ), and progressive reduction in retinal sensitivity on perimetry and microperimetry [2-6,11]. Multimodal imaging studies, including OCT, fundus autofluorescence (FAF), and OCT angiography (OCTA), have demonstrated profound alterations of the outer retina and choriocapillaris [6-10]. Natural-history studies consistently document progressive

enlargement of atrophic lesions and functional decline in EMAP [4-6,11-13].

Although EMAP shares phenotypic features with advanced atrophic macular diseases, increasing evidence suggests that it represents a distinct degenerative spectrum with overlapping features of age-related and inherited retinal disorders [4,5,8]. Chronic para-inflammatory and immune-mediated mechanisms, including microglial activation, oxidative stress, and complement dysregulation, have been implicated in outer retinal degeneration [7,8,15,16].

Within this inflammatory framework, TNF-α is a pro-inflammatory cytokine capable of amplifying inflammatory signaling and contributing to photoreceptor injury in experimental retinal degeneration. Experimental studies have shown that TNF-α blockade with adalimumab can reduce photoreceptor cell death and delay retinal degeneration in animal models, providing a biological rationale for investigating this pathway in degenerative retinal disease [17-27].

Adalimumab, a fully human monoclonal antibody against TNF-α, is approved for systemic administration in several immune-mediated diseases; however, intravitreal administration and treatment of EMAP are off-label uses. Preclinical studies have evaluated retinal toxicity after intravitreal exposure [18-21], and early clinical experience with intravitreal TNF-α inhibitors in non-infectious uveitis and intraocular inflammation has provided preliminary ocular tolerability data [15,22,24,25-29]. Importantly, our group subsequently published a prospective pilot study in retinitis pigmentosa using intravitreal adalimumab at 2 mg/0.05 mL at baseline (M0), month 2 (M2), and month 4 (M4), with follow-up at month 6; that study found the regimen feasible and did not identify serious ocular adverse events over the observation period [30]. This prior clinical experience provided the practical dose and schedule used in the present EMAP cohort; it does not establish efficacy or safety of adalimumab for EMAP. A recent systematic review and meta-analysis further consolidated the clinical and multimodal imaging spectrum of EMAP, reinforcing current diagnostic and phenotypic criteria across cohorts [28]. Additional observational data have linked EMAP to systemic inflammatory conditions, particularly rheumatic disease, lending epidemiological support to investigation of immune-mediated mechanisms [15,29]. Nevertheless, TNF-α inhibition in EMAP remains investigational, and the present report concerns off-label treatment.

Therefore, the present prospective exploratory study aimed primarily to characterize the short-term ocular safety and tolerability of off-label intravitreal adalimumab in patients with EMAP. Functional, structural, and electrophysiological changes were evaluated as exploratory outcomes and were not intended to establish therapeutic efficacy or disease modification. The dose and schedule were based on our previously published prospective retinitis pigmentosa pilot study using the same intravitreal regimen [30].

A preprint version of this manuscript reporting the six-month analysis was previously posted to the Research Square preprint server on February 18, 2026 [23]. The prospective study remains ongoing for longer-term follow-up.

Materials And Methods

Study design, ethics, and participants

This was a prospective, exploratory, single-arm, investigator-initiated clinical study conducted at the Rubens Siqueira Research Center, São José do Rio Preto, São Paulo, Brazil. The study was initiated on August 1, 2025, and remains ongoing, with an estimated overall Study Completion Date of August 1, 2027. The registered Primary Completion Date is February 2026. The present reanalysis uses the available M0 and month 6 records in the EMAP group of Planilha2 from the source workbook. The investigator confirmed that the follow-up interval corresponded to the registered six-month assessment. Participants continue prospective follow-up under the ethics-approved protocol for longer-term assessments, including subsequent analyses beyond month 6. The study protocol was approved by the Brazilian National Research Ethics Committee (CONEP; CAAE 86943125.0.0000.0317) on July 10, 2025, before participant enrollment and initiation of study intervention. Enrollment and treatment began in August 2025. The trial registration was subsequently first submitted to ClinicalTrials.gov on November 30, 2025 (NCT07348588; ADARET); met ClinicalTrials.gov quality-control criteria on January 8, 2026; and was publicly posted on January 16, 2026. Enrollment and treatment preceded initial submission and public posting of the trial record. No changes were made to the approved protocol or its outcome measures before initial submission or first public posting. Intravitreal adalimumab was used off-label because neither the intravitreal route nor EMAP is an approved indication. The study was conducted in accordance with the Declaration of Helsinki and Good Clinical Practice principles.

Eligible participants were adults aged ⩾18 years with a clinical diagnosis of EMAP confirmed by multimodal retinal imaging, demonstrating widespread outer retinal and RPE atrophy, pseudodrusen-like deposits, and peripheral retinal involvement. The diagnosis was established by experienced retina specialists according to currently accepted phenotypic criteria for EMAP, integrating fundus examination with multimodal imaging (color fundus photography, fundus autofluorescence, and spectral-domain OCT), and, where available, full-field electroretinography. Differential diagnoses, in particular inherited retinal dystrophies as well as age-related macular degeneration and other atrophic maculopathies, were systematically considered and

excluded on clinical, imaging, and electrophysiological grounds. Genetic testing was not routinely performed, and the exclusion of inherited retinal dystrophies was therefore based on clinical, multimodal imaging, and electrophysiological assessment by retina specialists rather than on molecular confirmation. Inclusion criteria required the availability of paired best-corrected visual acuity (BCVA) measurements expressed in logMAR at M0 and after treatment. When available, paired automated visual field data, including mean deviation (MD), pattern standard deviation (PSD), and field preservation deviation index (FPDI), were also analyzed.

Eyes were excluded if there was evidence of concurrent retinal pathology capable of confounding functional outcomes, such as neovascular AMD, diabetic macular edema, or retinal vascular occlusion. Additional exclusion criteria included active or recent ocular infection or inflammation, significant media opacity precluding reliable imaging or functional testing, and intraocular surgery within three months prior to M0, with the exception of uncomplicated phacoemulsification. When both eyes of a patient met eligibility criteria, each eye was included and analyzed independently, with intra-subject correlation addressed in the "Statistical analysis" section.

Intervention

All included eyes received off-label intravitreal adalimumab (Humira®, AbbVie Inc., North Chicago, IL, USA) at a dose of 2 mg/0.05 mL, administered via pars plana injection using standard sterile technique. The intravitreal route and the use of adalimumab for EMAP are off-label. The 2 mg/0.05 mL dose and three-dose schedule were selected from our prior clinical research experience in retinitis pigmentosa, subsequently published as a prospective pilot study, in which the same intravitreal dose was administered at M0, M2, and M4, with follow-up to month 6 and without serious ocular adverse events identified during the study period [30]. This prior RP experience was used as a dose-selection and feasibility precedent and was not assumed to demonstrate efficacy or safety in EMAP. Procedures in the present cohort were performed under topical anesthesia with 5% povidone-iodine antisepsis, with an injection distance of 3.5 to 4.0 mm from the limbus, adjusted according to lens status. Patients underwent safety evaluations 7-14 days after each injection, as well as at scheduled follow-up visits. No additional intraocular therapies were administered during the observation period.

Systemic safety assessment

Prior to intravitreal administration of adalimumab, all patients underwent clinical screening to exclude active systemic or ocular infection. Particular attention was given to signs or history suggestive of infectious diseases, including tuberculosis or other chronic infections. Patients with known active infection or uncontrolled systemic inflammatory or infectious conditions were not eligible for treatment. None of the included patients were receiving systemic immunosuppressive therapy at the time of intravitreal injection, and patients with significant systemic immunocompromise were excluded based on clinical evaluation. During follow-up, patients were clinically monitored for potential systemic adverse events related to TNF-α inhibition. No systemic adverse events or complications attributable to intravitreal adalimumab were identified during the study period.

Clinical assessments and data collection

BCVA was assessed using Snellen charts and converted to logMAR for statistical analysis. Measurements were obtained at M0, prior to the first intravitreal injection, and at the post-treatment follow-up, defined as the first available visit after completion of the three-dose injection series. Only eyes with complete paired logMAR data were included in BCVA analyses.

Automated static perimetry was performed using the iCare COMPASS system (iCare, Vantaa, Finland), employing either a 10-2 or 24-2 testing strategy depending on disease severity and fixation stability. Three functional indices were extracted: MD, PSD, and FPDI. Visual field data were included only when both M0 and post-treatment measurements were available and considered reliable. OCT was performed using spectral-domain instruments, with qualitative evaluation of ellipsoid zone integrity and quantitative measurement of central macular thickness. Full-field ERG was performed according to the International Society for Clinical Electrophysiology of Vision (ISCEV) Standard for full-field clinical electroretinography, which specifies minimum requirements for stimulus conditions, recording procedures, response measurement, and reporting [17]. The light-adapted 30-Hz flicker response was used as the principal cone-mediated readout. Reliable recordings were obtainable only in a minority of eyes because of advanced disease and fixation limitations; paired analyses were restricted to eyes with measurable responses.

A standardized prospective data collection framework was used for the predefined clinical assessments. Right- and left-eye measurements were recorded separately. Non-numeric or non-measurable entries, such as “not performed” or “not measurable,” were excluded from the corresponding quantitative analyses. Because advanced EMAP can limit fixation and test reliability, the number of eyes contributing to individual secondary outcomes varied according to the availability of interpretable paired examinations.

Outcome measures

The primary outcome measure was the change in BCVA, expressed as ΔlogMAR (post-treatment minus M0). Secondary outcomes included changes in automated perimetry parameters (ΔMD, ΔPSD, and ΔFPDI), categorical analysis of visual acuity outcomes (proportion of eyes achieving a clinically meaningful improvement (⩾0.2 logMAR gain) and proportion demonstrating worsening (⩾0.2 logMAR loss)), and qualitative assessment of OCT and ERG stability. Safety outcomes included the occurrence of any procedure-related serious adverse event, signs of intraocular inflammation, endophthalmitis, sustained intraocular pressure elevation, and structural or electrophysiological evidence of retinal toxicity.

Statistical analysis

All statistical analyses were performed using Python (NumPy 1.26, Pandas 2.2, SciPy 1.13, and statsmodels 0.14). The distribution of paired differences was assessed using the Shapiro-Wilk test. Because data deviated from normality, Wilcoxon signed-rank tests were applied for paired comparisons. Continuous variables are reported as mean ± standard deviation, median, and 95% confidence intervals, as appropriate. Categorical outcomes are reported as counts and percentages. A two-sided p-value < 0.05 was considered statistically significant. Given the exploratory pilot design and rarity of EMAP, no formal a priori sample size calculation was performed; the sample comprised eligible participants enrolled during the study period.

A Gaussian identity-link GEE with an intercept-only mean model was recalculated for the eye-level BCVA changes, using the participant as the cluster and an exchangeable working correlation. The empirical sandwich variance was multiplied by m/(m − 1), and confidence intervals and two-sided tests used a t reference distribution with m − 1 degrees of freedom. For BCVA, m = 16, the variance multiplier was 16/15, and the degrees of freedom were 15. This explicit finite-cluster correction replaces the earlier GEE result, whose original analysis code was unavailable. Every included participant contributed two eyes, so the corrected GEE mean and standard error are algebraically identical to those obtained from the 16 independent participant-average changes. This equivalence was checked numerically. The separate exact participant-level Wilcoxon analysis addresses the same bilateral inclusion issue using rank-based inference. Paired perimetry summaries and exact tests were calculated analogously using 10 participant-average changes. The flow of source records and analysis denominators is shown in Figure *1*.

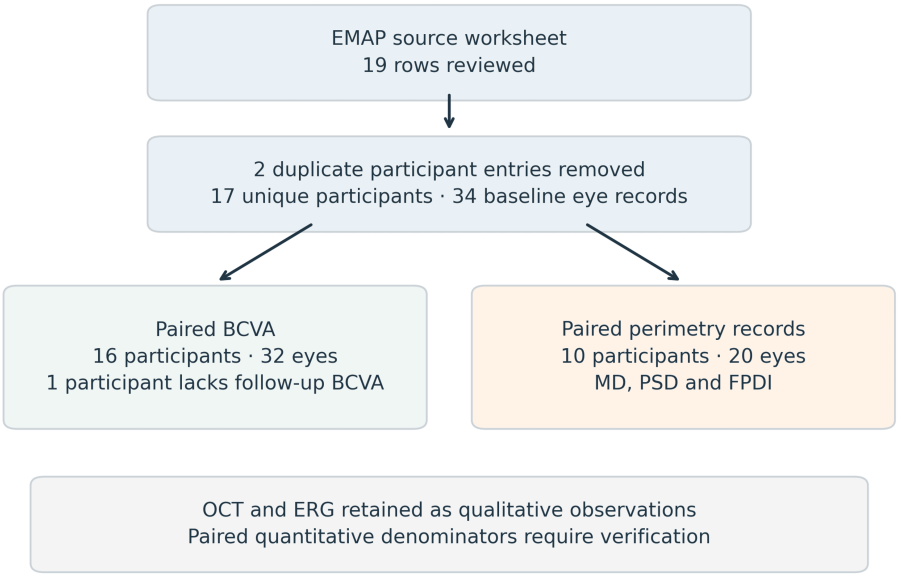

FIGURE 1: Reconciliation of the EMAP source records and availability of paired assessments

The 19 worksheet entries represented 17 unique participants after two duplicate entries were removed. Baseline records covered 34 eyes. One participant had no follow-up BCVA measurement, leaving 32 eyes from 16 participants for the paired BCVA analysis. Paired perimetry records were available for 20 eyes from 10 participants.

BCVA: best-corrected visual acuity, EMAP: extensive macular atrophy with pseudodrusen-like appearance.

Results

Cohort characteristics

A total of 19 patients (36 eyes) with a clinical diagnosis of EMAP and complete paired BCVA data were included. Table 1 summarizes the baseline demographic, clinical, and ophthalmological characteristics of the study cohort. Among patients with available demographic data (n = 16), mean age at M0 was 60.8 ± 6.1 years (median 61.5; range 47-70), and 9/16 (56.2%) were female. The cohort exhibited advanced functional impairment consistent with the EMAP phenotype, with mean M0 BCVA of 1.05 ± 0.48 logMAR and mean M0 visual field MD of −8.09 ± 3.58 dB.

Characteristic	Value	Range/detail
Patients, n	19	-
Eyes analyzed, n	36	Bilateral involvement in most participants
Sex, % female	9/16 (56.2%) female	Available for 16/19 patients
Mean age at baseline, years	60.8 ± 6.1	Median 61.5 (IQR 58-64); range 47-70
Disease laterality	Bilateral	Consistent with EMAP phenotype
Baseline BCVA, logMAR (mean ± SD)	1.05 ± 0.48	Advanced functional impairment
Baseline BCVA, Snellen approx.	~20/200	Range: 20/40 to count fingers
Baseline MD, dB (mean ± SD)	-8.09 ± 3.58	n = 20 eyes with paired data
Baseline PSD, dB (mean ± SD)	9.29 ± 2.29	n = 20 eyes
Baseline FPDI, % (mean)	66.9	n = 20 eyes
EZ status at baseline	Disrupted in all eyes	Qualitative OCT assessment
Pseudodrusen-like deposits	Present (100%)	Diagnostic criterion
Peripheral retinal involvement	Present (100%)	Diagnostic criterion
Macular neovascularization at baseline	None	Exclusion criterion
Concurrent systemic immunosuppression	None	Exclusion criterion
Prior intraocular surgery (≤3 monts)	None except phacoemulsification	Per protocol
Treatment regimen	3 injections (M0, M2, M4)	Intravitreal adalimumab 2 mg/0.05 mL
Follow-up duration	6 months	Standardized per protocol

TABLE 1: Baseline demographic, clinical, and ophthalmological characteristics of the EMAP cohort treated prospectively with off-label intravitreal adalimumab

Functional and structural variables are reported for the subset of eyes with paired data available.

M0: baseline, M2: month 2, M4: month 4, BCVA: best-corrected visual acuity, MD: mean deviation, PSD: pattern standard deviation, FPDI: field preservation deviation index, EMAP: extensive macular atrophy with pseudodrusen-like appearance.

Visual acuity outcomes

In the 32 paired eyes from 16 participants, mean BCVA was 1.106 ± 0.714 logMAR at M0 and 0.991 ± 0.439 logMAR at month 6. Mean eye-level change was -0.116 ± 0.582 logMAR, with a median of 0.000 logMAR. The mean of the participant-average changes was -0.116 ± 0.362 logMAR (95% CI -0.308 to +0.077). The recalculated GEE used a variance multiplier of 16/15 and a t reference distribution with 15 degrees of freedom, yielding β = -0.116 logMAR, corrected standard error 0.090 logMAR, 95% CI -0.308 to +0.077, and p = 0.221. The exact participant-level Wilcoxon test yielded W = 7.0 and p = 0.141. Neither test detected a statistically significant change. The interval remains compatible with improvement and worsening and does not establish functional stability or equivalence between visits. Figure 2 displays the same 32 paired eye records and the same means and standard deviations as this section.

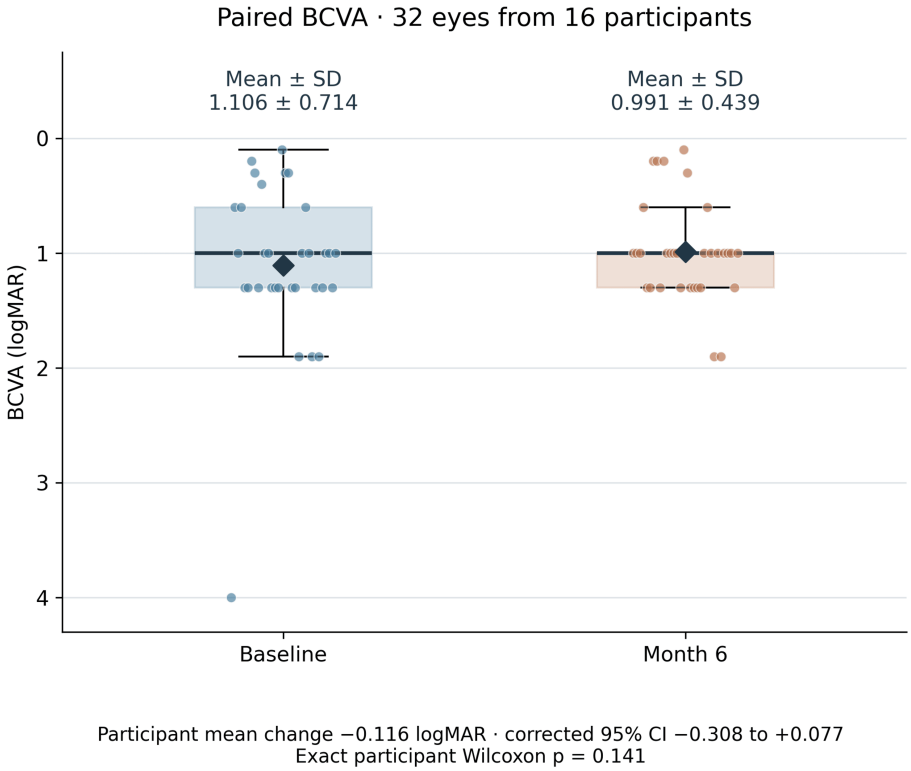

FIGURE 2: BCVA at baseline and month 6 in the same 32 paired eyes from 16 participants

Boxes show the median and interquartile range, whiskers extend to the most extreme observations within 1.5 interquartile ranges, and circles represent individual eyes. Diamonds mark the arithmetic means. Annotations give mean ± sample standard deviation: baseline 1.106 ± 0.714 and month 6 0.991 ± 0.439 logMAR. Inference accounts for participant clustering: corrected GEE p = 0.221 and exact participant-level Wilcoxon p = 0.141. Lower logMAR values indicate better visual acuity.

BCVA: best-corrected visual acuity.

From a clinical perspective, heterogeneity of individual responses was observed. Seven of 36 eyes (19.4%) achieved a clinically meaningful improvement, 2 eyes (5.6%) worsened, and 27 eyes (75.0%) remained stable within ±0.2 logMAR. The categorical outcome analysis used all 36 eyes with paired BCVA values. Figure *3* displays individual trajectories for the 28 eyes for which complete trajectory-level records were available for graphical plotting; eight additional eyes contributed to the aggregate paired BCVA analysis but were not included in the trajectory plot. This distinction accounts for the different denominators.



FIGURE 3: Individual baseline-to-month 6 trajectories for all 32 paired eyes from 16 participants

Seven eyes (21.9%) gained at least 0.2 logMAR, 23 (71.9%) had an absolute change smaller than 0.2 logMAR, and two (6.3%) lost at least 0.2 logMAR. Percentages may sum to more than 100% because of rounding. The plotted records are the same records used in the "Visual acuity outcomes" section and Figure 2.

BCVA: best-corrected visual acuity.

Visual field outcomes

Paired visual field data were available for 20 eyes from 10 participants. Values below are eye-level medians (interquartile ranges). MD was -7.43 (-11.34--5.64) dB at M0 and -6.54 (-10.56--4.34) dB at month 6 (p = 0.160). PSD was 10.33 (7.79-11.11) dB at M0 and 9.45 (8.02-11.14) dB at month 6 (p = 0.695). FPDI was 68.50 (53.75-77.25) % at M0 and 71.00 (66.00-80.25) % at month 6 (p = 0.328). Figure *4* illustrates the paired M0 and month 6 distributions for MD, PSD, and FPDI. The p-values are derived from exact Wilcoxon tests of the 10 participant-average changes. These findings do not establish functional preservation or disease stabilization.

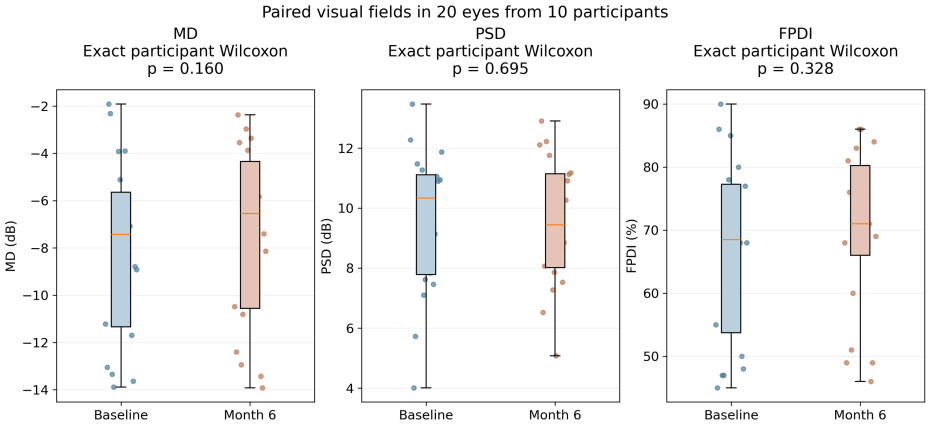

FIGURE 4: Recalculated paired MD, PSD, and FPDI in 20 eyes from 10 participants

Boxes show medians and interquartile ranges, whiskers extend to observations within 1.5 interquartile ranges, circles show individual eyes, and diamonds mark arithmetic means. Two-sided exact Wilcoxon tests were performed on the 10 participant-average changes, yielding p = 0.160 for MD, 0.695 for PSD, and 0.328 for FPDI. VFI was not substituted for FPDI. Conflicting duplicate perimetry records and records explicitly obtained on different perimeters were excluded. The investigator confirmed that each included eye maintained the same 10-2 or 24-2 strategy at both visits. Numerical test-reliability thresholds were not supplied.

MD: mean deviation, PSD: pattern standard deviation, and FDPI: field preservation deviation index.

Structural OCT and electrophysiological outcomes

Structural evaluation using OCT demonstrated no significant changes in EZ integrity or central macular thickness over the six-month follow-up period. Mean OCT-derived parameters remained stable from M0 to month 6, with no signs of accelerated macular atrophy, outer retinal thinning, or treatment-related structural damage on qualitative inspection. Electrophysiological assessment was performed using full-field ERG with 30-Hz flicker stimulation, serving as a surrogate marker of macular cone function. In eyes with measurable responses, both flicker amplitude and implicit time remained stable throughout the study period, with no statistically significant changes detected between M0 and follow-up. Taken together, the OCT and ERG findings revealed no measurable structural or electrophysiological deterioration of the outer retina over the six-month period. Because the structural assessment was qualitative and no quantitative atrophy metrics were obtained, these observations are consistent with short-term tolerability but do not, on their own, establish disease stabilization, which would require quantitative structural endpoints and a controlled design to demonstrate. It should be emphasized that structural assessment in this study was qualitative and limited to central macular thickness and ellipsoid zone inspection. Quantitative atrophy-based metrics that more sensitively track EMAP progression, including FAF-quantified atrophy area, automated outer retinal and RPE atrophy segmentation, ellipsoid zone loss area, and OCTA-derived choriocapillaris flow indices, were not systematically available in this real-world dataset and were therefore not analyzed. Accordingly, the structural stability reported here should be interpreted with caution and confirmed in prospective studies incorporating these standardized quantitative endpoints.

Safety outcomes

Throughout the six-month follow-up period, no procedure-related serious ocular adverse events were observed in the treated eyes. Specifically, there were no clinical signs of intraocular inflammation, such as anterior chamber reaction, vitritis, or retinal vasculitis, and no cases of ocular infection, including endophthalmitis, were recorded. Intraocular pressure remained stable, with no clinically meaningful elevations attributable to treatment. There was no evidence of treatment-related retinal toxicity, as supported by the absence of structural deterioration on OCT and the stability of electrophysiological parameters on full-field ERG. From a functional standpoint, no systematic reduction in BCVA or visual field sensitivity was detected at the cohort level. Collectively, these findings indicate that intravitreal adalimumab demonstrated a favorable ocular safety profile, without signs of inflammatory, infectious, or toxic effects, supporting the procedural safety and tolerability of this intervention in patients with EMAP over the observed period. These safety observations should, however, be interpreted as preliminary and short-term. With only 19 patients and a six-month follow-up, the study was not powered to detect rare, idiosyncratic, or late-onset ocular or systemic adverse events associated with intravitreal adalimumab. Larger prospective cohorts with longer follow-up are required before any definitive conclusion regarding the ocular and systemic safety profile of intravitreal adalimumab in EMAP can be drawn.

Discussion

EMAP is a rare and clinically aggressive degenerative macular phenotype characterized by bilateral atrophy and progressive functional impairment [1-6]. Natural-history studies document progressive enlargement of atrophic lesions, extension beyond the macula in advanced disease, and worsening visual function over time [4-6,11-13]. Against this background, the absence of a statistically significant decline in BCVA or the measured visual-field indices over six months is an exploratory observation. However, because the present study had no untreated or sham comparator, these findings cannot establish that TNF-α inhibition altered the natural history of EMAP.

In this prospective exploratory cohort, intravitreal administration of adalimumab was associated with overall functional and structural stability over a six-month follow-up period. Mean BCVA remained stable at the cohort level, with the majority of eyes demonstrating changes within ±0.2 logMAR, and the GEE sensitivity analysis confirmed the robustness of this estimate after accounting for intra-subject correlation. Notably, a subset of eyes (19.4%) achieved clinically meaningful improvement, while only a small proportion (5.6%) experienced deterioration. The proportion of eyes showing a gain of ⩾0.2 logMAR should, however, be interpreted with caution. Given the uncontrolled design, the small sample size, and the well-recognized contributions of test-retest variability, learning effects, and regression to the mean to apparent visual acuity gains in advanced disease, these improvements are best regarded as preliminary, hypothesis-generating signals rather than as evidence of a therapeutic benefit. Similarly, visual field parameters, including MD, PSD, and FPDI, did not demonstrate evidence of progressive decline, and FPDI showed a small directional trend toward preservation. Although these findings do not establish therapeutic efficacy, the absence of measurable deterioration across multiple functional metrics may represent a clinically relevant observation in a condition typically characterized by relentless progression.

Structural and electrophysiological findings were consistent with this pattern of stability. OCT demonstrated no significant changes in central macular thickness or qualitative progression of EZ disruption. The EZ is widely recognized as a key biomarker of photoreceptor integrity, and its preservation has been associated with functional stability in degenerative retinal diseases [3-6,11]. In parallel, full-field ERG with 30-Hz flicker stimulation revealed stable responses in eyes with measurable signals. Although ERG provides a global measure of retinal function and may not capture localized macular changes, the absence of electrophysiological deterioration further supports the short-term ocular safety of intravitreal adalimumab and suggests a potential stabilizing signal that requires confirmation.

The biological rationale for TNF-α inhibition in degenerative retinal disease is supported by evidence implicating inflammatory and immune-mediated mechanisms in outer retinal degeneration. Chronic para-inflammatory processes involving microglial activation, oxidative stress, and complement dysregulation have been proposed as contributors to photoreceptor loss [7,8,16]. Experimental retinal-degeneration studies have shown that adalimumab-mediated TNF-α blockade can reduce photoreceptor cell death and delay retinal degeneration, providing a mechanistic basis for further investigation [26,27]. The proposed inflammatory framework and the hypothesized modulatory effect of TNF-α inhibition are illustrated in Figure *5*; this mechanism was not directly tested in the present study.

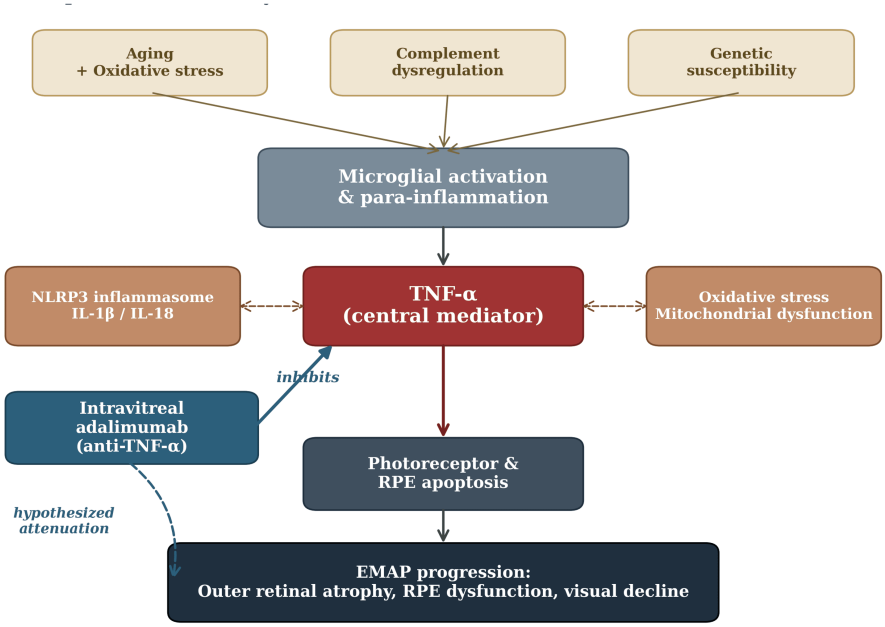

FIGURE 5: Proposed inflammatory cascade in extensive macular atrophy with pseudodrusen-like appearance (EMAP) and mechanistic rationale for intravitreal TNF-α blockade

The schematic is hypothetical and summarizes a biological rationale derived from published literature; no intraocular cytokine or biomarker measurements were obtained in the present cohort.

Image credits: This image was created using Python 3.12 and Matplotlib (Python Software Foundation, Fredericksburg, VA, USA); no externally reproduced material was used.

Although EMAP has traditionally been considered within the spectrum of macular atrophic disorders, emerging evidence suggests that inflammatory mechanisms may contribute to disease progression. Observational data have identified potential associations between EMAP and systemic inflammatory conditions, including rheumatic disease and rheumatic fever-related valvular involvement, supporting the hypothesis that immune-mediated pathways may play a role in disease pathogenesis [15,29]. While these associations remain preliminary and require confirmation in larger prospective cohorts, they provide a biological rationale for investigating inflammatory mediators such as TNF-α. In the present study, adalimumab was administered intravitreally as an off-label intervention. The dose and schedule were not developed specifically for EMAP; they were adopted from our previously published prospective retinitis pigmentosa pilot study using 2 mg/0.05 mL at M0, M2, and M4 [30]. The RP study provided a prior clinical tolerability and feasibility precedent for this regimen, but extrapolation from RP to EMAP remains investigational because the diseases are distinct and the present study did not test a mechanistic equivalence between them. Moreover, we did not obtain intraocular cytokine measurements, aqueous or vitreous biomarkers, inflammatory imaging markers, or systemic immunological profiling. The principal contribution of this work is therefore clinical rather than mechanistic: it describes short-term outcomes after off-label intravitreal adalimumab in EMAP. The proposed TNF-α mechanism should be regarded as a rationale to be tested, rather than demonstrated, and the clinical observations should be interpreted within the constraints of an uncontrolled design and qualitative structural assessment.

Safety considerations are particularly important when a biologic agent is administered by an off-label intraocular route. Preclinical findings with intravitreal adalimumab have been dose- and model-dependent. In one rabbit study, doses of 0.25 and 0.50 mg produced no detectable functional or structural toxicity, whereas 1.0 mg was associated with intraocular inflammation, greater than 30% ERG amplitude reduction in two of three eyes, and retinal necrosis in one eye [18]. In a subsequent dose-escalation rabbit study, doses up to 5 mg showed no short-term clinical or ERG toxicity, whereas 10 mg produced mild anterior chamber inflammation in three of six eyes and a significant reduction in the photopic ERG response, interpreted as possible early toxicity [19]. Other experimental studies have evaluated retinal morphology and function after intravitreal exposure [20,21]. These data do not justify a general statement of safety across all tested doses. Our previously published prospective retinitis pigmentosa pilot study used 2 mg/0.05 mL at M0, M2, and M4 without serious ocular adverse events during six months of follow-up [30]. In the present EMAP cohort, no procedure-related serious ocular adverse events were observed. These findings support short-term

tolerability of this specific regimen in this cohort but do not establish long-term or dose-independent safety.

Study limitations

Several limitations should be considered when interpreting these findings. First, the prospective single-arm design and absence of a concurrent untreated or sham control group preclude causal inference regarding treatment effects; observed stability may reflect natural variability, test-retest effects, or the underlying disease course rather than a direct effect of TNF-alpha inhibition. Second, intravitreal adalimumab for EMAP is an off-label intervention, and the 2 mg/0.05 mL dose and schedule were extrapolated from our prior prospective retinitis pigmentosa pilot study rather than established through an EMAP-specific dose-ranging study [30]. Although that prior study provided a clinical precedent for ocular exposure, feasibility, and short-term tolerability, retinitis pigmentosa and EMAP are distinct disorders, and this extrapolation cannot establish an optimal dose, efficacy, or long-term safety for EMAP. Third, the sample size was small and follow-up was limited to six months, reducing statistical power and the ability to detect rare or delayed adverse events. Fourth, quantitative structural biomarkers of atrophy progression, including fundus-autofluorescence lesion area, automated outer retinal and RPE atrophy segmentation, ellipsoid-zone loss area, and OCT angiography-derived choriocapillaris metrics, were not systematically available; structural assessment was therefore predominantly qualitative. Finally, visual field and electrophysiological data were available only in subsets of participants because advanced disease and fixation instability limited reliable testing. The proposed para-inflammatory and TNF-alpha-mediated mechanism remains biologically plausible but unproven because intraocular cytokine measurements and biomarker profiling were not performed. Accordingly, the functional and structural observations should be regarded as exploratory and hypothesis-generating rather than evidence of therapeutic efficacy or disease modification.

Future directions

Given the rarity of EMAP and the absence of established therapies, prospective exploratory data may help guide future research. Controlled studies with longer follow-up and standardized structural endpoints, such as quantitative FAF-based atrophy area, high-resolution OCT segmentation, ellipsoid-zone loss, and OCTA-derived choriocapillaris metrics, will be required to determine whether TNF-α inhibition influences disease progression. Future trials should incorporate a concurrent untreated or sham comparator or a prospectively matched natural-history cohort, together with adequately powered patient-level analyses. Integration of aqueous or vitreous cytokine profiling, including TNF-α, and systemic inflammatory characterization could directly test the proposed para-inflammatory mechanism and potentially support biomarker-based patient selection.

Conclusions

In this prospective, exploratory, single-arm study of patients with EMAP, off-label intravitreal adalimumab at 2 mg/0.05 mL administered at M0, M2, and M4 demonstrated favorable short-term ocular tolerability over six months, with no procedure-related serious ocular adverse events or consistent evidence of treatment-related retinal toxicity. Functional outcomes were generally stable, but the uncontrolled design does not permit attribution of these observations to treatment. The regimen was selected from our previously published prospective retinitis pigmentosa pilot experience, which served as a dose-selection and short-term tolerability precedent rather than evidence of efficacy in EMAP. These findings do not establish therapeutic efficacy, disease modification, an optimal EMAP dose, or long-term safety. Controlled studies with longer follow-up and standardized quantitative multimodal imaging endpoints are required.

Additional Information

Author Contributions

All authors have reviewed the final version to be published and agreed to be accountable for all aspects of the work.

Concept and design: Rubens C. Siqueira, Tainara S. Pinho, Thais Q. Brito, Cinara C. Brandao

Acquisition, analysis, or interpretation of data: Rubens C. Siqueira, Tainara S. Pinho, Thais Q. Brito, Cinara C. Brandao

Drafting of the manuscript: Rubens C. Siqueira, Tainara S. Pinho, Thais Q. Brito, Cinara C. Brandao

Critical review of the manuscript for important intellectual content: Rubens C. Siqueira, Tainara S. Pinho, Thais Q. Brito, Cinara C. Brandao

Supervision: Rubens C. Siqueira, Tainara S. Pinho, Thais Q. Brito, Cinara C. Brandao

Disclosures

Human subjects: Informed consent for treatment and open access publication was obtained or waived by all participants in this study. Sociedade Brasileira para Pesquisa e Estudo em Terapia Celular (CEP/SOCELL) issued approval 86943125.0.0000.0317. **Animal subjects:** All authors have confirmed that this study did not involve animal subjects or tissue. **Conflicts of interest:** In compliance with the ICMJE uniform disclosure form, all authors declare the following: **Payment/services info:** All authors have declared that no financial support was received from any organization for the submitted work. **Financial relationships:** All authors have declared that they have no financial relationships at present or within the previous three years with any organizations that might have an interest in the submitted work. **Other relationships:** All authors have declared that there are no other relationships or activities that could appear to have influenced the submitted work.

References

1. Hamel CP, Meunier I, Arndt C, et al.: Extensive macular atrophy with pseudodrusen-like appearance: a new clinical entity. Am J Ophthalmol. 2009, 147:609-20. 10.1016/j.ajo.2008.10.022
2. Spaide RF, Ooto S, Curcio CA: Subretinal drusenoid deposits AKA pseudodrusen. Surv Ophthalmol. 2018, 63:782-815. 10.1016/j.survophthal.2018.05.005
3. Douillard A, Picot MC, Delcourt C, et al.: Clinical characteristics and risk factors of extensive macular atrophy with pseudodrusen: the EMAP case-control national clinical trial. Ophthalmology. 2016, 123:1865-73. 10.1016/j.ophtha.2016.05.018
4. Antropoli A, Arrigo A, Bianco L, et al.: Quantitative multimodal imaging of extensive macular atrophy with pseudodrusen and geographic atrophy with diffuse trickling pattern. Sci Rep. 2023, 13:1822. 10.1038/s41598-023-28906-4
5. Antropoli A, Bianco L, Romano F, et al.: Extensive macular atrophy with pseudodrusen-like appearance (EMAP) clinical characteristics, diagnostic criteria, and insights from allied inherited retinal diseases and age-related macular degeneration. Prog Retin Eye Res. 2025, 104:101320. 10.1016/j.preteyeres.2024.101320
6. Antropoli A, Bianco L, Condroyer C, et al.: Extensive macular atrophy with pseudodrusen-like appearance: progression kinetics and late-stage findings. Ophthalmology. 2024, 131:1175-84. 10.1016/j.ophtha.2024.04.001
7. Fleckenstein M, Keenan TD, Guymer RH, et al.: Age-related macular degeneration. Nat Rev Dis Primers. 2021, 7:31. 10.1038/s41572-021-00265-2
8. Douillard A, Picot MC, Delcourt C, et al.: Dietary, environmental, and genetic risk factors of extensive macular atrophy with pseudodrusen, a severe bilateral macular atrophy of middle-aged patients. Sci Rep. 2018, 8:6840. 10.1038/s41598-018-25003-9
9. Carlà MM, Giannuzzi F, Boselli F, Crincoli E, Rizzo S: Extensive macular atrophy with pseudodrusen-like appearance: comprehensive review of the literature. Graefes Arch Clin Exp Ophthalmol. 2024, 262:3085-97. 10.1007/s00417-024-06600-z
10. Rajabian F, Arrigo A, Bordato A, Mercuri S, Bandello F, Battaglia Parodi M: Optical coherence tomography angiography in extensive macular atrophy with pseudodrusen-like appearance. Transl Vis Sci Technol. 2020, 9:2. 10.1167/tvst.9.3.2
11. Romano F, Boon CJ, Invernizzi A, et al.: Correlation between microperimetry and imaging in extensive macular atrophy with pseudodrusen-like appearance. Retina. 2024, 44:246-54. 10.1097/IAE.0000000000003951
12. Romano F, Airaldi M, Cozzi M, et al.: Progression of atrophy and visual outcomes in extensive macular atrophy with pseudodrusen-like appearance. Ophthalmol Sci. 2021, 1:100016. 10.1016/j.xops.2021.100016
13. Romano F, Cozzi M, Monteduro D, Oldani M, Boon CJ, Staurenghi G, Salvetti AP: Natural course and classification of extensive macular atrophy with pseudodrusen-like appearance. Retina. 2023, 43:402-11. 10.1097/IAE.0000000000003683
14. Trinco A, Antropoli A, Bianco L, et al.: Incidence, characteristics, and outcomes of macular neovascularization in extensive macular atrophy with pseudodrusen-like appearance. Retina. 2025, 45:1689-700. 10.1097/IAE.0000000000004506
15. Moreira-Neto CA, Schmidt Andujar RA, Chao JC, et al.: Rheumatic fever and long-term use of benzathine penicillin as possible risk factors for extensive macular atrophy with pseudodrusen in a Brazilian cohort. Int J Retina Vitreous. 2024, 10:75. 10.1186/s40942-024-00592-y
16. Siqueira RC, Brandão CC: The role of cytokines in degenerative retinal diseases: a comprehensive review . Biomedicines. 2025, 13:1724. 10.3390/biomedicines13071724
17. Yoshida N, Ikeda Y, Notomi S, et al.: Clinical evidence of sustained chronic inflammatory reaction in retinitis pigmentosa. Ophthalmology. 2013, 120:100-5. 10.1016/j.ophtha.2012.07.006
18. Manzano RP, Peyman GA, Carvounis PE, Kivilcim M, Khan P, Chevez-Barrios P, Takahashi W: Ocular toxicity of intravitreous adalimumab (Humira) in the rabbit. Graefes Arch Clin Exp Ophthalmol. 2008, 246:907-11. 10.1007/s00417-008-0765-z
19. Manzano RP, Peyman GA, Carvounis PE, et al.: Toxicity of high-dose intravitreal adalimumab (Humira) in the rabbit. J Ocul Pharmacol Ther. 2011, 27:327-31. 10.1089/jop.2010.0174
20. Myers AC, Ghosh F, Andréasson S, Ponjavic V: Retinal function and morphology in the rabbit eye after intravitreal injection of the TNF alpha inhibitor adalimumab. Curr Eye Res. 2014, 39:1106-16. 10.3109/02713683.2014.898309
21. Tsilimbaris M, Diakonis VF, Naoumidi I, et al.: Evaluation of potential retinal toxicity of adalimumab (Humira). Graefes Arch Clin Exp Ophthalmol. 2009, 247:1119-25. 10.1007/s00417-009-1065-y
22. Hasan N, Chawla R, Shaikh N, Kandasamy S, Azad SV, Sundar MD: A comprehensive review of intravitreal immunosuppressants and biologicals used in ophthalmology. Ther Adv Ophthalmol. 2022, 14:25158414221097418. 10.1177/25158414221097418
23. Siqueira RC, Pinho TS, Brito TQ, et al.: Intravitreal TNF-α inhibition in extensive macular atrophy with pseudodrusen-like appearance (EMAP): a real-world cohort study (Preprint). Research Square. 2026,

10.21203/rs.3.rs-8888943/v1

24. Kheir WJ, Mehanna CJ, Abdul Fattah M, Al Ghadban S, El Sabban M, Mansour AM, Hamam RN: Intravitreal adalimumab for the control of breakthrough intraocular inflammation. Ocul Immunol Inflamm. 2018, 26:1206-11. 10.1080/09273948.2017.1335756
25. Hamam RN, Barikian AW, Antonios RS, Abdulaal MR, Alameddine RM, El Mollayess G, Mansour AM: Intravitreal adalimumab in active noninfectious uveitis: a pilot study . Ocul Immunol Inflamm. 2016, 24:319-26. 10.3109/09273948.2014.990041
26. Velasco S, Gallego I, Olivares-González L, et al.: Noninvasive ocular delivery of adalimumab-loaded nanostructured lipid carriers for targeted retinitis pigmentosa therapy. Biomed Pharmacother. 2025, 185:117962. 10.1016/j.biopha.2025.117962
27. Olivares-González L, Velasco S, Millán JM, Rodrigo R: Intravitreal administration of adalimumab delays retinal degeneration in rd10 mice. FASEB J. 2020, 34:13839-61. 10.1096/fj.202000044RR
28. Arruda MP, Lima RV, Valle GS, et al.: Clinical and multimodal imaging findings in extensive macular atrophy with pseudodrusen (EMAP): a systematic review and meta-analysis. Am J Ophthalmol. 2026, 285:228-39. 10.1016/j.ajo.2026.02.006
29. Cassavia Junior AS, Bellanda V, Audi LO, et al.: Assessing the prevalence of extensive macular atrophy with pseudodrusen-like appearance in patients with rheumatic fever-associated valvular heart disease: a cross-sectional study. Int J Retina Vitreous. 2026, 12:31. 10.1186/s40942-026-00805-6
30. Siqueira RC, Pinho TS, Brandao CC: Intravitreal adalimumab in retinitis pigmentosa: a prospective pilot study assessing ocular safety and feasibility. Cureus. 2026, 18:e109091. 10.7759/cureus.109091