Cureus
Part of SPRINGER NATURE

Open Access Original Article

Short-Term Clinical and Radiographic Follow-Up of a Synthetic Calcium Sulfate and Beta-Tricalcium Phosphate Composite Bone Graft (genex®)

Review began 10/21/2026
Review ended 11/11/2026
Published 11/20/2026

© Copyright 2026
Buchalter et al. This is an open access article distributed under the terms of the Creative Commons Attribution License CC-BY 4.0., which permits unrestricted use, distribution, and reproduction in any medium, provided the original author and source are credited.

DOI: 10.7759/cureus.120017

Wyatt H. Buchalter [1], Davis T. Hedbany [2], Christopher K. Johnson [3], Timothy A. Damron [3]

1. Orthopedic Surgery, State University of New York Upstate Medical University, Syracuse, USA 2. Surgery, State University of New York Upstate Medical University, Syracuse, USA 3. Orthopedics, State University of New York Upstate Medical University, Syracuse, USA

Corresponding author: Davis T. Hedbany, davishedbany@gmail.com

Abstract

Background: Synthetic bone grafts have gained popularity for addressing bone defects following trauma or curettage of bone lesions. While studies have investigated calcium phosphate, calcium sulfate, or tricalcium phosphate, limited data exist on the use of genex®, a synthetic calcium composite, in oncologic applications. This study evaluated the effectiveness of genex® in terms of graft resorption, incorporation, and complications. We hypothesized that genex® would progressively incorporate into bone and resorb in coordination with bone healing over one year and sought to characterize its short-term safety profile in the oncologic setting.

Methods: A retrospective chart review of 13 consecutive patients who underwent genex® placement after open biopsy and defect grafting between 2020 and 2021 at a single academic medical center was performed. Graft resorption was measured by the proportion of remaining graft material on anteroposterior and lateral radiographs, and incorporation was determined by the proportion of bone formation relative to the initial defect. Resorption and incorporation were evaluated at six weeks, three months, six months, and one year postoperatively, and any complications were noted.

Results: Thirteen patients (mean age 18.5±13.6) were included. Graft resorption averaged 65.9%±20.8 at six weeks (n=13), 78.7%±28.3 by three months (n=10), 87.4%±15.9 at six months (n=6), and 99.1%±1.8 at one year (n=4). Graft incorporation averaged 17.7%±26.8 at six weeks (n=13), 45.1%±40.1 at three months (n=10), 69.1%±23.6 at six months (n=4), and 98.7%±2.5 at one year (n=2). A "halo" of sclerotic bone around the graft was present in 12 out of 13 patients at six weeks, with heterogeneous resorption. Two post-operative fractures were noted: one due to a local recurrence of a unicameral bone cyst and the other occurred early post-op following trauma. Two local recurrences occurred in unicameral and aneurysmal bone cysts. No post-operative adverse local tissue graft reactions were noted.

Conclusions: genex® demonstrated rapid resorption and progressive incorporation while promoting osteo-regeneration in this cohort. Four complications were noted but appeared more consistent with disease- or trauma-related than graft-related mechanisms. No post-operative adverse local tissue reactions were observed over short-term follow-up. Further research is needed to investigate the long-term outcomes and enhance treatment strategies for these bone lesions.

Categories: Therapeutics, Oncology, Orthopedics
Keywords: benign bone tumors, beta-tricalcium phosphate, bone graft substitutes, calcium sulfate, genex®, synthetic bone graft

Introduction

Benign bone tumors may require bone curettage with or without grafting [1,2]. Bone defects from trauma or after curettage of bone tumors create a unique challenge, as they reduce the mechanical strength of native bone and introduce the risk of pathological fracture [3,4]. Although curettage alone can effectively treat some small tumors, the standard of care for most larger bone defects is to use a filler [4-6].

Autologous bone grafts are considered the gold standard because they have osteoconductive, osteoinductive, and osteogenic properties that allow rapid, effective integration with the bone [7,8]. However, autograft donor sites are a significant source of morbidity and may fail to yield the desired amount of graft material [7,9-11]. Allogeneic bone grafts, which provide only osteoconductive properties, avoid graft harvest-site morbidity and are available in structural, cortical, and cancellous (cubes, chips, and crushed) forms, but they are associated with the risk of disease transmission [7,12,13].

Synthetic bone graft substitutes only provide osteoconductive properties while avoiding the drawbacks associated with autografts and allografts. Synthetic bone graft substitutes include calcium sulfate, calcium phosphate (CaP) ceramics, calcium phosphate cements (CPC), and bioactive glass [7,14]. Some fillers may include osteoinductive growth factors such as bone morphogenetic proteins (BMPs) to promote more effective healing [7,15].

genex® (Zimmer Biomet, Warsaw, IN, USA) is a relatively new bone graft substitute comprised of 50% calcium sulfate osteoconductive carrier and 50% β-tricalcium phosphate osteoconductive scaffold. It has strength similar to trabecular bone and is purportedly completely resorbable, allowing native bone remodeling and defect healing. genex® is introduced to the surgical site as an injectable paste and sets at body temperature within 15 minutes [16]. Numerous reports describe filling bone defects with CaP, calcium sulfate, or tricalcium phosphate alone after curettage of bone lesions [1,17-20]. Although genex®'s potential adverse effects have been reported, and its use has been examined in trauma, spine, and osteomyelitis applications, data are lacking on its use for oncologic indications [1,21-23].

This retrospective case series includes 13 patients who underwent genex® grafting after bone lesion curettage. The purpose of this study was to evaluate the timeline and radiographic features of graft incorporation, resorption, and complications for genex® in the setting of curetted bone defects. We hypothesized that the genex® graft would progressively incorporate into the bone and exhibit controlled resorption relative to bone healing over one year, while remaining safe and efficacious in oncologic applications.

This article was previously presented at the 2024 Orthopaedic Research Society Annual Meeting on February 3, 2024.

Materials And Methods

This retrospective chart review was conducted at a single tertiary academic medical center and was determined to be exempt from Institutional Review Board review by the State University of New York (SUNY) Upstate Medical University IRB (IRBNet #1819241; exemption category 4(iii)), with a waiver of Health Insurance Portability and Accountability Act (HIPAA) authorization. We performed a chart review of 13 consecutive patients who underwent placement of genex® bone graft. Patients were eligible for inclusion if they underwent curettage of a benign or low-grade (nonmalignant) bone lesion with genex® grafting during the study period and had at least one postoperative radiograph available for review. Patients were excluded if they had a malignant lesion requiring en bloc resection, received a graft substitute other than genex® at the index procedure, or did not have adequate postoperative imaging. All consecutive eligible patients were included.

Each patient had undergone open biopsy and defect grafting by a single surgeon during 2020-2021. We obtained initial graft dimensions from the operative notes. Graft resorption was calculated by subtracting the proportion of the remaining graft volume from the initial graft volume from one on standard anteroposterior and lateral radiographs, similar to previously described techniques [22]:

$$\%\ \text{Resorption} = 100 \times \left(1 - \frac{\text{Remaining Graft Volume}}{\text{Initial Graft Volume}}\right)$$

Graft incorporation was calculated by the proportion of bone formation versus the initial bone defect size:

$$\%\ \text{Incorporation} = 100 \times \frac{\text{Bone Formation Volume}}{\text{Initial Bone Defect Volume}}$$

We differentiated and measured remaining graft material separately from bone formation, as the graft material appears denser than bone. Measurements were made using tools within the Synapse Radiology PACS imaging software (Fujifilm Medical Systems, Stamford, CT, USA) by an orthopedic surgery resident and confirmed by the senior author. Lesion and graft dimensions were measured in three planes - greatest length, width, and depth - on orthogonal anteroposterior and lateral radiographs using Synapse PACS, and volume was estimated using the ellipsoid approximation, $V = \frac{\pi}{6} \times \text{length} \times \text{width} \times \text{depth}$.

These radiographic estimates approximate, rather than directly measure, three-dimensional volume (e.g., by CT), which we address as a limitation. Resorption and incorporation were assessed at the six-week, three-month, six-month, and one-year postoperative visits. Patient charts were also reviewed at each visit for complications, including graft reaction, prolonged drainage, seroma, lesion recurrence, or fracture. Continuous variables are reported as mean ± standard deviation and categorical variables as counts and percentages. Given the small, descriptive cohort, no inferential statistical testing was performed; accordingly, no test statistics or p-values are reported.

Results

Thirteen patients (mean age 18.5 ± 13.6) were included in the analysis (Table 1).

Characteristic	N (%)
Number of patients	13
Female	7 (53.8)
Mean age (years)	18.5 ± 13.6 (range 6-56)
Prophylactic stabilization	3 (23.1)
Active smoker	0 (0)
Diabetes	0 (0)
Revision surgery	1 (7.7); CERAMENT™

TABLE 1: Patient demographics and clinical characteristics

We recorded lesion characteristics for each patient who received a bone graft (Table 2).

Characteristic	Category	N (%)
Diagnosis	Unicameral bone cyst	3 (23.1)
	Intraosseous hemangioma	2 (15.4)
	Fibrous dysplasia	2 (15.4)
	Aneurysmal bone cyst	1 (7.7)
	Giant cell-rich ABC	1 (7.7)
	Chondroblastoma	1 (7.7)
	Enchondroma	1 (7.7)
	Non-ossifying fibroma	1 (7.7)
	No diagnosis	1 (7.7)
Enneking stage	Latent	5 (38.5)
	Active	5 (38.5)
	Aggressive	3 (23.1)
Tumor location	Upper extremity	7 (53.8)
	Lower extremity	5 (38.5)
	Pelvis	1 (7.7)

TABLE 2: Lesion characteristics

ABC: aneurysmal bone cyst

Resorption and incorporation

The percentage of graft material resorption and incorporation gradually increased over time and approached 100% at one year, although fewer patients were followed up (Figure 1). At six months, six patients (resorption) and four patients (incorporation) had radiographs available, and at one year, four and two patients, respectively.

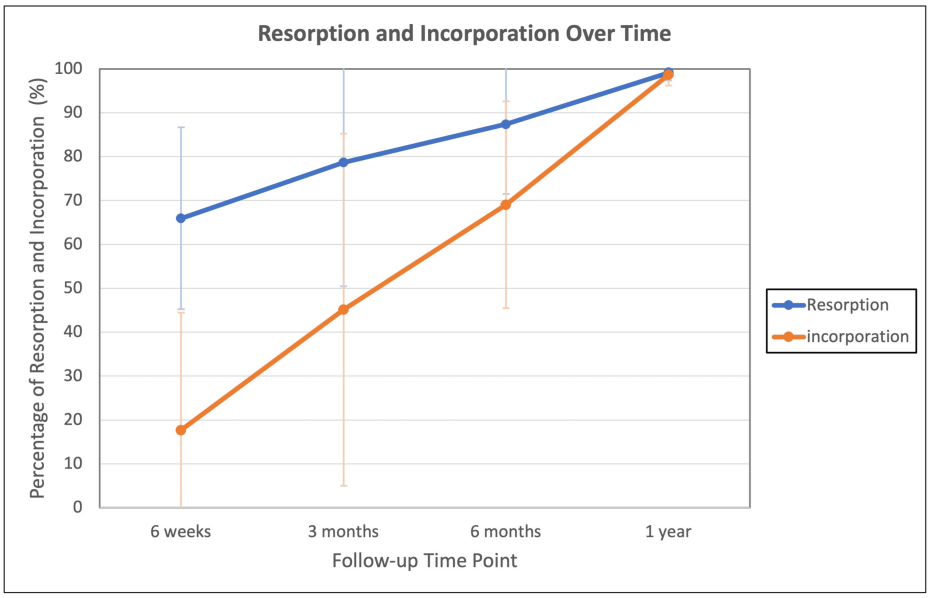

FIGURE 1: Resorption and incorporation of genex® as a percentage at six weeks, three months, six months, and one year

Radiographic patterns

The "marble sign," denoted by a marble-shaped hypodense area of remaining graft material, was seen in several patients through the six-month time point. Additionally, the "puddle sign," defined as a hyperdense remnant of the graft material accumulating at the inferior aspect of the defect site, was scarcely seen through the six-month time point. Notably, the most prevalent radiographic finding was the "halo sign," defined as a halo of sclerotic bone around the graft material, evident in most patients through the six-month time point (Table *3* and Figure *2*) [22].

Feature	Six weeks (n=13)	Three months (n=10)	Six months (n=6)	One year (n=4)
Halo sign	12/13 (92.3%)	5/10 (50.0%)	3/6 (50.0%)	0/4 (0%)
Marble sign	5/13 (38.5%)	2/10 (20.0%)	1/6 (16.7%)	0/4 (0%)
Puddle sign	2/13 (15.4%)	1/10 (10.0%)	1/6 (16.7%)	0/4 (0%)

TABLE 3: Frequency of radiographic signs at follow-up

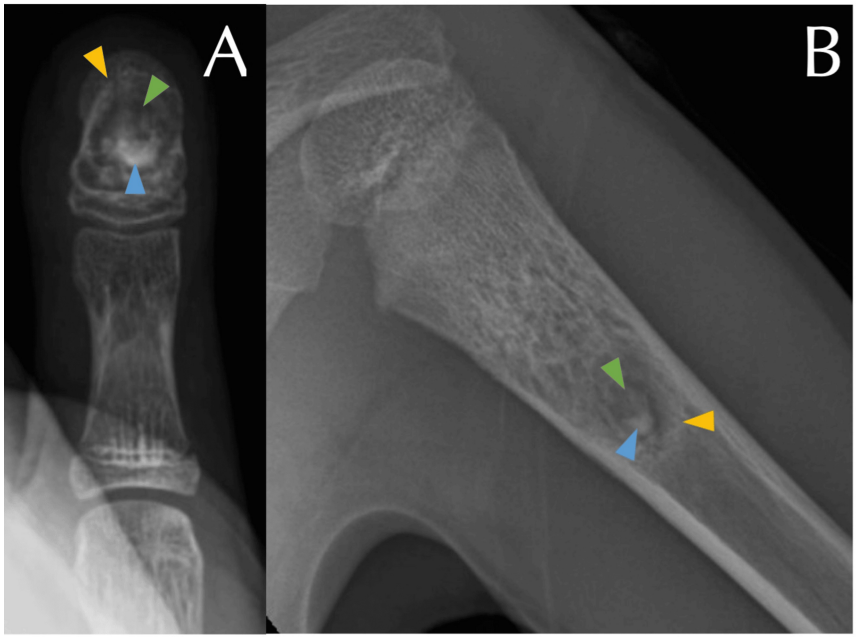

FIGURE 2: Radiographic patterns

(A) Radiograph of a giant cell-rich aneurysmal bone cyst of the distal phalanx of the thumb at six weeks postoperatively. (B) Radiograph of fibrous dysplasia of the proximal humerus demonstrating the "puddle sign." Yellow arrows indicate bone incorporation, green arrows indicate radiolucency, and blue arrows indicate residual graft material.

Centripetal resorption (graft resorbed from the periphery of the lesion toward the center) and heterogeneous resorption (moth-eaten pattern) are also visible.

The graft material was typically resorbed heterogeneously (Figure *2*) and incorporated in a centripetal fashion, with increasing dense new bone formation on the periphery working its way towards the center of the defect.

Complications

Four complications occurred across three of 13 patients (23.1%) during follow-up: two fractures and two local recurrences, with one patient contributing both (Table *4*).

Complication	N (%)
Tumor recurrence without fracture	1 (7.7)
Tumor recurrence with fracture	1 (7.7)
Fracture without recurrence	1 (7.7)
Total patients with complications	3 (23.1)

TABLE 4: Complications and tumor recurrence

Recurrence without fracture: aneurysmal bone cyst; recurrence with fracture: unicameral bone cyst; fracture without recurrence: unicameral bone cyst. One patient sustained both a recurrence and a fracture.

One patient with a proximal femoral shaft unicameral bone cyst had a local recurrence and, during baseball practice approximately one year after curettage, a fracture through the graft site. A second patient with a humeral shaft unicameral bone cyst sustained a fracture without recurrence 10 days postoperatively following direct trauma. A third patient with an aneurysmal bone cyst had a local recurrence without fracture. Thus, four complications occurred across three patients, with two fractures in total. There were no post-operative graft reactions, infections, or wound complications.

Discussion

Synthetic bone substitutes, including calcium sulfate and β-tri-calcium phosphate, are commonly used to fill large bony defects [24]. Calcium sulfate has been shown to resorb over one to three months, creating porosity while stimulating bony ingrowth. However, it is resorbed faster than bone can be incorporated, making it unsuitable for early weight-bearing [25]. β-tri-calcium phosphate resorbs over a longer time, over 12-20 weeks, with effective bone incorporation at six months. Osteoconductive properties can be attributed to its porosity, and the longer resorption time may lead to delayed bone incorporation [25]. Thus, a material that undergoes controlled resorption followed by effective incorporation in a balanced, sequential fashion is desired, which led to the development of biphasic synthetic bone grafts. In the current study, genex® demonstrated controlled, effective resorption and incorporation, as shown by a steady increase that approached 100% at one-year follow-up.

Our study demonstrated genex®'s resorption and incorporation ability, with almost complete incorporation of the graft at one year. Yang et al. showed that genex® resorbs within eight weeks of implantation and allows formation of native trabecular structure in an in vivo sheep vertebral body defect model [26]. genex® can promote native bone remodeling within the bone defect, allowing the bone to restore its original mechanical strength over time. In fact, Yang et al. showed through biomechanical testing that although polymethylmethacrylate (PMMA) provided higher mechanical compressive strength and stiffness to the bone defect on setting, immediately after implantation than the genex® and sham (no material) groups, there was no statistically significant difference at the implant site observed from eight through 36 weeks [26]. Our study demonstrated genex®'s osteo-regenerative capacity and resorption capability, allowing for incorporation of native bone structure.

Although resorption is a distinct feature of this bone graft substitute, the resorption rate is crucial. If the substitute resorbs too quickly, as seen with calcium sulfate alone (which can be resorbed in as little as four weeks), it may form a void without structural substance or adequate mechanical strength, increasing the risk of pathologic fracture [1,26,27]. Conversely, if resorption is too slow or does not occur, remodeling may be ineffective and lead to late fractures, as sometimes seen with coralline hydroxyapatites. Razii et al. examined the use of genex® following curettage of benign bone tumors and found a mean time to complete resorption of 12 months [28]. In the present study, we found a steady resorption rate approaching 100% at one year, consistent with the literature.

The temporal dissociation between resorption and incorporation has clinical implications. At six weeks, graft resorption was already substantial (65.9%), while incorporation remained low (17.7%), defining an early window in which the defect may be mechanically vulnerable before adequate new bone forms. This dissociation, visible in Figure *1*, supports protected weight-bearing and activity restriction during the early postoperative period, particularly for lesions in load-bearing locations. The mechanical demands on the graft also vary with lesion site and biological aggressiveness. Grafts in weight-bearing lower-extremity sites and in more aggressive (Enneking active/aggressive) lesions may be subjected to greater load and larger defects than those in non-weight-bearing upper-extremity or latent lesions. Consistent with this, the two fractures in this series occurred in a proximal femur (weight-bearing, during sport one year postoperatively) and a humeral shaft (following direct trauma at 10 days), illustrating both load- and trauma-related mechanisms.

Regarding patterns of resorption and incorporation, previous studies noted a "halo sign," or a rim of sclerotic bone around the graft material, present at the six-week time point. Ferguson et al. commonly found this halo sign at six-week follow-up in their assessment of radiographic bone healing with a gentamicin-eluting synthetic bone graft substitute for treatment of osteomyelitis [22]. This centripetal resorption pattern has been postulated to represent the initial resorption beginning at the periphery of the graft and subsequently progressing toward the center [29]. We also noted this halo sign in the present study, suggesting a similar resorption pattern.

While four complications in three patients were noted in this study, one of the two fractures occurred early (10 days postoperatively) following direct trauma, before any graft incorporation would be expected, and the other occurred approximately one year postoperatively in association with documented local recurrence. The latter fracture occurred beyond our radiographic follow-up period, so graft resorption and incorporation status at the time of fracture was not assessed. We interpret both fractures as more consistent with trauma- or disease-related than graft-related mechanisms; however, in an uncontrolled retrospective series, a graft-related contribution cannot be formally excluded. Regarding local tumor recurrence in this study, the two cases occurred in bone tumors that tend to recur (unicameral bone cyst and aneurysmal bone cyst). This implies that these tumors are inherently difficult to fully cure with or without the use of a bone substitute, and that recurrence is likely a result of disease and surgical technique independent of the filler.

There were found to be no instances of post-operative graft reactions, including graft discharge, prolonged drainage, seroma formation, or infection/cellulitis. Friesenbichler et al. reported several "major" complications in 16% (5/31) of the patients, including sterile inflammation adjacent to the graft leading to

delayed wound healing with continuous secretion and pain, skin damage requiring revision, and inflammatory cystic formations in the soft tissues causing slight to moderate pain and swelling, leading to the early cessation of the study [1]. Saadoun et al. found that all three patients in their study demonstrated sterile inflammation adjacent to the graft referred to as “sterile pus” [21]. Friesenbichler et al. postulated that this inflammation may result from liquefaction of calcium sulfate during resorption, acidifying the local tissue and leading to invasion by inflammatory cells [1]. The authors also noted that sealing the filler was difficult in most cases, which may have led to the material leaching out into the surrounding tissues [28,30]. Complications may also relate to factors beyond the bone graft material itself, including the superficial location of the graft site in some cases, such as the digits of the hand.

The authors also suggest that defect overfilling and pressurization may contribute to inflammation and soft tissue cyst development, especially with allografts [1]. The difference in complications in Friesenbichler’s study may also be related to tumor type. For example, they had a large proportion of patients with enchondromas. However, in the current study, there were no post-operative graft reactions, so at least in the hands of the authors, in the specific patient population and locations in which genex® was used, this material was not associated with the local tissue reactions previously reported, though the small sample may limit any strong inference about comparative safety.

This study had several limitations. First, it is retrospective, with all the inherent limitations of this methodology. Further, the study included very few patients (N=13). However, this is reasonable as the incidence of orthopedic oncologic cases is much lower than traumatic cases where bone filler is more frequently used. The absence of a control or comparator group precludes any assessment of genex®’s effectiveness relative to autograft, allograft, or other substitutes. Follow-up attrition was also substantial: radiographic data were available for only six (resorption) and four (incorporation) patients at six months, and four and two patients, respectively, at one year, so the later estimates are based on very few patients and are susceptible to attrition bias. Another limitation was the limited long-term follow-up. Although most patients were followed for only about six months, this is reasonable, as this should be sufficient time to observe the soft tissue reactions mentioned by Friesenbichler et al., which ranged from seven to 52 days after the primary procedure [1]. Our series followed patients for up to a year, which is a reasonable follow-up period for genex®, as seen in other studies ranging from 36 weeks to two years [26,28]. Finally, X-ray in this study yielded relatively imprecise bone lesion measurements. Graft and defect volumes were approximated from two-dimensional radiographs using an ellipsoid estimation rather than measured volumetrically by CT, and formal interobserver reliability was not assessed; both constrain measurement precision. However, this was the best available technology with the least radiation exposure given the young age of this study population.

Conclusions

In conclusion, this preliminary case series suggests that genex® may be a feasible option for bone defect management after curettage of nonmalignant and low-grade malignant bone tumors. In this cohort, the material was associated with native bone regeneration and incorporation through controlled resorption at a desirable rate. Because of the small sample, substantial loss to follow-up, absence of a comparator group, and lack of functional outcomes, these data support an early feasibility observation rather than definitive conclusions regarding safety or efficacy. Larger comparative studies with longer, more complete follow-up and validated, functional outcome measures are warranted before firm conclusions about the safety and efficacy of genex® in orthopedic oncology can be drawn.

Additional Information

Author Contributions

All authors have reviewed the final version to be published and agreed to be accountable for all aspects of the work.

Concept and design: Davis T. Hedbany, Wyatt H. Buchalter, Timothy A. Damron

Acquisition, analysis, or interpretation of data: Davis T. Hedbany, Wyatt H. Buchalter, Christopher K. Johnson

Drafting of the manuscript: Davis T. Hedbany, Wyatt H. Buchalter

Critical review of the manuscript for important intellectual content: Timothy A. Damron, Christopher K. Johnson

Supervision: Timothy A. Damron

Disclosures

Human subjects: Informed consent for treatment and open access publication was obtained or waived by all participants in this study. Institutional Review Board, State University of New York (SUNY) Upstate Medical University issued approval #1819241; exemption category 4(iii). **Animal subjects:** All authors have confirmed that this study did not involve animal subjects or tissue. **Conflicts of interest:** In compliance with the ICMJE uniform disclosure form, all authors declare the following: **Payment/services info:** All authors have declared that no financial support was received from any organization for the submitted work. **Financial relationships:** All authors have declared that they have no financial relationships at present or within the previous three years with any organizations that might have an interest in the submitted work. **Other relationships:** All authors have declared that there are no other relationships or activities that could appear to have influenced the submitted work.

References

1. Friesenbichler J, Maurer-Ertl W, Sadoghi P, Pirker-Fruehauf U, Bodo K, Leithner A: Adverse reactions of artificial bone graft substitutes: lessons learned from using tricalcium phosphate geneX®. Clin Orthop Relat Res. 2014, 472:976-82. 10.1007/s11999-013-3305-z
2. Copley L, Dormans JP: Benign pediatric bone tumors. Evaluation and treatment. Pediatr Clin North Am. 1996, 43:949-66. 10.1016/s0031-3955(05)70444-2
3. Gava NF, Engel EE: Treatment alternatives and clinical outcomes of bone filling after benign tumour curettage. A systematic review. Orthop Traumatol Surg Res. 2022, 108:102966. 10.1016/j.otsr.2021.102966
4. Hirn M, de Silva U, Sidharthan S, Grimer RJ, Abudu A, Tillman RM, Carter SR: Bone defects following curettage do not necessarily need augmentation. Acta Orthop. 2009, 80:4-8. 10.1080/17453670902804505
5. Prosser GH, Baloch KG, Tillman RM, Carter SR, Grimer RJ: Does curettage without adjuvant therapy provide low recurrence rates in giant-cell tumors of bone?. Clin Orthop Relat Res. 2005, 211-18. 10.1097/01.blo.0000160024.06739.ff
6. Kundu ZS, Gupta V, Sangwan SS, Rana P: Curettage of benign bone tumors and tumor like lesions: a retrospective analysis. Indian J Orthop. 2013, 47:295-301. 10.4103/0019-5413.111507
7. Wang W, Yeung KWK: Bone grafts and biomaterials substitutes for bone defect repair: a review . Bioact Mater. 2017, 2:224-47. 10.1016/j.bioactmat.2017.05.007
8. Goldberg VM, Stevenson S: The biology of bone grafts . Semin Arthroplasty. 1993, 4:58-63. 10.1385/1-59259-863-3:057
9. Khan SN, Cammisa FP Jr, Sandhu HS, Diwan AD, Girardi FP, Lane JM: The biology of bone grafting . J Am Acad Orthop Surg. 2005, 13:77-86.
10. Roberts TT, Rosenbaum AJ: Bone grafts, bone substitutes and orthobiologics: the bridge between basic science and clinical advancements in fracture healing. Organogenesis. 2012, 8:114-24. 10.4161/org.23306
11. Chiarello E, Cadossi M, Tedesco G, Capra P, Calamelli C, Shehu A, Giannini S: Autograft, allograft and bone substitutes in reconstructive orthopedic surgery. Aging Clin Exp Res. 2013, 25 Suppl 1:S101-3. 10.1007/s40520-013-0088-8
12. Stevenson S, Horowitz M: The response to bone allografts . J Bone Joint Surg Am. 1992, 74:939-50.
13. Tomford WW: Transmission of disease through transplantation of musculoskeletal allografts . J Bone Joint Surg Am. 1995, 77:1742-54. 10.2106/00004623-199511000-00017
14. Zwingenberger S, Nich C, Valladares RD, Yao Z, Stiehler M, Goodman SB: Recommendations and considerations for the use of biologics in orthopedic surgery. BioDrugs. 2012, 26:245-56. 10.2165/11631680-000000000-00000
15. Fisher DM, Wong JM, Crowley C, Khan WS: Preclinical and clinical studies on the use of growth factors for bone repair: a systematic review. Curr Stem Cell Res Ther. 2013, 8:260-8. 10.2174/1574888x11308030011
16. genex® bone graft substitute. Zimmer Biomet . (2024). Accessed: January 13th, 2024: https://www.zimmerbiomet.com/en/products-and-solutions/specialties/foot-and-ankle/genex-bone-graft-substitute.html.
17. Evaniew N, Tan V, Parasu N, Jurriaans E, Finlay K, Deheshi B, Ghert M: Use of a calcium sulfate-calcium phosphate synthetic bone graft composite in the surgical management of primary bone tumors. Orthopedics. 2013, 36:e216-22. 10.3928/01477447-20130122-25
18. Orii H, Sotome S, Chen J, Wang J, Shinomiya K: Beta-tricalcium phosphate (beta-TCP) graft combined with bone marrow stromal cells (MSCs) for posterolateral spine fusion. J Med Dent Sci. 2005, 52:51-7.
19. Walsh WR, Morberg P, Yu Y, et al.: Response of a calcium sulfate bone graft substitute in a confined cancellous defect. Clin Orthop Relat Res. 2003, 228-36. 10.1097/01.blo.0000030062.92399.6a
20. Van Hoff C, Samora JB, Griesser MJ, Crist MK, Scharschmidt TJ, Mayerson JL: Effectiveness of ultraporous β-tricalcium phosphate (vitoss) as bone graft substitute for cavitary defects in benign and low-grade malignant bone tumors. Am J Orthop (Belle Mead NJ). 2012, 41:20-3.
21. Saadoun S, Macdonald C, Bell BA, Papadopoulos MC: Dangers of bone graft substitutes: lessons from using GeneX. J Neurol Neurosurg Psychiatry. 2011, 82:e3. 10.1136/jnnp.2010.232371
22. Ferguson J, Athanasou N, Diefenbeck M, McNally M: Radiographic and histological analysis of a synthetic bone graft substitute eluting gentamicin in the treatment of chronic osteomyelitis. J Bone Jt Infect. 2019, 4:76-84. 10.7150/jbji.31592
23. Sung TW, Lee ES, Kim OG, Heo KS, Shon WY: Usefulness of synthetic osteoconductive bone graft substitute with zeta potential control for intramedullary fixation with proximal femur nail antirotation in osteoporotic unstable femoral intertrochanteric fracture. Hip Pelvis. 2021, 33:211-18. 10.5371/hp.2021.33.4.211
24. Archunan MW, Petronis S: Bone grafts in trauma and orthopaedics . Cureus. 2021, 13:e17705. 10.7759/cureus.17705
25. Fernandez de Grado G, Keller L, Idoux-Gillet Y, et al.: Bone substitutes: a review of their characteristics, clinical use, and perspectives for large bone defects management. J Tissue Eng. 2018, 9:2041731418776819. 10.1177/2041731418776819
26. Yang HL, Zhu XS, Chen L, Chen CM, Mangham DC, Coulton LA, Aiken SS: Bone healing response to a

synthetic calcium sulfate/β-tricalcium phosphate graft material in a sheep vertebral body defect model. J Biomed Mater Res B Appl Biomater. 2012, 100:1911-21. 10.1002/jbm.b.32758

27. Ricci J, Weiner M, Di Iorio D, Mamidwar S, Alexander H: Evaluation of timed release calcium sulfate (CS-TR) bone graft substitutes. Microsc Microanal. 2005, 11:1256-7. 10.1017/S1431927605506585
28. Razii N, Docherty LM, Halai M, Mahendra A, Gupta S: Injectable synthetic beta-tricalcium phosphate/calcium sulfate (genex) for the management of contained defects following curettage of benign bone tumours. Curr Oncol. 2023, 30:3697-707. 10.3390/curroncol30040281
29. Kotnis NA, Parasu N, Finlay K, Jurriaans E, Ghert M: Chronology of the radiographic appearances of the calcium sulphate-calcium phosphate synthetic bone graft composite following resection of bone tumours - a preliminary study of the normal post-operative appearances. Skeletal Radiol. 2011, 40:563-70. 10.1007/s00256-010-1037-7
30. Friesenbichler J, Maurer-Ertl W, Sadoghi P, Pirker-Fruehauf U, Bodo K, Leithner A: Reply to the letter to the editor: adverse reactions of artificial bone graft substitutes: lessons learned from using tricalcium phosphate geneX ®. Clin Orthop Relat Res. 2014, 472:767-8. 10.1007/s11999-013-3421-9