Cureus

Open Access Original Article

DOI: 10.7759/cureus.48867

The Effect of Acromioplasty Performed During Rotator Cuff Repairs on Clinical Outcomes in Patients With Type 3 Acromion: A Retrospective Study

Review began 10/23/2023
Review ended 11/12/2023
Published 11/15/2023

© Copyright 2023
Özcan et al. This is an open access article distributed under the terms of the Creative Commons Attribution License CC-BY 4.0., which permits unrestricted use, distribution, and reproduction in any medium, provided the original author and source are credited.

Seçkin Özcan [1] , Hakan Yurten [2]

1. Orthopedics and Traumatology, Yalova Education and Research Hospital, Yalova, TUR 2. Orthopedics and Traumatology, Ministry of Health Elazığ Fethî Sekîn City Hospital, Elazığ, TUR

Corresponding author: Seçkin Özcan, seckinozcan1301@gmail.com

Abstract

Objective: Rotator cuff (RC) tears often necessitate surgery, with acromioplasty being frequently performed alongside RC repair. However, the impact of acromioplasty on clinical outcomes remains a subject of discussion. The current study aimed to investigate the effect of acromioplasty during RC repair on clinical outcomes in patients with type 3 acromion.

Materials and methods: Eighty-five patients, who underwent RC repair between January 2016 and December 2020, were categorized into two groups: Group 1, comprising 40 patients without acromioplasty, and Group 2, including 45 patients who received acromioplasty. Subacromial distance (SAD) and clinical scores were assessed pre- and post-operatively.

Results: Group 1, comprising 40 patients without acromioplasty, had an average age of 59.45±10.43 years. Among them, 27 (67.5%) were female. The mean symptom duration was 10.4±4.3 months, and the mean follow-up period was 16.2±1.9 months. Group 2, which underwent acromioplasty, included 45 patients with an average age of 56.49±8.97 years, with 30 (66.7%) of them being female. The mean symptom duration was 9.5±3.6 months, and the mean follow-up time was 15.78±2.17 months in this group. Group 2 showed a relatively greater improvement in SAD compared to Group 1. The evaluation of clinical outcomes did not reveal any significant differences between the groups.

Conclusion: Concomitant acromioplasty does not have a significant effect on clinical outcomes in patients undergoing arthroscopic RC repair.

Categories: Orthopedics, Trauma, Sports Medicine
Keywords: impingement, type 3 acromion, subacromial distance, rotator cuff, acromioplasty

Introduction

Rotator cuff tears (RCTs) are frequently encountered by orthopaedic surgeons, driven by an increase in physically active elderly individuals and extended life expectancy [1-3]. While affecting approximately 30% of the population aged 60 and older, the incidence of RCTs rises with advancing age [4]. When planning the treatment for RCTs, factors such as tear location, size, associated lesions, and etiological considerations are taken into consideration. With the growing number of RC repair surgeries, numerous studies have been conducted to explore the etiological factors [1-4].

Until recently, extrinsic factors were emphasized as contributors to RCT. These factors such as the anatomical shape of the acromion or the subacromial spur were thought to restrict the movements of the rotator muscles by narrowing the subacromial space, thus resulting in subacromial pain syndrome and RCT. For this reason, it has become increasingly common to perform acromioplasty with RC repair to address these factors by enlarging the subacromial space [1,2,5]. However, contemporary research suggests that extrinsic factors may not have a significant effect as previously claimed. Current studies have shifted their focus more toward intrinsic etiological factors [6]. It is thought that the accumulation of any damage within the tendon reduces its resistance, particularly against eccentric forces, ultimately leading to RCT. These studies advocated that acromioplasty may not yield meaningful improvements in clinical outcomes [6,7].

There is a dynamic relationship between the RCT and the subacromial distance (SAD), which is determined by measuring the distance between the lower border of the acromion and the humeral head. A narrow SAD is believed to contribute to RCT. When the RC is damaged, its compressive effect on the humeral head diminishes, causing superior migration of the humeral head and reduction in SAD [8,9]. This study aimed to investigate the impact of acromioplasty in patients with type 3 acromion who have undergone arthroscopic RC repair. Our hypothesis posits that acromioplasty may not significantly affect the clinical outcomes of

arthroscopic RC repair in patients with full-thickness RCT and type 3 acromion.

Materials And Methods

Study population

This retrospective case-control study was approved by our institution's ethical review board and conducted in accordance with the Declaration of Helsinki. Patients with type 3 acromion, whose diagnosis of full-thickness RCT was confirmed clinically and radiologically and who underwent arthroscopic repair between January 2016 and December 2020 were included in the study (Figure *1*).



FIGURE 1: Magnetic resonance images of RCT and type 3 acromion.

RCT: Rotator cuff tear

A total of 96 patients received treatment within this timeframe. Exclusion criteria encompassed incomplete follow-up or inadequate medical records (n:5), partial-thickness or irreparable full-thickness RCTs (Patte Classification Stage 3 or Goutallier Classification Grade ⩾3) (n:4), and history of upper extremity surgery or fracture (n:2). Patients who had a full-thickness RCT but required secondary repair, such as those with a tear in the subscapularis muscle or a slap lesion were also excluded. Eighty-five patients (28 males, 57 females) included in our study were categorized into two groups: Group 1, comprising 40 patients without acromioplasty, and Group 2, which included 45 patients who received acromioplasty.

Surgical technique

All patients received comprehensive pre-surgical information and provided informed consent. Two senior surgeons in our department performed all procedures simultaneously, with patients positioned in the lateral decubitus position. Standard glenohumeral and subacromial arthroscopy was performed. In Group 2, following arthroscopic RC repair, the arthroscope was inserted from the standard posterior portal. Acromioplasty was performed with a burr placed from the lateral portal, creating a smooth surface at the posterior part of the acromion and deepening by 0.5 cm at the anterior end (Figure *2*).

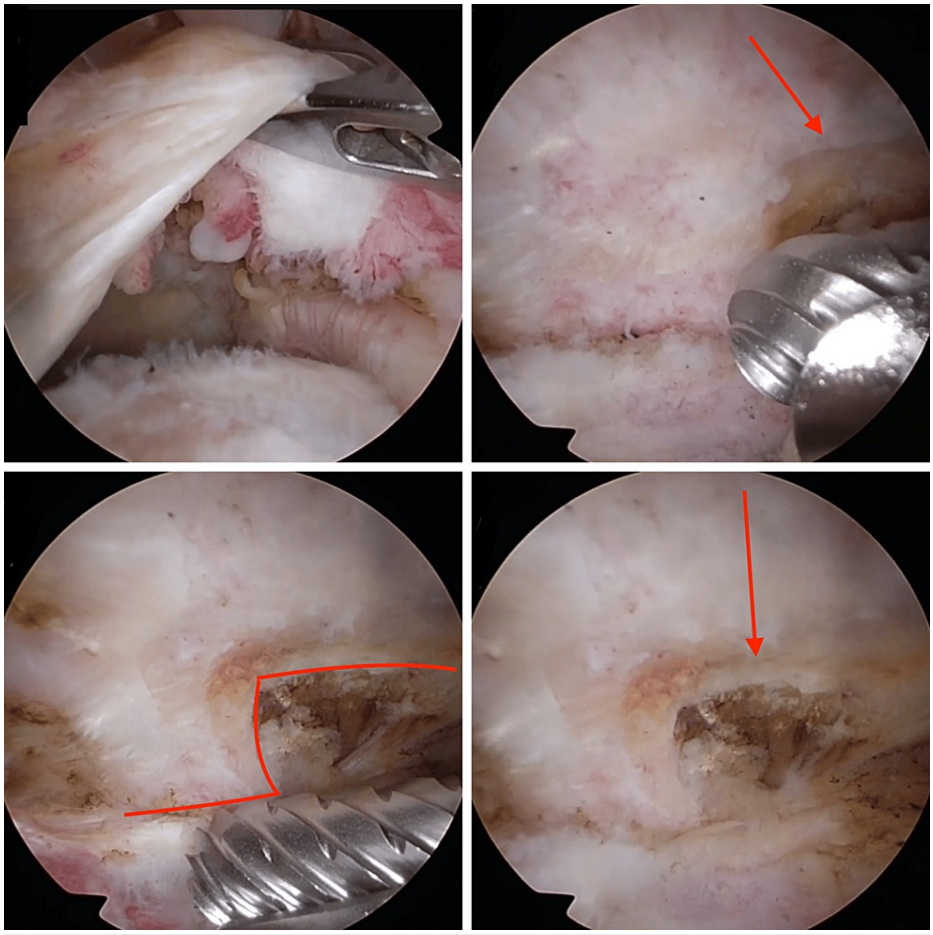

FIGURE 2: Arthroscopic images from the acromioplasty procedure

All patients initiated passive shoulder motion and pendulum exercises one week after the surgery. This practice was continued for the postoperative initial six-week period. After this first six-week period, a standard physical therapy program was implemented, including more aggressive passive and active shoulder movements and muscle strengthening. Patients were regularly called to the outpatient clinic for follow-up visits and their physical examinations were repeated. All patients were compliant with follow-up and physical therapy programs.

Data collection

Patients were evaluated for functional and clinical outcomes at preoperative and 12-month postoperative. All patients were evaluated by the same surgeon during the preoperative and postoperative periods. At the time of initial admission, patient data including age, gender, and symptom duration (in months) were recorded. SAD measurements, both in sagittal (sSAD) and coronal (cSAD) planes, were conducted using MRI by an observer who had experience in evaluating musculoskeletal system images. Shoulder range of motion (ROM) measurements, visual analogue scale (VAS) score, the Disability of Arm and Shoulder (Quick DASH) score, and the American Shoulder and Elbow Surgeons (ASES) score were assessed for each patient upon their initial admission and again at the first year postoperative follow-up.

Statistical analyses

Continuous variables are reported as mean± standard deviation, as well as median and interquartile range (IQR) values, while categorical variables are presented as frequencies and percentages. The Shapiro-Wilk test was used to assess the normal distribution of continuous variables. In group comparisons, variables with normal distribution were analyzed using the independent two-sample t-tests, while the variables without normal distribution were analyzed using the Mann-Whitney U test. The analysis of categorical variable ratios was conducted utilizing the chi-square test. Additionally, the Wilcoxon signed-rank test was used to scrutinize the differences between repeated measurements.

A p-value of <0.05 was considered statistically significant in all analyses. Statistical Package for the Social Sciences (IBM SPSS Statistics for Windows, IBM Corp., Version 21, Armonk, NY) and NCSS v.21.0.3 (NCSS, LLC, Kaysville, UT, USA) software were used in the analyses.

Results

Group 1, comprising 40 patients without acromioplasty, had an average age of 59.45±10.43 years. Among them, 27 (67.5%) were female. The 12 patients had comorbidities. These diseases were as follows: diabetes mellitus (n: 4), hypertension (n: 3), hypothyroidism (n: 3), and coronary artery disease (n: 2). The mean symptom duration was 10.4±4.3 months, and the mean follow-up period was 16.2±1.9 months. Group 2, which underwent acromioplasty, included 45 patients with an average age of 56.49±8.97 years, with 30 (66.7%) of them being female. The 11 patients had comorbidities. These diseases were as follows: diabetes mellitus (n: 5), hypertension (n: 2), hypothyroidism (n: 2), and coronary artery disease (n: 2). The mean symptom duration was 9.5±3.6 months, and the mean follow-up time was 15.78±2.17 months in this group.

The mean preoperative abduction degrees were 79.25±13.08 and 84.89± 15.9 in Group 1 and Group 2, respectively. At the final follow-up, these angles were 114.75±16.01 and 115.78±13.56 for Group 1 and Group 2, respectively. While other ROM values improved significantly after surgery, there was no statistical difference between the two groups. At the first-year follow-up, both groups showed a significant decrease in mean VAS and Quick DASH scores, along with a significant increase in the mean ASES score. However, the differences in the mean clinical scores were not significant between the groups. In both groups, postoperative cSAD and sSAD values showed a statistically significant increase compared to the preoperative values. Notably, the improvement in cSAD and sSAD values in Group 2 showed a statistically significant difference compared to Group 1 (Tables *1*, *2*).

Group 1					**Group 2**			
	Preoperative	Postoperative			Preoperative	Postoperative		
	Mean ± SD	Mean ± SD	Change (%)	p	Mean ± SD	Mean ± SD	Change (%)	p
Flexion	144.75 ± 11.98	155.50 ± 9.594	7,427	<0.001	141.56 ± 10.435	153.78 ± 6.839	8,632	<0.001
Internal Rotation	44.25 ± 11.068	58.75 ± 7.574	32,768	<0.001	45.33 ± 10.135	60 ± 6.030	32,363	<0.001
External Rotation	54.5 ± 12.999	67.25 ± 12.401	23,395	<0.001	56.22 ± 12.301	68.67 ± 8.944	22,145	<0.001
Abduction	79.25 ± 13.085	114.75 ± 16.011	44,795	<0.001	84.89 ± 15.901	115.78 ± 13.566	36,388	<0.001
VAS	6.988 ± 0.537	1.15 ± 0.427	83.543	<0.001	6.899 ± 0.411	1.122 ± 0.372	83,737	<0.001
Quick DASH	59.376 ± 5.571	21.463 ± 2.667	63,852	<0.001	57.554 ± 5.519	20.864 ± 2.639	63,749	<0.001
ASES	21.395 ± 2.34	38.243 ± 2.939	78,747	<0.001	21.709 ± 1.944	38.589 ± 2.385	77,757	<0.001
Coronal SAD	6.133 ± 0.784	6.488 ± 0.632	5.79	<0.001	6.198 ± 0.774	6.984 ± 0.564	12.69	<0.001
Sagittal SAD	6.148 ± 0.774	6.415 ± 0.604	4.34	<0.001	6.216 ± 0.778	6.904 ± 0.570	11.07	<0.001

TABLE 1: Range of motion, clinical scores and radiological measurements of Groups 1 and 2

VAS: Visual analog scale, DASH: Disability of Arm and Shoulder, ASES: American Shoulder and Elbow Surgeons, SAD: Sub-acromial distance

	Preoperative			Postoperative		
	Group 1	Group 2		Group 1	Group 2	
	Mean ± SD	Mean ± SD	p	Mean ± SD	Mean ± SD	p
Flexion	144.75 ± 11.98	141.56 ± 10.435	0.240	155.50 ± 9.594	153.78 ± 6.839	0.336
Internal Rotation	44.25 ± 11.068	45.33 ± 10.135	0.459	58.75 ± 7.574	60 ± 6.030	0.367
External Rotation	54.5 ± 12.999	56.22 ± 12.301	0.326	67.25 ± 12.401	68.67 ± 8.944	0.357
Abduction	79.25 ± 13.085	84.89 ± 15.901	0.085	114.75 ± 16.011	115.78 ± 13.566	0.755
VAS	6.988 ± 0.537	6.899 ± 0.411	0.337	1.15 ± 0.427	1.122 ± 0.372	0.581
Quick DASH	59.376 ± 5.571	57.554 ± 5.519	0.022	21.463 ± 2.667	20.864 ± 2.639	0.295
ASES	21.395 ± 2.34	21.709 ± 1.944	0.351	38.243 ± 2.939	38.589 ± 2.385	0.551
Coronal SAD	6.133 ± 0.784	6.198 ± 0.774	0.548	6.488 ± 0.632	6.984 ± 0.564	0.337
Sagittal SAD	6.148 ± 0.774	6.216 ± 0.778	0.488	6.415 ± 0.604	6.904 ± 0.570	0.867

TABLE 2: Range of motion, clinical scores and radiological measurements in preoperative and postoperative periods

VAS: Visual analog scale, DASH: Disability of Arm and Shoulder, ASES: American Shoulder and Elbow Surgeons, SAD: Sub-acromial distance

Discussion

In the current study, we observed significant improvements in the clinical outcomes of patients undergoing arthroscopic RC repair, irrespective of whether acromioplasty was performed. While patients who received acromioplasty during RC repair demonstrated greater radiological improvement, there was no additional clinical benefit observed in this cohort.

RC syndrome is one of the common problems in orthopaedics and traumatology, with a growing global incidence [4,10]. Factors such as age, comorbid diseases, activity levels, and smoking are among the known risk factors for RC tears [4]. However, the relationship between acromion and glenoid morphology and RCTs, as well as their role in treatment, remains a topic of discussion in the literature [4,11-13]. Notably, Bigliani et al. reported a high incidence of RCTs in individuals with a hooked (type 3) acromion structure [14].

Subacromial pain syndrome and RC tears are thought to be associated with a reduction in the subacromial space [15,16]. Therefore, some have advocated for the routine inclusion of acromioplasty during RC repair procedures to increase this space [15]. Cheng et al. stated that the pain and ASES scores in patients who underwent acromioplasty were superior compared to those who underwent RC repair alone in a one-year follow-up study [16]. Similarly, another study indicated that individuals with type 3 acromion had poorer Constant, Simple Shoulder Test (SST), and VAS scores when compared to those with type 1 acromion [17]. Several studies have suggested that ROM may improve more significantly in patients who undergo acromioplasty for RCTs. Furthermore, there is an argument that performing acromioplasty may reduce the risk of RC re-injury [18]. In their study with an average follow-up of 11 years, Woodmass et al. reported higher reoperation rates among patients with types 2-3 acromion who had only undergone RC repair compared to those who had both RC repair and acromioplasty [19].

The necessity of acromioplasty has been a matter of debate in recent years. Singh et al. published a study in 2021 that found no significant difference between groups based on whether acromioplasty was performed or not [6]. Gartsman and O'Connor showed that acromioplasty did not provide any superiority in functional outcomes in individuals with full-thickness RC tears and type 2 acromions [20]. Similarly, Shin et al. demonstrated that acromioplasty had no effect on clinical outcomes [5]. In a study by Waterman et al. conducted after 7.5 years of follow-up, acromioplasty performed during RC repair showed no effect on clinical scores and revision rates [21]. Another study even indicated that concurrent acromioplasty with RC repair was associated with an increased rate of revision [22]. In Kolk et al.'s study, the researchers found no significant difference between the group that underwent only bursectomy and the group that underwent bursectomy and acromioplasty in patients operated on for subacromial pain syndrome, after an average of 12 years of follow-up [23].

SAD, also known as acromiohumeral distance, refers to the shortest distance between the undersurface

cortex of the acromion and the top of the humeral head on a Grashey radiograph [24]. While this measurement was initially defined using radiography, it can now be obtained using ultrasound (USG) and MRI. The most critical difference between radiography and other measurement techniques lies in the patient's position. Discussions regarding the impact of the dorsal decubitus position on MRI measurements and its potential alteration of results due to reduced gravitational effects continue in the literature [24]. In a study conducted by Mirzayan et al., it was stated that the SAD value was significantly smaller in MRI compared to AP radiographs in patients with RCT arthropathy [25]. Another study evaluating the relationship between RC injury and the elevation of the humeral head revealed that MRI evaluations remained unaffected by gravitational force, with the main factors being the size and shape of the tear as well as accompanying lesions [9].

Limitations of the study

This study had some limitations, most importantly its retrospective nature. The inclusion of only type 3 acromion patients restricted the sample size, and longer follow-up periods are necessary to assess reoperation rates for these individuals. On the other hand, the study's strength lies in its more objective evaluation, as it exclusively included patients with type 3 acromion and no additional pathologies, such as subscapularis tears. Unlike many similar studies employing different imaging modalities for measurements, this study exclusively utilized MRI.

Conclusions

Our study exclusively included patients with type 3 acromion and evaluated the pre- and post-operative SAD values using MRI. While SAD increased in all patients undergoing RC repair, the acromioplasty group exhibited a greater increase. However, this did not translate into superior clinical outcomes. In conclusion, we observed significant improvements in the clinical outcomes of patients undergoing arthroscopic RC repair, irrespective of whether acromioplasty was performed. Although SAD increased in all RC repair patients, the acromioplasty group demonstrated a more substantial increase. While patients who received acromioplasty during RC repair demonstrated greater radiological improvement, concomitant acromioplasty had no significant effect on clinical outcomes.

Additional Information

Author Contributions

All authors have reviewed the final version to be published and agreed to be accountable for all aspects of the work.

Concept and design: Seçkin Özcan, Hakan Yurten

Acquisition, analysis, or interpretation of data: Seçkin Özcan, Hakan Yurten

Drafting of the manuscript: Seçkin Özcan, Hakan Yurten

Critical review of the manuscript for important intellectual content: Seçkin Özcan, Hakan Yurten

Supervision: Seçkin Özcan, Hakan Yurten

Disclosures

Human subjects: Consent was obtained or waived by all participants in this study. Institutional Committee of Yalova University issued approval 2023/74. The study was conducted in strict accordance with the Declaration of Helsinki and approved by the Institutional Committee of Yalova University (protocol code: 2023/74, date: May 08, 2023). **Animal subjects:** All authors have confirmed that this study did not involve animal subjects or tissue. **Conflicts of interest:** In compliance with the ICMJE uniform disclosure form, all authors declare the following: **Payment/services info:** All authors have declared that no financial support was received from any organization for the submitted work. **Financial relationships:** All authors have declared that they have no financial relationships at present or within the previous three years with any organizations that might have an interest in the submitted work. **Other relationships:** All authors have declared that there are no other relationships or activities that could appear to have influenced the submitted work.

References

1. Consigliere P, Haddo O, Levy O, Sforza G: Subacromial impingement syndrome: management challenges . Orthop Res Rev. 2018, 10:83-91. 10.2147/ORR.S157864
2. Frank JM, Chahal J, Frank RM, Cole BJ, Verma NN, Romeo AA: The role of acromioplasty for rotator cuff problems. Orthop Clin North Am. 2014, 45:219-24. 10.1016/j.ocl.2013.12.003
3. He S, Xu H, Liu S: Effect of arthroscopic acromioplasty combined with rotator cuff repair in the treatment of aged patients with full-thickness rotator cuff tear and rotator cuff injury. Emerg Med Int. 2022,

2022:4475087. 10.1155/2022/4475087

4. Garibaldi R, Altomare D, Sconza C, et al.: Conservative management vs. surgical repair in degenerative rotator cuff tears: a systematic review and meta-analysis. Eur Rev Med Pharmacol Sci. 2021, 25:609-19. 10.26355/eurrev_202101_24619
5. Shin SJ, Oh JH, Chung SW, Song MH: The efficacy of acromioplasty in the arthroscopic repair of small- to medium-sized rotator cuff tears without acromial spur: prospective comparative study. Arthroscopy. 2012, 28:628-35. 10.1016/j.arthro.2011.10.016
6. Singh C, Lam PH, Murrell GA: Effect of acromioplasty on postoperative pain following rotator cuff repair . HSS J. 2021, 17:150-7. 10.1177/1556331621993123
7. Lavignac P, Lacroix PM, Billaud A: Quantification of acromioplasty. Systematic review of the literature . Orthop Traumatol Surg Res. 2021, 107:102900. 10.1016/j.otsr.2021.102900
8. Lädermann A, Chagué S, Preissmann D, et al.: Acromioplasty during repair of rotator cuff tears removes only half of the impinging acromial bone. JSES Int. 2020, 4:592-600. 10.1016/j.jseint.2020.03.009
9. de Oliveira França F, Godinho AC, Ribeiro EJ, Falster L, Búrigo LE, Nunes RB: Evaluation of the acromiohumeral distance by means of magnetic resonance imaging umerus. Rev Bras Ortop. 2016, 51:169-74. 10.1016/j.rboe.2016.01.008
10. Malavolta EA, Assunção JH, Andrade-Silva FB, Gracitelli ME, Kiyomoto HD, Ferreira Neto AA: Prognostic factors for clinical outcomes after arthroscopic rotator cuff repair. Orthop J Sports Med. 2023, 11:23259671231160738. 10.1177/23259671231160738
11. Longo UG, Petrillo S, Candela V, Rizzello G, Loppini M, Maffulli N, Denaro V: Arthroscopic rotator cuff repair with and without subacromial decompression is safe and effective: a clinical study. BMC Musculoskelet Disord. 2020, 21:24. 10.1186/s12891-019-3032-z
12. Franceschetti E, Giovannetti de Sanctis E, Palumbo A, et al.: Lateral acromioplasty has a positive impact on rotator cuff repair in patients with a critical shoulder angle greater than 35 degrees. J Clin Med. 2020, 9:3950. 10.3390/jcm9123950
13. Surucu S, Aydin M: Are differences in shoulder morphology and hand dominance risk factors for rotator cuff tears?. Eur Rev Med Pharmacol Sci. 2022, 26:1565-9. 10.26355/eurrev_202203_28222
14. Bigliani LU, Morrison DS, April EW: The morphology of the acromion and its relationship to rotator cuff tears. Ortho Trans. 1986, 10:228-10.
15. Sayampanathan AA, Silva AN, Hwee Chye AT: Rotator cuff repairs with and without acromioplasties yield similar clinical outcomes: a meta-analysis and systematic review. Arthroscopy. 2021, 37:1950-7. 10.1016/j.arthro.2021.01.025
16. Cheng C, Chen B, Xu H, Zhang Z, Xu W: Efficacy of concomitant acromioplasty in the treatment of rotator cuff tears: a systematic review and meta-analysis. PLoS One. 2018, 13:e0207306. 10.1371/journal.pone.0207306
17. Abrams GD, Gupta AK, Hussey KE, et al.: Arthroscopic repair of full-thickness rotator cuff tears with and without acromioplasty: randomized prospective trial with 2-year follow-up. Am J Sports Med. 2014, 42:1296-303. 10.1177/0363546514529091
18. MacDonald P, McRae S, Leiter J, Mascarenhas R, Lapner P: Arthroscopic rotator cuff repair with and without acromioplasty in the treatment of full-thickness rotator cuff tears: a multicenter, randomized controlled trial. J Bone Joint Surg Am. 2011, 93:1953-60. 10.2106/JBJS.K.00488
19. Woodmass JM, Al Khatib L, McRae S, Lapner P, Mascarenhas R, Neogi D, MacDonald PB: Arthroscopic rotator cuff repair with and without acromioplasty in the treatment of full-thickness rotator cuff tears: long-term outcomes of a multicenter, randomized controlled trial. J Bone Joint Surg Am. 2022, 104:2101-7. 10.2106/JBJS.22.00135
20. Gartsman GM, O'connor DP: Arthroscopic rotator cuff repair with and without arthroscopic subacromial decompression: a prospective, randomized study of one-year outcomes. J Shoulder Elbow Surg. 2004, 13:424-6. 10.1016/j.jse.2004.02.006
21. Waterman BR, Newgren J, Gowd AK, et al.: Randomized trial of arthroscopic rotator cuff with or without acromioplasty: no difference in patient-reported outcomes at long-term follow-up. Arthroscopy. 2021, 37:3072-8. 10.1016/j.arthro.2021.04.041
22. Swindell HW, Kang HP, Mueller JD, et al.: Rotator cuff repair with acromioplasty is associated with an increased rate of revision and subsequent procedures. Arthrosc Sports Med Rehabil. 2022, 4:e2065-71. 10.1016/j.asmr.2022.09.008
23. Kolk A, Thomassen BJ, Hund H, et al.: Does acromioplasty result in favorable clinical and radiologic outcomes in the management of chronic subacromial pain syndrome? A double-blinded randomized clinical trial with 9 to 14 years' follow-up. J Shoulder Elbow Surg. 2017, 26:1407-15. 10.1016/j.jse.2017.03.021
24. Hufeland M, Brusis C, Kubo H, Grassmann J, Latz D, Patzer T: The acromiohumeral distance in the MRI should not be used as a decision criterion to assess subacromial space width in shoulders with an intact rotator cuff. Knee Surg Sports Traumatol Arthrosc. 2021, 29:2085-9. 10.1007/s00167-020-06090-6
25. Mirzayan R, Donohoe S, Batech M, Suh BD, Acevedo DC, Singh A: Is there a difference in the acromiohumeral distances measured on radiographic and magnetic resonance images of the same shoulder with a massive rotator cuff tear?. J Shoulder Elbow Surg. 2020, 29:1145-51. 10.1016/j.jse.2019.10.020