

COVID-19-Associated Pulmonary Aspergillosis in a Patient Treated With Remdesivir, Dexamethasone, and Baricitinib: A Case Report

Review began 03/15/2022
Review ended 03/30/2022
Published 04/02/2022

© Copyright 2022
Shimada et al. This is an open access article distributed under the terms of the Creative Commons Attribution License CC-BY 4.0., which permits unrestricted use, distribution, and reproduction in any medium, provided the original author and source are credited.

Ayako Shimada¹, Shinnosuke Ohnaka¹, Kosumi Kubo¹, Masanao Nakashima¹, Atsushi Nagai¹

¹. Department of Respiratory Medicine, Shin-Yurigaoka General Hospital, Kanagawa, JPN

Corresponding author: Ayako Shimada, romanholiday52@yahoo.co.jp

Abstract

Remdesivir, dexamethasone, and baricitinib have recently been used to treat patients with coronavirus disease 2019 (COVID-19) and respiratory failure. However, the adverse effects of combination therapy have not been fully explored. A 64-year-old man was diagnosed with COVID-19 and was treated with remdesivir, dexamethasone, and baricitinib. His respiratory condition worsened on day 17, and in the following days, he was diagnosed with pneumomediastinum and COVID-19-associated pulmonary aspergillosis (CAPA). His condition improved with a reduction in the corticosteroid regime and antifungal treatment. This is the first case of pulmonary aspergillosis in a patient with COVID-19 that was treated with remdesivir, dexamethasone, and baricitinib.

Categories: Radiology, Infectious Disease, Pulmonology

Keywords: jak inhibitor, baricitinib, pulmonary aspergillosis, respiratory failure, covid-19

Introduction

Secondary infections (superinfections) are known complications of the coronavirus disease 2019 (COVID-19) [1]. COVID-19-associated pulmonary aspergillosis (CAPA) is an infectious complication that has been increasingly reported worldwide. A systematic review of CAPA in critical or intensive care unit (ICU)-treated COVID-19 patients has reported the incidence and mortality to be 10.2% and 54.9%, respectively. However, the incidence varies widely among reports [2], and the high mortality rate highlights the importance of early diagnosis and adequate treatment of *Aspergillus* infection. Several factors, including viral-associated airway epithelial cell injury, immunosuppression caused by corticosteroids or other immunomodulatory drug use, host immunodeficiency, and temporary facilities with inadequate room ventilation, are considered risk factors for CAPA [3-5].

However, it is important to control the hyperinflammatory state in patients with COVID-19 and acute respiratory failure or multiple organ dysfunction. Drugs such as dexamethasone and baricitinib, selective Janus kinase (JAK) inhibitors, are effective in COVID-19 patients who require oxygen therapy or mechanical ventilation [6-8]. Although randomized trials of baricitinib with the standard of care, including corticosteroids, showed no differences in infectious complications [8], there is still little information on the complications of immunomodulatory combinations in COVID-19 patients.

Herein, we present the first report of a case of a patient who developed pulmonary aspergillosis during remdesivir, dexamethasone, and baricitinib therapy for COVID-19.

Case Presentation

A 64-year-old man with fever and dyspnea was admitted to our hospital in November 2021. The patient was symptomatic three days before admission and was diagnosed with COVID-19 based on the antigen test for severe acute respiratory syndrome coronavirus 2 (SARS-CoV-2) the day before. The patient had untreated hypertension and diabetes mellitus (DM). He had a 40 pack-year history of smoking; however, he had quit smoking 20 years ago. On admission, his body mass index was 29.7 (bodyweight, 92 kg), body temperature was 36.9 °C, respiratory rate was 24 breaths/min, and oxygen saturation in room air was 88%. His breath sounds were normal on auscultation, and physical examination results were unremarkable. Chest computed tomography (CT) revealed diffuse bilateral ground-glass opacities (chest CT severity score: 20 [9]) (Figure 1).

How to cite this article

Shimada A, Ohnaka S, Kubo K, et al. (April 02, 2022) COVID-19-Associated Pulmonary Aspergillosis in a Patient Treated With Remdesivir, Dexamethasone, and Baricitinib: A Case Report. *Cureus* 14(4): e23755. DOI 10.7759/cureus.23755

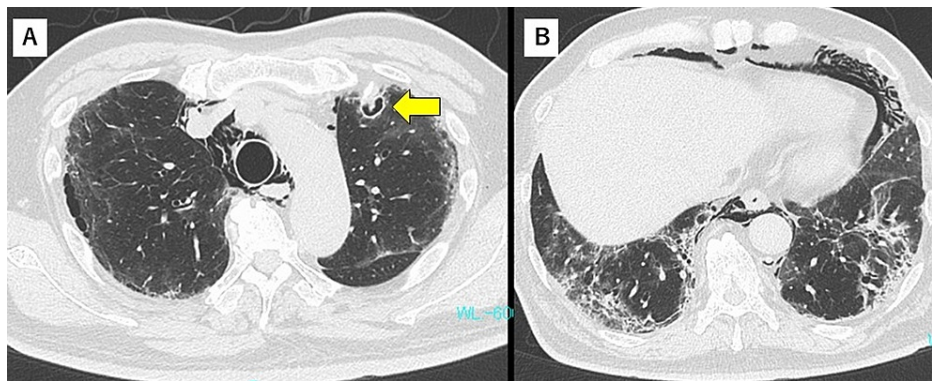


FIGURE 3: Chest CT findings on day 19

(A) Cavity seen with a small nodule in the left upper lobe (arrow). (B) Pneumomediastinum and fibrosis in lower lungs.

CAPA was suspected, and intravenous administration of voriconazole (at a loading dose of 500mg twice daily on day one, followed by 300mg twice daily on days 2 to 7) was initiated. The serum β -D-glucan test result was positive, and sputum cytology revealed fungal filaments. Serum antigen and sputum cultures were negative for *Aspergillus*. With rest and corticosteroid tapering, pneumomediastinum improved. Voriconazole-induced acute liver dysfunction was observed on day 26, and the antifungal drug was switched to amphotericin B (300mg once daily, intravenously). On day 34, amphotericin B was switched to itraconazole (200mg twice daily, orally) because of hypokalemia (minimum 2.3mEq/L). The cavity enlarged on the follow-up CT, which was done on day 26 (Figure 4).

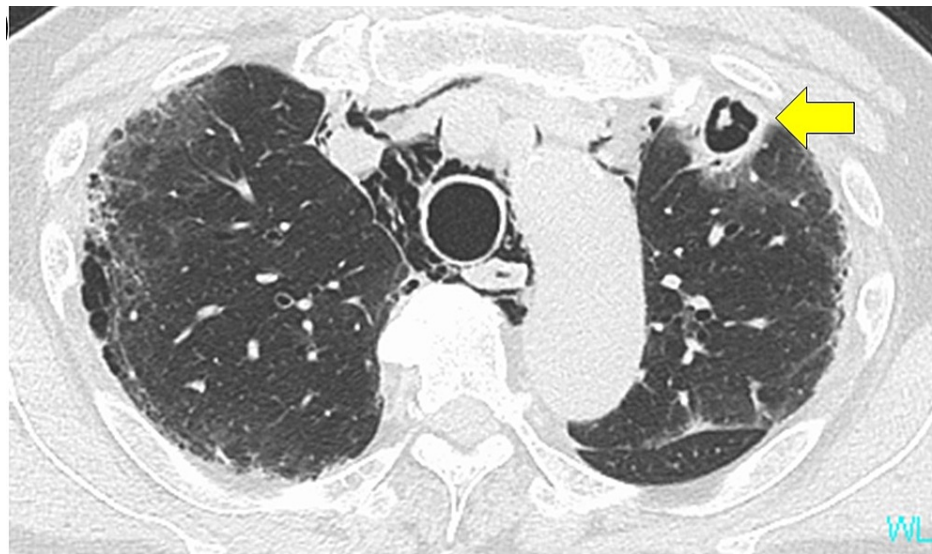

FIGURE 4: Chest CT findings on day 26

Cavity in the upper lobe enlarged (arrow).

However, CT scan images before discharge showed a reduction in the cavitory lung lesion (Figure 5).

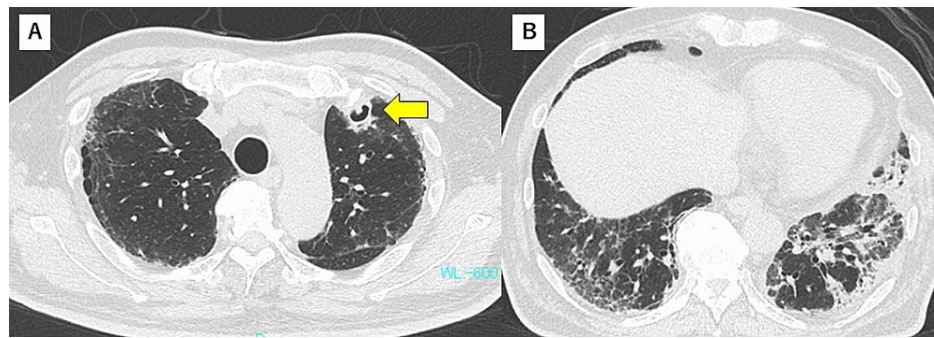


FIGURE 5: Chest CT findings on day 42

(A) Gradual improvement of the cavity was observed (arrow). (B) Lung fibrosis improved with partial lung shrinkage.

The patient's respiratory condition and electrolyte abnormalities gradually improved, and he was discharged from the hospital on day 46.

Discussion

To the best of our knowledge, this is the first report of CAPA in a patient treated with a combination of remdesivir, dexamethasone, and baricitinib.

Pulmonary aspergillosis is often difficult to diagnose in critically ill patients because radiological changes are nonspecific, and serum galactomannan (GM) has low sensitivity. Moreover, the gold standard for obtaining mycological evidence of invasive diseases is bronchoscopy, which is often avoided to protect healthcare workers from aerosol exposure. The consensus definition for CAPA has been proposed by the European Respiratory Society (ERS) and the European Confederation for Medical Mycology, International Society for Human and Animal Mycology [10,11]. To avoid an overestimation of CAPA due to *Aspergillus* contamination or colonization, both criteria suggest bronchoalveolar lavage (BAL) or non-bronchoscopic lavage acquire positive results for *Aspergillus* culture or GM. However, due to the high mortality rate of CAPA, these two criteria propose active screening for CAPA. In the ERS criteria, when BAL is not possible, the presence of at least one serum biomarker, such as *Aspergillus* antigen, polymerase chain reaction, or β -D-glucan positivity, indicates CAPA.

In our report, the patient's chest CT images showed a cavitory lesion, which is a classical finding of invasive aspergillosis. His sputum culture was negative for *Aspergillus*; however, it showed microscopic fungal elements, and his serum β -D-glucan test was positive. The BAL specimen was not collected because the patient had a severe respiratory failure due to pneumomediastinum at the onset of putative CAPA. The cavitory lesion on chest CT and β -D-glucan test values both showed improvement after antifungal treatment, which supports the diagnosis of CAPA. Our patient had diabetes mellitus and severe respiratory distress and was treated with high-dose corticosteroids, all of which can be risk factors for *Aspergillus* infection. It was quite difficult to assess the involvement of baricitinib in the present case.

Baricitinib inhibits the JAK-STAT pathway, downregulates multiple inflammatory cytokines, and inhibits viral entry via the AAK1 receptor [12]. The COV-BARRIER study showed that treatment with baricitinib, in addition to the standard of care (including dexamethasone), reduced mortality [8]. In Japan, this regimen was approved for the treatment of COVID-19 patients with respiratory failure in April 2021. Since then, triple therapy with remdesivir, dexamethasone, and baricitinib has been widely used in Japan [13]. Although the COV-BARRIER study reported that baricitinib-added therapy did not increase serious infections, there are still concerns that JAK inhibitors increase the incidence of CAPA when used with corticosteroids. In vitro and in vivo experiments have shown reduced fungal elimination by the JAK inhibitor ruxolitinib via inhibition of Interleukin-6/23-activated neutrophils [14]. However, it is unclear how the combination of baricitinib and corticosteroids affects immunity against fungi.

Conclusions

We treated a COVID-19 patient who developed pulmonary *Aspergillus* infection after treatment with remdesivir, dexamethasone, and baricitinib. Combination therapy with immunomodulatory drugs has been commonly used in patients with severe COVID-19, but the incidence and characteristics of CAPA in these patients are unclear. Physicians should be aware of CAPA, and early screening should be performed for worsening respiratory conditions in patients with COVID-19.

Additional Information

Disclosures

Human subjects: Consent was obtained or waived by all participants in this study. **Conflicts of interest:** In compliance with the ICMJE uniform disclosure form, all authors declare the following: **Payment/services info:** All authors have declared that no financial support was received from any organization for the submitted work. **Financial relationships:** All authors have declared that they have no financial relationships at present or within the previous three years with any organizations that might have an interest in the submitted work. **Other relationships:** All authors have declared that there are no other relationships or activities that could appear to have influenced the submitted work.

References

- Musuuzza JS, Watson L, Parmasad V, Putman-Buehler N, Christensen L, Safdar N: Prevalence and outcomes of co-infection and superinfection with SARS-CoV-2 and other pathogens: a systematic review and meta-analysis. *PLoS One*. 2021, 16:e0251170. [10.1371/journal.pone.0251170](https://doi.org/10.1371/journal.pone.0251170)
- Mitaka H, Kuno T, Takagi H, Patrawalla P: Incidence and mortality of COVID-19-associated pulmonary aspergillosis: a systematic review and meta-analysis. *Mycoses*. 2021, 64:995-1001. [10.1111/myc.13292](https://doi.org/10.1111/myc.13292)
- Short KR, Kasper J, van der Aa S, et al.: Influenza virus damages the alveolar barrier by disrupting epithelial cell tight junctions. *Eur Respir J*. 2016, 47:954-66. [10.1183/13993003.01282-2015](https://doi.org/10.1183/13993003.01282-2015)
- Ichai P, Saliba F, Baune P, Daoud A, Coilly A, Samuel D: Impact of negative air pressure in ICU rooms on the risk of pulmonary aspergillosis in COVID-19 patients. *Crit Care*. 2020, 24:538. [10.1186/s13054-020-03221-w](https://doi.org/10.1186/s13054-020-03221-w)
- Montrucchio G, Lupia T, Lombardo D, Stroffolini G, Corcione S, De Rosa FG, Brazzi L: Risk factors for invasive aspergillosis in ICU patients with COVID-19: current insights and new key elements. *Ann Intensive Care*. 2021, 11:136. [10.1186/s13613-021-00923-4](https://doi.org/10.1186/s13613-021-00923-4)
- Horby P, Lim WS, Emberson JR, et al.: Dexamethasone in hospitalized patients with Covid-19. *N Engl J Med*. 2021, 384:693-704. [10.1056/NEJMoa2021436](https://doi.org/10.1056/NEJMoa2021436)
- Kalil AC, Patterson TF, Mehta AK, et al.: Baricitinib plus remdesivir for hospitalized adults with Covid-19. *N Engl J Med*. 2021, 384:795-807. [10.1056/NEJMoa2031994](https://doi.org/10.1056/NEJMoa2031994)
- Marconi VC, Ramanan AV, de Bono S, et al.: Efficacy and safety of baricitinib for the treatment of hospitalised adults with COVID-19 (COV-BARRIER): a randomised, double-blind, parallel-group, placebo-controlled phase 3 trial. *Lancet Respir Med*. 2021, 9:1407-18. [10.1016/S2213-2600\(21\)00331-3](https://doi.org/10.1016/S2213-2600(21)00331-3)
- Yang R, Li X, Liu H, et al.: Chest CT severity score: an imaging tool for assessing severe COVID-19. *Radiol Cardiothorac Imaging*. 2020, 2:e200047. [10.1148/ryct.2020200047](https://doi.org/10.1148/ryct.2020200047)
- Armstrong-James D, Youngs J, Bicanic T, et al.: Confronting and mitigating the risk of COVID-19 associated pulmonary aspergillosis. *Eur Respir J*. 2020, 56: [10.1183/13993003.02554-2020](https://doi.org/10.1183/13993003.02554-2020)
- Koehler P, Bassetti M, Chakrabarti A, et al.: Defining and managing COVID-19-associated pulmonary aspergillosis: the 2020 ECMM/ISHAM consensus criteria for research and clinical guidance. *Lancet Infect Dis*. 2021, 21:e149-62. [10.1016/S1473-3099\(20\)30847-1](https://doi.org/10.1016/S1473-3099(20)30847-1)
- Richardson P, Griffin I, Tucker C, et al.: Baricitinib as potential treatment for 2019-nCoV acute respiratory disease. *Lancet*. 2020, 395:e30-1. [10.1016/S0140-6736\(20\)30304-4](https://doi.org/10.1016/S0140-6736(20)30304-4)
- Izumo T, Kuse N, Awano N, et al.: Clinical impact of combination therapy with baricitinib, remdesivir, and dexamethasone in patients with severe COVID-19. *Respir Investig*. 2021, 59:799-803. [10.1016/j.resinv.2021.07.004](https://doi.org/10.1016/j.resinv.2021.07.004)
- Taylor PR, Roy S, Meszaros EC, Sun Y, Howell SJ, Malesmud CJ, Pearlman E: JAK/STAT regulation of *Aspergillus fumigatus* corneal infections and IL-6/23-stimulated neutrophil, IL-17, elastase, and MMP9 activity. *J Leukoc Biol*. 2016, 100:213-22. [10.1189/jlb.4A1015-483R](https://doi.org/10.1189/jlb.4A1015-483R)