

# Macrodystrophia Lipomatosa: A Rare Cause of Bilateral Lower Limb Gigantism

Dijendra Nath Biswas<sup>1</sup>, Arkadeep Dhali<sup>2</sup>, Sabnam Parvin<sup>1</sup>, Archana Singh<sup>1</sup>, Gopal Krishna Dhali<sup>3</sup>

Review began 10/15/2021

Review ended 10/22/2021

Published 10/23/2021

© Copyright 2021

Biswas et al. This is an open access article distributed under the terms of the Creative Commons Attribution License CC-BY 4.0., which permits unrestricted use, distribution, and reproduction in any medium, provided the original author and source are credited.

1. Department of Radiology, Institute of Post Graduate Medical Education and Research, Kolkata, IND 2. Department of Gastrointestinal Surgery, Institute of Post Graduate Medical Education and Research, Kolkata, IND 3. Department of Gastroenterology, Institute of Post Graduate Medical Education and Research, Kolkata, IND

Corresponding author: Sabnam Parvin, [sabnamparvin.bmc@gmail.com](mailto:sabnamparvin.bmc@gmail.com)

---

## Abstract

Macrodystrophia lipomatosa (MDL) is a rare congenital overgrowth syndrome characterised by inadvertent proliferation of all the mesenchymal elements resulting in localised gigantism. Herein, we present an eight-month-old female child, who presented to us with a history of gradual enlargement of both lower limbs along with the toes which was noticed by the parents a few days after birth. There was no history of trauma, pain or skin changes. Physical examination revealed unusual hypertrophy of both feet and toes. It was non-tender with no evidence of oedema or bruit over the swelling. X-ray of lower limbs revealed bony hypertrophy and overgrowth of all the bones with increased soft tissue shadow of bilateral foot. On ultrasound evaluation of the lower limbs, there was increased soft tissue in both dorsal and plantar aspect of bilateral foot without any vascular malformation. To characterise the swelling better, magnetic resonance imaging was warranted which revealed accumulation of excessive fat in the subcutaneous tissue without discernible capsule. Fibrous strand within the fat in bilateral feet, both in the plantar and dorsal aspect (more in plantar aspect), was seen. Core tissue biopsy was performed which showed abundant adipose tissue dispersed in mesh-like fibrous tissue and infiltrating the dermal connecting, suggestive of macrodystrophia lipomatosa. Currently, patient is advised for corrective surgery. Clinicians should be aware of these atypical presentations of MDL to differentiate it from other causes of local gigantism like fibrolipohamartoma (FLH) of nerve sheath, lymphangiomatosis, hemangiomatosis, Proteus syndrome, Klippel-Trenaunay syndrome and neurofibromatosis 1 as they differ in management and outcome.

---

**Categories:** General Surgery

**Keywords:** macrodystrophia lipomatosa, cosmetic surgery, fibrolipohamartoma, overgrowth syndrome, localised gigantism

## Introduction

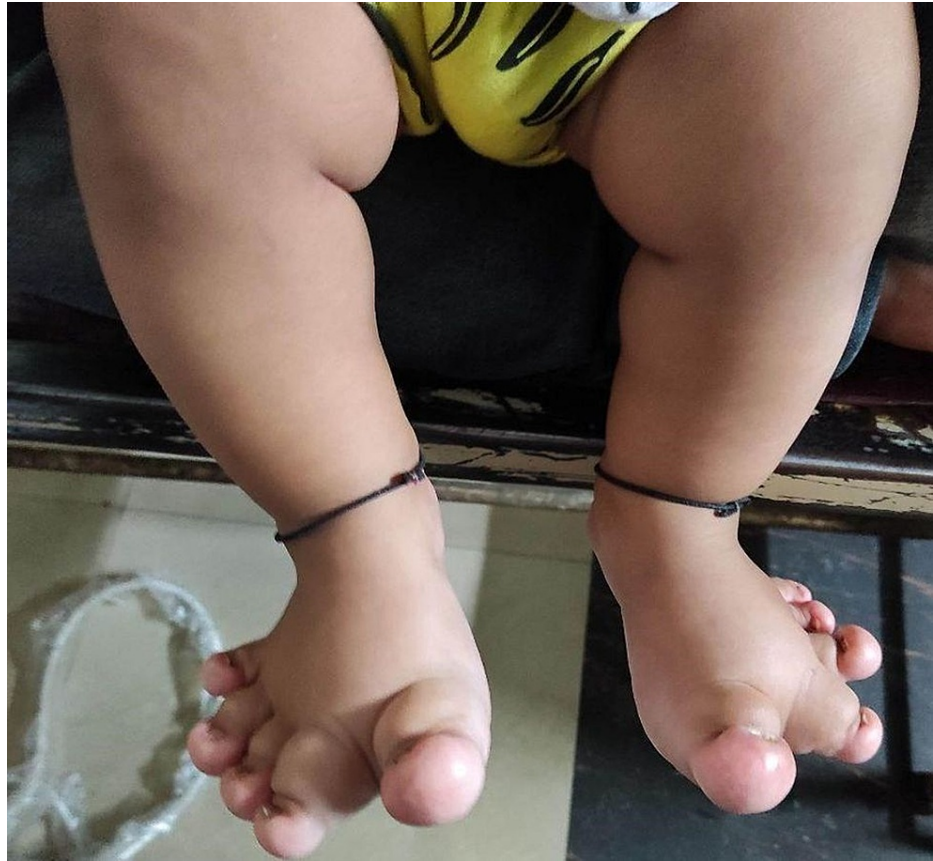Macrodystrophia lipomatosa (MDL) is a rare congenital disorder of local gigantism by the overgrowth of mesenchymal elements (including the periosteum, bone marrow, nerve sheath or muscle), predominantly the fibroadipose tissue [1,2]. The affected limb increases in length and girth until the child reaches puberty. Usually, involvement of unilateral foot with predilection for second and third digits is commonly encountered [3,4]. In our case, bilateral involvement of lower limbs along with involvement of all the digits was seen. It is important to report such anecdotal cases to get knowledge about their clinicopathological behaviour and standardise optimal treatment options since prospective studies are not feasible due to rarity of the disease and paucity of data.

## Case Presentation

Herein, we present an eight-month-old female child born out of non-consanguineous marriage via normal vaginal delivery, who presented to us with a history of gradual enlargement of both lower limbs along with the toes which was noticed by the parents a few days after birth. This was not associated with any delayed attainment of developmental milestones. There was no history of trauma, pain or skin changes. There is no relevant family history of any similar diseases. The upper limbs were normal. There were no stigmata of neurofibromatosis. On further reviewing the reports of antenatal ultrasound, no limb asymmetry was documented. Physical examination revealed unusual hypertrophy of both feet and toes (Figure 1).

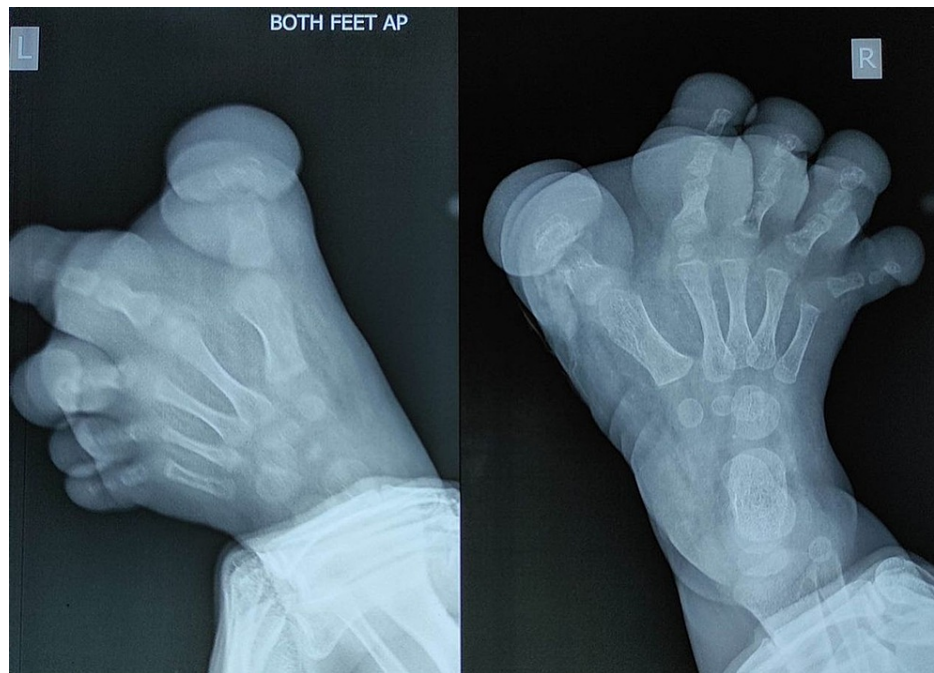
### How to cite this article

Biswas D, Dhali A, Parvin S, et al. (October 23, 2021) Macrodystrophia Lipomatosa: A Rare Cause of Bilateral Lower Limb Gigantism . Cureus 13(10): e18986. DOI 10.7759/cureus.18986



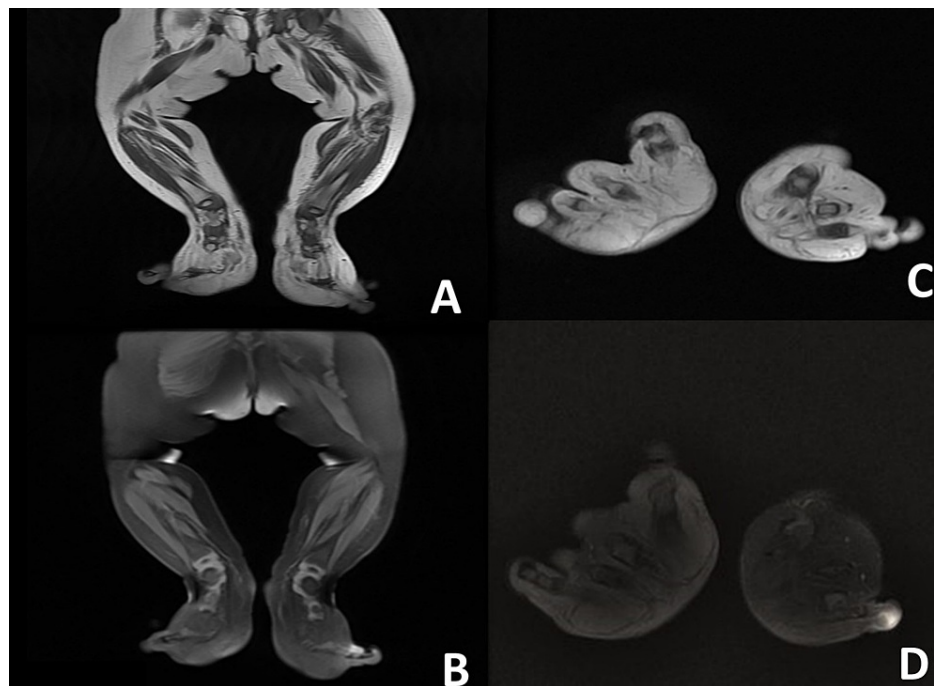
**FIGURE 1: Abnormal enlargement of bilateral feet and all the toes.**

The skin over this was thickened. It was non-tender with no evidence of oedema or bruit over the swelling. X-ray of lower limbs revealed bony hypertrophy and overgrowth of all the bones with increased soft tissue shadow of bilateral foot (Figure 2). No evidence of osteolytic or sclerotic lesions was seen, and no periosteal reaction was noted. On ultrasound evaluation of the lower limbs, there was increased soft tissue in both dorsal and plantar aspect of bilateral foot without any vascular malformation. To characterise the swelling better, magnetic resonance imaging (Figure 3A-3D) was warranted which revealed accumulation of excessive fat in the subcutaneous tissue without discernible capsule. Fibrous strand within the fat in bilateral feet, both in the plantar and dorsal aspect (more in plantar aspect), was seen. There was osseous hypertrophy and bony overgrowth without any cortical thickening. Core tissue biopsy was performed which showed abundant adipose tissue dispersed in mesh-like fibrous tissue and infiltrating the dermal connecting, suggestive of macrodystrophia lipomatosa. Currently, patient is advised for corrective surgery.



**FIGURE 2: X-ray AP view of bilateral feet showing bony hypertrophy and overgrowth of all the bones with increased soft tissue shadow.**

AP: anteroposterior, L: left, R: right.



**FIGURE 3: MRI image.**

Coronal T1W (A), coronal fat-suppressed sequence (B), axial T1W (C) and axial T1 fat suppressed (D) showing accumulation of excessive fat in the subcutaneous tissue without discernible capsule. Fibrous strands are seen within the fat in bilateral feet both in plantar and dorsal aspect (more in plantar aspect). There is osseous hypertrophy and bony overgrowth without any cortical thickening

## Discussion

Macrodystrophia lipomatosa (MDL) is a rare congenital overgrowth syndrome characterised by inadvertent

proliferation of all the mesenchymal elements that result in localised gigantism in the form of overgrowth of affected limbs [1,2]. It has no variation in sex distribution, and the exact incidence is unknown. Inglis has hypothesised probable theories for pathogenesis which include (1) humoral mechanism, (2) vascular mechanism and (3) neural mechanism [5]. PIK3CA gene association has been highlighted in newer studies [6]. Unilateral foot involvement with predilection for second and third digits is commonly encountered [3,4]. In our case, all the digits of both feet were involved. This was unique to our case as generalised involvement of all the digits of both lower limbs in MDL has never been reported before.

Most of the cases have shown to increase in length as well as girth until puberty [7]. According to the pattern of growth, Barsky had classified MDL into static and progressive type [8]. In terms of diagnostic imaging modality, plain radiograph, magnetic resonance imaging (MRI) and ultrasound evaluation are used [9]. MRI can demonstrate diffuse fatty overgrowth without discernible capsule in the subcutaneous area. It is also helpful in picking up abnormalities of the neurovascular components [10,11]. Definitive diagnosis of MDL is quite challenging due to its similarities with other disorders like neurofibromatosis 1 (NF-1), fibrolipohamartoma (FLH) of nerve sheath, lymphangiomatosis, hemangiomas, Proteus syndrome and Klippel-Trenaunay syndrome. FLH presents with isolated nerve involvement associated with intramuscular fat deposition, contrary to MDL, where all components of the mesenchymal elements are involved [12]. NF-1 is usually bilateral with other associated findings like café-au-lait spot and multiple cutaneous neurofibromas [13]. Proteus syndrome presents with skull abnormalities, pigmented nevi, lung cysts and intraabdominal lipoma [14]. Port-wine stain and varicose veins are seen in Klippel-Trenaunay syndrome [15].

Surgical intervention is required in MDL. The principle over here is to improve cosmetic appearance with utmost care in preserving the physiological functions. Multiple debulking surgeries with or without partial amputation have shown to provide promising results. In absence of neurological signs and symptoms, surgery should be delayed till completion of patient's growth [16].

## Conclusions

What is unique about our case was the bilateral involvement of lower limbs along with involvement of all the digits. It is important to report such anecdotal cases to get knowledge about their clinicopathological behaviour and standardise optimal treatment options since prospective studies are not feasible due to rarity of the disease and paucity of data. Moreover, clinicians should be aware of these atypical presentations to differentiate it from other causes of local gigantism like fibrolipohamartoma (FLH) of nerve sheath, lymphangiomatosis, hemangiomas, Proteus syndrome, Klippel-Trenaunay syndrome and neurofibromatosis 1 as they differ in management and outcome.

## Additional Information

### Disclosures

**Human subjects:** Consent was obtained or waived by all participants in this study. **Conflicts of interest:** In compliance with the ICMJE uniform disclosure form, all authors declare the following: **Payment/services info:** All authors have declared that no financial support was received from any organization for the submitted work. **Financial relationships:** All authors have declared that they have no financial relationships at present or within the previous three years with any organizations that might have an interest in the submitted work. **Other relationships:** All authors have declared that there are no other relationships or activities that could appear to have influenced the submitted work.

## References

- Goldman AB, Kaye JJ: Macrodystrophia lipomatosa: radiographic diagnosis. *AJR Am J Roentgenol.* 1977, 128:101-5. [10.2214/ajr.128.1.101](https://doi.org/10.2214/ajr.128.1.101)
- Singla V, Virmani V, Tuli P, Singh P, Khandelwal N: Case Report: macrodystrophia lipomatosa: illustration of two cases. *Indian J Radiol Imaging.* 2008, 18:298-301. [10.4103/0971-3026.43844](https://doi.org/10.4103/0971-3026.43844)
- Ranawat CS, Arora MM, Singh RG: Macrodystrophia lipomatosa with carpal-tunnel syndrome. A case report. *J Bone Joint Surg Am.* 1968, 50:1242-4.
- Upadhyay D, Parashari UC, Khanduri S, Bhadury S: Macrodystrophia lipomatosa: radiologic-pathologic correlation. *J Clin Imaging Sci.* 2011, 1:18. [10.4103/2156-7514.78264](https://doi.org/10.4103/2156-7514.78264)
- Inglis K: Local gigantism (a manifestation of neurofibromatosis): its relation to general gigantism and to acromegaly: illustrating the influence of intrinsic factors in disease when development of the body is abnormal. *Am J Pathol.* 1950, 26:1059-83.
- Rios JJ, Paria N, Burns DK, Israel BA, Cornelia R, Wise CA, Ezaki M: Somatic gain-of-function mutations in PIK3CA in patients with macrodactyly. *Hum Mol Genet.* 2013, 22:444-51. [10.1093/hmg/ddt440](https://doi.org/10.1093/hmg/ddt440)
- Khan RA, Wahab S, Ahmad I, Chana RS: Macrodystrophia lipomatosa: four case reports. *Ital J Pediatr.* 2010, 36:69. [10.1186/1824-7288-36-69](https://doi.org/10.1186/1824-7288-36-69)
- Barsky AJ: Macrodactyly. *J Bone Joint Surg Am.* 1967, 49:1255-66.
- Prabhu CS, Madhavi K, Amogh VN, Panwala HK, Sathyakumar K: Macrodystrophia lipomatosa: a single large radiological study of a rare entity. *J Clin Imaging Sci.* 2019, 9:4. [10.25259/JCIS-9-4](https://doi.org/10.25259/JCIS-9-4)
- Soler R, Rodríguez E, Bargiela A, Martínez C: MR findings of macrodystrophia lipomatosa. *Clin Imaging.* 1997, 21:135-7. [10.1016/0899-7071\(95\)00095-x](https://doi.org/10.1016/0899-7071(95)00095-x)

11. Gupta SK, Sharma OP, Sharma SV, Sood B, Gupta S: Macrodystrophia lipomatosa: radiographic observations. *Br J Radiol.* 1992, 65:769-73. [10.1259/0007-1285-65-777-769](https://doi.org/10.1259/0007-1285-65-777-769)
12. Hoellwarth JS, Goitz RJ: Lipofibromatous hamartoma of the palmar cutaneous branch of the median nerve. *J Hand Microsurg.* 2018, 10:109-12. [10.1055/s-0038-1626682](https://doi.org/10.1055/s-0038-1626682)
13. Boyd KP, Korf BR, Theos A: Neurofibromatosis type 1. *J Am Acad Dermatol.* 2009, 61:1-14; quiz 15-6. [10.1016/j.jaad.2008.12.051](https://doi.org/10.1016/j.jaad.2008.12.051)
14. Ou M, Sun Z, Zhu P, Sun G, Dai Y: Proteus syndrome: a case report and review of the literature. *Mol Clin Oncol.* 2017, 6:381-3. [10.3892/mco.2017.1140](https://doi.org/10.3892/mco.2017.1140)
15. Sharma D, Lamba S, Pandita A, Shastri S: Klippel-Trénaunay syndrome: a very rare and interesting syndrome. *Clin Med Insights Circ Respir Pulm Med.* 2015, 9:1-4. [10.4137/CCRPM.S21645](https://doi.org/10.4137/CCRPM.S21645)
16. Kwon JH, Lim SY, Lim HS: Macrodystrophia lipomatosa. *Arch Plast Surg.* 2015, 40:270-2. [10.5999/aps.2013.40.3.270](https://doi.org/10.5999/aps.2013.40.3.270)