Cureus
Part of SPRINGER NATURE

Open Access Case Report

High-Grade Endometrial Stromal Sarcoma With Focal Rhabdomyosarcomatous Differentiation and Peritoneal Dissemination: A Case Report

Kaouthar Khater [1], Asmae Bali [1], Fadoua Jebrouni [1], Soufia El Ouardani [1], Hind Chibani [1], Sami Aziz Brahmi [1], Said Afqir [1]

1. Medical Oncology, Mohammed VI University Hospital, Oujda, MAR

Corresponding author: Kaouthar Khater, kaoutharkhater78@gmail.com

Review began 11/18/2026
Review ended 11/23/2026
Published 11/26/2026

© **Copyright** 2026
Khater et al. This is an open access article distributed under the terms of the Creative Commons Attribution License CC-BY 4.0., which permits unrestricted use, distribution, and reproduction in any medium, provided the original author and source are credited.

DOI: 10.7759/cureus.120310

Abstract

High-grade endometrial stromal sarcoma (HG-ESS) is a rare and aggressive uterine mesenchymal malignancy. Rhabdomyosarcomatous differentiation is an uncommon form of divergent or heterologous differentiation in endometrial stromal tumors and is particularly unusual in HG-ESS. We report the case of a 75-year-old woman with no significant medical history who presented with abnormal uterine bleeding for four months. Pelvic magnetic resonance imaging revealed a 65 mm endometrial mass with deep myometrial invasion. The patient underwent total hysterectomy with bilateral salpingo-oophorectomy. Histopathological examination demonstrated a HG-ESS with focal rhabdomyosarcomatous differentiation and a high mitotic rate of approximately 45 mitoses per 10 high-power fields. The tumor infiltrated more than 50% of the myometrial thickness and extended to the left parametrium, right uterine horn, and right fallopian tube. Omental and peritoneal biopsies confirmed metastatic involvement. Immunohistochemical analysis showed heterogeneous and focal expression of cluster of differentiation 10 (CD10 and cyclin D1 in the conventional stromal component, whereas the rhabdomyosarcomatous component demonstrated diffuse desmin expression and nuclear expression of MyoD1 and myogenin, supporting skeletal muscle differentiation. Integrase Interactor 1 (INI1) expression was retained. The tumor was negative for pancytokeratin, estrogen receptor, progesterone receptor, h-caldesmon, CD34, S100 protein, Human Melanoma Black 45 (HMB45), Mouse Double Minute 2 (MDM2), and Cyclin-Dependent Kinase 4 (CDK4). Postoperative thoraco-abdomino-pelvic computed tomography demonstrated multiple intraperitoneal nodules and masses with loculated ascites, consistent with diffuse peritoneal dissemination. The case was discussed at a multidisciplinary tumor board, and systemic chemotherapy with doxorubicin was initiated. This case highlights the diagnostic complexity of HG-ESS with focal rhabdomyosarcomatous differentiation and emphasizes the importance of integrating morphology and immunohistochemistry, particularly when molecular characterization is unavailable.

Categories: Obstetrics/Gynecology, Pathology, Oncology
Keywords: cyclin d1, high-grade endometrial stromal sarcoma, myod1, myogenin, peritoneal dissemination, rhabdomyosarcomatous differentiation, uterine sarcoma

Introduction

Endometrial stromal tumors are rare mesenchymal neoplasms of the uterus. According to the 2020 World Health Organization (WHO) classification, these tumors include endometrial stromal nodule, low-grade endometrial stromal sarcoma (LG-ESS), and high-grade endometrial stromal sarcoma (HG-ESS), while undifferentiated uterine sarcoma is classified separately among malignant uterine mesenchymal tumors [1,2].

HG-ESS is an aggressive uterine sarcoma characterized by high-grade cytological features and recurrent molecular alterations. Well-established molecular subtypes include tumors with Tyrosine 3-Monooxygenase/Tryptophan 5-Monooxygenase Activation Protein Epsilon-NUT Family Member 2 (YWHAE-NUTM2) fusions and BCL6 Corepressor (BCOR)-related alterations [3,4].

Endometrial stromal tumors may rarely exhibit divergent or heterologous differentiation, including smooth muscle, sex cord-like, glandular, rhabdomyoblastic, and other skeletal muscle-associated differentiation [5,6]. Rhabdomyosarcomatous differentiation is particularly uncommon and may create substantial diagnostic difficulty, especially when the rhabdomyosarcomatous component is prominent [6].

The differential diagnosis of a high-grade uterine sarcoma with rhabdomyosarcomatous differentiation includes carcinosarcoma, adenosarcoma with sarcomatous overgrowth, primary uterine rhabdomyosarcoma, leiomyosarcoma, malignant rhabdoid tumor, and undifferentiated uterine sarcoma. Accurate diagnosis therefore requires careful correlation of morphological findings with immunohistochemical results and, when available, molecular studies [1,2,5].

How to cite this article
Khater K, Bali A, Jebrouni F, et al. (November 26, 2026) High-Grade Endometrial Stromal Sarcoma With Focal Rhabdomyosarcomatous Differentiation and Peritoneal Dissemination: A Case Report. Cureus 18(11): e120310. DOI 10.7759/cureus.120310

We report a rare case of HG-ESS with focal rhabdomyosarcomatous differentiation associated with diffuse peritoneal dissemination in a 75-year-old woman. Particular emphasis is placed on the morphological and immunohistochemical findings supporting the diagnosis in the absence of molecular characterization.

Case Presentation

A 75-year-old woman with no significant past medical history presented with abnormal uterine bleeding that had been present for four months. She reported no associated pelvic pain or constitutional symptoms. Clinical examination revealed no remarkable abnormalities.

Initial pelvic ultrasonography demonstrated diffuse endometrial thickening, raising suspicion for an underlying endometrial neoplasm. Endometrial curettage was subsequently performed.

Pelvic magnetic resonance imaging (MRI) revealed a 65 mm endometrial mass with low signal intensity on T1-weighted images and heterogeneous intermediate-to-high signal intensity on T2-weighted sequences. Diffusion-weighted imaging demonstrated marked restriction, suggestive of high cellularity. The lesion showed an irregular interface with the junctional zone and deep myometrial invasion exceeding 50% of the myometrial thickness. The uterine serosa appeared preserved, with no radiological evidence of direct extrauterine extension (Figure *1*).

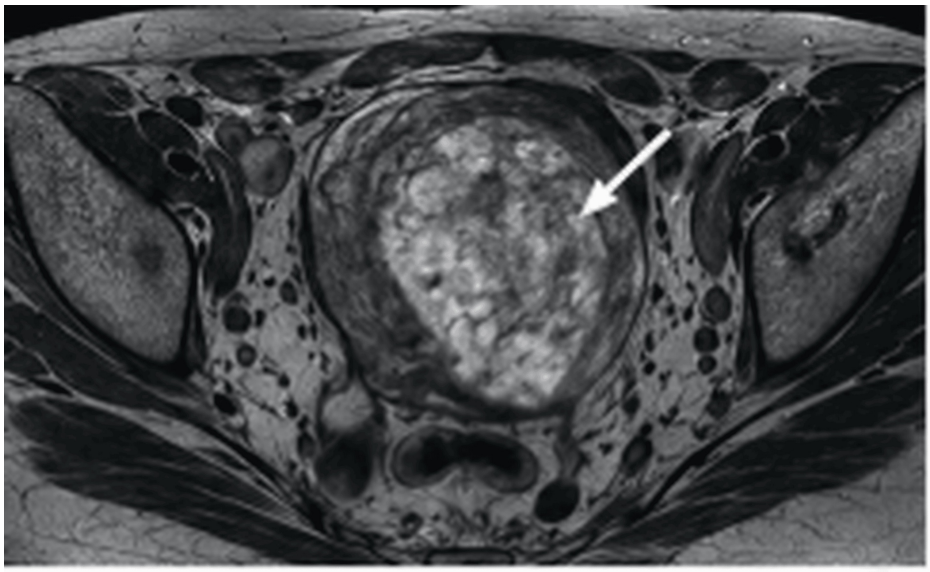

FIGURE 1: Axial T2-weighted pelvic MRI

Shows a large endometrial mass with heterogeneous intermediate-to-high signal intensity (arrow), demonstrating deep myometrial invasion.

The patient underwent total hysterectomy with bilateral salpingo-oophorectomy. Histopathological examination revealed a HG-ESS composed of densely cellular sheets of atypical spindle to round stromal cells with marked nuclear atypia, brisk mitotic activity, and infiltrative myometrial invasion. The tumor cells showed marked anisokaryosis, irregular and hyperchromatic nuclear contours, and abundant eosinophilic cytoplasm. Focal areas demonstrated rhabdomyosarcomatous differentiation, characterized by enlarged round to polygonal cells with abundant eosinophilic cytoplasm, marked nuclear atypia, prominent nucleoli, and rhabdomyoblastic morphology (Figure *2*).

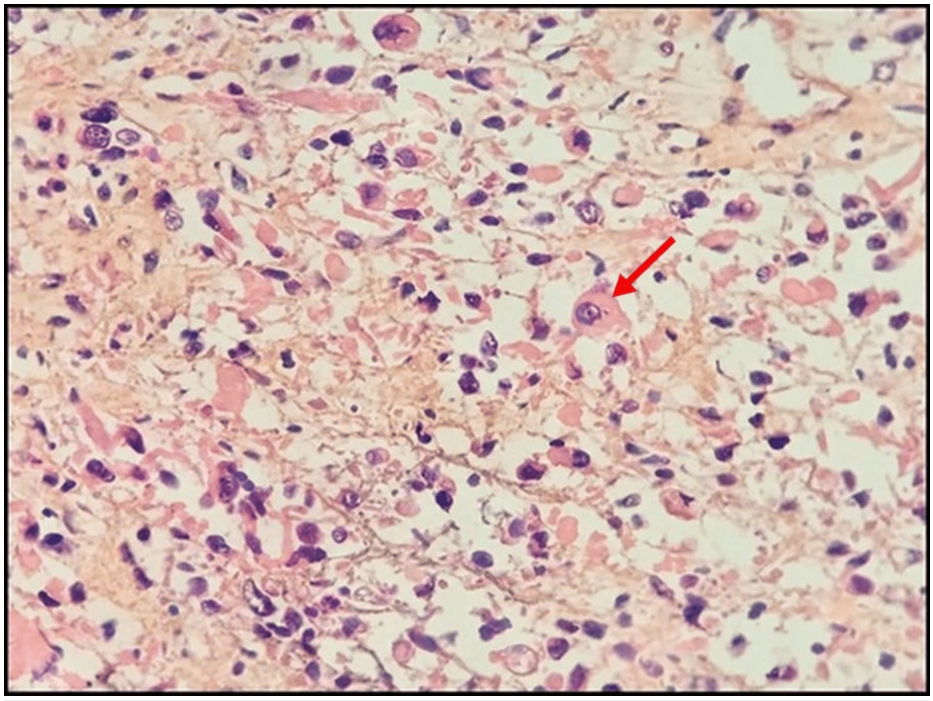

FIGURE 2: Histopathological features of the rhabdomyosarcomatous component

Tumor cells show abundant eosinophilic cytoplasm, marked nuclear atypia, and rhabdomyoblastic morphology, with occasional cells displaying eccentric nuclei and prominent nucleoli (hematoxylin and eosin, ×400).

The mitotic index was approximately 45 mitoses per 10 high-power fields. Extensive areas of tumor necrosis were identified, associated with fibro-inflammatory and focally myxoid stroma. Tumor infiltration involved more than 50% of the myometrial thickness.

The tumor infiltrated the left parametrium, right uterine horn, and right fallopian tube. The ovaries were free of tumor. No vascular emboli or perineural invasion were identified. A biopsy of a peritoneal nodule demonstrated metastatic tumor deposits with similar histomorphological features, confirming peritoneal dissemination. The omental specimen was also infiltrated by the same tumor.

Immunohistochemical analysis demonstrated heterogeneous and focal positivity for CD10 and cyclin D1 within the conventional stromal tumor component. The rhabdomyosarcomatous areas showed diffuse desmin expression and nuclear positivity for MyoD1 and myogenin, supporting skeletal muscle differentiation. Smooth muscle actin expression was focal. Tumor cells showed retained nuclear expression of integrase interactor 1 (INI1; Figure *3*).

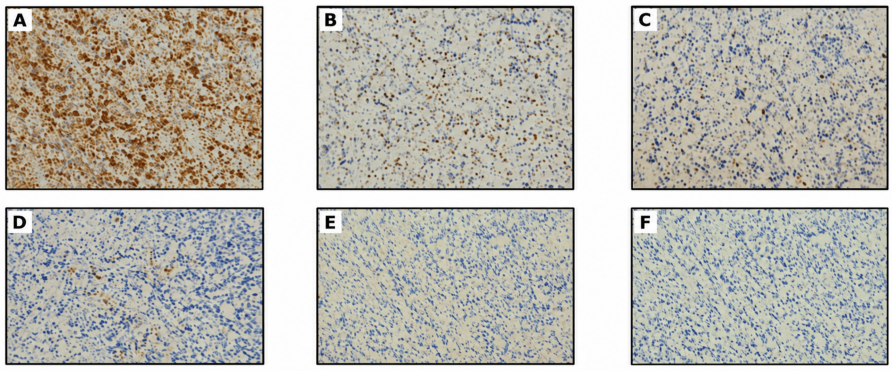

FIGURE 3: Immunohistochemical profile of the tumor

(A) Diffuse cytoplasmic expression of desmin in the rhabdomyosarcomatous component. (B) Nuclear expression of MyoD1 in the rhabdomyosarcomatous component. (C) Nuclear expression of myogenin in the rhabdomyosarcomatous component, supporting skeletal muscle differentiation. (D) Focal and heterogeneous nuclear expression of cyclin D1 in the conventional stromal component. (E) Focal and heterogeneous expression of CD10 in the conventional stromal component. (F) Negative pancytokeratin expression, arguing against epithelial differentiation (×200).

The tumor was negative for pancytokeratin, estrogen receptor, progesterone receptor, h-caldesmon, CD34, S100 protein, Human Melanoma Black 45 (HMB45), Mouse Double Minute 2 (MDM2), and Cyclin-Dependent Kinase 4 (CDK4).

Based on the 2009 FIGO staging system for uterine sarcomas, the presence of histologically confirmed omental and peritoneal dissemination corresponded to FIGO stage IIIB [7,8].

Postoperative thoraco-abdomino-pelvic computed tomography demonstrated multiple intraperitoneal nodules and masses, some with central necrosis, associated with loculated ascites and compatible with diffuse peritoneal dissemination.

The case was discussed at a multidisciplinary tumor board. Given the advanced stage and diffuse peritoneal dissemination, systemic chemotherapy was recommended. The patient received first-line treatment with doxorubicin at a dose of 75 mg/m² administered intravenously on day one of a three-week cycle. Treatment was well tolerated, and the patient remained clinically stable at the most recent follow-up.

Discussion

HG-ESS is a rare and aggressive uterine mesenchymal malignancy whose classification integrates morphology, immunohistochemistry, and molecular findings. YWHAE-NUTM2 and BCOR-related alterations represent important molecular subsets [1,3,4]. Clinical presentation is nonspecific and commonly includes abnormal uterine bleeding or an enlarged uterine mass [2,9,10], as observed in our patient.

The present case is unusual because of focal rhabdomyosarcomatous differentiation. Although rare, skeletal muscle differentiation has been described in endometrial stromal tumors and may create a significant diagnostic challenge [5,6,11]. In our case, the conventional component showed a high-grade stromal neoplasm with marked atypia, infiltrative myometrial invasion, extensive necrosis, and a high mitotic index (45 mitoses/10 high-power fields), while focal areas displayed rhabdomyoblastic morphology. Diffuse desmin expression and nuclear expression of MyoD1 and myogenin supported true skeletal muscle differentiation [11]. A similar association of HG-ESS with skeletal muscle differentiation was reported by Ohta et al. [12].

The main differential diagnoses included carcinosarcoma, adenosarcoma with sarcomatous overgrowth, primary uterine rhabdomyosarcoma, undifferentiated uterine sarcoma, and malignant rhabdoid tumor. Carcinosarcoma was unlikely because no malignant epithelial component was identified and pancytokeratin was negative. Adenosarcoma was considered because heterologous rhabdomyosarcomatous differentiation may occur in this tumor; however, no benign glandular component was identified [13]. Primary uterine rhabdomyosarcoma was considered unlikely because of the presence of a conventional high-grade stromal component. Malignant rhabdoid tumor was also considered, but the combination of rhabdomyoblastic morphology, diffuse desmin expression, nuclear MyoD1 and myogenin expression, and retained INI1 supported true rhabdomyosarcomatous differentiation rather than rhabdoid morphology alone.

Immunohistochemistry further supported the integrated diagnosis. The conventional stromal component showed focal and heterogeneous CD10 and cyclin D1 expression, whereas the rhabdomyosarcomatous component showed diffuse desmin and nuclear MyoD1 and myogenin expression. Pancytokeratin and h-caldesmon were negative, arguing against epithelial and smooth muscle differentiation, respectively. Cyclin D1 has been described as a useful marker of YWHAE-rearranged HG-ESS when diffusely and strongly expressed [14]; however, its focal and heterogeneous expression in the present case was not considered diagnostic of a YWHAE-NUTM2-rearranged tumor. Similarly, focal CD10 expression supported an endometrial stromal phenotype but was not specific for a molecular subgroup [1,3,4,15].

Molecular characterization is increasingly important in the classification of HG-ESS, particularly for identifying YWHAE-NUTM2 and BCOR-related tumors [3,4,15,16]. In the present case, molecular testing was not performed because of financial constraints and limited access to molecular analysis. Therefore, no specific molecular alteration could be demonstrated and the tumor could not be assigned to a defined molecular subgroup. Nevertheless, the diagnosis was supported by the concordance of the high-grade stromal morphology, infiltrative growth pattern, marked mitotic activity, necrosis, stromal immunophenotype, and unequivocal skeletal muscle differentiation. Thus, the absence of molecular testing represents a limitation for molecular classification but does not preclude an integrated histopathological diagnosis.

Radiological evaluation is important for assessing local extension and extrauterine disease in uterine sarcomas [17]. In this case, MRI demonstrated deep myometrial invasion, whereas postoperative CT showed diffuse intraperitoneal dissemination. Histologically confirmed involvement of multiple abdominal sites, including the peritoneum and omentum, corresponded to FIGO stage IIIB according to the 2009 FIGO staging system for uterine sarcomas [7,8].

Treatment of advanced HG-ESS remains challenging because of the rarity of the disease and the limited evidence available to guide systemic therapy [18]. In patients with metastatic or unresectable uterine sarcomas, chemotherapy may be considered as part of an individualized, multidisciplinary treatment strategy. Doxorubicin, an anthracycline widely used in the treatment of advanced soft tissue sarcomas, represents a therapeutic option, although evidence specifically supporting its efficacy in HG-ESS remains limited [2,19]. In the present case, given the diffuse peritoneal dissemination, postoperative systemic chemotherapy with doxorubicin monotherapy (75 mg/m^2 every three weeks) was recommended following multidisciplinary discussion. Treatment was initially well tolerated, and the patient remained clinically stable at the time of reporting.

The prognostic significance of rhabdomyosarcomatous differentiation in HG-ESS remains poorly understood because of the limited number of reported cases [12]. In our patient, the advanced FIGO stage and diffuse peritoneal dissemination were the principal indicators of aggressive disease. Overall, this case highlights the diagnostic challenge posed by focal rhabdomyosarcomatous differentiation in HG-ESS and emphasizes the value of integrating tumor morphology with immunohistochemistry, particularly when molecular testing is unavailable.

Conclusions

HG-ESS with focal rhabdomyosarcomatous differentiation is a rare and aggressive tumor with significant diagnostic and therapeutic challenges. In this case, the diagnosis was supported by the characteristic high-grade stromal morphology and confirmed skeletal muscle differentiation. At the same time, extensive peritoneal and omental involvement indicated advanced disease (FIGO stage IIIB). After multidisciplinary discussion, systemic chemotherapy with doxorubicin was initiated. Although molecular testing was unavailable, the concordant morphological and immunohistochemical findings supported the integrated diagnosis, while molecular characterization remains important for definitive molecular classification.

Additional Information

Author Contributions

All authors have reviewed the final version to be published and agreed to be accountable for all aspects of the work.

Concept and design: Kaouthar Khater, Asmae Bali, Fadoua Jebrouni, Soufia El Ouardani, Hind Chibani, Sami Aziz Brahmi, Said Afqir

Acquisition, analysis, or interpretation of data: Kaouthar Khater, Asmae Bali, Fadoua Jebrouni, Soufia El Ouardani, Hind Chibani, Sami Aziz Brahmi, Said Afqir

Drafting of the manuscript: Kaouthar Khater, Asmae Bali, Fadoua Jebrouni, Soufia El Ouardani, Hind Chibani, Sami Aziz Brahmi, Said Afqir

Critical review of the manuscript for important intellectual content: Kaouthar Khater, Asmae Bali,

Fadoua Jebrouni, Soufia El Ouardani, Hind Chibani, Sami Aziz Brahmi, Said Afqir

Supervision: Kaouthar Khater, Asmae Bali, Fadoua Jebrouni, Soufia El Ouardani, Hind Chibani, Sami Aziz Brahmi, Said Afqir

Disclosures

Human subjects: Informed consent for treatment and open access publication was obtained or waived by all participants in this study. **AI use statement:** The authors have declared that no AI tools were used during the work or in the drafting of this article. The authors take full responsibility for the work. **Conflicts of interest:** In compliance with the ICMJE uniform disclosure form, all authors declare the following: **Payment/services info:** All authors have declared that no financial support was received from any organization for the submitted work. **Financial relationships:** All authors have declared that they have no financial relationships at present or within the previous three years with any organizations that might have an interest in the submitted work. **Other relationships:** All authors have declared that there are no other relationships or activities that could appear to have influenced the submitted work.

References

1. WHO Classification of Tumours Editorial Board: Female Genital Tumours. WHO Classification of Tumours, 5th Edition, Volume 4. International Agency for Research on Cancer, Lyon, France; 2020.
2. Croce S, Devouassoux-Shisheboran M, Pautier P, et al.: Uterine sarcomas and rare uterine mesenchymal tumors with malignant potential. Diagnostic guidelines of the French Sarcoma Group and the Rare Gynecological Tumors Group. Gynecol Oncol. 2022, 167:373-89. 10.1016/j.ygyno.2022.07.031
3. Akaev I, Yeoh CC, Rahimi S: Update on endometrial stromal tumours of the uterus . Diagnostics (Basel). 2021, 11:429. 10.3390/diagnostics11030429
4. Lewis N, Soslow RA, Delair DF, et al.: ZC3H7B-BCOR high-grade endometrial stromal sarcomas: a report of 17 cases of a newly defined entity. Mod Pathol. 2018, 31:674-84. 10.1038/modpathol.2017.162
5. Baker P, Oliva E: Endometrial stromal tumours of the uterus: a practical approach using conventional morphology and ancillary techniques. J Clin Pathol. 2007, 60:235-43. 10.1136/jcp.2005.031203
6. Meng LL, Jia XP, Lu LX, et al.: Unusual morphologic features of low-grade endometrial stromal sarcoma: a case report. J Clin Lab Anal. 2022, 36:e24502. 10.1002/jcla.24502
7. Prat J: FIGO staging for uterine sarcomas . Int J Gynaecol Obstet. 2009, 104:177-8. 10.1016/j.ijgo.2008.12.008
8. Corrigendum to “FIGO staging for uterine sarcomas” (International Journal of Gynecology and Obstetrics (2009) 104:179). Int J Gynaecol Obstet. 2009, 106:277. 10.1016/j.ijgo.2009.04.002
9. Rauh-Hain JA, del Carmen MG: Endometrial stromal sarcoma: a systematic review . Obstet Gynecol. 2013, 122:676-83. 10.1097/AOG.0b013e3182a189ac
10. Mbatani N, Olawaiye AB, Prat J: Uterine sarcomas . Int J Gynaecol Obstet. 2018, 143:51-8. 10.1002/ijgo.12613
11. Cessna MH, Zhou H, Perkins SL, Tripp SR, Layfield L, Daines C, Coffin CM: Are myogenin and myoD1 expression specific for rhabdomyosarcoma? A study of 150 cases, with emphasis on spindle cell mimics. Am J Surg Pathol. 2001, 25:1150-7. 10.1097/00000478-200109000-00005
12. Ohta Y, Suzuki T, Kojima T, et al.: High-grade endometrial stromal sarcoma with smooth muscle and skeletal muscle differentiation: report of a case with cytomorphologic and immunocytologic analysis. Diagn Cytopathol. 2011, 39:301-5. 10.1002/dc.21431
13. Yang G, Lu Y, An Y, He X, Ma D, Jiao L, Li Y: Adenosarcoma of uterus characterized by differentiation of rhabdomyosarcoma and chondrosarcoma: a case report and review of literature. Sci Prog. 2025, 108:368504251362743. 10.1177/00368504251362743
14. Lee CH, Ali RH, Rouzbahman M, et al.: Cyclin D1 as a diagnostic immunomarker for endometrial stromal sarcoma with YWHAE-FAM22 rearrangement. Am J Surg Pathol. 2012, 36:1562-70. 10.1097/PAS.0b013e31825fa931
15. Conklin CM, Longacre TA: Endometrial stromal tumors: the new WHO classification . Adv Anat Pathol. 2014, 21:383-93. 10.1097/PAP.0000000000000046
16. Parra-Herran C, Howitt BE: Uterine mesenchymal tumors: update on classification, staging, and molecular features. Surg Pathol Clin. 2019, 12:363-96. 10.1016/j.path.2019.01.004
17. Rha SE, Byun JY, Jung SE, et al.: CT and MRI of uterine sarcomas and their mimickers . AJR Am J Roentgenol. 2003, 181:1369-74. 10.2214/ajr.181.5.1811369
18. Ray-Coquard I, Casali PG, Croce S, et al.: ESGO/EURACAN/GCIG guidelines for the management of patients with uterine sarcomas. Int J Gynecol Cancer. 2024, 34:1499-521. 10.1136/ijgc-2024-005823
19. Desar IM, Ottevanger PB, Benson C, van der Graaf WT: Systemic treatment in adult uterine sarcomas . Crit Rev Oncol Hematol. 2018, 122:10-20. 10.1016/j.critrevonc.2017.12.009