Cureus
Part of SPRINGER NATURE

Open Access Case Report

Bordetella bronchiseptica-Associated Granulomatous Lymphadenopathy in an Immunocompetent Host: A Case Report and Review of the Literature

Review began 11/14/2026
Review ended 11/20/2026
Published 11/24/2026

© **Copyright** 2026
Pata et al. This is an open access article distributed under the terms of the Creative Commons Attribution License CC-BY 4.0., which permits unrestricted use, distribution, and reproduction in any medium, provided the original author and source are credited.

DOI: 10.7759/cureus.120182

Ramakanth Pata [1, 2, 3], Mithun Suresh [4], Joanna Kristeva [5, 4]

1. Pulmonary and Critical Care Medicine, CentraCare Health System, St. Cloud, USA 2. Pulmonary and Critical Care Medicine, One Brooklyn Health, New York, USA 3. Pulmonary and Critical Care Medicine, University of Cincinnati Medical Center, Cincinnati, USA 4. Internal Medicine, CentraCare Health System, St. Cloud, USA 5. Health, University of Phoenix, Phoenix, USA

Corresponding author: Ramakanth Pata, cookybrey1@gmail.com

Abstract

Bordetella bronchiseptica is a Gram-negative bacterium that commonly causes respiratory infections in animals, particularly dogs and pigs. Human infections are rare and predominantly occur in immunocompromised individuals. Granulomatous lymphadenopathy mimicking sarcoidosis is an unusual potential presentation of this infection. We report the case of a 61-year-old man without a significant medical history who presented with a two-month history of abdominal pain, unintentional weight loss, night sweats, and decreased oral intake. CT of the chest revealed right hilar and subcarinal lymphadenopathy without associated pulmonary parenchymal abnormalities. Endobronchial ultrasound-guided fine-needle aspiration demonstrated non-necrotizing granulomatous inflammation. Although the histopathological findings initially raised suspicion for sarcoidosis, cultures of the lymph node aspirate subsequently grew *B. bronchiseptica*. Bronchoalveolar lavage studies, including mycobacterial and fungal cultures, were negative. The patient reported recent exposure to a household dog that had died following an infectious illness. He was treated with doxycycline 100 mg twice daily for 21 days, resulting in substantial improvement within one week and complete resolution of constitutional and abdominal symptoms within two weeks. This case describes an unusual presentation of *B. bronchiseptica* infection associated with sarcoid-like granulomatous hilar and mediastinal lymphadenopathy in an apparently immunocompetent host. It highlights the importance of microbiological evaluation of lymph node specimens when investigating unexplained granulomatous inflammation, particularly in patients with potential animal exposure. Recognition of infectious mimics of sarcoidosis is essential to avoid inappropriate immunosuppressive treatment.

Categories: Pulmonology, Infectious Disease
Keywords: bordetella bronchiseptica, granulomatous lymphadenopathy, hilar lymphadenopathy, sarcoid-like reaction, zoonotic infection

Introduction

Granulomatous inflammation of thoracic lymph nodes presents a broad differential diagnosis that includes sarcoidosis, mycobacterial infections, endemic fungal diseases, and malignancy. Establishing the underlying etiology can be challenging, particularly when initial serological studies, microbiological testing, and imaging findings are inconclusive [1].

Bordetella bronchiseptica is a Gram-negative, aerobic, motile coccobacillus that primarily causes respiratory infections in animals, particularly dogs and pigs. It is commonly associated with kennel cough in dogs and respiratory disease in other animal species [2]. Human infection is uncommon and has predominantly been described in individuals with underlying immunosuppression, including patients with HIV infection, malignancy, and organ transplantation [3].

Although zoonotic transmission has been described, infection in immunocompetent individuals remains unusual. Reported clinical manifestations include tracheobronchitis, pneumonia, bacteremia, and other invasive infections [4]. Granulomatous lymphadenopathy mimicking sarcoidosis is an exceptionally unusual presentation.

We describe a case of *B. bronchiseptica* infection presenting with constitutional symptoms and non-necrotizing granulomatous hilar and mediastinal lymphadenopathy in an apparently immunocompetent man. This case highlights the importance of considering unusual infectious etiologies in the evaluation of sarcoid-like reactions and emphasizes the diagnostic value of microbiological cultures obtained directly from affected lymph nodes.

How to cite this article
Pata R, Suresh M, Kristeva J (November 24, 2026) Bordetella bronchiseptica-Associated Granulomatous Lymphadenopathy in an Immunocompetent Host: A Case Report and Review of the Literature. Cureus 18(11): e120182. DOI 10.7759/cureus.120182

Case Presentation

A 61-year-old man with no significant past medical history other than a 40-pack-year smoking history presented with a two-month history of right upper and lower quadrant abdominal pain, decreased oral intake, and unintentional weight loss of approximately 15-20 pounds. He also reported night sweats and intermittent dizziness. Before the onset of symptoms, he had remained physically active while working on his cattle farm. Notably, his household dog had died approximately three months before presentation following an infectious illness. On physical examination, the patient was hemodynamically stable, with an oxygen saturation of 94% on room air. He was not in acute respiratory distress, and pulmonary auscultation revealed clear breath sounds bilaterally. The remainder of the physical examination was unremarkable.

Laboratory investigations were largely unremarkable, with a mildly elevated C-reactive protein level of 2.97 mg/dL. An extensive autoimmune evaluation, including antinuclear antibodies, antineutrophil cytoplasmic antibodies, double-stranded DNA antibodies, rheumatoid factor, cyclic citrullinated peptide antibodies, SSA/SSB antibodies, thyroid peroxidase antibodies, and complement levels (C3 and C4), was unrevealing. Testing for HIV, hepatitis B and C, Epstein-Barr virus, herpes simplex virus, SARS-CoV-2, and influenza was negative. Serological testing for endemic fungal infections, including *Blastomyces* and *Histoplasma*, was also negative (Table *1*).

Laboratory test	Result	Reference
C-reactive protein	2.97 mg/dL	<0.3 mg/dL
Antinuclear antibody	Negative	Negative
Antineutrophil cytoplasmic antibodies	Negative	Negative
Anti-double-stranded DNA antibodies	Negative	Negative
Rheumatoid factor	Negative	Negative
Cyclic citrullinated peptide antibodies	Negative	Negative
SSA/SSB antibodies	Negative	Negative
Thyroid peroxidase antibodies	Negative	Negative
Complement levels (C3 and C4)	Negative	Negative
HIV antigen	Negative	Negative
Hepatitis B and C antibodies	Negative	Negative
Epstein-Barr virus PCR in serum	Negative	Negative
SARS-CoV-2 PCR	Negative	Negative
Influenza PCR	Negative	Negative
Blastomyces and *Histoplasma* antibodies	Negative	Negative

TABLE 1: Relevant laboratory investigations.

CT of the chest demonstrated right hilar and subcarinal lymphadenopathy measuring up to 2 cm, without evidence of an associated pulmonary parenchymal process (Figures *1*-*3*).

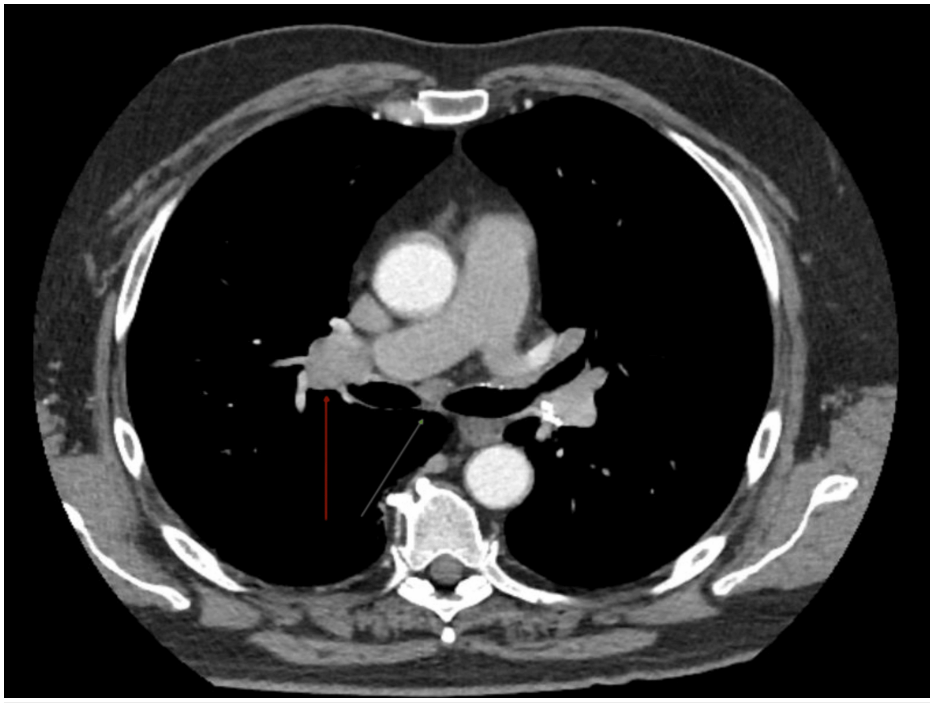

FIGURE 1: CT chest, axial view, soft-tissue window at the level of the carina, demonstrating lymph node enlargement at station 7 (green arrow) and station 10R (red arrow).

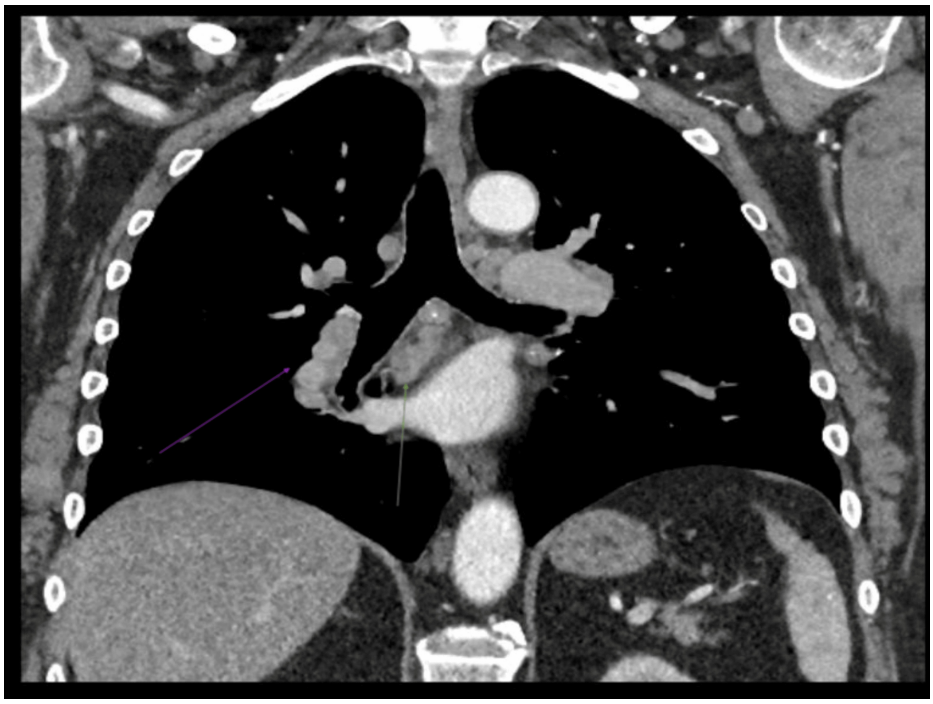

FIGURE 2: CT chest, coronal view, soft-tissue window, demonstrating enlarged lymph nodes at station 7 (green arrow) and station 11R (purple arrow).



FIGURE 3: CT chest, coronal view, lung window, demonstrating no parenchymal involvement (blue arrow).

Splenic calcifications were also noted, consistent with prior granulomatous disease. CT imaging of the abdomen and pelvis revealed no acute abnormalities.

Given the unexplained thoracic lymphadenopathy, the patient underwent endobronchial ultrasound (EBUS)-guided lymph node sampling. Enlarged lymph nodes were identified at stations 7, 10R, and 11R. Fine-needle aspiration demonstrated non-necrotizing granulomatous inflammation (Figure *4*).

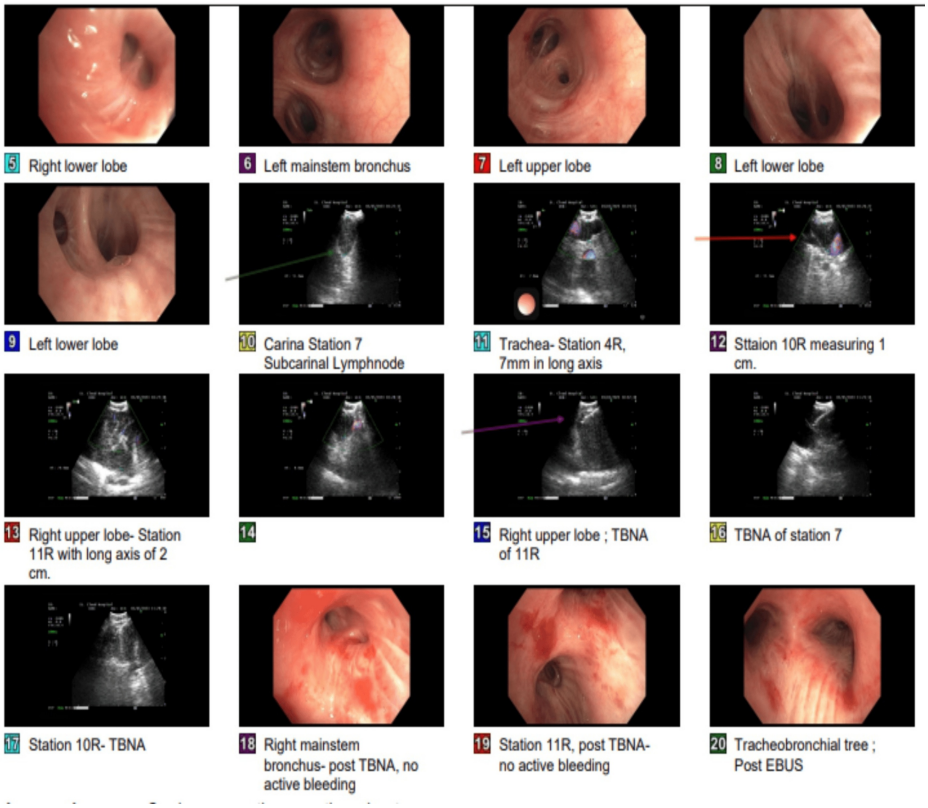

FIGURE 4: Endobronchial ultrasound-guided transbronchial needle aspiration of enlarged lymph nodes at station 7 (green arrow), station 10R (red arrow), and station 11R (purple arrow).

EBUS, endobronchial ultrasound

Acid-fast bacilli, Grocott-Gomori methenamine silver, and periodic acid-Schiff stains were performed on the lymph node specimen and were negative for organisms. Microbiological cultures of the lymph node station 11R aspirate subsequently grew *B. bronchiseptica*, whereas cultures from the other sampled lymph node stations showed no microbial growth (Table *2*).

Antibiotic	Minimum inhibitory concentration (mcg/mL)	Interpretation
Piperacillin/tazobactam	≤8/4	Susceptible
Cefepime	>16	Resistant
Ceftazidime	>16	Resistant
Meropenem	≤0.12	Susceptible
Aztreonam	>16	Resistant
Ciprofloxacin	2	Intermediate
Levofloxacin	≤0.5	Susceptible
Amikacin	16	Susceptible
Gentamicin	4	Susceptible
Tobramycin	4	Susceptible
Trimethoprim/sulfamethoxazole	≤0.5/9.5	Susceptible

TABLE 2: Culture and susceptibility results for Bordetella bronchiseptica obtained via fine-needle aspiration from station 11R.

In contrast, bronchoalveolar lavage studies were negative, including mycobacterial and fungal cultures and the respiratory pathogen panel.

In the context of the positive lymph node culture, compatible clinical presentation, and potential animal exposure, the patient was treated with doxycycline 100 mg orally twice daily for 21 days. At follow-up one week after initiating therapy, he reported substantial improvement in abdominal pain and constitutional symptoms. His symptoms resolved completely within two weeks, accompanied by gradual improvement in appetite and weight. Repeat CT of the chest three months later revealed a significant decrease in lymph node size.

Discussion

A comprehensive literature search was conducted using MEDLINE, PubMed, Embase, Scopus, Web of Science, and the Cochrane Library to identify previously reported cases of *B. bronchiseptica* infection associated with granulomatous intrathoracic lymphadenopathy. The search covered publications from January 1980 through November 2026 and included combinations of the following search terms: “Bordetella bronchiseptica”, “granulomatous lymphadenitis”, “intrathoracic lymphadenopathy”, “mediastinal lymphadenopathy”, and “lymph node infection”. Reference lists of relevant publications were also reviewed to identify additional reports. To the best of our knowledge, no previous case describing the combination of granulomatous intrathoracic lymphadenopathy and isolation of *B. bronchiseptica* from an intrathoracic lymph node has been reported.

Granulomatous lymphadenopathy represents a diagnostic challenge because it can result from a broad range of infectious, inflammatory, and neoplastic conditions. The identification of non-necrotizing granulomas in a patient with constitutional symptoms and thoracic lymphadenopathy frequently raises suspicion for sarcoidosis. However, histopathological findings alone are insufficient to establish this diagnosis, as several infectious diseases can produce similar granulomatous reactions [1].

This case describes an unusual presentation of *B. bronchiseptica* infection associated with non-necrotizing granulomatous hilar and mediastinal lymphadenopathy in an apparently immunocompetent individual. The positive culture obtained directly from the lymph node aspirate, the absence of an alternative identified etiology, the history of potential animal exposure, and the favorable response to antimicrobial therapy collectively support a possible infectious cause of the sarcoid-like presentation.

Microbiology, epidemiology, and zoonotic transmission

B. bronchiseptica is a small (0.5-2 µm), Gram-negative, strictly aerobic, motile coccobacillus belonging to the family Alcaligenaceae. It possesses peritrichous flagella and several virulence factors that facilitate adherence to and colonization of the respiratory epithelium. Unlike *Bordetella pertussis*, it does not produce pertussis toxin [2].

B. bronchiseptica primarily infects animals (guinea pigs, rabbits, cats, dogs, swine, rats, mice, ferrets, foxes, turkeys, monkeys, sheep, skunks, raccoons, horses, and hedgehogs), colonizing the ciliated respiratory epithelium through adhesins and cytolytic toxins that impair host immunity. It is most commonly described in dogs and pigs. It is known to cause a wide spectrum of respiratory illnesses in these animals, ranging from "snuffles" and "kennel cough" to "suppurative bronchopneumonia." In vitro, it has been demonstrated to form biofilms [5].

B. bronchiseptica is prevalent worldwide. In addition to colonizing animals, it can also exist as a free-living organism in lake water across a wide temperature range, from 10°C to 37°C. It can survive in soil for up to 45 days. The incubation period is unknown but has been reported to be up to 10 days [6].

Transmission generally occurs through respiratory droplets, direct contact with infected animals, or exposure to contaminated respiratory secretions (mucopurulent or catarrhal nasal exudates) and fomites. Human-to-human transmission is theoretically possible. The organism adheres to ciliated respiratory epithelial cells through specialized adhesins and produces virulence factors that interfere with mucociliary clearance and host immune responses. Its ability to form biofilms may further contribute to persistent colonization [5].

Although *B. bronchiseptica* is primarily an animal pathogen, human infections have been documented, most frequently in individuals with impaired immunity. Reported predisposing conditions include HIV/AIDS, hematologic and solid-organ malignancies, chemotherapy, chronic pulmonary disease, and solid-organ transplantation [7,8].

Zoonotic transmission from domestic animals, particularly dogs and cats, has been implicated in human infections. In this case, the patient's history of close animal contact, including exposure to cattle and a household dog that had died following an infectious illness, raises the possibility of zoonotic transmission. However, the specific source of infection cannot be definitively established.

Human infections and review of previously reported cases

Clinically, human infection with *B. bronchiseptica* ranges from asymptomatic colonization to severe pneumonia. Reported human infections with *B. bronchiseptica* in immunosuppressed individuals include nosocomial tracheobronchitis, sinusitis, pneumonia, peritonitis, meningitis, and septicemia, whereas whooping cough can occur in healthy individuals [3].

Human infection with *B. bronchiseptica* is uncommon because of the organism's limited capacity to evade intact host immunity. Reported infections are often associated with immunosuppressive conditions, such as HIV infection, chemotherapy, lung cancer, chronic respiratory disease, or organ transplantation [7,9]. In immunocompetent individuals, zoonotic exposure, particularly to domestic cats, dogs, or livestock, appears to be an important risk factor. Because coinfection with other organisms has also been reported, distinguishing asymptomatic colonization from true infection is essential. Underlying risk factors, clinical manifestations, and the absence of alternative infectious etiologies should be considered when determining the clinical significance of an isolate. In this case, the patient's close contact with his recently deceased dog suggests possible zoonotic transmission. Although sporadic infections have been reported in immunocompetent individuals, cases associated with granulomatous inflammation are exceedingly rare.

Woolfrey and Moody published a comprehensive review in 1991 identifying 23 previously reported human infections. They concluded that most clinically significant infections occurred in severely compromised hosts and predominantly involved the respiratory tract [3]. Subsequent reports have expanded the recognized clinical spectrum of this organism, including infections in apparently immunocompetent individuals. Reina et al. described pneumonia in a previously healthy 37-year-old man following thoracic trauma and mechanical ventilation. Repeated exposure to a household dog was considered a possible source of colonization, with subsequent lower respiratory tract infection following intubation [10].

Lo Re et al. reported an infected branchial cleft cyst caused by *B. bronchiseptica* in an otherwise healthy 23-year-old man. The organism was isolated from an infected neck lesion, demonstrating that localized extrapulmonary infection can occur in immunocompetent hosts [11]. de la Torre et al. also reported recurrent pertussis-like respiratory illness caused by *B. bronchiseptica* in an immunocompetent seven-month-old infant [12].

In contrast, most reported infections continue to involve immunocompromised patients. Yacoub et al. described cases of infection in patients with underlying malignancies and reviewed the clinical characteristics of infections in immunosuppressed individuals [4]. Gujju et al. subsequently reviewed an additional 30 reported infections among 29 patients with HIV/AIDS, further illustrating the association between impaired immunity and clinically significant disease [13].

More recently, Tessier et al. described fatal hemorrhagic bronchopneumonia caused by *B. bronchiseptica* in a patient without recognized immunosuppression, demonstrating that severe disease can occur even in

apparently immunocompetent individuals [14].

García-de-la-Fuente et al. evaluated 36 respiratory isolates from 22 patients and found that most patients had underlying immunosuppressive conditions. Eighteen of the 22 patients had respiratory symptoms, and two deaths were associated with respiratory infection. Their study also demonstrated the importance of accurate microbiological identification and antimicrobial susceptibility testing [15].

Although these reports establish that *B. bronchiseptica* can cause a variety of clinical syndromes in humans, previously described presentations have predominantly involved respiratory tract infections, localized infections, or bloodstream infections. In our literature review, we did not identify a previously reported case with the same combination of sarcoid-like intrathoracic granulomatous lymphadenopathy and isolation of *B. bronchiseptica* from an intrathoracic lymph node aspirate. This presentation therefore represents a potentially distinctive clinical manifestation of this uncommon zoonotic pathogen (Table 3).

Study	Host characteristics	Clinical presentation	Important findings
Woolfrey and Moody (1991) [3]	Predominantly immunocompromised	Mainly respiratory infections	Review of 23 previously reported human infections
Yacoub et al. (2014) [4]	Immunocompromised patients	Various infections	Case series and review of infections in immunosuppressed individuals
Reina et al. (1991) [10]	Immunocompetent, 37-year-old man	Pneumonia following thoracic trauma	Repeated dog exposure; respiratory isolation
Lo Re et al. (2001) [11]	Immunocompetent, 23-year-old man	Infected branchial cleft cyst	Organism isolated from an infected neck lesion
de la Torre et al. (2012) [12]	Immunocompetent, seven-month-old infant	Recurrent pertussis-like respiratory illness	Molecular analysis demonstrated identical isolates in the infant and mother
Gujju et al. (2021) [13]	Patients with HIV/AIDS	Predominantly respiratory infections	Review of 30 additional cases in 29 patients
Tessier et al. (2023) [14]	Patient without recognized immunosuppression	Hemorrhagic bronchopneumonia	Fatal infection
García-de-la-Fuente et al. (2015) [15]	Predominantly immunocompromised	Respiratory infections	Analysis of 36 isolates from 22 patients
Present case	Apparently immunocompetent, 61-year-old man	Constitutional symptoms and hilar lymphadenopathy	Non-necrotizing granulomas and positive lymph node culture

TABLE 3: Summary of previously reported human infections with Bordetella bronchiseptica.

Granulomatous inflammation and the sarcoid-like reaction

The clinical presentation in this patient closely resembled sarcoidosis. He had constitutional symptoms, including unintentional weight loss and night sweats, together with right hilar and subcarinal lymphadenopathy. Histopathological examination demonstrated non-necrotizing granulomas, a characteristic finding in sarcoidosis [16].

Sarcoidosis is a multisystem granulomatous disorder of unknown etiology, most commonly involving the lungs and intrathoracic lymph nodes. Bilateral hilar lymphadenopathy, pulmonary involvement, and systemic symptoms such as fatigue, weight loss, and night sweats are recognized manifestations. Histologically, sarcoidosis is characterized by non-necrotizing granulomatous inflammation. However, these findings are not pathognomonic and may be encountered in a variety of infectious and noninfectious conditions [16].

Although right upper and lower quadrant abdominal pain was one of the main presenting symptoms, abdominal and pelvic CT did not reveal any identifiable organic cause. We speculate that the abdominal pain may have been attributable to mesenteric lymphadenitis (possibly microscopic) associated with the underlying granulomatous infection, as mesenteric lymph node involvement can occur in other infectious granulomatous diseases. Although this possibility was not radiologically confirmed, the improvement in abdominal pain following antimicrobial therapy suggests a possible infectious etiology. Nevertheless, the

precise mechanism underlying the abdominal pain remains unclear.

The term "sarcoid-like reaction" is used to describe granulomatous inflammation that resembles sarcoidosis clinically or histologically but occurs secondary to another identifiable process. Infectious causes, particularly mycobacterial and fungal diseases, are important considerations in this setting. Other potential causes include malignancy-associated granulomatous reactions and certain medications [17].

In our case, the isolation of *B. bronchiseptica* from the lymph node aspirate provided an alternative potential explanation for the granulomatous inflammation. Although granulomatous reactions associated with *B. bronchiseptica* infection have not been well characterized in humans, the organism's ability to produce persistent tissue colonization and stimulate host immune responses provides a plausible biological basis for an inflammatory response [5]. Nevertheless, the precise mechanism underlying granuloma formation in this patient remains uncertain.

The distinction between sarcoidosis and an infectious sarcoid-like reaction is clinically important. Misinterpreting infection-associated granulomatous inflammation as sarcoidosis may lead to inappropriate corticosteroid administration or other immunosuppressive therapy, potentially worsening an underlying infection.

Diagnostic considerations

The diagnosis of *B. bronchiseptica* infection can be challenging because of its rarity in humans and the potential for misinterpretation as colonization or contamination. The organism can be recovered using conventional microbiological culture techniques, including blood agar and MacConkey agar, under appropriate aerobic incubation conditions. Accurate species identification is important, particularly because other nonfermenting Gram-negative organisms may have similar preliminary characteristics [2].

In patients presenting with unexplained granulomatous lymphadenopathy, tissue sampling provides an opportunity to obtain both histopathological and microbiological information. EBUS-guided lymph node aspiration is a valuable minimally invasive diagnostic procedure for evaluating mediastinal and hilar lymphadenopathy. In addition to cytological and histological assessment, appropriate specimens should be submitted for bacterial, mycobacterial, and fungal cultures when clinically indicated. In our patient, the positive culture from the lymph node aspirate was a particularly important finding.

Nevertheless, the possibility of contamination during specimen collection or processing must be acknowledged. The isolation of an unusual organism from a lymph node aspirate does not independently establish tissue invasion. In this case, the combination of constitutional symptoms, compatible histopathology, absence of an alternative identified etiology, potential animal exposure, and favorable response to antimicrobial treatment supports the interpretation that the isolate was clinically significant.

This case illustrates the importance of obtaining microbiological cultures directly from affected lymph nodes rather than relying exclusively on histopathological examination.

Treatment and clinical outcome

There are no standardized treatment guidelines for human *B. bronchiseptica* infection because of the limited number of reported cases. Antimicrobial selection should be guided by clinical severity, susceptibility testing, underlying host factors, and the site of infection.

Antibiotics reported to have activity against *B. bronchiseptica* include tetracyclines, fluoroquinolones, trimethoprim-sulfamethoxazole, selected beta-lactam antibiotics, including antipseudomonal penicillins, carbapenems, and aminoglycosides [13]. However, susceptibility patterns may vary. In our case, the organism was resistant to cefepime, ceftazidime, and aztreonam and was intermediate to ciprofloxacin. García-de-la-Fuente et al. demonstrated the activity of doxycycline, minocycline, tigecycline, colistin, and meropenem against the isolates evaluated in their study [15]. Resistance to certain antimicrobial classes, including macrolides and some cephalosporins, has also been reported [9]. Therefore, susceptibility testing is important when an isolate is recovered. Doxycycline may be considered a treatment option if the causative organism is confirmed to be susceptible.

Treatment duration is not well established and should be individualized according to the severity and extent of infection, host immune status, and clinical response. Longer treatment courses (up to several weeks or months) may be necessary in patients with significant immunosuppression or invasive disease [12].

Our patient received doxycycline 100 mg twice daily for 21 days, with substantial improvement within one week and complete resolution of abdominal and constitutional symptoms within two weeks. This favorable response supports the potential clinical significance of the positive lymph node culture and suggests that doxycycline may be an effective treatment option in selected patients with localized infection. The patient's clinical resolution with doxycycline alone suggests that this may be a viable therapeutic approach in

immunocompetent individuals. However, a single case cannot establish the optimal antimicrobial regimen or duration of therapy.

Prevention and disinfection

B. bronchiseptica is a fragile organism and has a short shelf life of a few days on a dry surface. It is susceptible to widely available disinfectants such as 70% ethanol, chloride (<1 ppm), phenols (orthophenylphenol, ortho-benzyl-para-chlorophenol), 2% aqueous glutaraldehyde, and peracetic acid [18,19]. The use of standard precautions and disinfectants when handling infected animals is recommended, especially for immunosuppressed individuals. Human vaccines are not available; however, veterinary vaccines exist. Vaccination of cats may not provide complete protection for immunocompromised patients who own cats; hence, the risk of infection is non-negligible [20].

Clinical significance and limitations

This case highlights several important clinical considerations. First, non-necrotizing granulomatous inflammation should not automatically be attributed to sarcoidosis without adequate evaluation for infectious etiologies. Second, a detailed animal exposure history may provide important diagnostic clues when evaluating unusual respiratory or granulomatous presentations. Finally, microbiological examination of lymph node aspirates can be decisive when routine serological testing and respiratory investigations are unrevealing.

An important limitation of this report is that the precise route and source of infection could not be established. Although the patient's animal exposure history raises the possibility of zoonotic transmission, the household dog's illness was not microbiologically confirmed. Furthermore, contamination during specimen collection cannot be completely excluded.

Despite these limitations, the combination of a positive lymph node culture, compatible clinical features, and favorable response to targeted antimicrobial therapy supports a clinically meaningful association between *B. bronchiseptica* and the patient's granulomatous lymphadenopathy.

Conclusions

B. bronchiseptica should be considered a rare potential cause of infectious sarcoid-like granulomatous lymphadenopathy, even in apparently immunocompetent individuals. This case highlights an unusual clinical presentation characterized by constitutional symptoms, hilar and mediastinal lymphadenopathy, and non-necrotizing granulomatous inflammation, with the organism recovered directly from an intrathoracic lymph node aspirate. Non-necrotizing granulomas are not specific for sarcoidosis, and histopathological findings should always be interpreted in conjunction with clinical and microbiological data. EBUS-guided lymph node aspiration with appropriate microbiological cultures may be particularly valuable in establishing an alternative infectious diagnosis. Our case underscores the importance of maintaining a broad differential diagnosis when evaluating granulomatous lymphadenopathy, particularly in patients with potential animal exposure. Early recognition of infectious mimics of sarcoidosis can prevent unnecessary immunosuppressive therapy and facilitate timely, targeted antimicrobial treatment.

Additional Information

Author Contributions

All authors have reviewed the final version to be published and agreed to be accountable for all aspects of the work.

Concept and design: Ramakanth Pata

Acquisition, analysis, or interpretation of data: Ramakanth Pata, Joanna Kristeva, Mithun Suresh

Drafting of the manuscript: Ramakanth Pata, Joanna Kristeva

Critical review of the manuscript for important intellectual content: Ramakanth Pata, Mithun Suresh

Supervision: Ramakanth Pata, Joanna Kristeva

Disclosures

Human subjects: Informed consent for treatment and open access publication was obtained or waived by all participants in this study. **AI use statement:** The authors used Grammarly as follows: language polishing in the Abstract, Introduction, Case Presentation, Discussion, and Conclusions sections. The authors confirm that they have reviewed and verified all AI-assisted content and take full responsibility for the work. **Conflicts of interest:** In compliance with the ICMJE uniform disclosure form, all authors declare the

following: **Payment/services info:** All authors have declared that no financial support was received from any organization for the submitted work. **Financial relationships:** All authors have declared that they have no financial relationships at present or within the previous three years with any organizations that might have an interest in the submitted work. **Other relationships:** All authors have declared that there are no other relationships or activities that could appear to have influenced the submitted work.

References

1. Jiang M, Li W, He Y, Meng J: Aetiologic diagnosis of thoracic granulomatous diseases: a retrospective multicentre study in South-Central China. BMJ Open. 2025, 15:e102521. 10.1136/bmjopen-2025-102521
2. Goodnow RA: Biology of Bordetella bronchiseptica. Microbiol Rev. 1980, 44:722-38. 10.1128/mr.44.4.722-738.1980
3. Woolfrey BF, Moody JA: Human infections associated with Bordetella bronchiseptica. Clin Microbiol Rev. 1991, 4:243-55. 10.1128/CMR.4.3.243
4. Yacoub AT, Katayama M, Tran J, Zadikany R, Kandula M, Greene J: Bordetella bronchiseptica in the immunosuppressed population - a case series and review. Mediterr J Hematol Infect Dis. 2014, 6:e2014031. 10.4084/MJHID.2014.031
5. Mattoo S, Cherry JD: Molecular pathogenesis, epidemiology, and clinical manifestations of respiratory infections due to Bordetella pertussis and other Bordetella subspecies. Clin Microbiol Rev. 2005, 18:326-82. 10.1128/CMR.18.2.326-382.2005
6. Porter JF, Wardlaw AC: Long-term survival of Bordetella bronchiseptica in lakewater and in buffered saline without added nutrients. FEMS Microbiol Lett. 1993, 110:33-6. 10.1111/j.1574-6968.1993.tb06291.x
7. Dworkin MS, Sullivan PS, Buskin SE, Harrington RD, Olliffe J, MacArthur RD, Lopez CE: Bordetella bronchiseptica infection in human immunodeficiency virus-infected patients. Clin Infect Dis. 1999, 28:1095-9. 10.1086/514761
8. Goldberg JD, Kamboj M, Ford R, Kiehn TE, Gilhuley K, Perales MA: 'Kennel cough' in a patient following allogeneic hematopoietic stem cell transplant. Bone Marrow Transplant. 2009, 44:381-2. 10.1038/bmt.2009.22
9. Monti M, Diano D, Allegrini F, et al.: Bordetella bronchiseptica pneumonia in a patient with lung cancer; a case report of a rare infection. BMC Infect Dis. 2017, 17:644. 10.1186/s12879-017-2736-7
10. Reina J, Bassa A, Llompart I, Borrell N, Gomez J, Serra A: Pneumonia caused by Bordetella bronchiseptica in a patient with a thoracic trauma. Infection. 1991, 19:46-8. 10.1007/BF01643760
11. Lo Re V 3rd, Brennan PJ, Wadlin J, Weaver R, Nachamkin I: Infected branchial cleft cyst due to Bordetella bronchiseptica in an immunocompetent patient. J Clin Microbiol. 2001, 39:4210-2. 10.1128/JCM.39.11.4210-4212.2001
12. de la Torre MJ, de la Fuente CG, de Alegría CR, Del Molino CP, Agüero J, Martínez-Martínez L: Recurrent respiratory infection caused by Bordetella bronchiseptica in an immunocompetent infant. Pediatr Infect Dis J. 2012, 31:981-3. 10.1097/INF.0b013e31825d2e84
13. Gujju VR, Akram B, Shibib DR, McGhee MA, Drevets DA: Bordetella bronchiseptica infections in patients with HIV/AIDS: a case report and review of the literature. Medicine (Baltimore). 2021, 100:e28244. 10.1097/MD.0000000000028244
14. Tessier S, Longo S, Turki M, Numeir M, Le T, Ido F: Fatal hemorrhagic bronchopneumonia caused by Bordetella bronchiseptica in an immunocompetent patient. Germs. 2023, 13:172-6. 10.18683/germs.2023.1381
15. García-de-la-Fuente C, Guzmán L, Cano ME, et al.: Microbiological and clinical aspects of respiratory infections associated with Bordetella bronchiseptica. Diagn Microbiol Infect Dis. 2015, 82:20-5. 10.1016/j.diagmicrobio.2015.01.011
16. Baughman RP, Valeyre D, Korsten P, et al.: ERS clinical practice guidelines on treatment of sarcoidosis . Eur Respir J. 2021, 58:2004079. 10.1183/13993003.04079-2020
17. Prasse A: The diagnosis, differential diagnosis, and treatment of sarcoidosis . Dtsch Arztebl Int. 2016, 113:565-74. 10.3238/arztebl.2016.0565
18. Burnett LC, Lunn G, Coico R: Biosafety: guidelines for working with pathogenic and infectious microorganisms. Curr Protoc Microbiol. 2009, Chapter 1:Unit 1A.1. 10.1002/9780471729259.mc01a01s13
19. Rutala WA: APIC guideline for selection and use of disinfectants . Am J Infect Control. 1996, 24:313-42. 10.1016/s0196-6553(96)90066-8
20. Moore JE, Rendall JC, Millar BC: A doggy tale: risk of zoonotic infection with Bordetella bronchiseptica for cystic fibrosis (CF) patients from live licenced bacterial veterinary vaccines for cats and dogs. J Clin Pharm Ther. 2022, 47:139-45. 10.1111/jcpt.13492