Cureus
Part of SPRINGER NATURE

Open Access Case Report

Epidermoid Cyst of the Penile Shaft: A Case Report

Pankaj Singodia [1], Shalini Sarkar [1], Farah Rana [2], Deb Sanjay Nag [3]

1. Department of Plastic Surgery, Tata Main Hospital, Jamshedpur, IND 2. Department of Pathology, Tata Main Hospital, Manipal Tata Medical College, Jamshedpur, IND 3. Department of Anesthesiology, Tata Main Hospital, Jamshedpur, IND

Corresponding author: Deb Sanjay Nag, ds.nag@tatasteel.com

Review began 11/17/2026
Review ended 11/19/2026
Published 11/23/2026

© **Copyright** 2026
Singodia et al. This is an open access article distributed under the terms of the Creative Commons Attribution License CC-BY 4.0., which permits unrestricted use, distribution, and reproduction in any medium, provided the original author and source are credited.

DOI: 10.7759/cureus.120130

Abstract

Epidermoid cysts are common benign cutaneous lesions, but involvement of the penis is rare. In adults, penile epidermoid cysts usually develop following circumcision, trauma, or penile surgery involving implantation of epidermis into the dermis, so de novo lesions are particularly uncommon. We report a 22-year-old uncircumcised man with no history of penile trauma or surgery who presented with a painless, slowly enlarging swelling on the lateral aspect of the penile shaft that had been present for six months and had recently ulcerated. The lesion was firm, non-tender, and well circumscribed, without induration, rolled edges, or regional lymphadenopathy. Because the ulceration raised the possibility of squamous cell carcinoma or Bowen disease, the lesion was completely excised under spinal anesthesia through an elliptical incision, and the wound was closed primarily. Gross examination revealed a 2.2 × 1.5 × 1 cm cyst filled with pultaceous material. Histopathological examination showed a cyst lined by stratified squamous epithelium with a granular layer and containing lamellar keratin, without skin adnexal structures. The focal surface ulceration did not communicate with the cyst, and there was no dysplasia or malignancy, confirming the diagnosis of an epidermoid cyst. Recovery was uneventful, and there was no recurrence at six months. An ulcerated penile cyst should be completely excised and examined histologically to exclude malignancy, even when the clinical picture favors a benign lesion.

Categories: Plastic Surgery, Pathology
Keywords: epidermoid cyst, pathology, penile, plastic and reconstructive surgery, urology

Introduction

Epidermoid cysts are among the most common benign cutaneous lesions. They usually arise on the face, neck, and upper trunk, and the older term “sebaceous cyst” is a misnomer because the cyst wall contains no sebaceous glands [1]. Penile involvement is rare, and the literature consists largely of isolated case reports [2-4].

In children, penile epidermoid cysts are usually congenital and attributed to abnormal closure of the median raphe. In adults, they typically follow trauma or surgery that implants epidermis into the dermis, such as circumcision or penile augmentation [5-7]. Primary penile epidermoid cysts are distinctly uncommon in adults without such a history [8,9]. Only a few such cases have been reported, mostly on the ventral shaft or near the coronal sulcus, so their clinical presentation, including surface ulceration, is poorly characterized [8,9].

We report a de novo epidermoid cyst on the lateral aspect of the penile shaft in a 22-year-old uncircumcised man. Surface ulceration raised clinical concern for malignancy, and the case illustrates why such lesions should be excised and examined histologically.

Case Presentation

A 22-year-old unmarried, uncircumcised man presented with an asymptomatic swelling on the lateral aspect of the penile shaft. The swelling had been present for six months and had grown slowly and painlessly. He sought care when its surface ulcerated. He had no history of penile trauma, surgery, or instrumentation and had no similar lesions elsewhere on the body.

On examination, there was a firm, non-tender, well-circumscribed subcutaneous swelling on the lateral penile shaft with an overlying superficial ulcer (Figure *1*). The ulcer had no induration, rolled edges, or discharge, and there was no surrounding inflammation or edema. No punctum was seen. There was no inguinal lymphadenopathy. Preoperative laboratory investigations are summarized in Table *1*. Values were within reference ranges except for marginally elevated red blood cell count, hematocrit, and red cell distribution width; marginally decreased mean corpuscular hemoglobin concentration; and a fasting blood glucose level of 102 mg/dL. These minor deviations did not alter management. Serology for HIV-1 and HIV-2, hepatitis B surface antigen, and hepatitis C antibody was negative. No preoperative imaging was

performed. Ultrasonography was considered but not undertaken because the lesion was superficial, discrete, and well circumscribed; it lay on the lateral shaft away from the ventral urethra and showed no clinical signs of urethral or corporal involvement. In addition, the ulceration meant that complete excision for histopathological diagnosis was required regardless of what the imaging showed, so ultrasonography was not expected to change management.

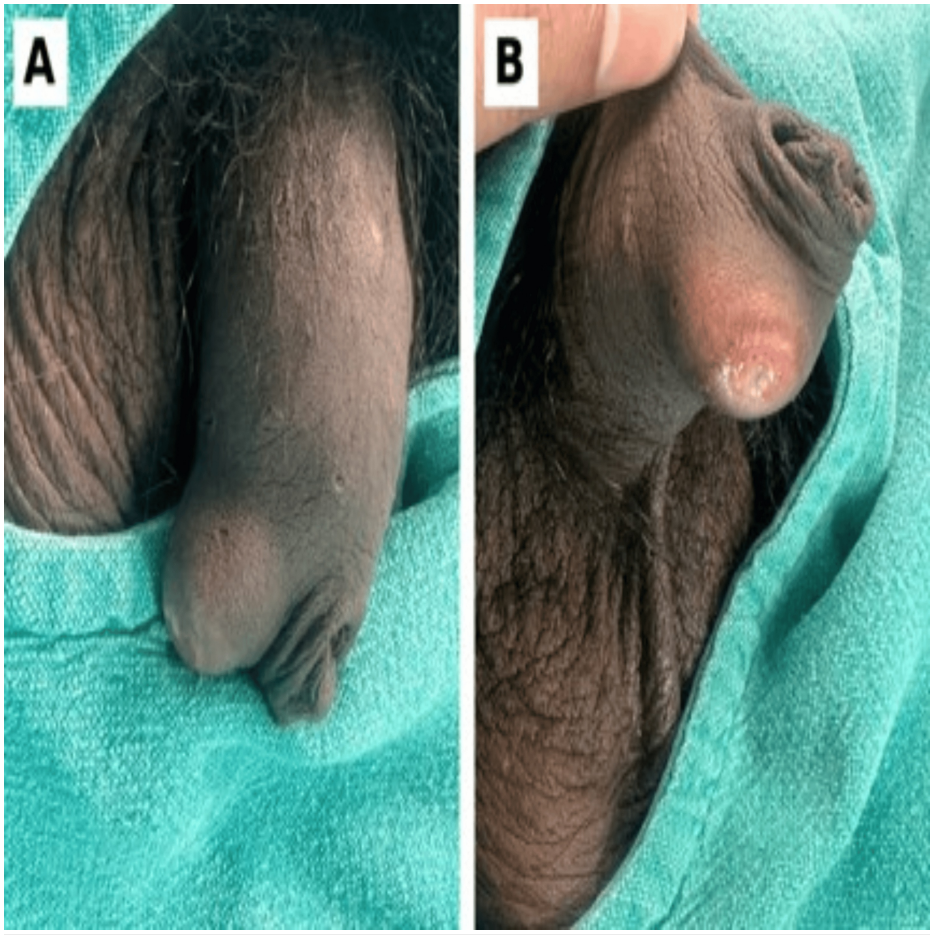

FIGURE 1: Preoperative appearance of the lesion

(A) Dome-shaped, well-circumscribed swelling on the lateral aspect of the penile shaft in an uncircumcised patient. (B) Close-up showing a superficial ulcer at the summit of the swelling, without rolled edges or surrounding induration.

Parameter	Value	Reference range
Hemoglobin (g/dL)	16.1	13.0-17.0
Total leukocyte count (/µL)	7,360	4,000-10,000
Platelet count (/µL)	252,000	150,000-410,000
Serum creatinine (mg/dL)	1.1	0.7-1.3
Fasting blood glucose (mg/dL)	102	70-99
HIV-1 and HIV-2 (fourth-generation antigen-antibody ELISA)	Negative	Negative
Hepatitis B surface antigen	Negative	Negative
Hepatitis C antibody	Negative	Negative

TABLE 1: Preoperative laboratory investigations

Reference ranges are standard adult male reference intervals.

HIV: human immunodeficiency virus, ELISA: enzyme-linked immunosorbent assay

The differential diagnosis included an epidermoid cyst, squamous cell carcinoma, and Bowen disease. Given the ulceration, complete excision for histological diagnosis was preferred over observation or incisional biopsy. Under spinal anesthesia, the lesion was excised intact through an elliptical incision that included the ulcerated overlying skin. The wound was closed primarily with 3-0 nylon sutures, and the specimen was sent for histopathological examination (Figure *2*).

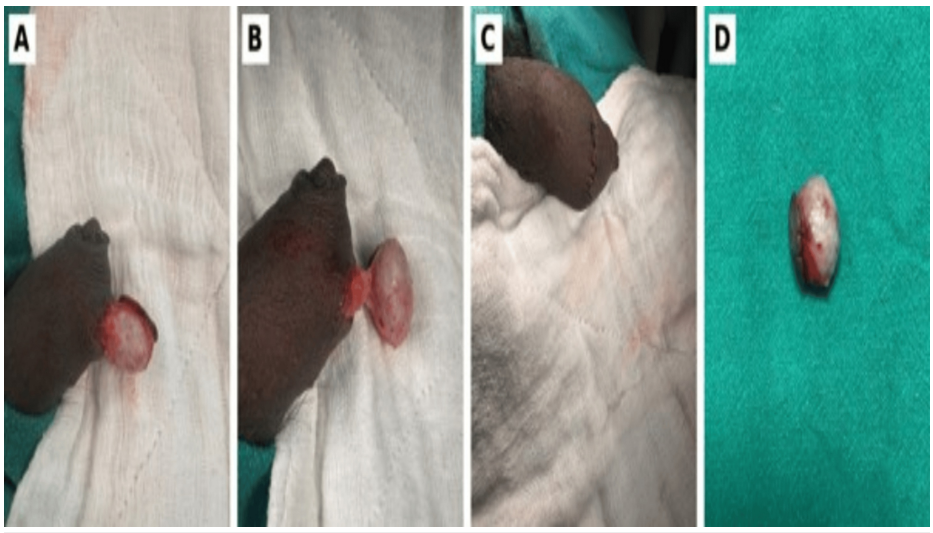

FIGURE 2: Intraoperative findings and excised specimen

(A) Dissection through an elliptical incision exposing the intact cyst wall. (B) Cyst delivered intact before division of its base. (C) Wound after primary closure with 3-0 nylon sutures. (D) Excised specimen.

Grossly, the specimen was a single globular mass measuring 2.2 × 1.5 × 1 cm, partly covered by a 2 x 1 cm ellipse of skin with a 0.5 x 0.5 cm focal ulcer. The cut surface showed a cyst filled with pultaceous material. Microscopy showed a partly ulcerated surface lined by stratified squamous epithelium, beneath which lay a cyst lined by stratified squamous epithelium with an identifiable granular layer and lamellar keratin in its lumen (Figure *3*). The surface ulcer was separated from the cyst by intervening dermis and did not communicate with the cyst lumen. The cyst wall was intact, without rupture or extravasation of keratin into the surrounding dermis, and there was no significant inflammatory infiltrate, foreign-body giant cell reaction, or keratin granuloma. No hair follicles, sebaceous glands, sweat glands, or other skin adnexal structures were present in the cyst wall, and no columnar, mucin-secreting, or urothelial-type epithelium was identified. There was no dysplasia or malignancy. The findings were compatible with a benign epidermoid cyst.

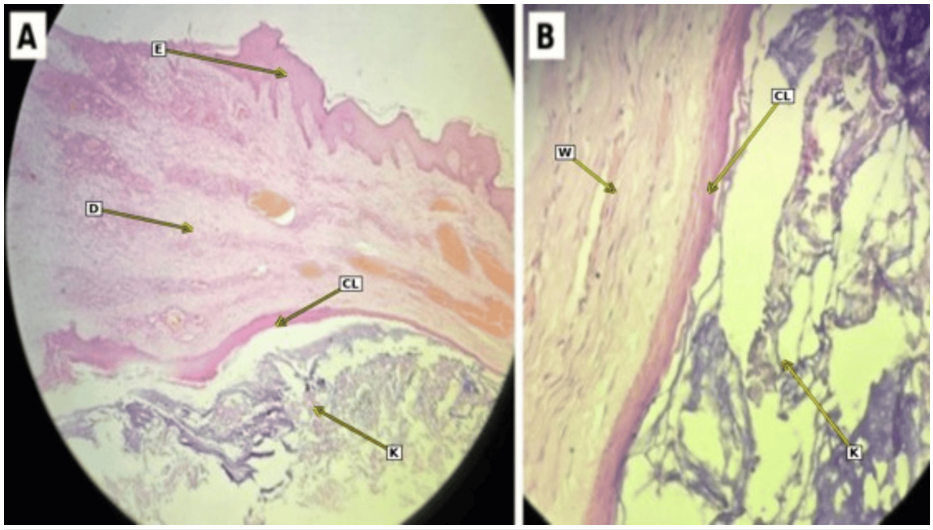

FIGURE 3: Histopathology of the excised lesion

(A) Low-power view showing a partly ulcerated surface lined by stratified squamous epithelium (top), with an underlying cyst lined by stratified squamous epithelium and containing lamellar keratin (bottom); hematoxylin and eosin stain, original magnification ×40. (B) High-power view of the cyst wall showing the stratified squamous epithelial lining (left) with lamellar keratin in the cyst lumen (right); hematoxylin and eosin stain, original magnification ×400.

E: surface epidermis, D: intervening dermis, CL: stratified squamous cyst lining, K: lamellar keratin in the cyst lumen, W: fibrous cyst wall

The postoperative course was uneventful, and the sutures were removed at two weeks. At six-month follow-up, the wound had healed with no recurrence, and the cosmetic and functional outcomes were normal.

Discussion

This case is unusual for three reasons: the patient had no history of circumcision, trauma, or penile surgery; the cyst lay on the lateral shaft; and it presented with surface ulceration. Most reported penile epidermoid cysts are secondary inclusion cysts, and almost all have occurred on the ventral shaft [8,9]. Only a few primary lesions in adults have been described [8,9].

Epidermoid cysts are lined by stratified squamous epithelium with a granular layer and contain lamellar keratin [1,3]. They arise from the follicular infundibulum or from epidermis implanted into the dermis by injury [1,3]. Because the penile shaft has few pilosebaceous units, secondary implantation after circumcision, hypospadias repair, or augmentation is the usual mechanism in adults [4-7]. In the absence of such a history, sequestration of embryonic epidermal rests and occlusion of a pilosebaceous unit have been proposed as possible explanations [10]. Neither can be proven in our patient, and unrecognized minor trauma cannot be fully excluded.

The ulceration was the main clinical concern. Most ulcerated penile lesions are not malignant, but a persistent ulcer over a penile swelling warrants histological evaluation to exclude malignancy. An ulcerated epidermoid cyst of the coronal sulcus has been reported to mimic penile cancer [9]. Malignant transformation of cutaneous epidermoid cysts, usually to squamous cell carcinoma, is rare, with an estimated incidence of 0.011% to 0.045% [11,12]. When it occurs, it may present with pain, rapid growth, or ulceration [12]. Malignant change has not been reported in penile epidermoid cysts, but long-term follow-up after excision is advised [9]. In our patient, the absence of induration, rolled edges, and lymphadenopathy favored a benign lesion, but histopathological examination was necessary to establish the definitive diagnosis.

Ulceration of a benign epidermoid cyst can arise in more than one way. As the cyst enlarges, the overlying skin is stretched and thinned, and pressure atrophy with local ischemia can lead to breakdown of the epidermis; friction from clothing or minor unnoticed trauma can then erode the attenuated skin. Alternatively, rupture of the cyst wall releases keratin into the dermis, which provokes an intense inflammatory and foreign-body granulomatous reaction that may itself ulcerate the surface [1]. In our patient, the intact cyst wall, the absence of inflammation or a keratin granuloma, and the lack of communication between the ulcer and the cyst lumen favor pressure atrophy of the stretched overlying skin, possibly aggravated by friction, rather than cyst rupture.

The differential diagnosis of a cystic penile swelling includes dermoid cyst, median raphe cyst, urethral diverticulum, pilonidal cyst, steatocystoma, and glomus tumor [3]. With ulceration, squamous cell carcinoma and Bowen disease must also be considered. Histology distinguishes these entities (Table *2*). The diagnosis of epidermoid cyst rests on a keratin-filled cyst lined by stratified squamous epithelium with a granular layer and no skin adnexal structures in its wall [1,3]; these features were present in our patient. Dermoid cysts have a similar keratinizing squamous lining but contain adnexal structures, such as hair follicles, sebaceous glands, and sweat glands, within the wall, while median raphe cysts are usually midline and lined by pseudostratified columnar or urothelium-like epithelium, sometimes with mucin-secreting cells, and lack a granular layer and lamellar keratin [13]. Steatocystoma has a thin, folded squamous lining with a compact eosinophilic cuticle, no granular layer, and sebaceous lobules in the wall. A pilonidal cyst usually forms a sinus containing hair shafts surrounded by granulation tissue. A urethral diverticulum communicates with the urethra and is lined by urothelium. A glomus tumor is a solid lesion composed of glomus cells around vascular channels, and squamous cell carcinoma and Bowen disease show epithelial atypia, which was absent here. None of these alternative features were present in our patient.

Lesion	Lining epithelium	Distinguishing histological features
Epidermoid cyst (present case)	Stratified squamous epithelium with a granular layer	Lumen filled with lamellar keratin; no skin adnexal structures in the wall
Dermoid cyst	Stratified squamous epithelium with a granular layer	Hair follicles, sebaceous glands, and/or sweat glands within the cyst wall; hair shafts may be present in the lumen
Median raphe cyst	Pseudostratified columnar or urothelium-like epithelium, occasionally squamous	Usually ventral midline; may contain mucin-secreting cells; no granular layer and no lamellar keratin
Steatocystoma	Thin, folded stratified squamous epithelium without a granular layer	Compact, wavy eosinophilic cuticle on the luminal surface; sebaceous lobules in the wall
Pilonidal cyst/sinus	Squamous-lined sinus tract or granulation tissue	Free hair shafts, foreign-body giant cells, and chronic inflammation
Urethral diverticulum	Urothelium (transitional epithelium)	Communicates with the urethral lumen
Squamous cell carcinoma/Bowen disease	Atypical squamous epithelium	Cytological atypia, dyskeratosis, and mitoses; invasion in squamous cell carcinoma

TABLE 2: Clinicopathological differential diagnosis of penile cystic and ulcerated lesions

Histopathological features that distinguish epidermoid cysts from other cystic and ulcerated lesions of the penis[1,3,13]. Features of the present case are shown in the first row.

Complete excision with preservation of the cyst wall is the treatment of choice, allows histopathological diagnosis, and is associated with a low risk of recurrence [2,4]. Aspiration or incomplete removal increases the risk of recurrence and does not definitively exclude malignancy. Primary closure gave a good cosmetic and functional result in our patient.

This report has limitations. Preoperative ultrasound, which can show a well-defined avascular lesion separate from the urethra and corpora, was not performed for the reasons given above. Follow-up was six months, which is short for detecting late recurrence, and the absence of recurrence should therefore be interpreted with caution.

Conclusions

Epidermoid cysts can arise de novo on the penile shaft in adults without circumcision, trauma, or prior surgery. Surface ulceration can make a benign cyst clinically indistinguishable from squamous cell carcinoma or Bowen disease. Complete excision followed by histopathological examination established the diagnosis, with no recurrence observed during six months of follow-up and good cosmetic and functional outcomes. Because this follow-up is short, continued clinical review for late recurrence is advisable.

Additional Information

Author Contributions

All authors have reviewed the final version to be published and agreed to be accountable for all aspects of the work.

Concept and design: Deb Sanjay Nag, Pankaj Singodia, Shalini Sarkar, Farah Rana

Acquisition, analysis, or interpretation of data: Deb Sanjay Nag, Pankaj Singodia, Shalini Sarkar, Farah Rana

Drafting of the manuscript: Deb Sanjay Nag, Pankaj Singodia, Shalini Sarkar, Farah Rana

Critical review of the manuscript for important intellectual content: Deb Sanjay Nag, Pankaj Singodia, Shalini Sarkar, Farah Rana

Supervision: Deb Sanjay Nag, Pankaj Singodia, Shalini Sarkar, Farah Rana

Disclosures

Human subjects: Informed consent for treatment and open access publication was obtained or waived by all participants in this study. **AI use statement:** The authors have declared that no AI tools were used during the work or in the drafting of this article. The authors take full responsibility for the work. **Conflicts of interest:** In compliance with the ICMJE uniform disclosure form, all authors declare the following: **Payment/services info:** All authors have declared that no financial support was received from any organization for the submitted work. **Financial relationships:** All authors have declared that they have no financial relationships at present or within the previous three years with any organizations that might have an interest in the submitted work. **Other relationships:** All authors have declared that there are no other relationships or activities that could appear to have influenced the submitted work.

References

1. Hoang VT, Trinh CT, Nguyen CH, Chansomphou V, Chansomphou V, Tran TT: Overview of epidermoid cyst. Eur J Radiol Open. 2019, 6:291-301. 10.1016/j.ejro.2019.08.003
2. Lachkar S, Boualaoui I, Ibrahimi A, Hamada S, El Sayegh H, Nouini Y: Epidermoid cyst of the penis: a case report. Int J Surg Case Rep. 2025, 129:111181. 10.1016/j.ijscr.2025.111181
3. Kumaraguru V, Prabhu R, Kannan NS: Penile epidermal cyst: a case report. J Clin Diagn Res. 2016, 10:05-6. 10.7860/JCDR/2016/18246.7794
4. Woldemichael MA, Alemayehu EM, Asmare BZ: Post-circumcision penile epidermal inclusion cyst in an 8-year-old: a rare late complication of neonatal surgery. Urol Case Rep. 2026, 68:103541. 10.1016/j.eucr.2026.103541
5. Jung JH, Eom M, Arkoncel FR, et al.: Penile epidermal cyst in a patient with augmentation penoplasty. Korean J Urol. 2013, 54:207-8. 10.4111/kju.2013.54.3.207
6. Okeke LI: Epidermal inclusion cyst as a rare complication of neonatal male circumcision: a case report. J Med Case Rep. 2009, 3:7321. 10.4076/1752-1947-3-7321
7. Park HJ, Park NC, Park SW, Jern TK, Choi KU: Penile epidermal inclusion cyst: a late complication of penile girth enhancement surgery. J Sex Med. 2008, 5:2238-40. 10.1111/j.1743-6109.2008.00888.x
8. Unsal A, Cimentepe E, Saglam R: Penile epidermoid cyst in an elderly patient. Int Urol Nephrol. 2002, 34:229-30. 10.1023/a:1023206126821
9. Cormio L, Mancini V, Sanguedolce F, et al.: Epidermoid cyst of the coronal sulcus mimicking penile cancer: a case report. J Med Case Rep. 2014, 8:179. 10.1186/1752-1947-8-179
10. El-Shazly M, Ghobashy A, Allam A, et al.: Penile epidermal inclusion cyst. Case Rep Urol. 2012, 2012:191343. 10.1155/2012/191343
11. Cappello ZJ, Kasdan ML, Augenstein AC, Shaheen SP: Squamous cell carcinoma in an epidermoid cyst. Eplasty. 2013, 13:44.
12. Frank E, Macias D, Hondorp B, Kerstetter J, Inman JC: Incidental squamous cell carcinoma in an epidermal inclusion cyst: a case report and review of the literature. Case Rep Dermatol. 2018, 10:61-8. 10.1159/000487794
13. Amaranathan A, Sinhasan SP, Dasiah SD: Median raphe cysts of the prepucial skin, with triple histological linings: a case report and review of the literature. J Clin Diagn Res. 2013, 7:1466-8. 10.7860/JCDR/2013/6168.3158