Cureus
Part of SPRINGER NATURE

Open Access Case Report

Novel Ribbon Gauze-Assisted Peritoneal Dissection Technique for Open Pre-peritoneal Mesh Hernioplasty of an Epigastric Hernia

Tapan K. Nayak [1]

1. Department of General Surgery, Veer Surendra Sai Institute of Medical Sciences and Research, Sambalpur, IND

Corresponding author: Tapan K. Nayak, drtapannayak@gmail.com

Review began 11/12/2026
Review ended 11/15/2026
Published 11/20/2026

© Copyright 2026
Nayak. This is an open access article distributed under the terms of the Creative Commons Attribution License CC-BY 4.0., which permits unrestricted use, distribution, and reproduction in any medium, provided the original author and source are credited.

DOI: 10.7759/cureus.119978

Abstract

A 65-year-old male presented with a two-year history of progressively increasing epigastric swelling associated with burning discomfort during physical activity. Clinical examination and imaging confirmed an epigastric hernia with an approximately 3-cm fascial defect containing preperitoneal fat and a small portion of omentum. Open preperitoneal mesh hernioplasty was performed under spinal anaesthesia. A sterile ribbon gauze measuring 40 cm in length and 1.5 cm in width was introduced sequentially into the preperitoneal plane from different directions using controlled reciprocating movements to facilitate progressive circumferential separation of the peritoneum from the overlying fascial structures. Following adequate dissection, a 13 × 13 cm lightweight polypropylene mesh was placed with adequate overlap and secured using interrupted sutures, followed by primary closure of the fascial defect. No peritoneal injury or intraoperative complications occurred. The postoperative recovery was uneventful, and the patient was discharged on the third postoperative day. At six-month follow-up, there was no clinical evidence of hernia recurrence, seroma, or chronic pain. Ribbon gauze-assisted preperitoneal dissection may represent a simple and potentially useful technique for developing the preperitoneal working space during open epigastric hernia repair. Further studies are required to establish its reproducibility, safety, and comparative effectiveness.

Categories: General Surgery
Keywords: blunt dissection, epigastric hernia, hernioplasty, preperitoneal mesh repair, ribbon gauze

Introduction

Epigastric hernias are primary ventral abdominal wall hernias that occur through defects in the linea alba between the xiphoid process and the umbilicus. They commonly arise due to protrusion of preperitoneal fat, although the hernia sac may occasionally contain omentum or bowel [1]. Patients may present with a palpable swelling, localized discomfort, or pain, particularly during physical exertion. Clinical examination, supplemented by ultrasonography or computed tomography when required, helps establish the diagnosis and assess the size and contents of the defect [2]. The European Hernia Society classifies primary abdominal wall hernias according to their anatomical location and defect width, facilitating standardized clinical assessment and reporting [3].

Surgical repair is recommended for symptomatic epigastric hernias, with mesh reinforcement generally preferred to reduce the risk of recurrence. Open preperitoneal flat mesh repair is an established approach recommended by the European Hernia Society and Americas Hernia Society guidelines [3,4]. However, adequate development of the preperitoneal plane is essential to facilitate proper mesh deployment, ensure sufficient overlap beyond the fascial defect, and minimize mesh folding or displacement [5]. Dissection of this relatively narrow anatomical plane can be technically challenging, particularly when dense peritoneal attachments are encountered. Conventional sharp and blunt dissection methods require careful tissue handling to avoid inadvertent peritoneal injury and ensure adequate preparation of the mesh-placement space [6].

The present case describes a novel ribbon gauze-assisted technique for controlled blunt dissection and progressive development of the preperitoneal plane during open mesh hernioplasty for an epigastric hernia. The technique utilizes a readily available sterile ribbon gauze, introduced sequentially from different directions using controlled reciprocating movements to facilitate circumferential separation of the peritoneum from the overlying fascial structures. This report aims to describe the technical steps, feasibility, and intraoperative application of this approach, along with the short-term postoperative outcome in the presented patient.

Case Presentation

Clinical presentation

A 65-year-old male presented with a two-year history of swelling over the anterior abdominal wall. The

swelling was insidious in onset and had gradually increased in size. It was associated with a burning sensation, particularly during strenuous physical activity. There was no history of vomiting, irreducibility, or obstipation.

The patient had a history of hypertension, which was well controlled with medication. His body mass index (BMI) was 26.2 kg/m². He had no history of diabetes mellitus, chronic obstructive pulmonary disease, or previous abdominal surgery. He was an ex-smoker and had discontinued smoking five years earlier. Routine preoperative laboratory investigations were within normal limits (Table *1*).

Parameter	Result	Unit	Reference range
Haemoglobin (Hb)	14.2	g/dL	13.0–17.0
Haematocrit (Hct)	42	%	40–50
Total leukocyte count (TLC)	7.2	×10³/µL	4.0–11.0
Platelet count	250	×10³/µL	150–400
Prothrombin time (PT)	12.5	seconds	11.0–14.0
International normalized ratio (INR)	1.0	ratio	0.8–1.2
Activated partial thromboplastin time (aPTT)	30	seconds	25–35
Blood urea	28	mg/dL	15–40
Serum creatinine	0.9	mg/dL	0.7–1.3
Sodium (Na^+)	140	mmol/L	135–145
Potassium (K^+)	4.2	mmol/L	3.5–5.0
Total bilirubin	0.7	mg/dL	0.2–1.2
Aspartate aminotransferase (AST)	24	U/L	<40
Alanine aminotransferase (ALT)	26	U/L	<41
Alkaline phosphatase (ALP)	88	U/L	44–147
Random blood glucose (RBG)	98	mg/dL	70–140
HIV I/II	Non-reactive	-	Non-reactive
Hepatitis B surface antigen (HBsAg)	Non-reactive	-	Non-reactive
Anti-hepatitis C virus (anti-HCV)	Non-reactive	-	Non-reactive
Routine and microscopic examination	Normal; no protein, glucose, or pus cells	-	Normal

TABLE 1: Preoperative laboratory investigations

Hb, haemoglobin; Hct, haematocrit; TLC, total leukocyte count; PT, prothrombin time; INR, international normalized ratio; aPTT, activated partial thromboplastin time; Na^+, sodium; K^+, potassium; AST, aspartate aminotransferase; ALT, alanine aminotransferase; ALP, alkaline phosphatase; RBG, random blood glucose; HIV, human immunodeficiency virus; HBsAg, hepatitis B surface antigen; HCV, hepatitis C virus.

On general examination, the patient was conscious, alert, and oriented, with stable vital parameters. Abdominal examination revealed a localized, reducible, and non-tender swelling in the epigastric region, with normal overlying skin and no signs of inflammation. An expansile impulse on coughing was elicited approximately 3 cm above the umbilicus. A palpable fascial defect measuring approximately 3 cm in diameter was identified along the linea alba.

Based on the clinical findings, a provisional diagnosis of epigastric hernia was established and classified as PM2W1 according to the European Hernia Society classification [3]. Ultrasonography and computed tomography (CT) of the abdomen confirmed the diagnosis, demonstrating a fascial defect measuring approximately 3 cm in diameter. CT further revealed a hernia sac containing preperitoneal fat and a small portion of omentum, without bowel involvement or additional abdominal wall defects (Figure *1*).

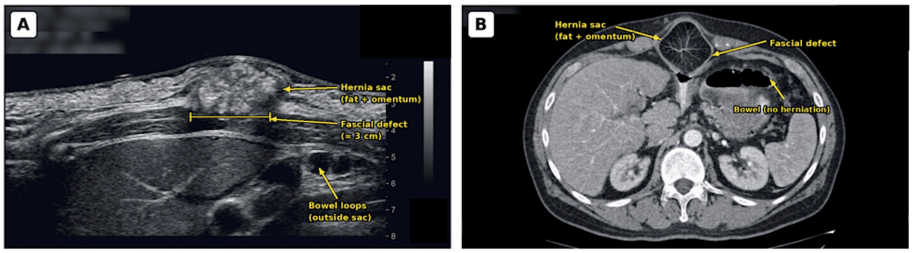

FIGURE 1: Preoperative imaging of the epigastric hernia

(A) Ultrasonography of the anterior abdominal wall, showing a fascial defect in the linea alba measuring approximately 3 cm (bracketed line). The hernia sac projects into the subcutaneous plane and contains echogenic preperitoneal fat and omentum (arrow). Bowel loops lie deep to the abdominal wall, outside the sac (arrow). (B) Axial contrast-enhanced CT of the abdomen, showing the hernia sac containing preperitoneal fat and a small portion of omentum (arrow) protruding through the fascial defect in the linea alba (arrow).

Following preoperative assessment, including cardiovascular and pulmonary fitness evaluation, the patient was considered fit for surgery and planned for open preperitoneal mesh hernioplasty.

Operative procedure

The procedure was performed under spinal anaesthesia. A midline skin incision was made directly over the hernia, and the hernia sac was identified and carefully dissected from the surrounding subcutaneous tissues. The sac contained preperitoneal fat and a small portion of omentum, which were reduced. The fascial defect in the linea alba was exposed, and adhesions between the hernia sac, peritoneum, and underlying structures were carefully released. No peritoneal breach occurred during the procedure.

The margins of the fascial defect were secured using Allis tissue forceps. The fascial edges were gently elevated to facilitate exposure of the operative field. Where required, minimal enlargement of the fascial defect was performed, wherever required, to facilitate adequate dissection and subsequent mesh placement without undue restriction.

Novel ribbon gauze-assisted peritoneal dissection technique

Following identification of the operative plane, the peritoneum was gently separated from the overlying linea alba and posterior fascial sheath. The developed space is referred to throughout this report as the preperitoneal plane; the retromuscular space was not entered.

A full-length, dry, sterile ribbon gauze was used to perform controlled blunt dissection. The length and width of the ribbon gauze could be adjusted according to the operative requirements. In the present case, a ribbon gauze measuring approximately 40 cm in length and 1.5 cm in width was used.

One end of the ribbon gauze was introduced into the potential space between the peritoneum and the overlying fascial layer, initially at the 3 o'clock position. The gauze was advanced gradually using controlled reciprocating movements while maintaining its orientation parallel and close to the fascial sheath. Advancement was continued until almost the entire length of the ribbon gauze had entered the dissected plane. The gauze was subsequently withdrawn gently.

The same manoeuvre was repeated sequentially, beginning at the 9 o'clock, 12 o'clock, and 6 o'clock positions, followed by the remaining intervening areas. This systematic approach facilitated progressive circumferential separation of the peritoneum from the overlying fascial structures and expansion of the preperitoneal working space.

During dissection, dense or resistant peritoneal attachments were carefully released using scissors or electrocautery, as appropriate, to achieve adequate tissue separation while minimizing the risk of peritoneal injury. The dissection was continued until an adequate preperitoneal plane was developed, and its extent was assessed before mesh placement.

The sequential ribbon gauze-assisted dissection manoeuvres and the progressive development of the preperitoneal working space are demonstrated in Figure *2*.

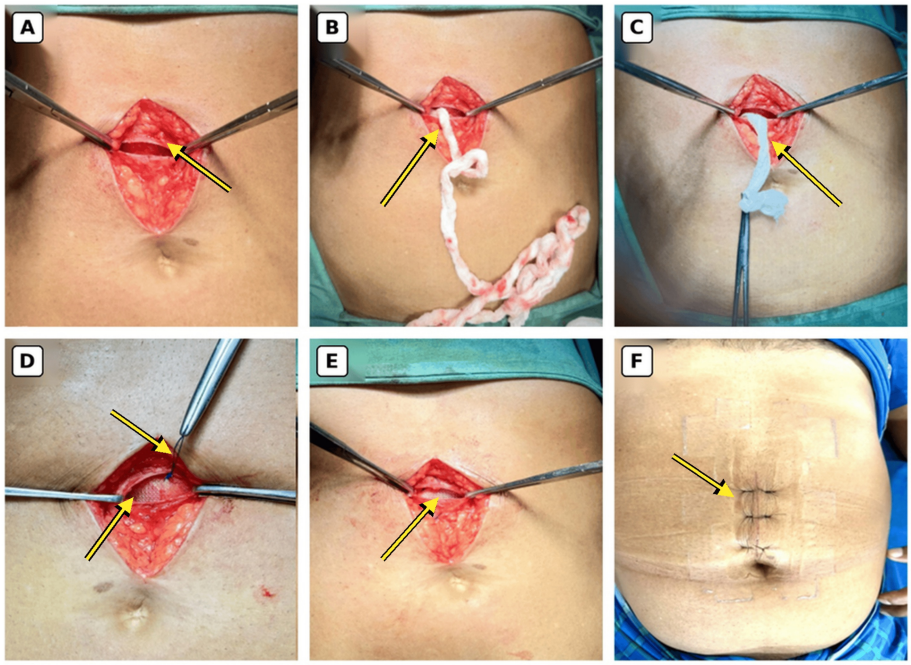

FIGURE 2: Intraoperative photographs demonstrating the novel ribbon gauze-assisted preperitoneal dissection technique for epigastric hernia repair

(A) Exposure of the epigastric fascial defect following dissection of the hernia sac (arrow).
(B) Introduction of sterile ribbon gauze into the potential preperitoneal space (arrow).
(C) Controlled advancement of the ribbon gauze using reciprocating movements to facilitate blunt tissue separation (arrow).
(D) Mesh placed in the preperitoneal plane and held with a central traction suture (arrows).
(E) Mesh secured to the overlying fascia at the 3, 6, 9, and 12 o'clock positions.
(F) Operative site on postoperative day 3.

Mesh placement and fixation

Circumferential dissection extending at least 5 cm beyond the margins of the fascial defect was ensured. The adequacy of the developed plane was assessed digitally by introducing a finger or forceps into the space and evaluating the extent of separation in all directions. The dissected margins were measured using a sterile measuring scale to confirm adequate mesh overlap in all four directions (superior, inferior, left, and right).

A lightweight, macroporous, monofilament polypropylene mesh measuring 13 × 13 cm was placed in the developed preperitoneal plane between the peritoneum and the overlying fascial sheath, ensuring a minimum overlap of 5 cm beyond the margins of the defect in all four directions. The mesh was deployed flat within the dissected space. Open preperitoneal flat mesh repair with subsequent fascial defect closure is an established approach for epigastric and umbilical hernias [3,4].

During mesh placement, a central traction suture using 2-0 polypropylene was applied to the centre of the mesh and secured using an artery forceps, which was kept visible throughout the procedure. This served as a reference point to maintain the orientation and positioning of the mesh and minimize inadvertent displacement during deployment. Following satisfactory positioning, the traction suture was removed.

The mesh was subsequently secured to the overlying fascial sheath at the 3, 6, 9, and 12 o'clock positions using interrupted 2-0 polypropylene sutures, with fixation points placed at least 2 cm beyond the margins of the defect. Following mesh fixation, the fascial defect was closed primarily using interrupted 1-0 polypropylene (non-absorbable monofilament) sutures. The abdominal wall was subsequently closed in a standard layered manner.

The total operative duration was 55 minutes, and the estimated intraoperative blood loss was less than 5 mL. No intraoperative complications were encountered.

Postoperative course and follow-up

No drain was placed. The patient recovered uneventfully from spinal anaesthesia. Oral feeding was initiated four hours after surgery, and ambulation was achieved at six hours postoperatively. Postoperative pain, assessed using the visual analogue scale (VAS), was 3/10 at six hours and 2/10 at 24 hours and was adequately controlled with oral paracetamol.

The surgical wound remained clean and dry, with no evidence of seroma, haematoma, wound infection, or other immediate postoperative complications. The patient had an uneventful postoperative recovery and was discharged on postoperative day 3.

The patient was followed up for six months, with clinical assessments at two weeks, three months, and six months. Ultrasonography performed at three months showed no evidence of recurrence or seroma. At the six-month clinical follow-up, there was no evidence of hernia recurrence or chronic pain. The postoperative course remained uneventful throughout the documented follow-up period.

Discussion

The management of symptomatic epigastric hernias has evolved towards mesh reinforcement to reduce recurrence while maintaining a relatively low risk of postoperative complications. Henriksen et al., in the European Hernia Society and Americas Hernia Society guidelines, recommended open preperitoneal flat mesh repair for most symptomatic umbilical and epigastric hernias [3]. The authors emphasized the importance of appropriate mesh positioning and adequate overlap. In the present case, an open preperitoneal approach was adopted, with placement of a 13 × 13 cm lightweight, macroporous, monofilament polypropylene mesh following circumferential development of the preperitoneal plane. A 5-cm overlap was achieved in all four directions. Although the guidelines suggest a 3-cm overlap for open preperitoneal repair of defects measuring 1-4 cm, the larger overlap in the present case was selected as part of the operative approach and should not be interpreted as an established superior standard.

The effectiveness of mesh reinforcement in epigastric hernia repair has also been demonstrated in observational studies. Fredberg et al., in a nationwide Danish registry study involving 1,112 patients undergoing elective epigastric hernia repair, reported a significantly lower risk of reoperation for recurrence following mesh repair compared with suture repair (hazard ratio 0.28; $p = 0.007$), with a median follow-up of 4.77 years [7]. Their findings support the use of mesh reinforcement and highlight the importance of selecting an appropriate anatomical plane. Similarly, Katawazai et al., in a randomized clinical trial involving 205 patients with medium-sized ventral hernias, reported a one-year recurrence rate of 2 (1.9%) following preperitoneal ventral mesh patch repair compared with 6 (5.9%) following barbed suture repair, although the difference was not statistically significant [8]. These findings provide clinical context for the preperitoneal mesh placement employed in the present case, in which no recurrence or mesh-related complication was identified during six months of follow-up period.

A distinctive feature of the present case was the use of sterile ribbon gauze for controlled blunt dissection and progressive development of the preperitoneal working space. Conventional dissection techniques generally rely on scissors, electrocautery, and blunt surgical instruments to separate tissue planes. In contrast, the described approach utilizes the flexibility and surface texture of ribbon gauze to facilitate sequential sweeping movements and circumferential tissue separation. Lakjuni et al., in a systematic review and network meta-analysis involving 11,037 patients across 21 studies, found no statistically significant differences in recurrence rates among preperitoneal, retromuscular, intraperitoneal, and onlay mesh positions, although the certainty of evidence was low [9]. Their findings emphasize that the choice of operative technique should consider anatomical feasibility and individual surgical requirements. In the present case, ribbon gauze-assisted dissection facilitated the development of the required preperitoneal space without inadvertent peritoneal injury. The procedure was completed in 55 minutes, with an estimated blood loss of less than 5 mL and no intraoperative complications. However, these observations represent the outcome of a single procedure and cannot establish superiority over conventional dissection methods.

The postoperative course was uneventful, with early ambulation, initiation of oral feeding within four hours, minimal postoperative pain, and discharge on the third postoperative day. No seroma, haematoma, wound infection, or recurrence was identified during the six-month follow-up. The technique may offer a practical alternative for developing the preperitoneal plane using an inexpensive and readily available surgical material, particularly in settings where specialized dissection instruments are not readily accessible. Nevertheless, the present report has important limitations, including its single-patient design, absence of a comparative group, and relatively short follow-up period. Furthermore, the proposed mechanical advantages of ribbon gauze have not been evaluated objectively. Future prospective studies involving larger patient populations are required to assess reproducibility, operative efficiency, peritoneal injury rates, postoperative complications, and long-term recurrence. The present case therefore demonstrates the technical feasibility of ribbon gauze-assisted preperitoneal dissection rather than establishing its clinical superiority.

Conclusions

Ribbon gauze-assisted preperitoneal dissection represents a simple and potentially useful technique for

controlled development of the preperitoneal working space during open mesh hernioplasty for epigastric hernia. In the present case, the technique facilitated circumferential tissue separation and adequate mesh placement without inadvertent peritoneal injury, with minimal intraoperative blood loss and an uneventful postoperative recovery. Its use of an inexpensive and readily available surgical material may offer practical advantages, particularly in resource-limited settings. However, further prospective studies involving larger patient populations and longer follow-up periods are necessary to establish its reproducibility, safety, and comparative effectiveness.

Additional Information

Author Contributions

All authors have reviewed the final version to be published and agreed to be accountable for all aspects of the work.

Concept and design: Tapan K. Nayak

Acquisition, analysis, or interpretation of data: Tapan K. Nayak

Drafting of the manuscript: Tapan K. Nayak

Critical review of the manuscript for important intellectual content: Tapan K. Nayak

Disclosures

Human subjects: Informed consent for treatment and open access publication was obtained or waived by all participants in this study. **AI use statement:** The authors used the ChatGPT language model (OpenAI, San Francisco, California) as follows: language polishing, structure or formatting, extensive copy editing or writing support in the Introduction, Case Presentation, Discussion, and Conclusion sections of the manuscript. The AI-generated suggestions were critically reviewed and edited by the authors. All clinical details, surgical descriptions, scientific statements, and references were independently checked and verified by the authors against the original clinical records and relevant literature. The authors exercised independent scientific judgment and take full responsibility for the accuracy, originality, and integrity of the manuscript. The authors confirm that they have reviewed and verified all AI-assisted content and take full responsibility for the work. **Conflicts of interest:** In compliance with the ICMJE uniform disclosure form, all authors declare the following: **Payment/services info:** All authors have declared that no financial support was received from any organization for the submitted work. **Financial relationships:** All authors have declared that they have no financial relationships at present or within the previous three years with any organizations that might have an interest in the submitted work. **Other relationships:** All authors have declared that there are no other relationships or activities that could appear to have influenced the submitted work.

References

1. Asuquo ME, Nwagbara VI, Ifere MO: Epigastric hernia presenting as a giant abdominal interparietal hernia . Int J Surg Case Rep. 2011, 2:243-5. 10.1016/j.ijscr.2011.07.008
2. Corvino A, Corvino F, Tafuri D, Catalano O: Usefulness of dynamic ultrasound in the diagnosis of epigastric herniation of stomach. Ultrasound. 2022, 30:162-6. 10.1177/1742271X211026013
3. Henriksen NA, Montgomery A, Kaufmann R, et al.: Guidelines for treatment of umbilical and epigastric hernias from the European Hernia Society and Americas Hernia Society. Br J Surg. 2020, 107:171-90. 10.1002/bjs.11489
4. Muysoms FE, Miserez M, Berrevoet F, et al.: Classification of primary and incisional abdominal wall hernias . Hernia. 2009, 13:407-14. 10.1007/s10029-009-0518-x
5. Ponten JE, Thomassen I, Nienhuijs SW: A collective review on mesh-based repair of umbilical and epigastric hernias. Indian J Surg. 2014, 76:371-7. 10.1007/s12262-013-0920-6
6. Blonk L, Civil YA, Kaufmann R, Ket JC, van der Velde S: A systematic review on surgical treatment of primary epigastric hernias. Hernia. 2019, 23:847-57. 10.1007/s10029-019-02017-4
7. Fredberg J, Oma E, Brandenburger N, Öztoprak M, Helgstrand F, Jørgensen LN: Repair of elective epigastric hernias in adults: nationwide registry study of short- and long-term complications requiring reoperation. Hernia. 2026, 30:10.1007/s10029-026-03884-4
8. Katawazai A, Wallin G, Sandblom G: Barbed suture versus preperitoneal ventral patch in medium-size ventral hernia repair: randomized clinical trial. BJS Open. 2025, 9:10.1093/bjsopen/zraf099
9. Á Lakjuni E, Ahmed U, Rosenberg J, Baker JJ: Mesh placement and the risk of recurrence and ileus in primary ventral hernia repair: a systematic review and network meta-analysis. Surgery. 2026, 190:109862. 10.1016/j.surg.2025.109862