Cureus
Part of SPRINGER NATURE

Open Access Case Report

Hydrocephalus as a Neurological Presentation of Occult Gastric Adenocarcinoma

Dany Cruz [1], Laura O. Cainé [1], Beatriz Rosa [1], João Mota [1], Ilda Coelho [1], Francisca Pereira [1], Paula Felgueiras [1]

1. Internal Medicine, Unidade Local de Saúde de Barcelos/Esposende, Barcelos, PRT

Corresponding author: Dany Cruz, danycamposcruz@gmail.com

Review began 11/13/2026
Review ended 11/24/2026
Published 11/27/2026

© **Copyright** 2026
Cruz et al. This is an open access article distributed under the terms of the Creative Commons Attribution License CC-BY 4.0., which permits unrestricted use, distribution, and reproduction in any medium, provided the original author and source are credited.

DOI: 10.7759/cureus.120327

Abstract

Leptomeningeal metastasis is a rare complication of gastric cancer. Neurological manifestations may precede the identification of the primary malignancy, posing a diagnostic challenge. We report the case of a 78-year-old woman with a two-month history of rapidly progressive loss of autonomy, gait impairment, and weight loss, who was admitted due to an acute deterioration in mental status. Urinary tract infection and metabolic disturbances were initially considered, but treatment did not result in neurological improvement. Thoracoabdominopelvic computed tomography (CT) showed non-specific gastric wall thickening and regional lymphadenopathy. Cranial CT revealed tetraventricular hydrocephalus. Brain magnetic resonance imaging (MRI) confirmed active hydrocephalus and leptomeningeal enhancement, not typical of normal-pressure hydrocephalus. Cerebrospinal fluid (CSF) cytology identified numerous malignant cells, initially suspected to be from a high-grade lymphoma. CSF flow cytometry did not support a lymphoproliferative disorder. Lumbar puncture was repeated to obtain a larger CSF sample. Repeat cytology confirmed their gastric origin. Upper gastrointestinal endoscopy revealed a gastric ulcer, and biopsy showed a moderately differentiated intestinal-type gastric adenocarcinoma. Because of hypercalcaemia with suppressed parathyroid hormone, bone scintigraphy was performed and showed multifocal uptake suspicious for osteoblastic metastases. The patient's condition continued to deteriorate. Best supportive care was provided, and she died during hospitalisation. This case illustrates the diagnostic challenges of leptomeningeal metastasis presenting with hydrocephalus, particularly when initial investigations suggest alternative diagnoses and the primary malignancy is unknown. It should be considered in the differential diagnosis of secondary hydrocephalus, even in patients without a known primary malignancy.

Categories: Neurology, Internal Medicine, Gastroenterology
Keywords: cerebrospinal fluid cytology, gastric adenocarcinoma, hydrocephalus, leptomeningeal metastasis (lm), occult malignancy

Introduction

Leptomeningeal metastasis consists of the spread of malignant cells to the leptomeninges and cerebrospinal fluid (CSF). Despite the high prevalence of gastric cancer worldwide, leptomeningeal involvement is an uncommon complication, with a reported occurrence of 0.06% in patients with gastric cancer [1,2]. Clinical manifestations are heterogeneous. Leptomeningeal infiltration may impair CSF circulation and absorption, leading to hydrocephalus and contributing to neurological deterioration. Symptoms related to leptomeningeal involvement may precede the identification of the primary malignancy [1].

We report a case of previously undiagnosed gastric adenocarcinoma presenting with rapidly progressive neurological and functional deterioration, associated with hydrocephalus and leptomeningeal metastases. Concomitant metabolic disturbances and initially discordant CSF findings posed diagnostic challenges. This case highlights the importance of considering leptomeningeal metastasis in patients with unexplained hydrocephalus and progressive neurological deterioration, even in the absence of a previously established diagnosis of malignancy.

Case Presentation

A 78-year-old woman with a history of arterial hypertension, type 2 diabetes, and obesity was admitted due to disorientation and inability to walk. Her family reported that she was fully independent, but over the preceding two months, she had developed progressive gait impairment and increasing dependence in activities of daily living. They also reported anorexia and unintentional weight loss of 12 kg over the same period.

Initial laboratory investigations revealed normocytic anaemia (haemoglobin 10.4 g/dL), hyponatraemia (sodium 130 mmol/L), mild hypercalcaemia (albumin-corrected calcium 10.7 mg/dL), and elevated C-reactive protein (15.31 mg/dL). Urinalysis showed marked leukocyturia. Empirical ceftriaxone was initiated for suspected urinary tract infection, and she was admitted to the Internal Medicine ward. No pathogen was isolated from urine. Despite antibiotic treatment and hyponatraemia correction, there was no neurological

improvement. Further investigation revealed an inflammatory pattern of anaemia, without B12 or folate deficiency.

Cranial computed tomography (CT) revealed ventricular enlargement with periventricular oedema, raising the possibility of normal-pressure hydrocephalus. Given the history of weight loss, thoracoabdominopelvic CT was performed and revealed gastric wall thickening involving the fundus and body (Figure *1*), with adjacent lymphadenopathy. Brain magnetic resonance imaging (MRI) demonstrated marked tetraventricular hydrocephalus with transependymal interstitial oedema, consistent with active hydrocephalus (Figure *2*), as well as leptomeningeal enhancement. The findings were not typical of normal-pressure hydrocephalus.

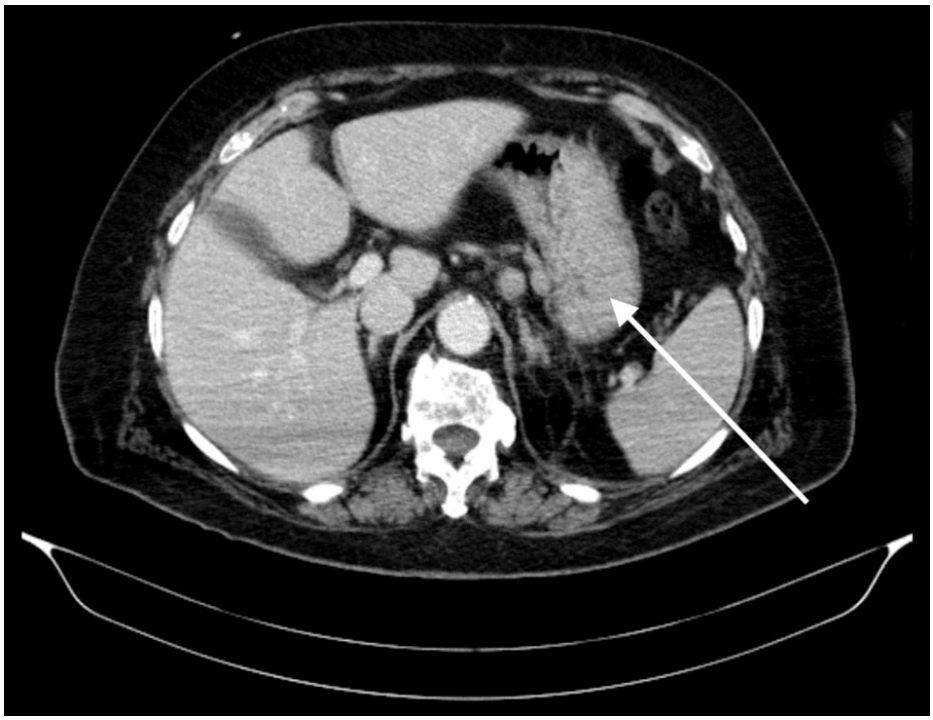

FIGURE 1: Contrast-enhanced abdominal computed tomography (CT) showing gastric wall thickening involving the gastric body (white arrow).

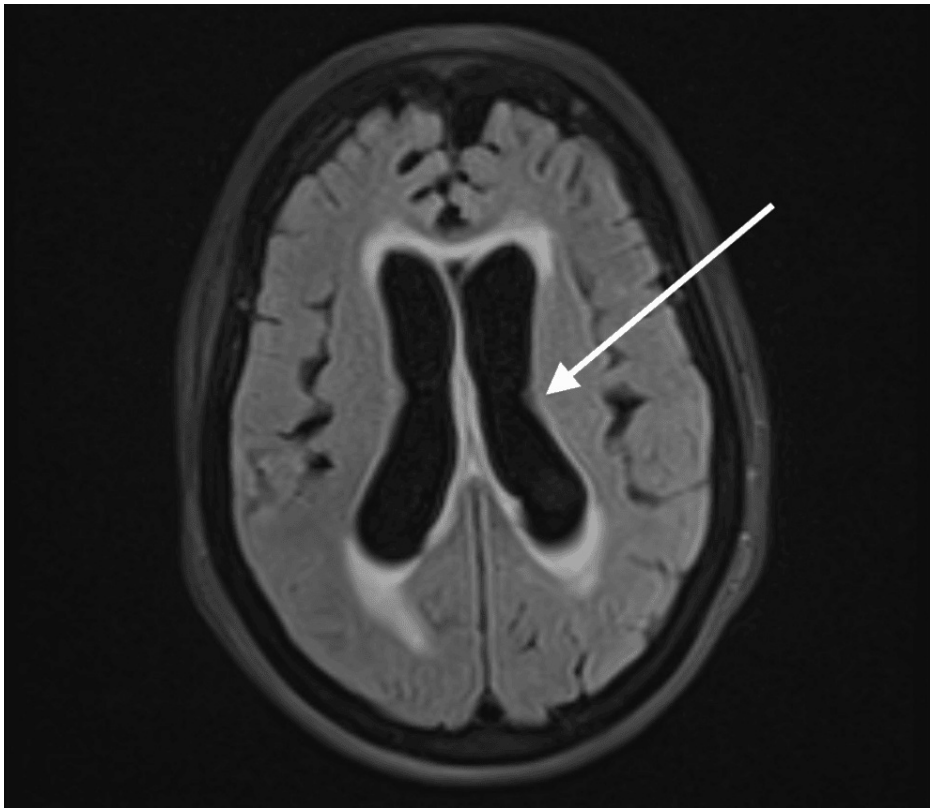

FIGURE 2: Axial T2-weighted fluid-attenuated inversion recovery (T2-FLAIR) brain magnetic resonance imaging (MRI) showing ventricular enlargement with periventricular hyperintensity (white arrow).

Given the significant weight loss and gastric wall thickening, a neoplastic aetiology was considered. Due to suspected secondary hydrocephalus and leptomeningeal enhancement, lumbar puncture was performed. CSF cytological analysis identified numerous malignant cells, initially interpreted as suggestive of high-grade lymphoma. However, the small volume of the CSF sample limited further immunocytochemical characterisation. CSF flow cytometry did not support a lymphoproliferative disorder. Lumbar puncture was repeated to obtain a larger CSF sample, and repeat cytological examination later confirmed the gastric origin of the malignant cells.

In the context of suspected malignancy, mild hypercalcaemia with suppressed parathyroid hormone levels and elevated alkaline phosphatase raised concern for bone metastases. Bone scintigraphy demonstrated multiple areas of heterogeneous uptake, particularly involving the ribs and thoracic spine (Figure *3*). Bone metastases were suspected based on scintigraphic findings but were not confirmed by additional imaging or histological examination. However, these findings suggested malignancy-associated hypercalcaemia, potentially related to bone metastases. A single dose of intravenous zoledronic acid was administered with subsequent normalisation of serum calcium levels. Upper gastrointestinal endoscopy revealed a gastric ulcer. Histological examination of the biopsied tissue revealed moderately differentiated tubular adenocarcinoma of intestinal type, confirming the gastric primary malignancy.

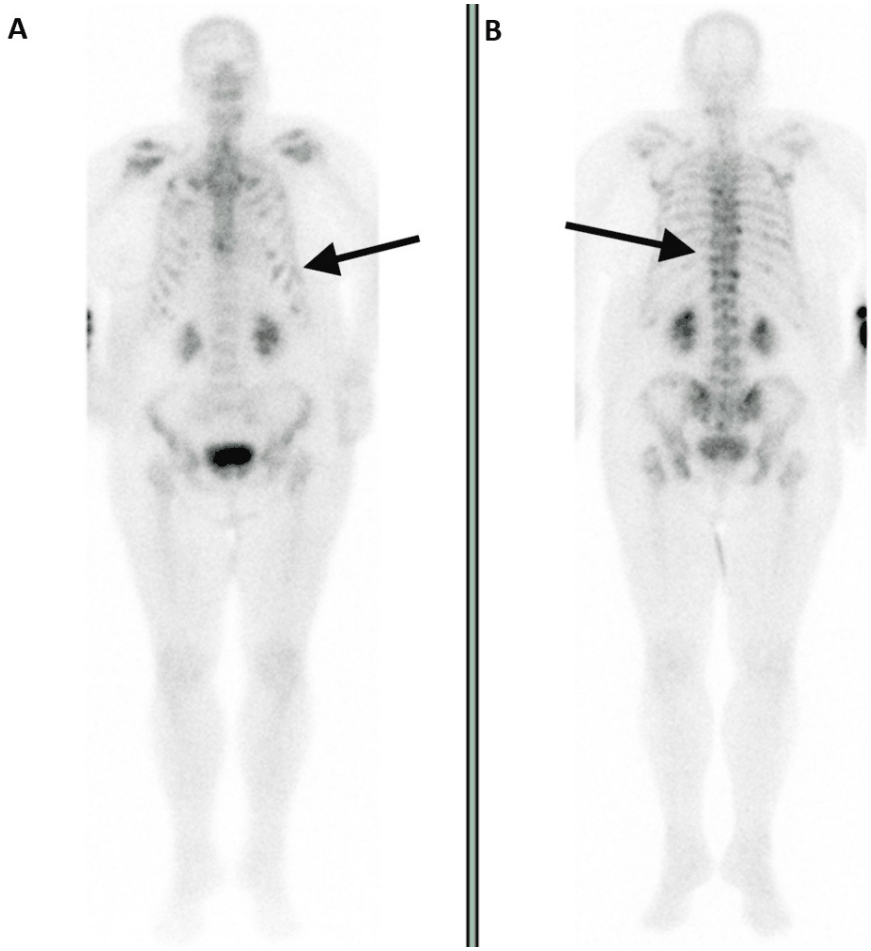

FIGURE 3: (A, B) Whole-body bone scintigraphy in anterior and posterior projections demonstrating multifocal heterogeneous radiotracer uptake, particularly involving the ribs and thoracic spine (black arrows), suspicious for osseous metastases.

Throughout hospitalisation, the patient's neurological and functional status continued to deteriorate. Following multidisciplinary discussion and considering the patient's progressive neurological and functional deterioration, she was not considered eligible for tumour-directed therapy or palliative CSF diversion.

Discussion

The patient presented with progressive gait impairment and loss of autonomy, followed by acute deterioration in mental status. The history of constitutional symptoms and the absence of neurological improvement despite treatment prompted further investigation. However, neurological manifestations of leptomeningeal metastases are often non-specific, making their recognition as the initial presentation of an unknown malignancy particularly challenging [1].

Neuroimaging studies revealed hydrocephalus, with subsequent brain MRI demonstrating signs of active hydrocephalus and leptomeningeal enhancement. These findings suggested a secondary aetiology for the hydrocephalus. In this patient, the combination of neuroimaging and CSF cytological findings was essential to establishing the diagnosis of leptomeningeal metastases [3].

The initial CSF cytological examination suggested high-grade lymphoma. However, the limited sample volume restricted further immunocytochemical characterisation, which may have contributed to diagnostic uncertainty. CSF flow cytometry did not support a lymphoproliferative disorder. Although the reason for the initial cytopathological discrepancy remains unclear, this case illustrates the importance of repeating CSF sampling when initial findings are inconclusive or incongruent. Adequate CSF sampling is important not only for detecting malignant cells but also for further cytopathological and immunocytochemical characterisation [3].

Leptomeningeal metastases as the initial manifestation of gastric cancer have been reported before [1].

However, in this case, the initial suspicion of a haematological malignancy added complexity to the diagnostic process. The histological characteristics of the primary tumour are also noteworthy. Although undifferentiated tumours were reported in 96.5% of patients with gastric leptomeningeal metastases in a recent cohort [4], our patient's gastric biopsy revealed moderately differentiated intestinal-type adenocarcinoma.

The prognosis of leptomeningeal metastases from gastric cancer remains poor, with a median survival of six weeks after diagnosis [4]. This poor prognosis, together with the patient's progressive neurological deterioration and severe functional impairment, led to a multidisciplinary decision to provide best supportive care and symptomatic treatment.

Conclusions

Leptomeningeal metastasis may warrant consideration in the differential diagnosis of secondary hydrocephalus, particularly in patients presenting with rapidly progressive neurological deterioration and constitutional symptoms, even in the absence of a known malignancy. This case highlights the importance of integrating clinical findings, neuroimaging, and CSF analysis to establish the diagnosis. Repeat CSF sampling may provide additional diagnostic information when initial cytological findings are inconclusive or discordant. Although repeat sampling allowed further diagnostic characterisation in this case, it did not alter the therapeutic approach.

Additional Information

Author Contributions

All authors have reviewed the final version to be published and agreed to be accountable for all aspects of the work.

Concept and design: Dany Cruz, Laura O. Cainé, Beatriz Rosa, João Mota, Ilda Coelho, Francisca Pereira, Paula Felgueiras

Acquisition, analysis, or interpretation of data: Dany Cruz, Laura O. Cainé, Beatriz Rosa, João Mota, Ilda Coelho, Francisca Pereira, Paula Felgueiras

Drafting of the manuscript: Dany Cruz

Critical review of the manuscript for important intellectual content: Dany Cruz, Laura O. Cainé, Beatriz Rosa, João Mota, Ilda Coelho, Francisca Pereira, Paula Felgueiras

Supervision: João Mota, Ilda Coelho, Francisca Pereira, Paula Felgueiras

Disclosures

Human subjects: Informed consent for treatment and open access publication was obtained or waived by all participants in this study. **AI use statement:** The authors used ChatGPT (OpenAI, San Francisco, CA, USA) as follows: language polishing, translation in Introduction, Case Description, Discussion. AI was used exclusively to assist with the linguistic dimension, primarily as a translation tool, as English is not the authors' native language. All text was reviewed and verified by the authors to ensure accuracy and consistency with the original content. AI was not involved in data analysis, interpretation of findings, or generation of results. The authors confirm that they have reviewed and verified all AI-assisted content and take full responsibility for the work. **Conflicts of interest:** In compliance with the ICMJE uniform disclosure form, all authors declare the following: **Payment/services info:** All authors have declared that no financial support was received from any organization for the submitted work. **Financial relationships:** All authors have declared that they have no financial relationships at present or within the previous three years with any organizations that might have an interest in the submitted work. **Other relationships:** All authors have declared that there are no other relationships or activities that could appear to have influenced the submitted work.

References

1. Arjani S, Jeon H, Chadha B, Yousuf H, Castellucci E: Leptomeningeal carcinomatosis in gastric cancer: a review. Gastric Cancer. 2025, 28:311-25. 10.1007/s10120-025-01597-8
2. Kim M: Intracranial involvement by metastatic advanced gastric carcinoma . J Neurooncol. 1999, 43:59-62. 10.1023/a:1006156204385
3. Le Rhun E, Weller M, van den Bent M, et al.: Leptomeningeal metastasis from solid tumours: EANO-ESMO Clinical Practice Guideline for diagnosis, treatment and follow-up. ESMO Open. 2023, 8:101624. 10.1016/j.esmoop.2023.101624
4. Byun SH, Kim TS, Ahn S, et al.: Leptomeningeal carcinomatosis in gastric cancer: a single-center retrospective analysis of 86 cases. Gastric Cancer. 2026, 29:250-60. 10.1007/s10120-025-01699-3