Cureus
Part of SPRINGER NATURE

Open Access Case Report

Supraglottic Airway Rescue After Endotracheal Tube Displacement During Craniotomy With Rigid Head Fixation: A Case Report

Alejandro Diaz Maas [1], Marc Edenharter [1]

1. Department of Anesthesiology, Kantonsspital Aarau, Aarau, CHE

Corresponding author: Alejandro Diaz Maas, alejandrodiazmaas@gmail.com

Review began 11/10/2026
Review ended 11/19/2026
Published 11/25/2026

© **Copyright** 2026
Diaz Maas et al. This is an open access article distributed under the terms of the Creative Commons Attribution License CC-BY 4.0., which permits unrestricted use, distribution, and reproduction in any medium, provided the original author and source are credited.

DOI: 10.7759/cureus.120228

Abstract

Endotracheal tube (ETT) displacement during neurosurgery is hazardous when rigid head fixation restricts airway access. A 53-year-old man underwent emergency craniotomy for an acute subdural hematoma with his head rotated in a skull clamp. Intraoperatively, capnography and delivered tidal volume were lost, and the ETT had clinically migrated out of the trachea. Repeat videolaryngoscopy provided no glottic view; an intubation attempt was esophageal, and oxygen saturation fell to 71%. A size 4 AuraGain laryngeal mask (Ambu, Ballerup, Denmark) restored ventilation and oxygenation. Two visually guided intubation attempts through the device failed. With the dura open and oxygen saturation restored, the team continued hematoma evacuation with a plan for immediate clamp release if ventilation failed. Arterial carbon dioxide partial pressure ($PaCO_2$) subsequently reached 72 mmHg. After closure, the clamp was removed, and an oral ETT was placed under flexible endoscopic guidance. This case shows that a supraglottic airway may provide rescue oxygenation during rigid head fixation but does not remove the need to assess ventilation, aspiration risk, and access to definitive rescue.

Categories: Emergency Medicine, Neurosurgery, Anesthesiology
Keywords: airway management, craniotomy, endotracheal intubation, laryngeal mask, neurosurgery

Introduction

Endotracheal tube (ETT) displacement in the operating room is dangerous when airway access is restricted. During neurosurgery, the head may be rotated, fixed in a three-pin skull clamp, distant from the anesthesiologist, and covered by drapes. Supraglottic airway devices, such as the laryngeal mask, sit above the glottis and can restore oxygenation without intubation. They have been described for rescue in this setting, but their role during major intracranial surgery remains debated [1].

Evidence for rescue with the head fixed comes mainly from manikin studies [2-4]. Difficult airway guidelines recommend a supraglottic airway to restore oxygenation after failed intubation and advise limiting further interventions [5,6]. Continuing essential surgery with the device is a high-risk option requiring senior input [5], but guidance does not address an open cranium with rigid head fixation when waking or repositioning may be impractical. Clinical evidence on managing airway loss in this situation is limited. The dilemma is that a device may restore oxygenation without providing adequate ventilation or protection from aspiration.

We report ETT displacement during emergency craniotomy with the head rotated and pinned, followed by completion of surgery using a laryngeal mask. The report describes a carefully judged rescue situation and is not intended to show that surgery should routinely continue with a supraglottic airway. It follows the Anaesthesia Case Report checklist [7].

Case Presentation

A 53-year-old man (estimated weight: 85 kg) presented after a fall and seizure with expressive aphasia and a Glasgow Coma Scale score of 14. History was limited; alcohol and substance misuse were suspected, and fasting status was unknown. Computed tomography showed an acute left subdural hematoma with 6 mm of midline shift (Figure *1*), requiring emergency left craniotomy (American Society of Anesthesiologists physical status 4E) [8].

How to cite this article
Diaz Maas A, Edenharter M (November 25, 2026) Supraglottic Airway Rescue After Endotracheal Tube Displacement During Craniotomy With Rigid Head Fixation: A Case Report. Cureus 18(11): e120228. DOI 10.7759/cureus.120228

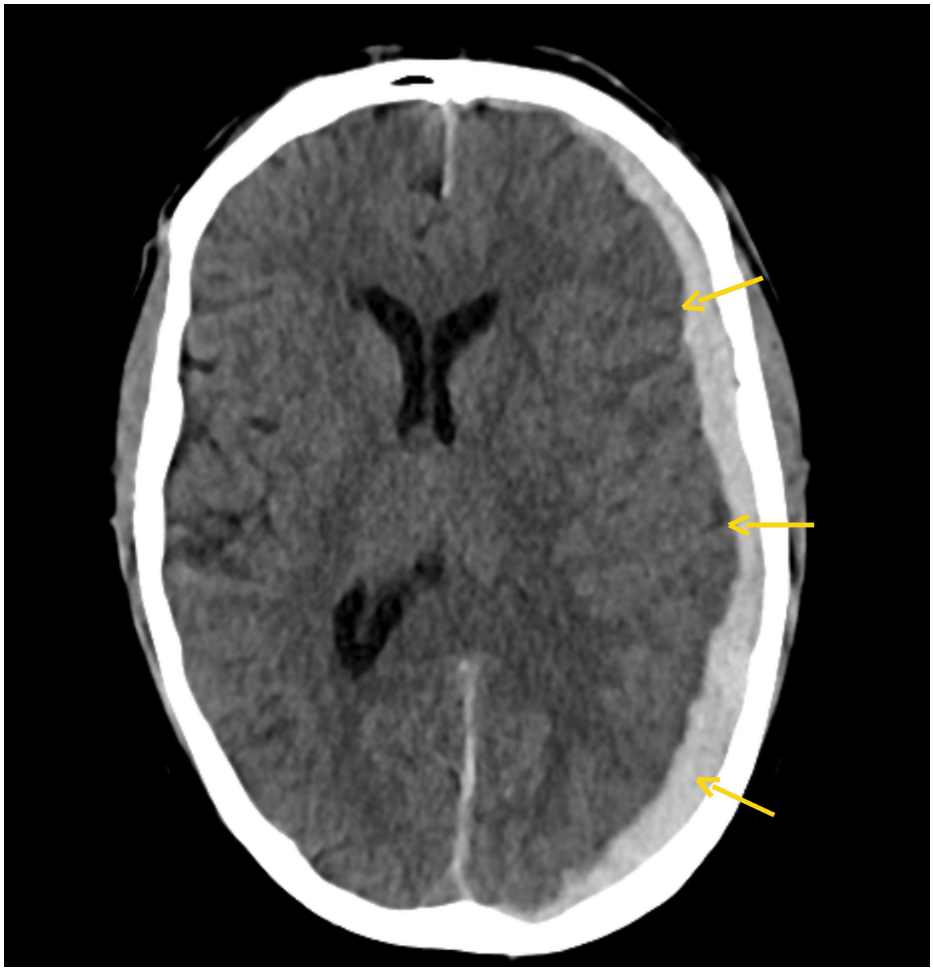

FIGURE 1: Preoperative non-contrast computed tomography of the head

Axial image showing an acute left subdural hematoma (arrows) with mass effect and 6 mm of midline shift. The image is displayed in radiological convention (patient's left on the image right).

After preoxygenation to an end-tidal oxygen fraction above 0.80, rapid sequence induction used target-controlled propofol and remifentanil, and rocuronium 100 mg. M4 videolaryngoscopy (Medcaptain, Shenzhen, China) gave a percentage of glottic opening score of 100%. An 8.0-mm Rusch Microcuff ETT (Teleflex, Athlone, Ireland) was secured at 23 cm at the corner of the mouth with two layers of tape; cuff pressure was below 30 cmH_2O. Ventilation produced high airway pressures and a shark-fin capnogram. The head was rotated to the right in a DORO QR3 radiolucent skull clamp (Pro Med Instruments GmbH, Freiburg, Germany).

At 15:58, capnography and delivered tidal volume were lost with a large leak. The ETT had clinically migrated outward, too far to remain intratracheal (depth at recognition not recorded), and secretions had loosened the tape. We gave 100% oxygen, activated the airway alarm, and worked through a DOPE assessment (displacement, obstruction, pneumothorax, equipment), which identified the displaced tube. While the tube was still partly in the airway, manual ventilation was given; we assume that some gas reached the lungs through the supraglottic region. The emergency team was called, and a videolaryngoscope was prepared. The ETT was removed after advancement failed. To achieve the best possible intubation conditions, rocuronium 100 mg was given. A single repeat videolaryngoscopy provided no glottic view, and the tube was placed in the esophagus, recognized by absent capnography and the presence of gastric sounds. Face-mask ventilation was not attempted because oxygen saturation was still acceptable during this first attempt. Saturation then fell to a nadir of 71% and remained below 92% for an estimated three to four minutes, with mild tachycardia but stable blood pressure.

At 16:06, a size 4 AuraGain laryngeal mask (Ambu, Ballerup, Denmark) restored ventilation and oxygen saturation on the first attempt; cuff pressure was below 50 cmH_2O. A suction catheter would not pass through the gastric channel. Two 20- to 30-second intubation attempts through the ventilated device used a loaded 4.9-mm Vathin flexible endoscope (Vathin, Xiangtan, China), first by the resident and then by a more experienced anesthesiologist. Only mucosa was seen.

Once oxygenation was restored, the anesthesia team and the surgeons held a brief multidisciplinary pause ("10 seconds for 10 minutes," a resuscitation strategy in which the whole team confers and agrees the next steps). The dura was open, and hematoma evacuation was underway, and the surgeon estimated that 45-60 minutes remained; the operation ultimately lasted about 100 minutes. Clamp release required removing the drapes, risked asepsis, and interrupted surgery with the brain exposed. The patient was mechanically ventilated in volume-controlled autoflow mode with a set tidal volume of 500-600 mL, adjusted over time, and peak inspiratory pressure below 20 cmH_2O; leak was not quantified. Oxygen saturation remained above 92%. As oxygenation and hemodynamics were maintained, the team jointly agreed to continue, with immediate clamp release planned for ventilation failure or any further airway emergency. Arterial carbon dioxide partial pressure ($PaCO_2$) was 59 mmHg in the sample taken after induction (14:55), already indicating hypercapnia, and increased to 72 mmHg (pH 7.17) at 16:37, 31 minutes after laryngeal-mask insertion (Figure *2*). Ventilation was most likely increased in response, but the adjustments, end-tidal carbon dioxide, respiratory rate, and minute ventilation were not recorded. Suctioning was performed; no bronchodilators were given, and no recruitment maneuver was made during laryngeal-mask ventilation. The device remained in place for approximately 110 minutes.

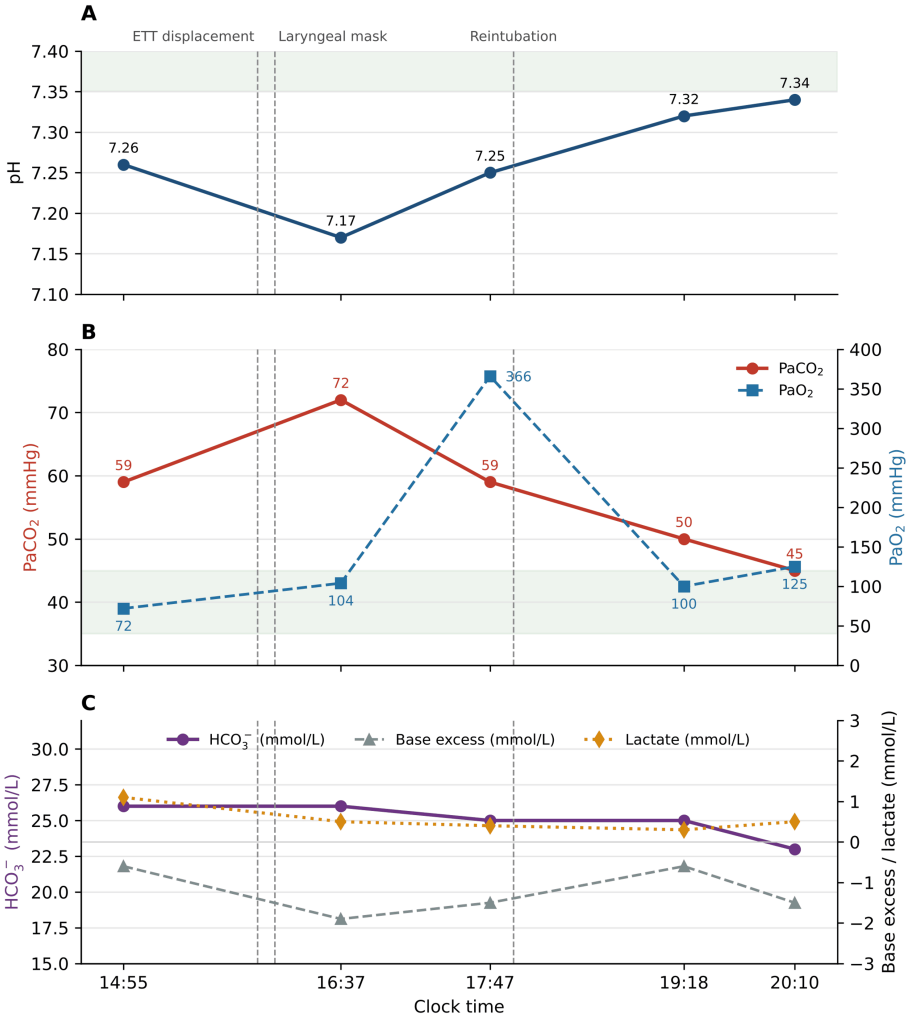

FIGURE 2: Arterial blood gas trends during the perioperative course

(A) pH; (B) $PaCO_2$ (left axis) and PaO_2 (right axis); (C) HCO_3^- (left axis), base excess, and lactate (right axis). Samples: 14:55, after induction; 16:37, 31 minutes after laryngeal-mask insertion; 17:47, end of surgery; 19:18 and 20:10, intensive care. Dashed vertical lines mark endotracheal tube displacement (15:58), laryngeal-mask insertion (16:06), and reintubation (17:58); shaded bands indicate reference ranges. Inspired oxygen fraction at sampling was not recorded. The figure was created using Claude Sonnet 5.5 (Anthropic, PBC, San Francisco, CA, USA).

$PaCO_2$: arterial carbon dioxide partial pressure; PaO_2: arterial oxygen partial pressure; HCO_3^-: bicarbonate

At 17:45, with advanced train-of-four recovery, sugammadex 100 mg was given to permit waking. $PaCO_2$ remained 59 mmHg at 17:47, prompting controlled reintubation. At 17:58, after closure, clamp

removal, and head neutralization, rocuronium 100 mg was given when the train-of-four ratio exceeded 0.90 and abolished all responses. The laryngeal mask was removed, and an oral ETT was placed under flexible endoscopic guidance; oxygen saturation remained above 92%. In intensive care, he was extubated two hours after arrival when he was normocapnic, responsive, and ventilating adequately. Figure *3* summarizes the airway events and arterial blood gas measurements.

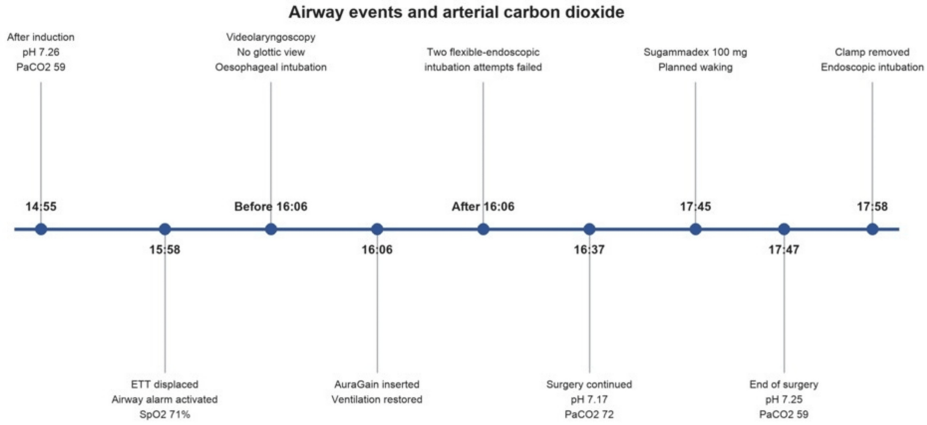

FIGURE 3: Timeline of airway management and arterial blood gas measurements

Times are those recorded contemporaneously. The figure was created using Claude Sonnet 5.5 (Anthropic, PBC, San Francisco, CA, USA).

$PaCO_2$: arterial carbon dioxide partial pressure; SpO_2: peripheral oxygen saturation

On postoperative day four, fever, inflammatory markers, and lung-ultrasound consolidation supported suspected aspiration pneumonia (diagnosed clinically; no chest radiograph or CT was obtained), which was treated with piperacillin-tazobactam without reintubation. On postoperative day nine, he was transferred to a regional hospital in improved condition, with a Glasgow Coma Scale score of 15, residual tiredness and difficulty concentrating, and no focal neurological deficit.

Discussion

A laryngeal mask restored oxygenation after ETT displacement and failed repeat videolaryngoscopy with the head rotated and pinned. It also permitted completion of essential surgery, but ventilation remained suboptimal. The case illustrates that successful intubation before positioning does not predict the conditions for reintubation and that rescue oxygenation does not itself establish that continuing surgery is safe.

Supraglottic airway rescue is consistent with difficult airway guidance [5,6] and manikin studies in restricted positions [2-4]. A narrative review also identifies these devices as useful rescue tools with the head in cranial pins [1]. Manikins, however, do not reproduce secretions, aspiration risk, abnormal respiratory mechanics, or an open surgical field and cannot define when surgery should continue in a patient.

Neither endoscope-guided attempt through the AuraGain showed the glottis. Failure to pass a catheter through the gastric channel and visualization of mucosa alone suggest that device alignment may have been suboptimal despite effective ventilation. Current guidance recommends considering a single visually guided intubation attempt through a functioning supraglottic airway [5]. A second attempt was made by a more experienced anesthesiologist because operator experience might have explained the first failure. Further attempts were avoided. Intubation succeeded after clamp removal, head neutralization, and device removal, although several conditions had changed.

The decision to continue depended on the surgical and rescue context rather than oxygen saturation alone. The dura was open, hematoma evacuation was underway, and releasing fixation would have required removal of the drapes with the brain exposed. Oxygenation, tidal volumes, and hemodynamics were adequate, and the team agreed that any ventilation failure would trigger immediate clamp release and reintubation. Front-of-neck access equipment was available, although the rotated and draped neck would have complicated its use; failed emergency front-of-neck access has been reported in the Fourth National Audit Project [9]. Rigid fixation therefore restricts both reintubation and the final rescue step.

Continuing surgery exposed the patient to aspiration risk because fasting status was unknown and the

gastric channel could not be used. It also accepted impaired carbon dioxide clearance. Hypercapnia can increase intracranial pressure [10] and was undesirable with a subdural hematoma and midline shift. $PaCO_2$ reached 72 mmHg before decreasing to 59 mmHg, and persistent hypercapnia prompted definitive airway control after closure. The subsequent pneumonia was compatible with aspiration, but its timing was uncertain; withdrawal delirium, sedation, and impaired secretion clearance offered alternative opportunities for aspiration.

Sugammadex was given during advanced spontaneous recovery in anticipation of waking. When reintubation was subsequently chosen, rocuronium 1.18 mg/kg produced complete neuromuscular block despite the short interval, consistent with prior reports [11], and quantitative monitoring was important in confirming the response.

Ultrasound can complement waveform capnography in confirming tube position. Anesthesiologists trained in point-of-care ultrasound can use transtracheal imaging to assess tube location directly or evaluate bilateral lung sliding or diaphragmatic motion for indirect evidence of ventilation. In a recent randomized trial of adults undergoing emergency intubation, sensitivities for tracheal placement were 98.2% with transtracheal imaging, 98.2% with lung sliding, and 96.6% with diaphragmatic ultrasound, with median confirmation times of 4.6, 9.4, and 13.4 seconds, respectively [12]. We did not use ultrasound; continuous waveform capnography, which showed the esophageal placement, and a flexible endoscope were available, and ultrasound assessment of tube position was not part of our routine practice.

This report is limited by incomplete recording of ventilator adjustments after 16:37, end-tidal carbon dioxide, respiratory rate, minute ventilation, and inspired oxygen fractions at blood gas sampling. The leak was not quantified, and ultrasound confirmation of tube position was not used. The cause of displacement remains uncertain: wet tape and secretions were observed, but circuit drag cannot be excluded. Sparse blood gas sampling prevents attribution of the carbon dioxide trend to a single cause, and possible underlying obstructive lung disease, suspected clinically from the shark-fin capnogram and high airway pressures without a prior diagnosis, spirometry, or smoking history, may have contributed to the arterial-to-end-tidal gradient. The sample after induction already showed hypercapnia ($PaCO_2$ 59 mmHg), so pre-existing hypercapnia may also have contributed. The failed gastric-channel catheter and absent glottic view may indicate device malposition. Inspection of the main bronchi did not exclude distal aspiration, and the postoperative pneumonia, diagnosed clinically without chest radiography or CT, cannot be attributed to the laryngeal-mask period.

Conclusions

A laryngeal mask can provide rapid rescue oxygenation after ETT displacement during craniotomy with rigid head fixation. Rescue oxygenation alone does not establish that ventilation is adequate or that continuing surgery is safe. Continuing with a supraglottic airway remains a high-risk, time-limited decision when aspiration protection and access to definitive rescue are compromised. In this patient, the decision to continue depended on the surgical stage, the availability of experienced staff, the adequacy of ventilation, and a predefined plan for immediate clamp release. This was a single case and cannot establish a standard of care. The successful outcome does not exclude important risk, and aspiration pneumonia cannot be causally linked to the laryngeal-mask period.

Before rigid fixation, anesthesiologists should plan ETT security, rescue-device placement, criteria for clamp release, and how front-of-neck access would be achieved. When a supraglottic airway restores oxygenation, the team should reassess ventilation, aspiration risk, the surgical stage, and the feasibility of definitive airway control. Ongoing multidisciplinary communication and a clear trigger for clamp release are essential. This case should inform preparation and contingency planning rather than justify routine use of a supraglottic airway during intracranial surgery.

Additional Information

Author Contributions

All authors have reviewed the final version to be published and agreed to be accountable for all aspects of the work.

Concept and design: Alejandro Diaz Maas

Acquisition, analysis, or interpretation of data: Alejandro Diaz Maas, Marc Edenharter

Drafting of the manuscript: Alejandro Diaz Maas

Critical review of the manuscript for important intellectual content: Alejandro Diaz Maas, Marc Edenharter

Disclosures

Human subjects: Informed consent for treatment and open access publication was obtained or waived by all participants in this study. **AI use statement:** The authors used Claude Sonnet 5.5 (Anthropic, PBC, San Francisco, CA, USA) as follows: language polishing, structure or formatting in all sections; and for the creation of Figures 2, 3. Every AI suggestion was reviewed line by line and accepted, modified, or rejected by the authors. All clinical facts, times, doses, and blood gas values were checked against the original anesthesia record, intensive care documentation, and laboratory results. All references were verified against the original sources (PubMed and DOI), and the timeline figure was checked against the contemporaneous record. No patient-identifiable data were entered into the AI tool. The authors confirm that they have reviewed and verified all AI-assisted content and take full responsibility for the work. **Conflicts of interest:** In compliance with the ICMJE uniform disclosure form, all authors declare the following: **Payment/services info:** All authors have declared that no financial support was received from any organization for the submitted work. **Financial relationships:** All authors have declared that they have no financial relationships at present or within the previous three years with any organizations that might have an interest in the submitted work. **Other relationships:** All authors have declared that there are no other relationships or activities that could appear to have influenced the submitted work.

Acknowledgements

The authors thank the anesthesia, neurosurgical, and intensive care teams at Kantonsspital Aarau for their prompt response and help in managing this patient.

References

1. Vaithialingam B, Bhadrinarayan V, Rudrappa S: Supraglottic airway devices in neuroanesthesia practice: a narrative review. J Anaesthesiol Clin Pharmacol. 2025, 41:410-7. 10.4103/joacp.joacp_317_24
2. Oshika H, Koyama Y, Taguri M, et al.: Supraglottic airway device versus a channeled or non-channeled blade-type videolaryngoscope for accidental extubation in the prone position: a randomized crossover manikin study. Medicine (Baltimore). 2018, 97:e11190. 10.1097/MD.0000000000011190
3. Rajaleelan W, Tuyishime E, Plitman E, Unger Z, Venkataraghavan L, Dinsmore M: Emergency airway management in the prone position: an observational mannequin-based simulation study. Adv Simul (Lond). 2024, 9:14. 10.1186/s41077-024-00285-4
4. Gupta B, Gupta S, Hijam B, Shende P, Rewari V: Comparison of three supraglottic airway devices for airway rescue in the prone position: a manikin-based study. J Emerg Trauma Shock. 2015, 8:188-92. 10.4103/0974-2700.166589
5. Ahmad I, El-Boghdadly K, Iliff H, et al.: Difficult Airway Society 2025 guidelines for management of unanticipated difficult tracheal intubation in adults. Br J Anaesth. 2026, 136:283-307. 10.1016/j.bja.2025.10.006
6. Apfelbaum JL, Hagberg CA, Connis RT, et al.: 2022 American Society of Anesthesiologists practice guidelines for management of the difficult airway. Anesthesiology. 2022, 136:31-81. 10.1097/ALN.0000000000004002
7. Shelton CL, Klein AA, Bailey CR, El-Boghdadly K: The Anaesthesia Case Report (ACRE) checklist: a tool to promote high-quality reporting of cases in peri-operative practice. Anaesthesia. 2021, 76:1077-81. 10.1111/anae.15391
8. Hendrix JM, Garmon EH: American Society of Anesthesiologists Physical Status Classification System . StatPearls [Internet]. StatPearls Publishing, Treasure Island (FL); 2025.
9. Cook TM, Woodall N, Frerk C: Major complications of airway management in the UK: results of the Fourth National Audit Project of the Royal College of Anaesthetists and the Difficult Airway Society. Part 1: anaesthesia. Br J Anaesth. 2011, 106:617-31. 10.1093/bja/aer058
10. Akça O: Optimizing the intraoperative management of carbon dioxide concentration . Curr Opin Anaesthesiol. 2006, 19:19-25. 10.1097/01.aco.0000192776.32398.5c
11. Cammu G, de Kam PJ, De Graeve K, et al.: Repeat dosing of rocuronium 1.2 mg kg-1 after reversal of neuromuscular block by sugammadex 4.0 mg kg-1 in anaesthetized healthy volunteers: a modelling-based pilot study. Br J Anaesth. 2010, 105:487-92. 10.1093/bja/aeq167
12. Kudu E, Korgan MB, Altun M, et al.: Comparison of three point-of-care ultrasound techniques to confirm endotracheal tube placement: a randomized clinical trial. Am J Emerg Med. 2026, 106:55-61. 10.1016/j.ajem.2026.04.039