Cureus
Part of SPRINGER NATURE

Open Access Case Report

Robot-Assisted Hysterectomy Following Uterine Artery Embolization for Large Uterine Fibroids With Documented Volume Reduction: A Case Report

Yuki Yaginuma [1], Hyo Kyozuka [1], Yumiko Kitago [1], Riho Yazawa [2], Toma Fukuda [1]

1. Obstetrics and Gynaecology, Ohta Nishinouchi Hospital, Koriyama, JPN 2. Obstetrics and Gynaecology, Fukushima Medical University, Fukushima, JPN

Corresponding author: Hyo Kyozuka, kyozuka@fmu.ac.jp

Review began 11/11/2026
Review ended 11/20/2026
Published 11/24/2026

© Copyright 2026
Yaginuma et al. This is an open access article distributed under the terms of the Creative Commons Attribution License CC-BY 4.0., which permits unrestricted use, distribution, and reproduction in any medium, provided the original author and source are credited.

DOI: 10.7759/cureus.120183

Abstract

Large uterine fibroids present technical challenges during minimally invasive hysterectomy because of restricted surgical exposure and increased bleeding risk. Uterine artery embolization (UAE) may facilitate subsequent surgery by reducing uterine size. We report a case of robot-assisted hysterectomy following UAE for large uterine fibroids.

A 50-year-old woman with multiple uterine fibroids presented with abdominal distension and constipation. UAE was performed using trisacryl gelatin microspheres (Embosphere) to reduce uterine size before considering surgical treatment. Magnetic resonance imaging (MRI) demonstrated a reduction in uterine dimensions from 200.3 × 108.3 × 116.7 mm to 167.0 × 107.4 × 93.9 mm, corresponding to an approximately 33.5% reduction in estimated uterine volume.

Following interval MRI and clinical reassessment, robot-assisted total hysterectomy was successfully completed approximately 10 months after UAE. The resected specimen weighed 782 g, and the operative and console times were 219 and 183 minutes, respectively, with no recorded intraoperative blood loss. The postoperative course was uneventful, and the patient was discharged on postoperative day 3. At follow-up visits two weeks and three months after surgery, no postoperative complications were identified, and pressure-related symptoms, including abdominal distension and constipation, had improved.

This case illustrates the feasibility of a staged minimally invasive approach involving UAE followed by robot-assisted hysterectomy for large uterine fibroids, with MRI-documented uterine size reduction. Further studies are needed to determine its clinical benefits and optimal timing.

Categories: Obstetrics/Gynecology, Radiology
Keywords: minimally invasive surgery, robot-assisted hysterectomy, uterine artery embolization, uterine leiomyoma, uterine volume reduction

Introduction

Uterine fibroids are common benign gynecologic tumors that may cause heavy menstrual bleeding, dysmenorrhea, and pressure-related symptoms [1]. Advances in minimally invasive treatment, including uterine artery embolization (UAE) and robot-assisted laparoscopic hysterectomy (RALH), have expanded therapeutic options for symptomatic uterine fibroids. Although RALH offers enhanced visualization and instrument maneuverability, large uterine fibroids remain technically challenging because of limited surgical exposure. We previously reported that increasing uterine length was associated with prolonged operative time during RALH [2].

UAE is a minimally invasive treatment that reduces fibroid perfusion and promotes uterine size reduction. In our previous study, UAE was more frequently selected for patients with larger uterine dimensions and more numerous fibroids than total laparoscopic hysterectomy [3]. Although UAE has been used as an adjunct to facilitate subsequent minimally invasive hysterectomy [4], its use as part of a staged approach involving interval assessment of uterine shrinkage before RALH remains insufficiently described. Here, we report a case of large uterine fibroids treated with UAE followed by RALH after MRI-documented uterine size reduction.

Case Presentation

A 50-year-old Japanese woman, gravida 2, para 2, with a history of 2 vaginal deliveries, was referred to our hospital for the management of large uterine fibroids. She presented with abdominal distension and constipation. The patient was premenopausal, with ongoing menstruation but no history of heavy menstrual bleeding, abnormal uterine bleeding, or dysmenorrhea. Her preprocedural hemoglobin level was 12.4 g/dL,

and she had no previous surgical history. Although she initially preferred to avoid surgery, she continued to experience pressure-related symptoms and expressed a preference for minimally invasive treatment.

Pelvic magnetic resonance imaging (MRI) revealed a markedly enlarged uterus containing 13 leiomyomas, all classified as FIGO (International Federation of Gynecology and Obstetrics) types 3-5 [5]. Given the uterine enlargement and the patient's treatment preference, UAE was selected to reduce uterine size, with the possibility of subsequent minimally invasive hysterectomy.

Bilateral UAE was performed using 500-700 μm trisacryl gelatin microspheres (Embosphere; Merit Medical Systems, Inc., South Jordan, UT, USA). Pre-embolization digital subtraction angiography demonstrated prominent uterine arterial supply to the fibroids. Embolization was continued until a marked reduction in distal uterine arterial flow and angiographic contrast stasis were observed. Post-embolization angiography confirmed markedly reduced uterine arterial flow bilaterally (Figure *1*). No immediate procedure-related complications occurred. Following UAE, abdominal distension partially improved but did not completely resolve.

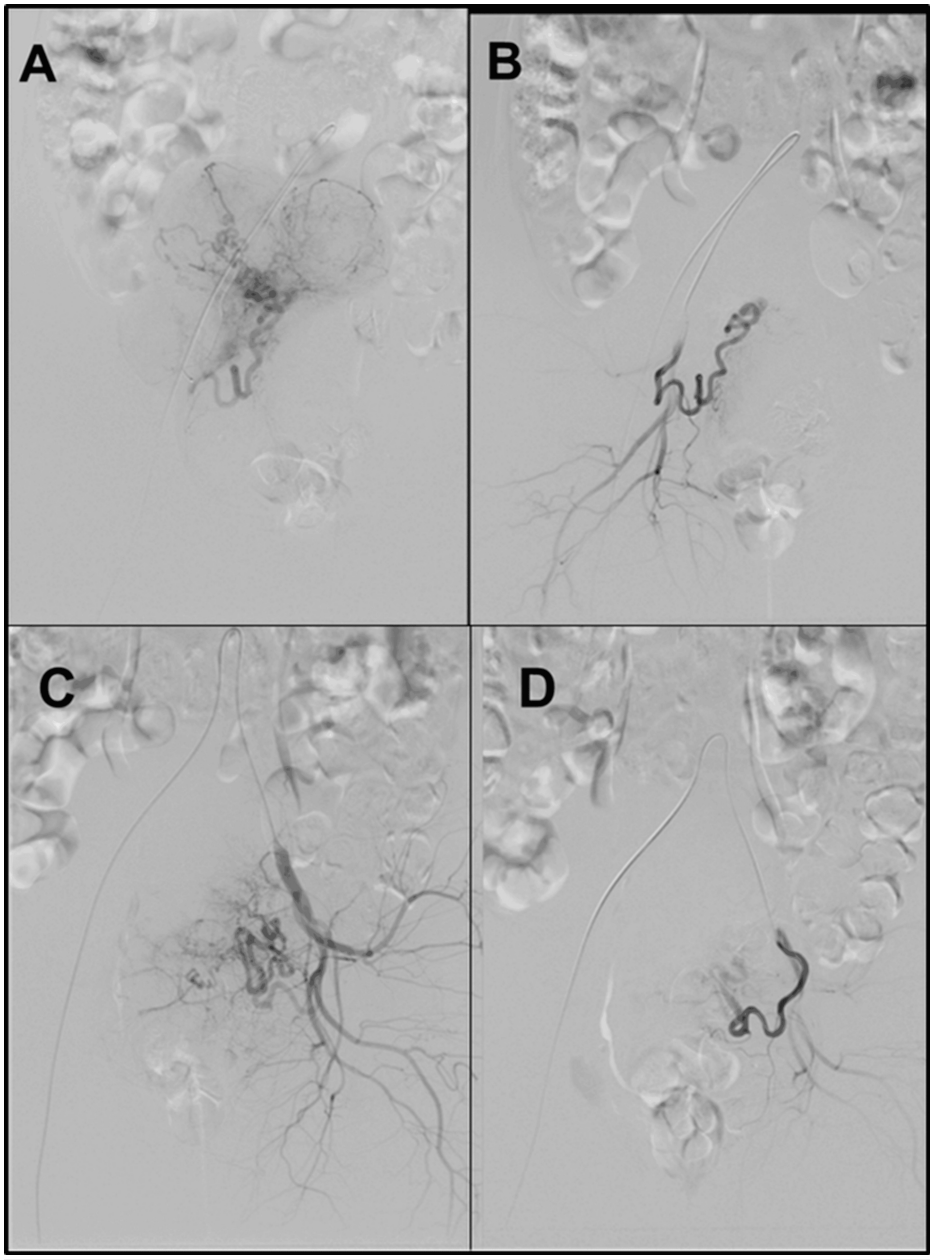

FIGURE 1: Digital subtraction angiography before and after uterine artery embolization

(A) Right internal iliac artery angiography before embolization, showing the uterine artery and prominent vascularity of the uterine fibroids. (B) Right internal iliac artery angiography after embolization, demonstrating a marked reduction in uterine arterial flow and fibroid vascularity. Under identical angiographic conditions, the inferior gluteal artery remained visible, whereas the uterine artery was no longer clearly visualized. (C) Left internal iliac artery angiography before embolization, showing prominent blood supply to the uterine fibroids. (D) Left internal iliac artery angiography after embolization, showing a marked reduction in uterine arterial flow and fibroid vascularity.

Uterine dimensions were assessed on T2-weighted MRI before and after UAE using the same anatomical definitions and measurement approach. Uterine length (LU) and uterine depth (DU) were measured on sagittal images according to previously described methods [3]. LU was defined as the longest distance from the external cervical os to the most distant point of the uterine fundus, and DU as the greatest perpendicular distance from the LU line. Following UAE, LU decreased from 200.3 to 167.0 mm (16.6%), while DU decreased from 108.3 to 107.4 mm (0.8%) (Figure *2*). The largest fibroid diameter on post-UAE MRI was 67.1 mm.

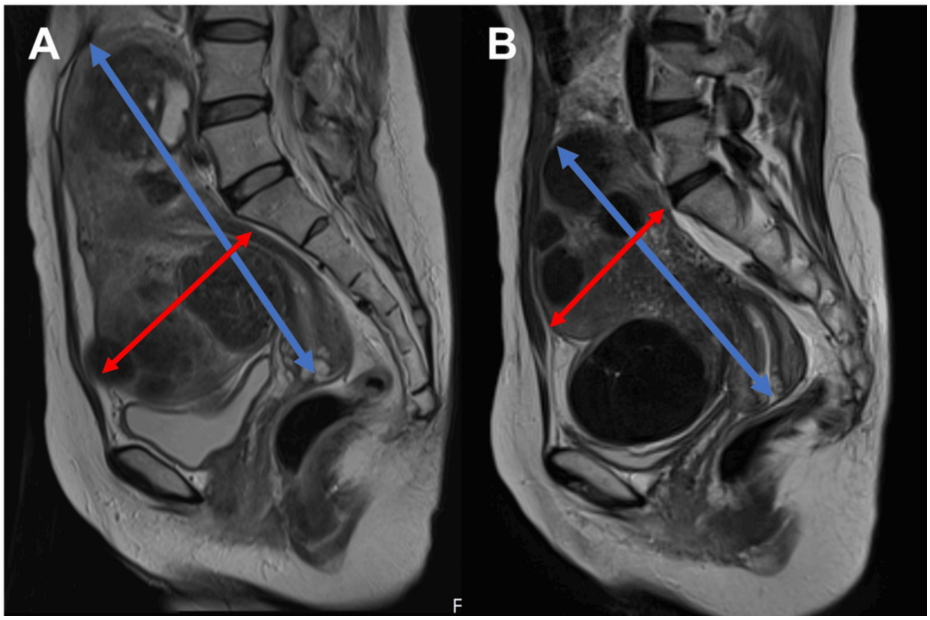

FIGURE 2: Comparison of sagittal T2-weighted magnetic resonance images before and after uterine artery embolization

(A) Before uterine artery embolization (UAE), the uterus was markedly enlarged with multiple fibroids. (B) After UAE, a reduction in uterine size was observed. The blue double-headed arrows indicate uterine length (LU), defined as the longest distance from the external cervical os to the most distant point of the uterine fundus. The red double-headed arrows indicate uterine depth (DU), defined as the greatest perpendicular distance from the LU line. Following UAE, LU decreased from 200.3 to 167.0 mm, and DU decreased from 108.3 to 107.4 mm.

Uterine width (WU) was defined as the maximum transverse diameter of the uterus, including fibroids, within the true pelvis on axial T2-weighted MRI. WU decreased from 116.7 to 93.9 mm (19.5%) following UAE (Figure 3). Uterine volume was approximated using the ellipsoid formula ($LU \times DU \times WU \times \frac{\pi}{6}$), with all dimensions measured in millimeters and the calculated volume converted to milliliters. Estimated uterine volume decreased from approximately 1,326 to 882 mL (33.5%). These values represent geometric estimates rather than direct volumetric measurements.

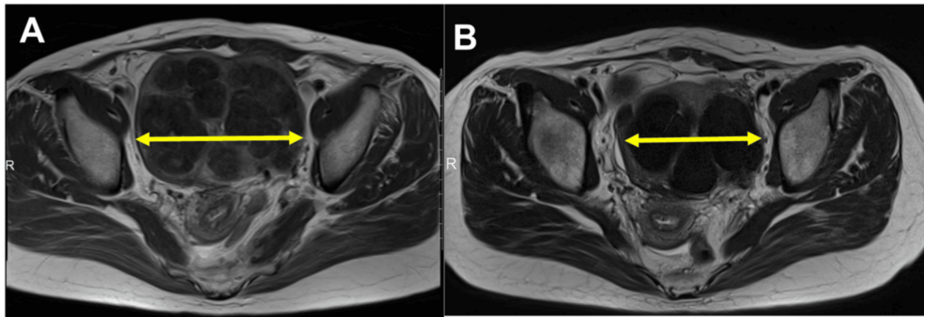

FIGURE 3: Comparison of axial T2-weighted magnetic resonance images before and after uterine artery embolization

(A) Before uterine artery embolization (UAE), the enlarged uterus with multiple fibroids occupied a substantial portion of the true pelvis. (B) After UAE, a reduction in uterine width was observed. The yellow double-headed arrows indicate uterine width (WU), defined as the maximum transverse diameter of the uterus, including fibroids, within the true pelvis. WU decreased from 116.7 mm before UAE to 93.9 mm after UAE.

At our institution, pelvic MRI and clinical reassessment are routinely performed approximately six months after UAE to evaluate uterine shrinkage and treatment response, and additional interventions are generally deferred until this assessment. In this case, robot-assisted total hysterectomy with bilateral salpingectomy was performed approximately 10 months after UAE, following the six-month evaluation and an additional four months for patient preference and hospital scheduling considerations.

During surgery, thin membranous adhesions were observed between a uterine fibroid and the anterior abdominal wall near the vesicouterine pouch despite the absence of previous surgery (Figure *4A*). Although the uterus remained enlarged, traction using Cadiere forceps (Intuitive Surgical, Inc., Sunnyvale, CA, USA) provided clear visualization of the left utero-ovarian ligament and fallopian tube (Figure *4B*). The surgeon perceived that the relatively firm residual fibroids facilitated traction and surgical exposure; however, tissue stiffness was not objectively measured.

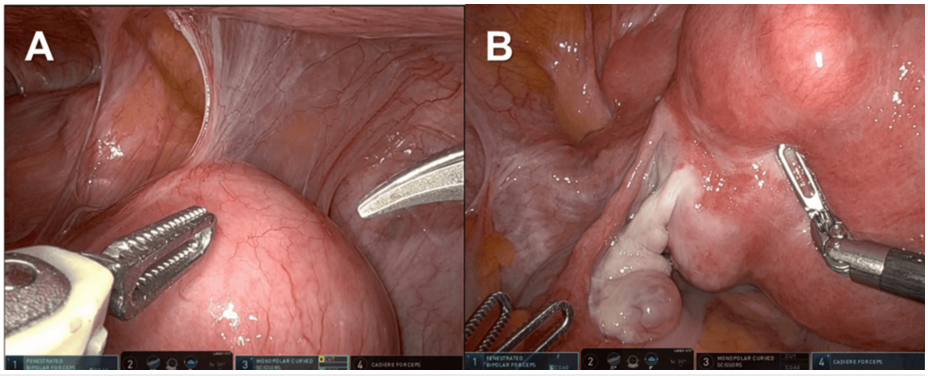

FIGURE 4: Intraoperative findings during robot-assisted hysterectomy following uterine artery embolization

(A) Thin membranous adhesions were observed between a uterine fibroid and the anterior abdominal wall near the vesicouterine pouch, despite the absence of previous abdominal surgery. (B) Traction of the uterus using robotic grasping forceps provided clear visualization of the left utero-ovarian ligament and fallopian tube. The surgeon perceived that the relatively firm residual fibroids facilitated traction and surgical field exposure. This assessment of tissue firmness and surgical maneuverability was subjective.

The hysterectomy was completed robotically without conversion to laparotomy. Both fallopian tubes and ovaries appeared grossly normal, and both ovaries were preserved. The resected specimen weighed 782 g. The total operative time was 219 minutes, including a console time of 183 minutes. No intraoperative blood loss was recorded, and no intraoperative complications occurred. Final histopathological examination confirmed uterine leiomyomas, and no immunohistochemical staining was performed. The postoperative course was uneventful, and the patient was discharged on postoperative day 3. Follow-up examinations at two weeks and three months revealed no postoperative complications, and pressure-related symptoms, including abdominal distension and constipation, had improved.

Discussion

The present case demonstrates the feasibility of a staged minimally invasive approach involving UAE followed by robot-assisted hysterectomy for large uterine fibroids. Following UAE, the estimated uterine volume decreased by 33.5%, and robot-assisted hysterectomy was subsequently completed without recorded intraoperative blood loss, despite a resected specimen weight of 782 g. Although the surgeon perceived the residual fibroids as relatively firm during surgical traction, the contribution of UAE to surgical maneuverability could not be objectively determined.

A previous study has reported the feasibility of robot-assisted hysterectomy for large uteri, although increasing uterine weight is associated with greater surgical difficulty [6]. Nozaki et al. reported favorable outcomes with robot-assisted hysterectomy compared with conventional laparoscopic hysterectomy, particularly for larger uteri [7]. In our previous study, UAE was more frequently selected for patients with larger uterine dimensions and more numerous fibroids than total laparoscopic hysterectomy [3]. Preoperative UAE has also been investigated as an adjunct to surgery. Kinariwala et al. reported a median interval of 21.6 hours between UAE and subsequent surgery in 53 patients [8], while Fox et al. described UAE to facilitate minimally invasive hysterectomy for very large fibroid uteri [4].

In contrast to these reports of UAE as an adjunct to surgery, UAE in the present case was initially performed to achieve uterine size reduction, with hysterectomy considered as a subsequent treatment option. In accordance with our institutional practice, MRI and clinical reassessment were performed approximately six months after UAE. Robot-assisted hysterectomy was subsequently performed four months later based on patient preference and scheduling considerations. This approach allowed documentation of uterine size reduction before surgery; however, the 10-month interval was not an evidence-based optimal waiting period, and its advantages over shorter intervals remain uncertain.

The principal observation in this case was the MRI-documented reduction in uterine dimensions before subsequent robot-assisted hysterectomy. Although reduced uterine size may theoretically improve surgical

exposure, its contribution to operative outcomes cannot be established from a single case. The surgeon also perceived the residual fibroids as relatively firm during traction. A previous histopathological study has described ischemic changes, including coagulative and hyaline necrosis, following UAE [9]. However, tissue stiffness was not measured in this patient, and no causal relationship between UAE-related tissue changes and surgical maneuverability can be inferred. Furthermore, thin membranous adhesions were observed near the vesicouterine pouch. Although histopathological changes following UAE may vary with time [10], and severe adhesions complicating hysterectomy after UAE have been reported [11], the origin of the adhesions in the present case remains uncertain.

Future studies should evaluate the reproducibility and predictive validity of MRI-based uterine measurements, including LU, DU, and WU. Prediction models incorporating these measurements, the interval between MRI assessment and surgery, and relevant clinical factors may help estimate hysterectomy specimen weight preoperatively and improve surgical planning. In addition, prospective studies should investigate whether UAE-related changes in uterine size, tissue stiffness, or adhesion severity are associated with surgical maneuverability and perioperative outcomes, including the potential influence of the interval between UAE and hysterectomy.

The strength of this report is the quantitative assessment of changes in uterine dimensions using MRI before and after UAE. However, the estimated uterine volume was derived from an ellipsoid approximation rather than direct volumetric measurement, and intraobserver and interobserver reproducibility were not formally evaluated. Furthermore, estimated uterine volume and resected specimen weight represent different physical quantities and are not directly interchangeable. Surgical maneuverability and tissue firmness were assessed subjectively, without objective quantification. As this is a single-case report, the contribution of UAE to subsequent surgical outcomes cannot be determined, and the findings cannot be generalized.

Conclusions

This case illustrates the feasibility of a staged minimally invasive approach involving UAE followed by robot-assisted hysterectomy for large uterine fibroids, with MRI-documented uterine size reduction. Although this approach may represent a treatment option for selected patients, its clinical benefits compared with conventional surgical management remain uncertain. Further studies are needed to evaluate the effectiveness and optimal timing of this combined treatment strategy.

Additional Information

Author Contributions

All authors have reviewed the final version to be published and agreed to be accountable for all aspects of the work.

Concept and design: Hyo Kyozuka, Yuki Yaginuma, Riho Yazawa

Acquisition, analysis, or interpretation of data: Hyo Kyozuka, Yuki Yaginuma, Yumiko Kitago, Toma Fukuda

Drafting of the manuscript: Hyo Kyozuka, Yuki Yaginuma

Critical review of the manuscript for important intellectual content: Yumiko Kitago, Riho Yazawa, Toma Fukuda

Supervision: Riho Yazawa, Toma Fukuda

Disclosures

Human subjects: Informed consent for treatment and open access publication was obtained or waived by all participants in this study. **AI use statement:** The authors have declared that no AI tools were used during the work or in the drafting of this article. The authors take full responsibility for the work. **Conflicts of interest:** In compliance with the ICMJE uniform disclosure form, all authors declare the following: **Payment/services info:** All authors have declared that no financial support was received from any organization for the submitted work. **Financial relationships:** All authors have declared that they have no financial relationships at present or within the previous three years with any organizations that might have an interest in the submitted work. **Other relationships:** All authors have declared that there are no other relationships or activities that could appear to have influenced the submitted work.

References

1. Stewart EA, Laughlin-Tommaso SK, Catherino WH, Lalitkumar S, Gupta D, Vollenhoven B: Uterine fibroids. Nat Rev Dis Primers. 2016, 2:16043. 10.1038/nrdp.2016.43

2. Yazawa R, Kyozuka H, Anjo K, Fukuda T, Suzuki D, Nomura Y: Comparing clinical outcomes of robot-assisted versus total laparoscopic hysterectomy for symptomatic uterine fibroids. Fukushima J Med Sci. 2026, 72:207-14. 10.5387/fms.25-00018
3. Anjo K, Kyozuka H, Yazawa R, et al.: Comparing clinical characteristic with uterine artery embolization versus laparoscopic hysterectomy in symptomatic uterine fibroids - a prospective, single-institution study. Eur J Obstet Gynecol Reprod Biol. 2026, 316:114806. 10.1016/j.ejogrb.2025.114806
4. Fox VS, Fajardo OM, Cook E, Anderson TL: Uterine artery embolization to facilitate minimally invasive hysterectomy for very large fibroid uteri. J Minim Invasive Gynecol. 2023, 30:944-5. 10.1016/j.jmig.2023.09.006
5. Munro MG, Critchley HO, Fraser IS: The FIGO classification of causes of abnormal uterine bleeding in the reproductive years. Fertil Steril. 2011, 95:2204-8, 2208.e1-3. 10.1016/j.fertnstert.2011.03.079
6. Akazawa M, Lee SL, Liu WM: Impact of uterine weight on robotic hysterectomy: analysis of 500 cases in a single institute. Int J Med Robot. 2019, 15:e2026. 10.1002/rcs.2026
7. Nozaki T, Matsuda K, Kagami K, Sakamoto I: Comparison of surgical outcomes between robot-assisted and conventional laparoscopic hysterectomy for large uterus. J Robot Surg. 2023, 17:2415-9. 10.1007/s11701-023-01673-0
8. Kinariwala DJ, Khaja MS, McCann S, et al.: Pre-operative uterine artery embolization before hysterectomy or myomectomy: a single-center review of 53 patients. Clin Imaging. 2023, 101:121-5. 10.1016/j.clinimag.2023.06.003
9. Weichert W, Denkert C, Gauruder-Burmester A, Kurzeja R, Hamm B, Dietel M, Kroencke TJ: Uterine arterial embolization with tris-acryl gelatin microspheres. A histopathologic evaluation. Am J Surg Pathol. 2005, 29:955-61. 10.1097/01.pas.0000159776.77912.ce
10. Maleki Z, Kim HS, Thonse VR, Judson K, Vinh TN, Vang R: Uterine artery embolization with trisacryl gelatin microspheres in women treated for leiomyomas: a clinicopathologic analysis of alterations in gynecologic surgical specimens. Int J Gynecol Pathol. 2010, 29:260-8. 10.1097/PGP.0b013e3181c3031f
11. Korkontzelos I, Gkioulekas N, Stamatopoulos C, Magos A: Complicated abdominal hysterectomy subsequent to uterine embolization for large fibroids. Clin Exp Obstet Gynecol. 2012, 39:122-3.