Cureus
Part of SPRINGER NATURE

Open Access Case Report

An Early Presentation of Taxane and Anti-human Epidermal Growth Factor Receptor 2 (Anti-HER2)-Induced Pneumonitis: A Case Report

Review began 11/07/2026
Review ended 11/19/2026
Published 11/24/2026

© **Copyright** 2026
Lima et al. This is an open access article distributed under the terms of the Creative Commons Attribution License CC-BY 4.0., which permits unrestricted use, distribution, and reproduction in any medium, provided the original author and source are credited.

DOI: 10.7759/cureus.120172

Duarte Lima [1], Constança Azeredo [2], Filipa Macieira [1], Marta Moreira [3], Marta Vilaça [3], Joana Cancela [1], Ana Mesquita [4]

1. Internal Medicine, Matosinhos Local Health Unit, Matosinhos, PRT 2. Infectious Diseases, Matosinhos Local Health Unit, Matosinhos, PRT 3. Oncology, Matosinhos Local Health Unit, Matosinhos, PRT 4. Intensive Care, Matosinhos Local Health Unit, Matosinhos, PRT

Corresponding author: Duarte Lima, duarte.lima@ulsm.min-saude.pt

Abstract

Pulmonary toxicity is a rare but potentially life-threatening complication of taxane-based chemotherapy combined with anti-human epidermal growth factor receptor 2 (HER2) therapy and may be difficult to distinguish from infection in immunocompromised patients. We report the case of a 53-year-old woman with stage III, HER2-positive, estrogen receptor-positive breast cancer who developed acute hypoxemic respiratory failure eight days after receiving paclitaxel, trastuzumab, and pertuzumab. Chest computed tomography revealed bilateral scattered ground-glass opacities. Initial empirical antimicrobial treatment targeting opportunistic infections, including *Pneumocystis jirovecii* and cytomegalovirus, produced no clinical improvement. Microbiological investigations were negative, while bronchoalveolar lavage cytology revealed marked lymphocytic and neutrophilic alveolitis without malignant cells. Drug-induced pneumonitis associated with the taxane-anti-HER2 combination was suspected, and prednisolone at 1 mg/kg/day was initiated, followed by progressive respiratory improvement and discontinuation of high-flow oxygen therapy. The patient was subsequently discharged under a home hospitalization program and discontinued oxygen therapy one week later. Given the severity of the suspected drug-induced pneumonitis, neoadjuvant treatment was discontinued and subsequent surgery revealed a pathological complete response. This case highlights the importance of considering treatment-related pneumonitis in patients presenting with acute respiratory deterioration shortly after taxane and anti-HER2 therapy. Diagnosis requires an integrated assessment of treatment chronology, imaging, microbiological findings, and clinical response. Although the temporal relationship suggests treatment-associated pulmonary toxicity, the individual contribution of paclitaxel, trastuzumab, and pertuzumab cannot be established. Early recognition and timely corticosteroid treatment are essential in severe cases, and hospital-at-home programs can contribute to early hospital discharge.

Categories: Emergency Medicine, Oncology, Pulmonology
Keywords: breast cancer, corticosteroid therapy, drug-induced pneumonitis, home hospitalization, interstitial lung disease, paclitaxel, trastuzumab

Introduction

Trastuzumab and pertuzumab are monoclonal antibodies that target the human epidermal growth factor receptor 2 (HER2) and are commonly combined with taxane-based chemotherapy in the neoadjuvant treatment of HER2-positive breast cancer [1,2]. Although these treatment regimens have significantly improved therapeutic outcomes for cancer patients, pulmonary toxicity, manifesting as interstitial lung disease (ILD) and pneumonitis, remains a rare but potentially life-threatening complication [3-5]. Trastuzumab-induced pulmonary toxicity has been reported across a spectrum of severity, ranging from interstitial pneumonitis to acute respiratory distress syndrome, whereas taxanes, including paclitaxel, are a recognized and independent cause of iatrogenic lung injury [6,7]. Furthermore, pulmonary toxicity reported during combination therapy with trastuzumab and a taxane may reflect the contribution of either agent or a potential synergic interaction between them [6]. Pharmacovigilance reports have also identified a potential association between pertuzumab and ILD [8].

The clinical presentation of drug-induced pneumonitis can substantially overlap with that observed in respiratory infectious complications in immunocompromised patients undergoing chemotherapy, making the differential diagnosis particularly challenging [4]. In this context, a systematic diagnostic approach is essential to investigate potential infectious causes and identify findings supportive of drug-induced pneumonitis. This evaluation guides therapeutic management, including empirical antibiotic therapy, when indicated, and early initiation of corticosteroid therapy when drug-induced pneumonitis is suspected, to prevent progression to lung fibrosis [6,7].

We report a case of rapidly progressive, severe hypoxemic respiratory failure developing within eight days of the concomitant administration of paclitaxel, trastuzumab, and pertuzumab in a woman with HER2-positive

breast cancer. This case illustrates the potential contribution of multiple antineoplastic agents to pulmonary toxicity, the importance of a systematic evaluation for infectious causes, and the favorable response to corticosteroids. Given the concomitant administration of these agents, the event was interpreted as potentially associated with the taxane-anti-HER2 combination, recognizing that isolating a single culprit is not possible in a individual case.

Case Presentation

A 53-year-old female patient with stage III, HER2-positive, estrogen receptor-positive breast cancer and a Ki67 index of 20%-30% underwent neoadjuvant chemotherapy, completing four cycles of dose dense doxorubicin and cyclophosphamide in two months, with good tolerance, followed by single-dose administration of intravenous paclitaxel (80 mg/m^2), subcutaneous trastuzumab (600 mg), and intravenous pertuzumab (840 mg) one month later. Twenty-four hours after treatment, she developed persistent fever, rhinorrhea, and a dry cough, for which she was evaluated in the Emergency Department (ED) on the third day of symptoms. She was discharged with amoxicillin/clavulanic acid and azithromycin for a presumed respiratory infection in an immunocompromised patient. Despite antibiotic treatment, her condition worsened, and she developed dyspnea and a productive cough on the eighth day of disease, prompting another visit to the ED.

On initial evaluation, the patient was febrile (39°C) and tachycardic (heart rate 146 beats per minute), with no other physical exam abnormalities. However, during the first hours of her ED stay, the patient developed progressive respiratory distress, with tachypnea (respiratory rate of 32 breaths/min) and oxygen desaturation to 81% on room air. Oxygen therapy via Venturi mask was initiated, requiring a FiO_2 of up to 40%. Arterial blood gas analysis revealed acute hypoxemic respiratory failure, with a PaO_2/FiO_2 ratio of 183 (pH 7.47, $PaCO_2$ 30 mmHg, PaO_2 73 mmHg), prompting admission to the ICU and initiation of high-flow oxygen therapy (HFOT).

Initial laboratory investigation revealed an isolated elevation of C-reactive protein level and negative serology for human immunodeficiency virus (Table *1*). The electrocardiogram showed sinus tachycardia. A chest radiography showed no abnormalities, so a thoraco-abdominal-pelvic computed tomography (CT) scan was performed, revealing bilateral scattered ground-glass opacities (Figure *1*) that were not present on the most recent CT scan, performed for malignancy staging. A transthoracic echocardiogram was carried out, revealing preserved biventricular systolic function, which, along with low pro-B-type natriuretic peptide (pro-BNP) levels, argued against cardiogenic pulmonary edema.

Test	Result	Reference range
Hemoglobin	12.0 g/dL	12-16 g/dL
Leukocytes	6610/µL	4000-11000/µL
Neutrophils	4200/µL	1300-8800/µL
Lymphocytes	1400/µL	1000-4800/µL
Platelets	386,000/µL	150,000-400,000/µL
C-reactive protein	109 mg/L	<5.0 mg/L
Procalcitonin	0.08 ng/mL	Systemic infection improbable if <0.5 ng/mL
Creatinine	0.7 mg/dL	0.5-1.1 mg/dL
Urea	30 mg/dL	21-43 mg/dL
Sodium	136 mEq/L	136-145 mEq/L
Potassium	3.8 mEq/L	3.4-5.1 mEq/L
Alanine aminotransferase	48 U/L	<55 U/L
Aspartate aminotransferase	28 U/L	5-34 U/L
Gamma-glutamyl transferase	35 U/L	<38 U/L
Alkaline phosphatase	82 U/L	40-150 U/L
Total bilirubin	0.3 mg/dL	0.2-1.2 mg/dL
Creatine kinase	38 mg/dL	29-168 U/L
Nt-proBNP	17.4 pg/mL	Improbable if <300 pg/mL

TABLE 1: Laboratory findings on admission.

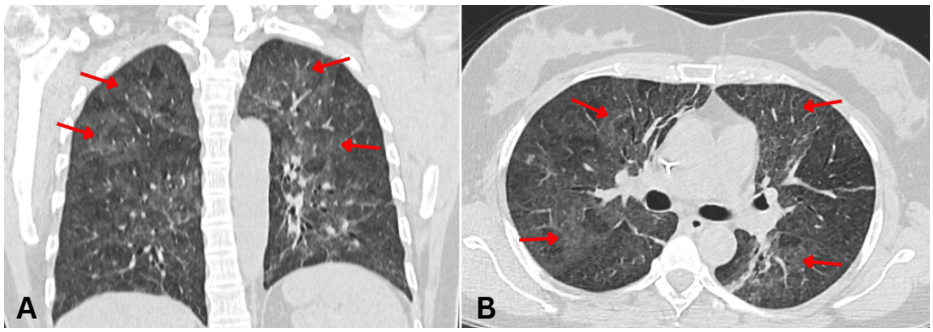

FIGURE 1: Chest computed tomography findings. Coronal (A) and axial (B) images showing bilateral, multifocal ground-glass opacities (red arrows), consistent with a diffuse pulmonary inflammatory process in the context of suspected treatment-related pneumonitis.

Given the clinical presentation and CT findings, pneumonia in an immunocompromised patient was suspected, for which microbiological specimens were collected, and empirical therapy covering *Pneumocystis jirovecii* and cytomegalovirus was initiated.

During ICU stay, she received co-trimoxazole and ganciclovir for six days without clinical or laboratory improvement, which were discontinued after microbiological investigations yielded no positive results (Table *2*). Bronchoalveolar lavage cytology revealed severe lymphocytic and neutrophilic alveolitis, with no malignant cells.

Specimen	Microbiological studies
Blood	Bacterial cultures
	PCR: CMV
Urine	Streptococcus pneumoniae and Legionella pneumophila antigen tests
Nasopharyngeal swab	PCR: SARS-CoV-2, influenza virus A and B, RSV
Bronchoalveolar lavage	Bacterial, mycological and mycobacterial cultures
	PCR: SARS-CoV-2, influenza virus A and B, RSV, CMV, metapneumovirus, parainfluenza viruses, adenovirus, Chlamydia pneumoniae, Mycoplasma pneumoniae, Legionella pneumoniae
	Pneumocystis jirovecii testing

TABLE 2: Microbiological investigations performed during the diagnostic workup, all of which yielded negative results.

CMV: Cytomegalovirus; PCR: polymerase chain reaction; RSV: respiratory syncytial virus; SARS-Cov-2: severe acute respiratory syndrome coronavirus 2.

Thus, a diagnosis of taxane/anti-HER2-induced toxic pneumonitis was considered the most probable cause, and prednisolone 1 mg/kg/day was initiated on the third day of hospitalization. After starting corticosteroid therapy, respiratory function progressively improved, allowing discontinuation of HFOT on the eighth day of hospitalization and transition to conventional oxygen therapy. Given the favorable clinical course, the patient was discharged under a home hospitalization program, where corticosteroid therapy was continued, allowing discontinuation of oxygen therapy after one week.

After discharge, the patient remained on systemic corticosteroids, tapered gradually over three months. A follow-up chest CT scan at the end of this period showed complete resolution of the ground-glass opacities, and pulmonary function tests showed normal parameters.

Regarding neoplastic disease, a multidisciplinary team discussion was held, and neoadjuvant therapy was discontinued due to the development of grade four toxicity (according to the Common Terminology Criteria for Adverse Events). Surgery was then performed, revealing a complete pathological response, followed by adjuvant radiation therapy and hormone therapy, which were well tolerated. Given the potential contribution of trastuzumab to the development of pulmonary toxicity, the patient was deemed unsuitable for adjuvant trastuzumab.

After two years of follow-up, the patient remains asymptomatic and free of oncological recurrence, with no clinical or radiological evidence of pneumonitis.

Discussion

Neoadjuvant chemotherapy combined with dual HER2 blockade using trastuzumab and pertuzumab is a standard treatment approach for patients with stage II or III HER2-positive breast cancer, as recommended in the European Society for Medical Oncology and National Comprehensive Cancer Network guidelines [1,9]. Despite their efficacy, these regimens combine multiple agents associated with pulmonary toxicity, creating conditions for the development of drug-induced lung injury that can be both severe and difficult to attribute [6,10].

Although anti-HER2-associated pneumonitis has been reported, interstitial pneumonitis occurring during or shortly after paclitaxel administration has also been described, leading to the hypothesis that taxanes may contribute to or potentiate pulmonary toxicity in patients receiving this therapy regimen [10]. In the present case, the close temporal gap between the administration of paclitaxel, trastuzumab, and pertuzumab and the onset of respiratory symptoms led us to consider pneumonitis associated with the combined taxane/anti-HER2 regimen as the most likely etiology. Nevertheless, the potential contribution of prior exposure to doxorubicin and cyclophosphamide should also be acknowledged, as both agents have been associated with pulmonary toxicity [11,12]. Their preceding administration may have increased pulmonary susceptibility to subsequent treatment-related injury, potentially acting as predisposing or sensitizing factors for the development of pneumonitis following taxane/anti-HER2 therapy.

The symptoms' onset approximately 24 hours after treatment is also notably early. As mentioned previously, paclitaxel-associated pneumonitis can manifest acutely, sometimes within hours to days of administration

[13]. At the same time, although trastuzumab-associated ILD has a reported median onset of about 75 days, cases developing as early as the first day after exposure have been described [14]. Safety studies also suggest that these pulmonary events tend to be reported more frequently early in treatment, a pattern described for both trastuzumab and pertuzumab [8]. These factors may account for the rapid onset observed in this case. However, prior exposure to doxorubicin and cyclophosphamide may also have contributed to pulmonary susceptibility and the unusually early presentation.

Because of their increased vulnerability, it is difficult to differentiate drug-induced pneumonitis from infection in patients undergoing chemotherapy. Therefore, the diagnostic approach should integrate the oncologic treatment timeline, imaging studies, microbiological tests, and treatment response, while considering alternative causes of pulmonary injury [5,15,16]. In this report, the absence of microbiological findings and the marked lymphocytic and neutrophilic alveolitis in the bronchoalveolar lavage were consistent with a non-infectious inflammatory process [17]. At the same time, the absence of malignant cells did not suggest a neoplastic etiology. Although none of these findings definitively rule out infection, the lack of clinical improvement with empirical antibiotic therapy, followed by progressive recovery after initiation of corticosteroid therapy, supported our diagnosis [18,19].

Systemic corticosteroid therapy and discontinuation of the suspected causative agents are the two main pillars of treatment for drug-induced ILD [5,16,18]. As recommended for severe cases, prednisolone at a dose of 1 mg/kg/day was initiated in this case, which led to a gradual improvement in respiratory failure [15]. Given the grade four pulmonary toxicity, discontinuing neoadjuvant treatment and proceeding to surgery was an appropriate decision from a risk-benefit perspective [18]. Although treatment rechallenge may be considered in selected patients, it is not recommended in the presence of life-threatening toxicities [16,18], which is why adjuvant trastuzumab was not administered.

Home hospitalization was possible after the patient's clinical condition stabilized and respiratory function improved. Although these programs can reduce hospital stay for selected cancer patients and have been shown in other contexts to yield financial benefits and positive clinical outcomes, including a lower rate of nosocomial complications, the scientific evidence remains limited [20].

Conclusions

Taxane/anti-HER2-induced pneumonitis, although rare, can present as fulminant hypoxemic respiratory failure with early onset and should be included in the differential diagnosis for patients receiving these treatment regimens, even when the initial presentation suggests an infectious etiology. This distinction is particularly challenging in immunocompromised patients; diagnosis requires integrating clinical, imaging, and microbiological data, along with the timeline of therapy. Furthermore, the potential role of prior exposure to agents associated with pulmonary toxicity should also be considered, as cumulative pulmonary toxic effects may be possible and may increase susceptibility to treatment-related lung injury and potentially influence the timing of pneumonitis onset.

This case highlights the importance of early recognition and timely initiation of corticosteroid therapy in severe cases, while also underscoring the difficulty in attributing pulmonary toxicity to a single drug when combination regimens with contributing or potentiating toxic effects are administered. Multidisciplinary evaluation is essential to guide treatment discontinuation and subsequent oncological management, and home hospitalization may reduce nosocomial exposure in these immunocompromised patients.

Additional Information

Author Contributions

All authors have reviewed the final version to be published and agreed to be accountable for all aspects of the work.

Concept and design: Duarte Lima, Constança Azeredo, Filipa Macieira, Marta Moreira

Acquisition, analysis, or interpretation of data: Duarte Lima, Constança Azeredo, Filipa Macieira, Marta Moreira, Marta Vilaça, Joana Cancela, Ana Mesquita

Drafting of the manuscript: Duarte Lima

Critical review of the manuscript for important intellectual content: Duarte Lima, Constança Azeredo, Filipa Macieira, Marta Moreira, Marta Vilaça, Joana Cancela, Ana Mesquita

Supervision: Marta Vilaça, Joana Cancela, Ana Mesquita

Disclosures

Human subjects: Informed consent for treatment and open access publication was obtained or waived by all

participants in this study. **AI use statement:** The authors have declared that no AI tools were used during the work or in the drafting of this article. The authors take full responsibility for the work. **Conflicts of interest:** In compliance with the ICMJE uniform disclosure form, all authors declare the following: **Payment/services info:** All authors have declared that no financial support was received from any organization for the submitted work. **Financial relationships:** All authors have declared that they have no financial relationships at present or within the previous three years with any organizations that might have an interest in the submitted work. **Other relationships:** All authors have declared that there are no other relationships or activities that could appear to have influenced the submitted work.

References

1. Loibl S, André F, Bachelot T, et al.: Early breast cancer: ESMO Clinical Practice Guideline for diagnosis, treatment and follow-up. Ann Oncol. 2024, 35:159-82. 10.1016/j.annonc.2023.11.016
2. Hudis CA: Trastuzumab - mechanism of action and use in clinical practice . N Engl J Med. 2007, 357:39-51. 10.1056/NEJMra043186
3. Hackshaw MD, Danysh HE, Singh J, et al.: Incidence of pneumonitis/interstitial lung disease induced by HER2-targeting therapy for HER2-positive metastatic breast cancer. Breast Cancer Res Treat. 2020, 183:23-39. 10.1007/s10549-020-05754-8
4. Rodríguez Sánchez MA, Verdiales Lugo AK, Aguilar Rubio JM, Olguin Guizado CA, Ortiz Jiménez JP, López Millán CO, Valenzuela Carvajal L: Trastuzumab-induced pneumonitis: a rare but potentially severe pulmonary complication. Cureus. 2026, 18:e105281. 10.7759/cureus.105281
5. Spagnolo P, Bonniaud P, Rossi G, Sverzellati N, Cottin V: Drug-induced interstitial lung disease . Eur Respir J. 2022, 60:2102776. 10.1183/13993003.02776-2021
6. Omarini C, Thanopoulou E, Johnston SR: Pneumonitis and pulmonary fibrosis associated with breast cancer treatments. Breast Cancer Res Treat. 2014, 146:245-58. 10.1007/s10549-014-3016-5
7. Long K, Suresh K: Pulmonary toxicity of systemic lung cancer therapy . Respirology. 2020, 25:72-9. 10.1111/resp.13915
8. Zhu Z, Li Y, Zhu C, et al.: Disproportionality analysis of interstitial lung disease associated with novel antineoplastic agents during breast cancer treatment: a pharmacovigilance study. EClinicalMedicine. 2025, 82:103160. 10.1016/j.eclinm.2025.103160
9. NCCN guidelines version 8.2026 Breast Cancer. (2026). Accessed: October 11, 2026: https://www.nccn.org/guidelines/guidelines-detail.
10. Romond EH, Perez EA, Bryant J, et al.: Trastuzumab plus adjuvant chemotherapy for operable HER2-positive breast cancer. N Engl J Med. 2005, 353:1673-84. 10.1056/NEJMoa052122
11. Fontes E Sousa M, Campainha S, Marques ID, et al.: Diagnosis and management of drug-induced interstitial lung disease in the context of anti-cancer therapy: a multidisciplinary viewpoint by Portuguese experts. Clin Drug Investig. 2024, 44:801-10. 10.1007/s40261-024-01400-z
12. Yerushalmi R, Kramer MR, Rizel S, et al.: Decline in pulmonary function in patients with breast cancer receiving dose-dense chemotherapy: a prospective study. Ann Oncol. 2009, 20:437-40. 10.1093/annonc/mdn652
13. Ardolino L, Lau B, Wilson I, Chen J, Borella L, Stone E, Lim E: Case report: paclitaxel-induced pneumonitis in early breast cancer: a single institution experience and review. Front Oncol. 2021, 11:701424. 10.3389/fonc.2021.701424
14. Kanbayashi Y, Uchida M, Kashiwagi M, Akiba H, Shimizu T: Evaluation of lung adverse events with trastuzumab using the Japanese pharmacovigilance database. Med Oncol. 2022, 39:219. 10.1007/s12032-022-01805-w
15. Conte P, Ascierto PA, Patelli G, et al.: Drug-induced interstitial lung disease during cancer therapies: expert opinion on diagnosis and treatment. ESMO Open. 2022, 7:100404. 10.1016/j.esmoop.2022.100404
16. Shannon VR, Anderson R, Blidner A, et al.: Multinational Association of Supportive Care in Cancer (MASCC) 2020 clinical practice recommendations for the management of immune-related adverse events: pulmonary toxicity. Support Care Cancer. 2020, 28:6145-57. 10.1007/s00520-020-05708-2
17. Novoa-Bolivar EM, Ros JA, Pérez-Fernández S, et al.: Diagnostic utility of bronchoalveolar lavage flow cytometric leukocyte profiling in interstitial lung disease and infection. Biomolecules. 2025, 15:597. 10.3390/biom15040597
18. Johkoh T, Lee KS, Nishino M, et al.: Chest CT diagnosis and clinical management of drug-related pneumonitis in patients receiving molecular targeting agents and immune checkpoint inhibitors: a position paper from the Fleischner Society. Chest. 2021, 159:1107-25. 10.1016/j.chest.2020.11.027
19. Sheshadri A, Goizueta AA, Shannon VR, et al.: Pneumonitis after immune checkpoint inhibitor therapies in patients with acute myeloid leukemia: a retrospective cohort study. Cancer. 2022, 128:2736-45. 10.1002/cncr.34229
20. Villegas Bruguera EB, Torres Corts AM, Mendiguren SO, Torra Bou JE, Blanco Blanco J: Hospital at Home vs conventional hospitalization: good clinical outcomes with lower cost and nosocomial complications. Int J Qual Health Care. 2026, 38:mzag099. 10.1093/intqhc/mzag099