Cureus
Part of SPRINGER NATURE

Open Access Case Report

Distal Radioulnar Joint-Preserving Reconstruction for Distal Radius Delayed Union With Severe Radial Shortening Using Ulnar Shortening Osteotomy: A Case Report

Takahisa Abe [1], Shinjiro Miura [2], Satsuki Onoda [1], Toshimi Aizawa [3]

1. Orthopaedics, Iwate Prefectural Central Hospital, Morioka, JPN 2. Orthopaedic Surgery, North Sendai Orthopaedic Clinic, Sendai, JPN 3. Orthopaedic Surgery, Tohoku University Graduate School of Medicine, Sendai, JPN

Corresponding author: Takahisa Abe, faceoff.09abe@gmail.com

Review began 11/11/2026
Review ended 11/22/2026
Published 11/27/2026

© Copyright 2026
Abe et al. This is an open access article distributed under the terms of the Creative Commons Attribution License CC-BY 4.0., which permits unrestricted use, distribution, and reproduction in any medium, provided the original author and source are credited.

DOI: 10.7759/cureus.120326

Abstract

Delayed union and nonunion after distal radius fractures are extremely rare, and the optimal reconstruction for cases with severe radial shortening and distal radioulnar joint (DRUJ) incongruity remains unclear. We report the case of a 74-year-old man who was initially treated conservatively because of multiple medical comorbidities. During conservative treatment, radial shortening progressed, resulting in delayed union, 13 mm of positive ulnar variance, marked DRUJ incongruity, and skin compromise over the prominent distal ulna. Complete restoration of radial length was expected to require substantial distraction and create a large bone defect. Therefore, radial reconstruction was combined with ulnar shortening osteotomy (USO). The radius was reduced without excessive lengthening, followed by autologous iliac bone grafting and fixation with a volar locking plate. The amount of ulnar shortening was determined based on intraoperative findings, including DRUJ alignment and stability and tension of the triangular fibrocartilage complex. At eight months after surgery, complete bone union of the radial fracture and ulnar osteotomy sites was confirmed. Wrist and forearm motion were preserved, and the patient had no pain during forearm rotation. Combined radial reconstruction and USO may be a joint-preserving reconstructive option for distal radius delayed union with severe radial shortening and DRUJ incongruity.

Categories: Trauma, Orthopedics
Keywords: bone grafting, distal radioulnar joint, distal radius delayed union, joint-preserving reconstruction, radial shortening, ulnar shortening osteotomy

Introduction

Distal radius fractures are common, whereas delayed union and nonunion are extremely rare. A large historical study reported an incidence of nonunion of approximately 0.2% after distal radius fractures [1]. Because of their rarity, high-quality evidence regarding their treatment remains limited [2].

In delayed union and nonunion of distal radius fractures, malalignment caused by radial shortening is an important clinical problem in addition to impaired bone healing. Severe radial shortening can lead to positive ulnar variance, distal radioulnar joint (DRUJ) incongruity, and increased loading on the ulnar side of the wrist, potentially affecting wrist function and forearm rotation [3].

The basic principles of treatment include debridement of the fracture site, restoration of alignment, bone grafting, and stable internal fixation [4]. However, restoring radial length can be difficult in cases with severe radial shortening. Excessive lengthening may create a large gap or bone defect at the fracture site, potentially compromising bone healing [3,5]. The optimal reconstructive approach for delayed union or nonunion with severe radial shortening has not been established [2].

Although the combination of radial reconstruction and ulnar shortening osteotomy (USO) has been reported previously [6], severe radial shortening can make it difficult to predict how much radial length can be restored without creating a substantial bone defect. We report a case of distal radius delayed union with severe radial shortening and marked DRUJ incongruity treated with combined radial reconstruction and USO. This case highlights the practical flexibility of adjusting the amount of ulnar shortening according to the radial reduction achieved intraoperatively, with qualitative assessment of DRUJ congruity, triangular fibrocartilage complex (TFCC) tension, and DRUJ stability using the ballottement test, rather than aiming for a predetermined ulnar variance.

Case Presentation

A 74-year-old right-handed man fell indoors and landed on his right hand. He visited a local hospital, where he was diagnosed with a right distal radius fracture, and was referred to our department. Initial radiographs showed an Arbeitsgemeinschaft für Osteosynthesefragen/Orthopaedic Trauma Association (AO/OTA) type

2R3A3 distal radius fracture with positive ulnar variance due to radial shortening (Figure *1*).



FIGURE 1: Initial radiographs

(A, B) Initial radiographs showing an AO/OTA type 2R3A3 distal radius fracture with radial shortening and positive ulnar variance.

AO/OTA: Arbeitsgemeinschaft für Osteosynthesefragen/Orthopaedic Trauma Association

Although surgical treatment was indicated, the patient had multiple comorbidities, including dementia, peripheral arterial disease, chronic kidney disease, and congestive heart failure. He also had poorly controlled diabetes mellitus, with an HbA1c level of 9.5%. His medical history also included a left distal radius fracture approximately eight years earlier, which had been treated conservatively with cast immobilization. After discussing the treatment options with the patient and his family, conservative treatment was selected because of his medical condition and perioperative risks. Closed reduction was performed under a brachial plexus block, followed by cast immobilization for six weeks. At six weeks after injury, radiographs demonstrated redisplacement of the fracture without callus formation. Although continued cast immobilization was considered because bone union had not been achieved, the patient reported little pain, and redness had developed over the prominent ulnar styloid. Therefore, the cast was removed and replaced with a wrist brace, and conservative treatment was continued. However, radiographs obtained three months after injury still showed no bone union. Radial shortening had progressed, resulting in 13 mm of positive ulnar variance and marked DRUJ incongruity (Figure *2*).



FIGURE 2: Preoperative radiographs

(A, B) Anteroposterior and lateral radiographs obtained three months after injury showing progressive radial shortening, marked positive ulnar variance (approximately 13 mm), and distal radioulnar joint (DRUJ) incongruity.

Preoperative computed tomography (CT) showed insufficient bony bridging at the fracture site, and delayed union was diagnosed. The dorsal portion of the sigmoid notch was preserved, with no apparent osteoarthritic changes. The DRUJ incongruity was considered to be primarily attributable to severe radial shortening rather than articular deformity or degeneration. Progressive radial shortening led to prominence of the ulnar styloid, with localized erythema and tension of the overlying skin. Although no ulceration or skin breakdown was observed, further skin compromise was a concern. Given this risk and the low likelihood of bone union with continued conservative treatment, surgical reconstruction was indicated. The patient's medical condition was reassessed and optimized before surgery.

Given the severe radial shortening and marked positive ulnar variance, restoration of radial length by radial lengthening alone was expected to require substantial distraction and create a large bone defect at the fracture site. Therefore, we planned to avoid excessive radial lengthening, obtain stable bone contact, and combine radial reconstruction with USO to correct the radioulnar length discrepancy and improve DRUJ congruity (Figure *3*).

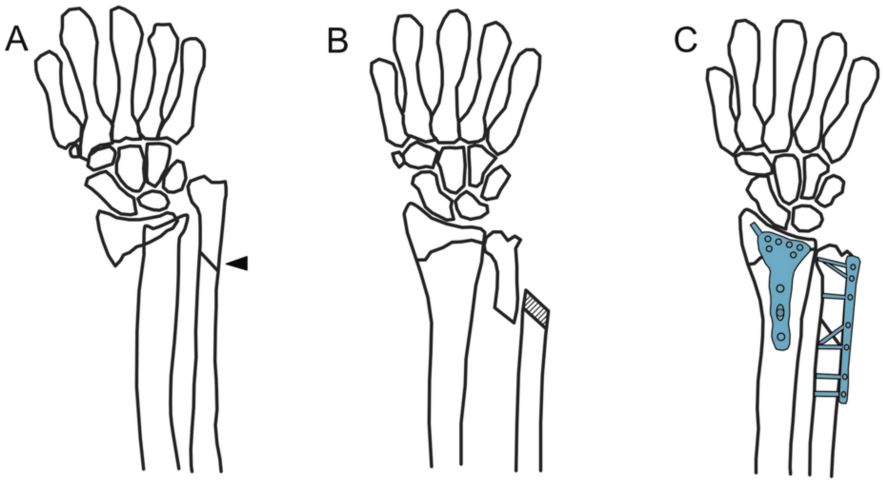

FIGURE 3: Schematic illustration of the surgical reconstruction

(A) Ulnar osteotomy before reduction of the distal radius. (B) Reduction of the distal radius and proximal translation of the ulnar head, resulting in overlap of the osteotomized ulnar segments. (C) Resection of the overlapping ulnar segment and plate fixation of the ulna, followed by bone grafting and plate fixation of the radius.

The arrowhead indicates the ulnar osteotomy site in (A), and the hatched area in (B) indicates the overlapping ulnar segment to be resected.

The schematic was originally hand-drawn by the authors and subsequently redrawn using Affinity software (Canva, Canva Pty Ltd, New South Wales, Australia).

Reconstructive surgery was performed four months after injury. A temporary external fixator was applied between the second metacarpal and the distal radial shaft. The distal radius was exposed through a trans-flexor carpi radialis (trans-FCR) approach, and scar tissue at the fracture site was removed. The exposure was extended using a dual-window approach to visualize the DRUJ and TFCC. A 7 cm incision was made over the ulna. After identifying the screw hole positions using an ulnar plate template, an oblique osteotomy was performed at the ulnar shaft. Mild traction was applied using the temporary external fixator, and radial inclination and volar tilt were corrected as much as possible. After radial reduction, the distal ulna was moved proximally. Direct visualization of the TFCC revealed no obvious tear, although the TFCC appeared lax. As the distal ulna was moved proximally, TFCC tension improved. DRUJ congruity was assessed under fluoroscopy, and DRUJ stability was evaluated using the ballottement test with the forearm in the neutral position before definitive ulnar fixation. The amount of ulnar shortening was determined based on these combined intraoperative findings rather than a predetermined target for ulnar variance. The distal ulnar fragment was temporarily fixed with a 1.8 mm Kirschner wire. At this point, ulnar variance was approximately 3 mm negative. The overlapping segment at the ulnar osteotomy site was then resected, and the ulna was fixed with a locking plate. Autologous iliac bone grafting was then performed at the radial fracture site, followed by fixation with a volar locking plate. After confirming DRUJ congruity, the temporary Kirschner wire and external fixator were removed. Postoperative radiographs showed approximately 3 mm of negative ulnar variance, a radial inclination of 18°, and a volar tilt of 12° (Figure *4*).



FIGURE 4: Postoperative radiographs

(A, B) Postoperative anteroposterior and lateral radiographs showing fixation of the distal radius and ulna, with approximately 3 mm of negative ulnar variance (compared with approximately 13 mm positive preoperatively), a radial inclination of 18°, and a volar tilt of 12°.

Preoperative and postoperative radiographic parameters, including measurements of the contralateral wrist, are summarized in Table *1*.

Radiographic parameter	Preoperative (right)	Postoperative (right)	Contralateral (left)
Radial height (mm)	0	9	12
Radial inclination (°)	0	18	23
Volar tilt (°)	-20	12	3
Ulnar variance (mm)	13	-3	3

TABLE 1: Comparison of preoperative, postoperative, and contralateral wrist radiographic parameters

Negative values for volar tilt indicate dorsal tilt. The contralateral wrist had a history of distal radius fracture treated conservatively approximately eight years earlier.

Postoperatively, the wrist was immobilized in a splint for three weeks, followed by range-of-motion exercises. At two months after surgery, radiographs showed no loss of correction, union at the ulnar osteotomy site, and callus formation at the radial fracture site. At eight months, complete bone union of both the radius and ulna was confirmed on radiographs and CT (Figure *5*).

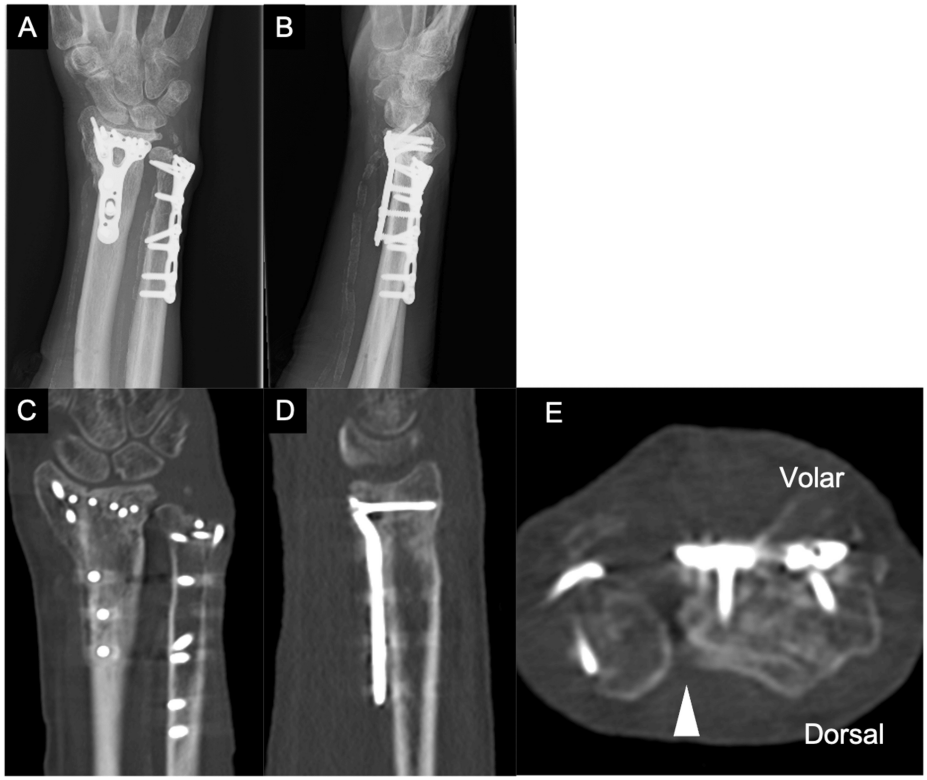

FIGURE 5: Radiographic and CT findings at eight months after surgery

(A, B) Anteroposterior and lateral radiographs showing maintained alignment and bone union. (C, D) Coronal and sagittal CT images confirming bone union at the radial fracture and ulnar osteotomy sites. (E) Axial CT image showing the relationship between the sigmoid notch and the ulnar head. The white arrowhead indicates the preserved dorsal portion of the sigmoid notch.

CT: computed tomography

Wrist and forearm range of motion on the contralateral and affected sides, respectively, was 80° and 60° of extension, 70° and 50° of flexion, 90° and 80° of pronation, and 90° and 70° of supination. The patient reported no pain during forearm rotation. Although the patient required assistance with eating and dressing because of dementia, no limitations in activities of daily living attributable to the wrist were noted. No postoperative complications, including infection, implant-related problems, graft-related complications, or symptomatic DRUJ instability, were observed during the eight-month follow-up.

Discussion

Delayed union and nonunion after distal radius fractures have been associated with local factors, such as fracture-site instability and inadequate immobilization, as well as patient-related factors, including diabetes mellitus, peripheral vascular disease, and smoking [3,7]. In our patient, poorly controlled diabetes mellitus (HbA1c 9.5%) and peripheral arterial disease may have contributed to delayed bone healing. The patient also reported little pain despite progressive deformity, suggesting possible sensory impairment associated with diabetes. Reduced pain sensation may have allowed continued loading at the fracture site, contributing to further deformity and delayed union.

Delayed union and nonunion of distal radius fractures are often associated with radial shortening, and lengthening reconstruction may be necessary to restore radial length [3,4]. However, excessive radial lengthening may create a gap or bone defect at the fracture site and compromise bone healing [3,5]. Prommersberger and Fernandez reported that severe radial shortening of more than 12 mm relative to the ulna may require substantial lengthening. They also suggested the Darrach procedure as an option when severe shortening cannot be adequately corrected [3]. In the present case, preoperative ulnar variance was 13 mm positive. Both the extent to which radial shortening could be anatomically corrected and the size of the resulting bone defect were difficult to predict preoperatively. Therefore, rather than pursuing a predetermined radial length, we prioritized correction of radial inclination and volar tilt while maintaining direct bone contact at the fracture site. Although greater radial lengthening with structural bone grafting might restore anatomical radial length, it could require reconstruction of a substantial bone defect and increase soft tissue tension. In contrast, combining radial reconstruction with USO allowed adjustment of the radioulnar length relationship while avoiding excessive radial distraction.

Combined radial reconstruction and USO for distal radius nonunion has been reported previously. Koo and Ho described a case of distal radius nonunion with severe radial shortening treated with internal fixation of the radius and a 1 cm USO. They reported bone union and good forearm rotation after restoration of DRUJ alignment [6]. The contralateral wrist also had a history of distal radius fracture and showed approximately 3 mm of positive ulnar variance; therefore, it was not considered a reliable anatomical reference for reconstruction. The present case illustrates the practical flexibility of adjusting the amount of ulnar shortening according to the radial reduction achieved intraoperatively. DRUJ congruity, TFCC tension, and stability were assessed qualitatively to guide this adjustment rather than to achieve a predetermined ulnar variance.

A biomechanical study showed that ulnar shortening increases TFCC tension and improves DRUJ stability when the foveal attachment of the TFCC is preserved [8]. The reliability and validity of the ballottement test for assessing DRUJ stability have also been evaluated [9]. Gao et al. used the ballottement test to assess DRUJ stability intraoperatively after USO in patients with ulnar impaction syndrome [10]. However, the intraoperative assessments in the present case were qualitative and did not constitute a standardized protocol for determining the amount of ulnar shortening.

Complete bone union was achieved at both the radial fracture site and the ulnar osteotomy site eight months after surgery, with painless forearm rotation. This favorable outcome suggests that joint-preserving reconstruction may be feasible even in cases with severe radial shortening and marked DRUJ incongruity. Several limitations should be acknowledged. Preoperative range of motion, postoperative grip strength, and standardized pain scores were not obtained, and dementia limited the assessment of patient-reported outcomes, including Disabilities of the Arm, Shoulder and Hand (DASH) and Patient-Rated Wrist Evaluation (PRWE) scores and patient satisfaction. The exact amount of ulnar bone resected and the respective contributions of radial reduction and ulnar shortening to the correction could not be quantified. Furthermore, the postoperative ulnar variance was approximately −3 mm, and its long-term implications remain uncertain. Excessive ulnar shortening may increase DRUJ contact pressure and potentially contribute to degenerative changes [11]. The relatively short follow-up period of eight months also limits the assessment of long-term DRUJ stability, functional outcomes, and implant-related complications. Therefore, further follow-up is warranted.

Conclusions

In this case of distal radius delayed union with severe radial shortening, combined radial reconstruction and USO achieved bone union at both the radial fracture and ulnar osteotomy sites, with preserved wrist and forearm motion. Intraoperative adjustment of ulnar shortening according to the achieved radial reduction, guided by qualitative assessment of DRUJ congruity, TFCC tension, and stability, may be a practical approach when the extent of radial length correction is difficult to predict preoperatively. Further follow-up is needed to evaluate the long-term implications of postoperative negative ulnar variance.

Additional Information

Author Contributions

All authors have reviewed the final version to be published and agreed to be accountable for all aspects of the work.

Concept and design: Takahisa Abe, Shinjiro Miura

Acquisition, analysis, or interpretation of data: Takahisa Abe, Satsuki Onoda, Toshimi Aizawa

Drafting of the manuscript: Takahisa Abe

Critical review of the manuscript for important intellectual content: Shinjiro Miura, Satsuki Onoda, Toshimi Aizawa

Disclosures

Human subjects: Informed consent for treatment and open access publication was obtained or waived by all participants in this study. **AI use statement:** The authors used ChatGPT (GPT-6, OpenAI, San Francisco, CA, USA; accessed November 2026) as follows: language polishing, translation, structure or formatting, literature comparison in Abstract, Introduction, Case Presentation, Discussion, and Conclusions. All AI-generated content was critically reviewed and edited by the authors. Clinical information and numerical data were verified against the original medical records, and references were checked against the original publications. The authors take full responsibility for the accuracy and integrity of the final manuscript. The authors confirm that they have reviewed and verified all AI-assisted content and take full responsibility for the work. **Conflicts of interest:** In compliance with the ICMJE uniform disclosure form, all authors declare the following: **Payment/services info:** All authors have declared that no financial support was received from any organization for the submitted work. **Financial relationships:** All authors have declared that they

have no financial relationships at present or within the previous three years with any organizations that might have an interest in the submitted work. **Other relationships:** All authors have declared that there are no other relationships or activities that could appear to have influenced the submitted work.

References

1. Bacorn RW, Kurtzke JF: Colles' fracture; a study of two thousand cases from the New York State Workmen's Compensation Board. J Bone Joint Surg Am. 1953, 35-A:643-58.
2. Bougioukli S, Chung KC: Distal radius nonunions: a rare entity? . Hand Clin. 2024, 40:49-61. 10.1016/j.hcl.2023.08.002
3. Prommersberger KJ, Fernandez DL: Nonunion of distal radius fractures. Clin Orthop Relat Res. 2004, 51-6. 10.1097/00003086-200402000-00009
4. Fernandez DL, Ring D, Jupiter JB: Surgical management of delayed union and nonunion of distal radius fractures. J Hand Surg Am. 2001, 26:201-9. 10.1053/jhsu.2001.22917
5. Hama S, Moriya K, Matsuyama Y, Maki Y, Nakamura H: Low-intensity pulsed ultrasound for delayed union of distal radius fracture after palmar locking plate fixation: a case report. Cureus. 2024, 16:e51468. 10.7759/cureus.51468
6. Koo SC, Ho ST: Non-union of fracture of distal radius: a case report and literature review . J Orthop Trauma Rehabil. 2011, 15:21-4. 10.1016/j.jotr.2010.11.004
7. Segalman KA, Clark GL: Un-united fractures of the distal radius: a report of 12 cases . J Hand Surg Am. 1998, 23:914-9. 10.1016/S0363-5023(98)80173-1
8. Nishiwaki M, Nakamura T, Nakao Y, Nagura T, Toyama Y: Ulnar shortening effect on distal radioulnar joint stability: a biomechanical study. J Hand Surg Am. 2005, 30:719-26. 10.1016/j.jhsa.2005.04.015
9. Nagashima M, Omokawa S, Hasegawa H, Nakanishi Y, Kawamura K, Tanaka Y: Reliability and validity analysis of the distal radioulnar joint ballottement test. J Hand Surg Am. 2024, 49:15-22. 10.1016/j.jhsa.2023.10.006
10. Gao X, Dong A, Li J, et al.: Clinical outcomes of isolated ulnar shortening osteotomy for ulnar impaction syndrome with concomitant distal radioulnar joint instability. J Plast Surg Hand Surg. 2026, 61:44-50. 10.2340/jphs.v61.45517
11. Nishiwaki M, Nakamura T, Nagura T, Toyama Y, Ikegami H: Ulnar-shortening effect on distal radioulnar joint pressure: a biomechanical study. J Hand Surg Am. 2008, 33:198-205. 10.1016/j.jhsa.2007.11.024