Cureus
Part of SPRINGER NATURE

Open Access Case Report

Anterior Cervical Discectomy and Fusion Hardware Migration Causing Oropharyngeal Injury: A Case Report

Review began 11/07/2026
Review ended 11/20/2026
Published 11/22/2026

© **Copyright** 2026
Suliman et al. This is an open access article distributed under the terms of the Creative Commons Attribution License CC-BY 4.0., which permits unrestricted use, distribution, and reproduction in any medium, provided the original author and source are credited.

DOI: 10.7759/cureus.120075

Mustafa Suliman [1], Umm E. Amara [2], Umme Nashrah [3], Nissar Shaikh [4]

1. Medical Education, University of Science and Technology, Omdurman, SDN 2. Obstetrics and Gynecology, Deccan College of Medical Sciences, Hyderabad, IND 3. Medicine, Deccan College of Medical Sciences, Hyderabad, IND 4. Surgical Intensive Care, Hamad Medical Corporation, Doha, QAT

Corresponding author: Mustafa Suliman, mustafahuzaifa67@gmail.com

Abstract

Hardware migration into the oropharynx is a rare but potentially life-threatening complication of anterior cervical discectomy and fusion (ACDF). We report the case of a 34-year-old man who presented to the emergency department with one week of increasing throat discomfort and blood-tinged salivation, 14 years after anterior cervical spine fixation for cervical trauma. Oral examination revealed a metallic object protruding into the oropharyngeal cavity, and computed tomography confirmed migration of the anterior cervical plate and screws at the first and second cervical vertebrae into the right paramedian aspect of the oropharynx. He underwent transcervical removal of the migrated plate with its loosened hexagonal screws, removal of granulation tissue, bone grafting, and primary closure of the pharyngeal wall defect. He was extubated on postoperative day 2, advanced to an oral diet by day 10, and discharged home on day 12. At the one- and three-month follow-ups, he remained asymptomatic. Early recognition and prompt surgical removal of the migrated hardware with primary pharyngeal repair afford an excellent outcome.

Categories: Neurosurgery, Anesthesiology
Keywords: anterior cervical discectomy and fusion, cervical spine fixation, dysphagia, hardware migration, oropharyngeal perforation, pharyngeal injury

Introduction

The dislodgement of anterior cervical spine fixation (anterior cervical discectomy and fusion (ACDF)/anterior cervical corpectomy and fusion (ACCF)) into the oropharynx is a rare but serious and potentially life-threatening complication [1]. This dislodgement occurs when the screws, plates, or cages of an anterior cervical spine fixation erode through the prevertebral tissues into the pharynx [2]. Dislodgement of cervical fixation frequently presents with dysphagia, odynophagia, and/or expectoration of hardware [3]. Early detection of cervical spine fixation migration is essential to avoid local hemorrhage, respiratory compromise, and infective complications [4]. In a retrospective series of 1,015 patients undergoing first-time ACDF for degenerative disease, Fountas et al. reported esophageal perforation in 0.3% of patients [5]. This figure is not an estimate of oropharyngeal perforation. A systematic review of 153 reported cases of esophageal perforation after anterior cervical spine surgery identified hardware failure and chronic erosion by prominent hardware as the leading mechanisms among the 75 patients with a documented cause. Among the 121 patients with timing data, the median time to diagnosis was 44.5 days, with a maximum of 18 years [6]. Such markedly delayed presentations underscore that a history of anterior cervical surgery must be actively sought in any patient with persistent dysphagia, odynophagia, or unexplained throat discomfort. We report a case of dislodgement of anterior cervical spine fixation occurring 14 years after the initial operation that was recognized promptly and followed by rapid recovery.

Case Presentation

A 34-year-old man presented to the emergency department with increasing throat discomfort and excessive blood-tinged salivation for one week. He gave a history of cervical trauma 14 years earlier, treated with anterior cervical spine fixation. On examination of the oral cavity, a metallic object was protruding from the oropharyngeal area (Figure *1*). Fiberoptic examination did not reveal any other pathological findings. The skin over the old incision on the front of the neck was normal.

How to cite this article
Suliman M, Amara U E, Nashrah U, et al. (November 22, 2026) Anterior Cervical Discectomy and Fusion Hardware Migration Causing Oropharyngeal Injury: A Case Report. Cureus 18(11): e120075. DOI 10.7759/cureus.120075



FIGURE 1: Oral cavity

Computed tomography (CT) showed anterior fixation of the first and second cervical vertebrae with a plate and screws, with migration into the right paramedian aspect of the oropharynx, loss of cervical lordosis, and muscle spasm (Figures *2*-*3*).

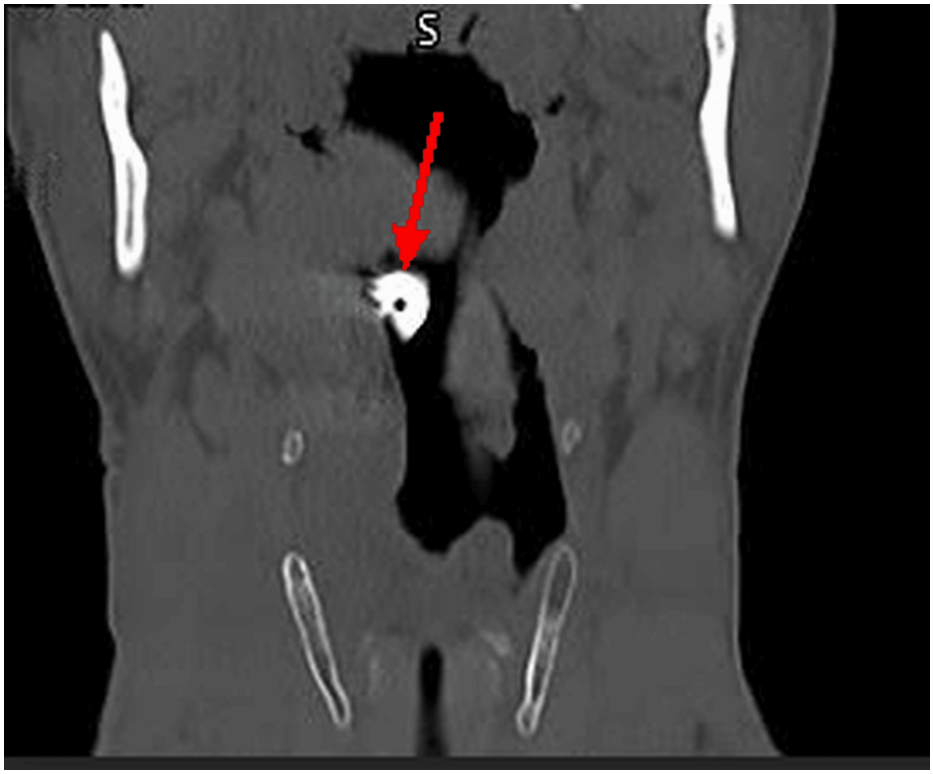

FIGURE 2: Coronal computed tomography

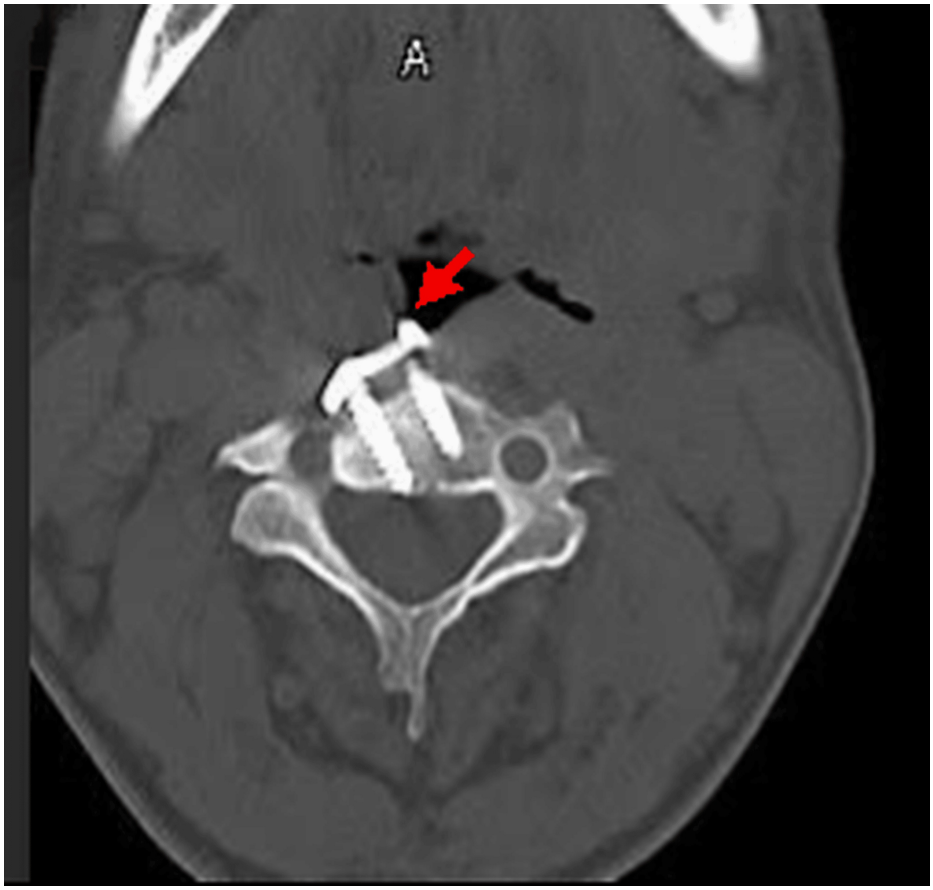

FIGURE 3: Axial computed tomography

The next day, he underwent transcervical removal of the migrated plate with its loosened hexagonal screws, removal of granulation tissue, and bone grafting, along with primary closure of the pharyngeal wall defect. General anesthesia was induced with propofol, fentanyl, and rocuronium, with easy intubation using video laryngoscopy. Anesthesia was maintained with propofol and remifentanil by total intravenous anesthesia (TIVA). The intraoperative period was uneventful.

Postoperatively, the patient was shifted to the surgical intensive care unit (SICU) intubated and ventilated, where he remained stable. He was covered with broad-spectrum antibiotics (Tazocin; piperacillin-tazobactam). After confirming the absence of airway edema and the absence of local hemorrhage or other complications, the patient was extubated on day 2 and started on enteral feeds. He was awake, free of respiratory issues, and stable and was transferred to the ward on day 3. There, he was ambulated and continued on enteral feeds. The nasogastric tube was removed on day 10, and an oral diet was started, which he tolerated. He was discharged home on day 12. He was followed up in the outpatient clinic at one and three months, and he is doing well without any issues.

Discussion

ACDF is routinely performed for cervical spine trauma and degenerative pathologies because of its high success rates of around 95%, and it offers the advantages of a small incision on the front of the neck, minimal muscle disruption, less postoperative pain, shorter recovery times, restoration of disc height and lordosis, and effective direct decompression of neural structures [7]. Al Eissa et al. reported postoperative dysphagia, dysphonia, hematoma, and wound infection after anterior cervical surgery [8]. Oropharyngeal perforation after anterior cervical fixation has been described in case reports [1,3].

The risk factors for oropharyngeal perforation are hardware migration or loosening, fixation at higher cervical levels (C2-C4), multilevel fixation, revision surgery, cervical osteophytes, female gender, comorbidities, and elderly patients [9]. Because the oropharynx lies at the level of the third cervical vertebra and lacks muscular protection, chronic irritation together with migration of a plate or screw causes focal ischemia and necrosis [10]. Esophageal perforations are more frequent with ACDF performed for traumatic cervical spinal injuries [11].

In patients with dislodgement of an ACDF plate and screw causing oropharyngeal or esophageal perforation, it is essential to remove the dislodged plate and screw and to repair the pharyngeal injury. These patients should be kept nil per os (NPO) to avoid local infection or more severe infection spreading to the mediastinum, aspiration pneumonia, or acute respiratory distress syndrome (ARDS), all of which carry increased mortality [4].

The clinical manifestations of pharyngoesophageal perforation are often subtle, and a low threshold for further investigation is required. In the largest series reported to date, comprising 44 patients referred with esophageal perforation after anterior cervical surgery, the most frequent symptoms were neck and throat pain, odynophagia, dysphagia, hoarseness, and aspiration, accompanied by fever, localized neck induration, and subcutaneous emphysema; 22 patients developed cervical osteomyelitis or a neck abscess, and nonoperative treatment was associated with a high mortality [12]. Similarly, a systematic review of 153 patients found that dysphagia was the most common presenting symptom, that hardware failure and chronic erosion by hardware were the dominant mechanisms of injury, and that primary repair reinforced with a sternocleidomastoid muscle flap was the most effective method of achieving definitive closure, with an overall mortality of 3.92% [6]. Notably, perforation may also occur without frank instrumentation failure, as repetitive friction between the pharyngoesophageal wall and a prominent plate can produce a pseudodiverticulum and delayed perforation even when the construct remains intact [13]. These observations support the management principles applied in our patient: removal of all offending hardware, debridement of granulation tissue, primary repair of the pharyngeal defect, broad-spectrum antibiotic coverage, and a period of enteral feeding until the repair has healed.

The main limitation of this report is its single-patient nature; however, the case illustrates that early detection, prompt removal of the migrated hardware, primary repair of the pharyngeal defect, and enteral feeding in the acute phase lead to an excellent outcome.

Conclusions

Rarely, anterior cervical fixation hardware can displace and erode into the oropharynx, producing a potentially life-threatening injury that may manifest years or even decades after the index operation. A high index of suspicion is therefore warranted in any patient presenting with persistent dysphagia, odynophagia, throat discomfort, or blood-tinged salivation following anterior cervical spine surgery, and appropriate imaging should be obtained without delay. Once the diagnosis is established, early detection, removal of the migrated metallic fixation, and primary repair of the pharyngeal injury are essential to prevent local infection, spread to the mediastinum, aspiration pneumonia, and respiratory compromise. In the acute phase after repair, patients should be maintained NPO and supported with enteral feeds until the pharyngeal closure has healed. As illustrated by our patient, who was discharged home within 12 days and remained asymptomatic at three months, this combined approach affords an excellent outcome.

Additional Information

Author Contributions

All authors have reviewed the final version to be published and agreed to be accountable for all aspects of the work.

Concept and design: Mustafa Suliman, Umm E. Amara, Umme Nashrah, Nissar Shaikh

Acquisition, analysis, or interpretation of data: Mustafa Suliman

Drafting of the manuscript: Mustafa Suliman, Umm E. Amara, Umme Nashrah, Nissar Shaikh

Critical review of the manuscript for important intellectual content: Mustafa Suliman

Supervision: Nissar Shaikh

Disclosures

Human subjects: Informed consent for treatment and open access publication was obtained or waived by all participants in this study. Medical Research Center at Hamad Medical Corporation issued approval MRC-04-26-91. **AI use statement:** The authors used Perplexity (Perplexity AI, Inc., San Francisco, California, United States) as follows: language polishing in the entire manuscript. The authors confirm that they have reviewed and verified all AI-assisted content and take full responsibility for the work. **Conflicts of interest:** In compliance with the ICMJE uniform disclosure form, all authors declare the following: **Payment/services info:** All authors have declared that no financial support was received from any organization for the submitted work. **Financial relationships:** All authors have declared that they have no financial relationships at present or within the previous three years with any organizations that might have an interest in the submitted work. **Other relationships:** All authors have declared that there are no other relationships or activities that could appear to have influenced the submitted work.

References

1. Erdem MB, Celtikci E, Aydil U, Yaman ME, Emmez H: Pharyngeal perforation after anterior cervical fusion surgery. Neurosurg Cases Rev. 2019, 2:025. 10.23937/2643-4474/1710025
2. Rama-López J, Tomás-Fernandez M, García-Garza C, Martínez-Madrigal M: Pharyngeal perforation after anterior cervical spine surgery treated by transoral endoscopic surgery. Head Neck. 2018, 40:E13-6. 10.1002/hed.25030
3. Quadri SA, Capua J, Ramakrishnan V, et al.: A rare case of pharyngeal perforation and expectoration of an entire anterior cervical fixation construct. J Neurosurg Spine. 2017, 26:560-6. 10.3171/2016.10.SPINE16560
4. Jung JW, Lee JB, Hur JW, Lee S, An S, Oh Y: Early detection and urgent surgical repair of pharyngeal injury after anterior cervical surgery: a case report. J Neurointensive Care. 2023, 6:158-62. 10.32587/jnic.2023.00703
5. Fountas KN, Kapsalaki EZ, Nikolakakos LG, et al.: Anterior cervical discectomy and fusion associated complications. Spine (Phila Pa 1976). 2007, 32:2310-7. 10.1097/BRS.0b013e318154c57e
6. Halani SH, Baum GR, Riley JP, Pradilla G, Refai D, Rodts GE Jr, Ahmad FU: Esophageal perforation after anterior cervical spine surgery: a systematic review of the literature. J Neurosurg Spine. 2016, 25:285-91. 10.3171/2016.1.SPINE15898
7. Lee S, Cho DC, Chon H, Roh SW, Choi I, Park JH: Comparison between anterior cervical decompression with fusion and posterior cervical fusion with wide facetectomy for treatment of severe bony foraminal stenosis. J Korean Neurosurg Soc. 2021, 64:552-61. 10.3340/jkns.2020.0263
8. Al Eissa S, Konbaz F, Aldeghaither S, et al.: Anterior cervical discectomy and fusion complications and thirty-day mortality and morbidity. Cureus. 2020, 12:e7643. 10.7759/cureus.7643
9. Anderson KK, Arnold PM: Oropharyngeal dysphagia after anterior cervical spine surgery: a review . Global Spine J. 2013, 3:273-86. 10.1055/s-0033-1354253
10. Liu FY, Yang DL, Huang WZ, et al.: Risk factors for dysphagia after anterior cervical spine surgery: a meta-analysis. Medicine (Baltimore). 2017, 96:e6267. 10.1097/MD.0000000000006267
11. Ji H, Liu D, You W, Zhou F, Liu Z: Success in esophageal perforation repair with open-wound management after revision cervical spine surgery: a case report. Spine (Phila Pa 1976). 2015, 40:E183-5. 10.1097/BRS.0000000000000712
12. Gaudinez RF, English GM, Gebhard JS, Brugman JL, Donaldson DH, Brown CW: Esophageal perforations after anterior cervical surgery. J Spinal Disord. 2000, 13:77-84. 10.1097/00002517-200002000-00015
13. Witwer BP, Resnick DK: Delayed esophageal injury without instrumentation failure: complication of anterior cervical instrumentation. J Spinal Disord Tech. 2003, 16:519-23. 10.1097/00024720-200312000-00006