Cureus
Part of SPRINGER NATURE

Open Access Case Report

Fatal Gastric Perforation by an Ingested Fish Bone With Hepatic Abscess and Generalized Peritonitis: A Case Report

Ruben E. Diaz Samada [1], Ernesto H. Castellano [2], Adrian O. Oliva Rodriguez [3], Carlos Alberto Crespo Bao [4], Miguel Gonzalez [5], Denit Ibanez Enriquez [6]

1. General Surgery, Entrust Clinical Research, Kendall, USA 2. General Surgery, Bath Regional Hospital, Berbice, GUY 3. General Surgery, HCA Healthcare, Brandon, USA 4. Surgery, Independent Research, Miami, USA 5. General Surgery, Camilo Cienfuegos Hospital, Sancti Spiritus, CUB 6. Surgery, St. George's University Medical School, St. George's, GRD

Corresponding author: Ruben E. Diaz Samada, rubenelieser960721@gmail.com

Review began 11/10/2026
Review ended 11/16/2026
Published 11/21/2026

© **Copyright** 2026
Diaz Samada et al. This is an open access article distributed under the terms of the Creative Commons Attribution License CC-BY 4.0., which permits unrestricted use, distribution, and reproduction in any medium, provided the original author and source are credited.

DOI: 10.7759/cureus.120061

Abstract

Gastric perforation by an ingested foreign body can cause serious intra-abdominal infection even when abdominal pain is relatively mild. We describe a 60-year-old woman with type 2 diabetes mellitus and hypertension who presented after one week of worsening but relatively mild abdominal pain and nausea. Computed tomography suggested foreign body penetration of the gastric antrum. At laparotomy, the presumed penetration site appeared sealed, yet exploration revealed generalized purulent peritonitis and a small hepatic abscess containing a 4-cm fish bone. The fish bone was removed, the abscess drained, and the peritoneal cavity irrigated; no gastric repair was performed. Postoperatively, her condition deteriorated with persistent hypotension, acidosis, and renal dysfunction despite antibiotics, vasopressors, and mechanical ventilation. The patient died on post-op day 2, with septic shock as the presumed cause of death. The contrast between her reported pain and the operative findings emphasizes the need to assess severity based on the extent of infection and the patient's physiologic condition.

Categories: General Surgery, Emergency Medicine, Gastroenterology
Keywords: fish bone, foreign body ingestion, gastric perforation, generalized peritonitis, hepatic abscess, septic shock

Introduction

Most ingested foreign bodies pass through the gastrointestinal tract spontaneously. Approximately 10%-20% require endoscopic removal, and fewer than 1% require surgery because of complications or failure to progress [1,2]. However, sharp objects such as fish bones can penetrate the gastrointestinal wall and cause perforation, abscesses, or peritonitis [2,3].

Diagnosis can be challenging because symptoms are often nonspecific and many patients do not recall swallowing the object. A contained perforation may also cause mild or persistent symptoms without the early signs of an acute abdomen. Fish bones can be difficult to identify on plain radiographs; CT can help locate the foreign body, identify the perforation site, and assess associated intra-abdominal complications [3,4].

Fish bones can progressively penetrate the gastric wall and migrate into adjacent structures, including the liver. Inflammation and adhesions between the stomach and liver may initially contain the perforation and promote localized abscess formation. However, the fish bone may carry bacteria into deeper tissues and sustain the infection while the gastrointestinal injury remains unrecognized [5-7].

Reported complications include abscesses, fistulas, and localized or generalized peritonitis. In severe cases, infection may progress to sepsis and septic shock. In a systematic review of 178 cases of liver abscess caused by ingested foreign bodies, fish bones accounted for 51% of the identified objects. Abdominal pain and fever were the most common clinical manifestations, although presentation may vary [7].

Imaging can be challenging because small fish bones may not be visible on plain radiographs or ultrasound. CT is generally more useful for locating the foreign body, assessing its trajectory, and identifying associated complications, although the fish bone may still be missed [6]. In our patient, the operative findings, a fish bone within a small abscess in the left hepatic lobe, an apparently sealed antral perforation, and generalized purulent peritonitis, suggest transmural migration. Despite surgical intervention, the patient developed septic shock and had a fatal outcome.

Case Presentation

A 60-year-old woman with a history of type 2 diabetes mellitus and hypertension presented with a one-week history of progressively worsening diffuse abdominal pain associated with nausea. Despite its progression,

the pain remained relatively mild in intensity. She reported no fever and recalled no preceding trauma or direct blow to the abdomen. The cause of her symptoms was not apparent from the initial history, and the provisional admission diagnosis was abdominal pain of undetermined etiology.

On initial evaluation, the patient was tachycardic (heart rate 105 beats/min), and abdominal palpation elicited mild diffuse tenderness with pain on release of pressure. As the cause of her abdominal pain remained unclear, she was kept under clinical observation, and laboratory investigations were requested. The results became available two hours later, approximately four hours after arrival, and revealed mild leukocytosis, with a white blood cell count of 12,000 cells/µL (reference range: 4,500-11,000 cells/µL) (Table *1*). At reassessment, she had developed a fever of 39.5°C, having been afebrile on arrival. Abdominal computed tomography (CT) and repeat laboratory testing were then requested.

Parameter	Four hours after arrival	Six hours after arrival	Postoperative	Reference range
Hemoglobin (g/dL)	10.8	10.8	9.6	12-16
White blood cell count (cells/µL)	12,000	16,000	22,000	4,500-11,000
Platelets (x 10^3 /µL)	-	210	150	150-450
Serum creatinine (mg/dL)	-	1.6	3.0	0.6-1.1
AST (U/L)	-	310	770	10-40
ALT (U/L)	-	290	700	7-40
LDH (U/L)	-	520	810	140-280
pH	-	7.25	7.16	7.35-7.45
Bicarbonate (mEq/L)	-	17	10	22-26
Partial pressure of CO_2 (mmHg)	-	33	27	35-45
Lactate (mmol/L)	-	2.3	8.0	<2

TABLE 1: Laboratory findings during hospitalization.

-: not available; AST: aspartate aminotransferase; ALT: alanine aminotransferase; LDH: lactate dehydrogenase; CO2: carbon dioxide; g/dL: grams per deciliter; cells/ µL: cells per microliter; x 10^3 µL: thousands per microliter; mg/dL: miligrams per deciliter; mEq/L: miliequivalents per liter; U/L: units per liter; mmHg: milimeters of mercury; mmol: millimoles per liter.

Both the CT findings and repeat laboratory results became available two hours later, approximately six hours after arrival. The white blood cell count had increased to 16,000 cells/µL and repeat tests also showed elevated transaminase and lactate dehydrogenase levels, mild metabolic acidosis, and elevated lactate level, and a rise in serum creatinine (Table *1*). CT demonstrated a calcific-density foreign body penetrating and projecting slightly beyond the posterior wall of the gastric antrum. Additional findings included mild pneumoperitoneum, free intraperitoneal fluid, and several small interloop fluid collections. These findings were consistent with gastric perforation caused by a foreign body (Figure *1*).

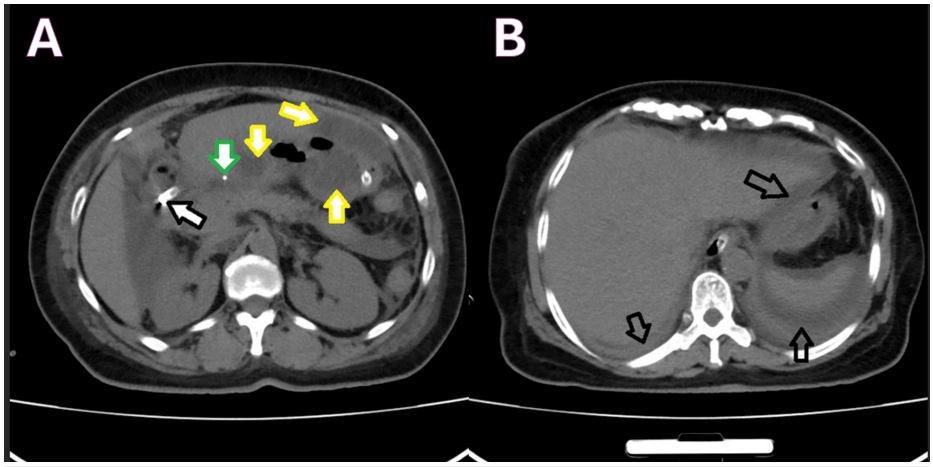

FIGURE 1: Axial noncontrast abdominal CT images.

(A) White arrow with black outlines indicate the Levin nasogastric (NG) tube; white arrow with green outlines indicate the foreign body; and white arrows with yellow outlines indicate interloop fluid. (B) Arrows with black outlines indicate free fluid in the peritoneal cavity.

Subsequently, the patient underwent an emergency laparotomy, which revealed generalized purulent peritonitis with pus throughout the peritoneal cavity. Extensive inflammatory changes and fibrinous exudate obscured visualization of the operative field. The left hepatic lobe was densely adherent to the stomach, particularly at the gastric antrum, and contained a localized abscess estimated intraoperatively to measure approximately 1 x 1 cm (Figure *2*). The presumed penetration site between the gastric antrum and the liver appeared sealed at exploration. No additional gastrointestinal perforation was identified.

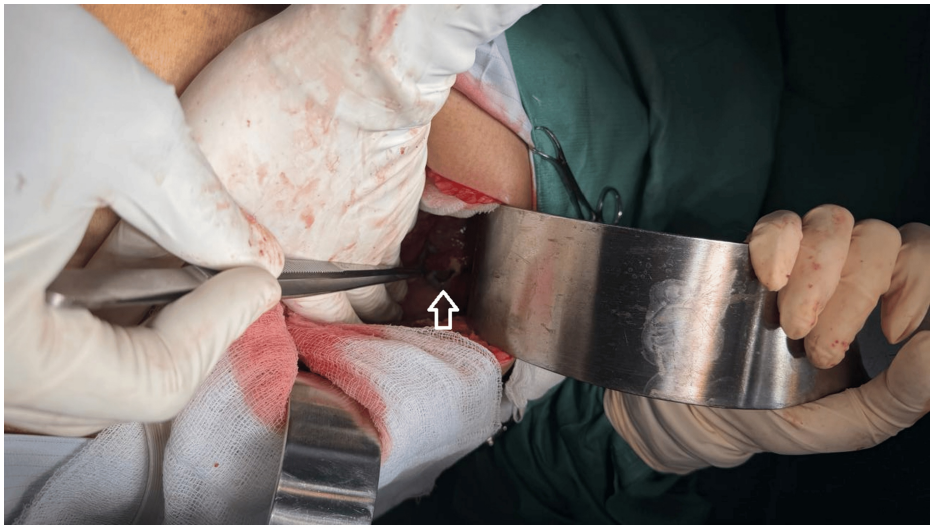

FIGURE 2: Intraoperative view of the left hepatic lobe densely adherent to the stomach.

The localized hepatic abscess, measuring approximately 1 × 1 cm, is indicated by the white-outlined arrow. The right side of the image corresponds to the patient's cephalad direction, and the left side corresponds to the caudal direction.

An incision was made into the hepatic abscess to allow drainage. During drainage and irrigation of the abscess cavity, the tip of an embedded fish bone became visible. The fish bone, measuring approximately 4 cm in length, carefully was extracted with minimal manipulation of the surrounding hepatic tissue to limit the risk of bleeding (Figure *3*). The remainder of the abdominal cavity was explored for additional fish bone fragments, other foreign bodies, and gastrointestinal perforations; none were identified. A sample of purulent peritoneal fluid was collected and submitted for microbiological culture and antimicrobial susceptibility testing to guide subsequent antibiotic therapy. Thorough peritoneal lavage was performed, and two intra-abdominal drains were placed: one in the pelvic cul-de-sac and the other in the sub hepatic

space. No gastric repair was performed because the presumed perforation site appeared sealed.



FIGURE 3: Extracted fish bone measuring approximately 4 cm.

The postoperative course was complicated by persistent hypotension, with blood pressure readings of approximately 80/60 mmHg or lower, accompanied by tachycardia, cool extremities and high fever ranging from 39 to 40 C°. The abdominal drains yielded predominantly purulent fluid with a small amount of blood. Despite antibiotic therapy with meropenem and vasopressor support, no sustained hemodynamic improvement was achieved. The patient remained sedated and required continued invasive mechanical ventilation throughout the postoperative period, as her respiratory status did not permit extubation. Ongoing sedation limited assessment of neurological recovery. Laboratory tests showed worsening leukocytosis, severe metabolic acidosis with inadequate respiratory compensation, marked hyperlactatemia, and acute kidney injury (Table *1*). Her condition continued to deteriorate, and she died on postoperative day 2. Septic shock was considered the presumed cause of death in the setting of generalized purulent peritonitis.

As the patient is deceased, verbal informed consent for publication was obtained from the patient's next of kin by the operating surgeon, Dr Ernesto Hernández (second author). Written consent was not obtained as re-establishing contact with the patient's family was not feasible. Every effort has been made to remove identifying information from the manuscript and accompanying images to protect the patient's confidentiality.

Discussion

Complications following foreign body ingestion are uncommon. Approximately 1% of ingested foreign bodies are reported to cause complications, while most pass through the gastrointestinal tract without incident [6]. When perforation occurs, it can involve different parts of the gastrointestinal tract, including the small bowel, colon, and stomach [8,9]. Liver abscess secondary to gastrointestinal perforation by a foreign body is even less common. Sharp objects such as fish bones can perforate the stomach or duodenum and migrate toward the liver [9]. Reported complications include generalized peritonitis, localized intra-abdominal abscesses, and visceral abscesses. In published cases of liver abscess caused by gastric foreign body perforation, the left hepatic lobe has often been involved [6].

Fish bones are small and may be difficult to identify on plain radiographs or ultrasound. These studies may instead show indirect findings, such as free intraperitoneal air or changes in the hepatic parenchyma. CT is generally considered the most useful imaging modality for identifying the foreign body and assessing associated complications [8,10]. In our patient, CT showed a calcific-density foreign body penetrating the posterior wall of the gastric antrum, along with mild pneumoperitoneum, free fluid, and small interloop collections.

Previous reports have described inflammatory adhesions between the stomach and the left hepatic lobe, gastric perforations of varying sizes, hepatic abscesses containing a foreign body, and localized or diffuse purulent collections [10-12]. To our knowledge, the unusual feature of our case was the combination of an apparently sealed antral perforation, a small hepatic abscess containing a fish bone, and generalized purulent peritonitis. At surgery, the approximately 4-cm fish bone was found within a 1 × 1-cm abscess in the left hepatic lobe. The presumed penetration site appeared sealed, but pus was present throughout the peritoneal cavity.

Patients with fish bone-related gastrointestinal perforation may present with nonspecific symptoms, including subacute abdominal pain and signs of infection. Many do not recall swallowing the foreign body [6,10]. When ingestion is remembered, symptoms may not develop until weeks or months later. A high index of suspicion and careful correlation of the clinical presentation with imaging findings are therefore important [10]. Our patient had a week of gradually worsening, relatively mild abdominal pain and did not report a recalled ingestion. Despite the mild symptoms, she had rebound tenderness, tachycardia, leukocytosis, and CT findings that suggested perforation.

Several treatment approaches have been reported, including antibiotics, percutaneous drainage, laparoscopic drainage and foreign body removal, and open surgery. Depending on the findings, procedures have also included gastric repair, omentoplasty, or liver resection [8,10]. Laparoscopic drainage with removal of the foreign body has been proposed as an effective approach in selected patients, while conservative management may be considered when surgery is unsuitable. Leaving the foreign body in place has been associated with recurrence [8,10]. However, the available case reports do not allow a reliable comparison of treatment outcomes. In our patient, laparotomy revealed generalized purulent peritonitis and a small hepatic abscess. Although the presumed gastric perforation appeared sealed, she developed persistent septic shock and died on postoperative day 2.

This case highlights the coexistence of a small hepatic abscess, an apparently sealed antral perforation, and generalized purulent peritonitis following fish bone ingestion. Although migration of the fish bone from the stomach into the liver cannot be definitively demonstrated, it is strongly suggested by the operative findings. A sealed perforation at exploration should not be taken as evidence that the peritoneal cavity is sterile. The patient's rapid deterioration and death underscore the seriousness of this condition and the complexity of its management. Her diabetes mellitus may have affected her ability to recover from the severe infection, although its specific contribution to the outcome cannot be determined from this case alone.

Conclusions

Foreign body ingestion is an uncommon cause of gastrointestinal perforation that may result in severe, life-threatening complications, including hepatic abscess formation, generalized peritonitis, and septic shock. This case highlights the diagnostic challenges associated with foreign body perforation, particularly because patients may not recall ingesting the object and may present with mild, nonspecific symptoms despite significant intra-abdominal pathology. CT plays a critical role in identifying the foreign body and assessing associated complications. The fatal outcome in this patient, despite operative intervention and intensive supportive care, underscores the seriousness of this condition and the need for particular caution in patients with comorbidities. Clinicians should maintain a high index of suspicion for occult gastrointestinal perforation in patients with unexplained abdominal pain and progressive signs of systemic inflammation.

Additional Information

Author Contributions

All authors have reviewed the final version to be published and agreed to be accountable for all aspects of the work.

Concept and design: Ruben E. Diaz Samada, Ernesto H. Castellano, Miguel Gonzalez, Adrian O. Oliva Rodriguez

Acquisition, analysis, or interpretation of data: Ruben E. Diaz Samada, Carlos Alberto Crespo Bao, Denit Ibanez Enriquez, Ernesto H. Castellano

Drafting of the manuscript: Ruben E. Diaz Samada, Carlos Alberto Crespo Bao, Denit Ibanez Enriquez, Ernesto H. Castellano, Miguel Gonzalez, Adrian O. Oliva Rodriguez

Critical review of the manuscript for important intellectual content: Ruben E. Diaz Samada, Carlos Alberto Crespo Bao, Denit Ibanez Enriquez, Ernesto H. Castellano, Miguel Gonzalez, Adrian O. Oliva Rodriguez

Supervision: Ruben E. Diaz Samada, Carlos Alberto Crespo Bao, Denit Ibanez Enriquez, Ernesto H. Castellano, Miguel Gonzalez, Adrian O. Oliva Rodriguez

Disclosures

Human subjects: Informed consent for treatment and open access publication was obtained or waived by all participants in this study. **AI use statement:** The authors used OpenAI Codex (GPT-6; OpenAI) as follows: translation in Introduction and Discussion. OpenAI Codex (GPT-6; OpenAI) was used only to assist with Spanish-to-English translation and language editing of selected sections of the manuscript. All authors reviewed the text, made corrections where needed, and take full responsibility for the final content. The authors confirm that they have reviewed and verified all AI-assisted content and take full responsibility for

the work. **Conflicts of interest:** In compliance with the ICMJE uniform disclosure form, all authors declare the following: **Payment/services info:** All authors have declared that no financial support was received from any organization for the submitted work. **Financial relationships:** All authors have declared that they have no financial relationships at present or within the previous three years with any organizations that might have an interest in the submitted work. **Other relationships:** All authors have declared that there are no other relationships or activities that could appear to have influenced the submitted work.

References

1. Demiroren K: Management of gastrointestinal foreign bodies with brief review of the guidelines . Pediatr Gastroenterol Hepatol Nutr. 2023, 26:1-14. 10.5223/pghn.2023.26.1.1
2. Oh YE, Moon HS: Upper gastrointestinal tract foreign bodies . Korean J Helicobacter Up Gastrointest Res. 2024, 24:24-30. 10.7704/kjhugr.2024.0002
3. Zuo W, Bai J, Wei J, Long C: Fishbone ingestion is a non-negligible cause of intestinal perforation . Front Med (Lausanne). 2025, 12:1607262. 10.3389/fmed.2025.1607262
4. Li D, Zeng W, Chen J: Fish bone migration: complications, diagnostic challenges, and treatment strategies . World J Emerg Surg. 2025, 20:35. 10.1186/s13017-025-00611-9
5. Hyndman D, Chaudhary R, Kettyle S, Husein H: CT diagnosis and laparoscopic treatment of hepatic abscess secondary to fish bone transmigration through the stomach wall. Radiol Case Rep. 2023, 18:3975-8. 10.1016/j.radcr.2023.08.076
6. Pornkul P, Bertucci R, Hawkins N, Smith S: Accidental fish bone ingestion leading to gastric perforation: a diagnostic challenge. Cureus. 2025, 17:e79025. 10.7759/cureus.79025
7. Suenghataiphorn T, Tribuddharat N, Danpanichkul P, Kulthamrongsri N: Hepatic abscess from ingested foreign body: clinical features and diagnostic challenges—a systematic review of current reported cases. J Clin Exp Hepatol. 2025, 15:102586. 10.1016/j.jceh.2025.102586
8. La PV, Dang QH, Doan VA, La PV, Duong TT, Nguyen TT: Fishbone-induced gastrointestinal perforation: a 21-case series from Vietnam. Korean J Gastroenterol. 2026, 86:462-7. 10.4166/kjg.2025.126
9. Pham TN, Nguyen QH, Lam HT, Nguyen TD, Vo TD: Foreign body-related liver abscess: a case study on fishbone. Cureus. 2024, 16:e60358. 10.7759/cureus.60358
10. Enes Silva J, Pinelas S, Pacheco M, Patacho M, Almeida J: Gastric perforation by fish bone with hepatic abscess formation presenting as prolonged fever. IDCases. 2021, 24:e01159. 10.1016/j.idcr.2021.e01159
11. Bekki T, Fujikuni N, Tanabe K, Amano H, Noriyuki T, Nakahara M: Liver abscess caused by fish bone perforation of stomach wall treated by laparoscopic surgery: a case report. Surg Case Rep. 2019, 5:79. 10.1186/s40792-019-0639-0
12. Grayson N, Shanti H, Patel AG: Liver abscess secondary to fishbone ingestion: case report and review of the literature. J Surg Case Rep. 2022, 2022:rjac026. 10.1093/jscr/rjac026