Cureus
Part of SPRINGER NATURE

Open Access Case Report

Severe Right Coronary Artery Stenosis With Troponin Below the Reported Threshold: Diagnostic Uncertainty in Suspected Non-ST-Elevation Acute Coronary Syndrome

Review began 11/06/2026
Review ended 11/14/2026
Published 11/20/2026

© **Copyright** 2026
Borumand et al. This is an open access article distributed under the terms of the Creative Commons Attribution License CC-BY 4.0., which permits unrestricted use, distribution, and reproduction in any medium, provided the original author and source are credited.

DOI: 10.7759/cureus.119994

Maryam Borumand [1], Suki Bernstein [2], Elham Sahibzada [3], Lahari Dammala [3], Natasha Sheelam [4]

1. Psychiatry, Altnagelvin Area Hospital, Bedford, GBR 2. Emergency Medicine, George Eliot Hospital, Nuneaton, GBR 3. Medicine, University of Buckingham, Buckingham, GBR 4. Paediatrics, Imperial College Healthcare NHS Trust, London, GBR

Corresponding author: Suki Bernstein, bernsteinsuki@gmail.com

Abstract

The distinction between non-ST-elevation myocardial infarction (NSTEMI) and unstable angina depends on objective evidence of acute myocardial injury, which can be difficult to establish in patients with chronic kidney disease and multimorbidity. A man in his 60s with type 2 diabetes mellitus, chronic kidney disease, hypertension, and previous coronary stenting presented with chest pain at rest radiating to the left shoulder. His electrocardiogram showed no acute ischaemic changes. Troponin T was reported as 0.058, below the reference limit of <0.1 ng/mL quoted in the original case account, whereas total creatine kinase was mildly elevated at 224 U/L (reference range: 55-170 U/L). The treating team recorded an NSTEMI diagnosis and proceeded to coronary angiography, which demonstrated 99% stenosis of the right coronary artery. A further coronary stent was inserted, and no immediate complications or recurrent pain were documented. Although the angiographic findings confirm important obstructive coronary disease, the available record does not establish the biochemical criteria for myocardial infarction: the assay-specific troponin threshold and serial measurements were not available. This case illustrates the importance of distinguishing a recorded clinical diagnosis from independently verifiable diagnostic criteria, and of integrating symptoms, biomarkers, electrocardiography, risk assessment, and coronary anatomy when managing suspected non-ST-elevation acute coronary syndrome in complex patients.

Categories: Cardiology, Emergency Medicine, Cardiac/Thoracic/Vascular Surgery
Keywords: acute coronary syndrome (acs) and stemi, coronary artery angiography, multimorbidity management, non-st elevated myocardial infarction, personalised precision medicine

Introduction

Acute coronary syndrome (ACS) encompasses a spectrum of presentations, including unstable angina, non-ST-elevation myocardial infarction (NSTEMI), and ST-elevation myocardial infarction. Whilst these conditions may present with similar symptoms, their classification is clinically important. Contemporary universal definitions require acute myocardial injury, demonstrated by an appropriate rise and/or fall in cardiac troponin with at least one value above the assay-specific 99th-percentile upper reference limit, together with evidence of myocardial ischaemia to establish myocardial infarction [1]. Conversely, patients with ischaemic symptoms but without biomarker evidence of acute myocardial injury may fall within the unstable-angina spectrum [1,2].

High-sensitivity cardiac troponin assays have improved the early detection of myocardial injury and support accelerated diagnostic pathways. Nevertheless, isolated results are vulnerable to misinterpretation when the assay, unit, reference limit, or sample timing is unclear. Chronic kidney disease (CKD) presents an additional challenge because baseline troponin concentrations can be elevated even without an acute coronary event; serial change, rather than a single measurement, is therefore particularly informative [2,3]. Total creatine kinase (CK), although historically used in the investigation of myocardial injury, lacks the cardiac specificity required to diagnose infarction independently [1].

We report a patient treated for presumed NSTEMI despite a troponin T result below the reference threshold quoted in the available case account and a non-ischaemic initial electrocardiogram (ECG). Subsequent angiography showed critical right coronary artery stenosis requiring intervention. Rather than assuming that the lesion retrospectively proves myocardial infarction, we examine what can and cannot be concluded from the recorded findings and how a patient-centred invasive strategy can remain appropriate in suspected non-ST-elevation ACS.

Case Presentation

Clinical history and presentation

How to cite this article
Borumand M, Bernstein S, Sahibzada E, et al. (November 20, 2026) Severe Right Coronary Artery Stenosis With Troponin Below the Reported Threshold: Diagnostic Uncertainty in Suspected Non-ST-Elevation Acute Coronary Syndrome. Cureus 18(11): e119994. DOI 10.7759/cureus.119994

A man in his 60s attended the emergency department with chest pain that had started at rest the preceding evening and radiated to his left shoulder. The pain was not described as crushing, and there was no associated nausea, vomiting, or diaphoresis. During the preceding months, he had experienced intermittent non-exertional, non-radiating chest discomfort accompanied by dizziness, without palpitations or shortness of breath.

His medical history included type 2 diabetes mellitus, CKD, hypertension, angina, and coronary stenting of the left coronary circulation approximately six years earlier. Regular medications were felodipine 10 mg once daily, aspirin 75 mg once daily, simvastatin 40 mg once daily, nicorandil 10 mg twice daily, furosemide 40 mg once daily, prazosin 1 mg twice daily, glyceryl trinitrate spray 400 µg as required, and gliclazide 40 mg daily. He lived with his wife and was independent in daily activities. He had never smoked and did not consume alcohol.

On examination, he was alert, oriented, and speaking in full sentences. Respiratory rate was 20 breaths/min, pulse was 75 beats/min in sinus rhythm, blood pressure was 166/94 mmHg, and temperature was 35.6°C. Heart sounds were not reported to be abnormal. Right basal crackles were present; the remainder of the documented examination was unremarkable.

Investigations and diagnostic interpretation

The chest radiograph was reported as normal, and the initial ECG showed no acute ischaemic changes. The only numerical cardiac biomarker results available from the original case account are troponin T of 0.058 and total CK of 224 U/L. They are reproduced in Table *1*, together with the reference values supplied in the original document. No additional enzyme values or serial troponin measurements have been supplied.

Laboratory test	Patient result	Source-stated reference interval	Units
Cardiac troponin T	0.058	<0.1	ng/mL*
Total creatine kinase (CK)	224	55-170 (adult male)	U/L

TABLE 1: Reported laboratory findings and source-stated reference intervals

*The unit for troponin T is inferred from the reference limit in the supplied case text, not independently verified against a laboratory report. The actual assay, 99th-percentile decision limit, and serial changes are unavailable. The table shows the original reference intervals, not independently validated local assay thresholds.

ng/mL: nanograms per millilitre; U/L: units per litre

On a direct comparison with the stated reference interval, troponin T 0.058 ng/mL is below the quoted cutoff of 0.1 ng/mL. This conflicts with the original narrative, which described the troponin as elevated or positive. The discrepancy cannot be resolved from the available information because the particular troponin assay and its 99th-percentile limit are unknown. If the unit was indeed nanograms per millilitre, 0.058 ng/mL corresponds to 58 ng/L; this concentration could exceed the threshold used by some high-sensitivity assays, but such a threshold must not be assumed retrospectively. CK of 224 U/L is above the source-stated upper limit of 170 U/L, but a modest rise in total CK is not specific for myocardial necrosis [1-3].

The treating clinicians recorded a diagnosis of NSTEMI in the context of symptoms and known coronary artery disease. However, without documented serial troponin measurements or a verified local assay threshold, the published evidence cannot independently confirm acute myocardial injury. The differential classification therefore includes suspected non-ST-elevation ACS, including unstable angina. Serum creatinine, estimated glomerular filtration rate, oxygen saturation, and a numerical Global Registry of Acute Coronary Events (GRACE) score were not provided; consequently, a formal score cannot be calculated from this case account. The original derivation of GRACE is cited here for completeness [4].

Management and immediate outcome

The recorded acute treatment consisted of aspirin 300 mg, clopidogrel 75 mg, glyceryl trinitrate spray, morphine, an antiemetic, and high-flow oxygen. The case account did not specify oxygen saturation, parenteral anticoagulation, the timing of each medication, or whether the clopidogrel dose represented a maintenance regimen rather than an initial loading dose. These details cannot be reconstructed retrospectively. The patient was discussed with interventional cardiology and cardiac surgical teams, with his involvement in shared decision-making. Although the source describes him as being at ‘intermediate risk’, no numerical GRACE score or full score inputs were recorded.

He was admitted to a cardiac ward and underwent coronary angiography, which identified a 99% stenosis of

the right coronary artery. A further stent was inserted. No procedural complications were described, and he experienced no recurrent chest pain during the documented immediate recovery period. Bisoprolol 2.5 mg daily was added at discharge, and an outpatient echocardiogram was planned. The stent type, full discharge medication list, subsequent echocardiography results, and longer-term clinical outcome were not available. Figure *1* summarises the clinical sequence using only documented findings.

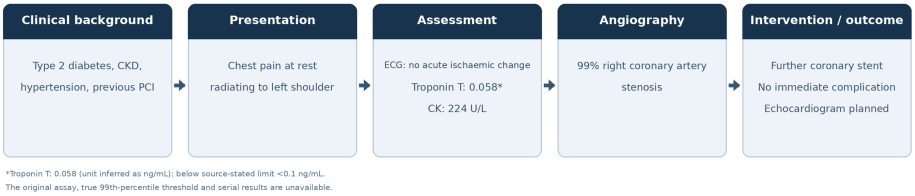

FIGURE 1: Clinical sequence from the supplied case account. The troponin T value was 0.058 (unit inferred as ng/mL), and total creatine kinase was 224 U/L; the original assay and serial troponin values were unavailable

Created programmatically with Python 3 and Pillow (Python Software Foundation, Fredericksburg, VA, USA); ChatGPT (OpenAI, San Francisco, CA, USA) assisted in preparing diagram labels and layout code.

CKD: chronic kidney disease; PCI: percutaneous coronary intervention; ECG: electrocardiogram; CK: creatine kinase; U/L: units per litre

Discussion

Diagnostic significance of troponin below the reported threshold

This case raises a distinction that is sometimes lost when a patient has both a typical risk profile and a severe coronary lesion: obstructive coronary anatomy does not, on its own, establish that an acute myocardial infarction has occurred. The patient had chest pain at rest, previous coronary intervention, diabetes, and CKD, making a coronary cause clinically plausible. However, the initial ECG showed no acute ischaemic changes, and the only reported troponin T value fell below the reference cutoff quoted in the source document. Angiography confirmed substantial coronary artery disease, but the description of 99% stenosis did not document an acute thrombus, plaque rupture, or other finding establishing an acute culprit mechanism. The terms ‘clinically diagnosed NSTEMI’ and ‘confirmed NSTEMI’ should therefore not be treated as interchangeable in this retrospective report [1,2].

The numerical troponin T value deserves particular attention. A concentration of 0.058 ng/mL is numerically lower than 0.1 ng/mL, but the latter may not represent the 99th-percentile threshold of the specific assay used in practice. If the original unit is correct, 0.058 ng/mL equals 58 ng/L; whether that is considered elevated depends on the assay and analytical method. Reporting only ‘troponin positive’ or ‘troponin negative’ without the assay-specific cutoff risks either overdiagnosis or missed myocardial injury. Even with a confirmed elevated result, a rise or fall on serial testing is needed to demonstrate an acute process, whilst ischaemic clinical evidence helps distinguish myocardial infarction from non-ischaemic injury [1-3]. No such series is available here. Thus, this case does not establish a genuinely biomarker-negative NSTEMI; instead, it demonstrates an unresolved discrepancy between the narrative diagnosis and the recorded laboratory comparator.

CK does not resolve that discrepancy. The total CK value of 224 U/L represents a mild increase above the supplied reference range, but total CK can increase because of skeletal muscle injury, exertion, and other non-cardiac processes. A total CK result is not equivalent to a CK-MB measurement and cannot be used as a specific substitute for cardiac troponin in the contemporary definition of myocardial infarction [1]. No CK-MB or repeat CK results were provided. The appropriate diagnostic interpretation is therefore that the patient had suspected non-ST-elevation ACS with critical obstructive coronary artery disease, whilst the recorded information does not permit a confident retrospective distinction between NSTEMI and unstable angina.

Why CKD makes interpretation and decision-making more complex

CKD often complicates interpretation in the opposite direction: troponin concentrations may remain chronically elevated even without an acute infarction. Chronic myocardial injury, cardiac remodelling, microvascular disease, and impaired kidney function all contribute to this phenomenon. This is why a single troponin result must be interpreted alongside renal function, the timing of chest pain, ECG findings, and changes on serial sampling [2,3]. In the present patient, CKD increases the importance of the missing

creatinine, estimated glomerular filtration rate, and sequential troponin data. It would be inappropriate to infer either a chronic baseline troponin elevation or an acute rise from the one number supplied.

The patient's diabetes, hypertension, and previous coronary stent also increased his pre-test probability of clinically important coronary disease. The absence of acute ECG changes was not reassuring enough to exclude non-ST-elevation ACS, since the ECG may be normal or non-diagnostic in this group [2]. Taken together, these factors support the need for a structured clinical assessment rather than applying a binary interpretation to an isolated laboratory result.

Risk-directed coronary angiography despite diagnostic uncertainty

The GRACE risk model incorporates clinical and biochemical variables to estimate short-term risk in ACS and can inform the urgency of invasive investigation [4]. The source case account referred to 'intermediate risk' but omitted a calculated score and renal function values, so that designation cannot be verified. Both European and UK pathways recommend tailoring invasive assessment to the patient's level of risk, ongoing symptoms, haemodynamic stability, and evidence of myocardial injury rather than advocating immediate catheterisation for every patient with chest discomfort [2,5,6].

In this case, angiography revealed a 99% right coronary artery lesion, and the patient received a further stent, demonstrating that a non-diagnostic initial ECG and uncertain biomarker interpretation can coexist with important coronary disease. The intervention is a factual outcome of the clinical decision, not independent proof that infarction occurred. Critical coronary stenosis can be present in unstable angina as well as in NSTEMI. Decision-making should additionally account for CKD-related contrast and bleeding risks, whilst avoiding the assumption that renal dysfunction automatically precludes invasive treatment [2,3].

Personalised antiplatelet therapy and secondary prevention

The original report described aspirin loading and treatment with clopidogrel. Antiplatelet therapy is central to the treatment of ACS and to care following coronary stenting, but the selection of a P2Y12 inhibitor, treatment timing, and duration of dual antiplatelet therapy should depend on coronary anatomy, intervention strategy, concomitant medicines, and bleeding risk [2,5]. CKD can increase both ischaemic and haemorrhagic risk; scoring systems such as CRUSADE may assist bleeding-risk evaluation but must not be interpreted as a substitute for individual assessment [7]. Because the case account lacks the bleeding history, stent type, clinical reasoning for clopidogrel, and complete procedural record, it cannot determine whether another antiplatelet regimen would have been preferable.

The reported use of high-flow oxygen also requires context. Contemporary guidelines discourage routine oxygen in normoxaemic patients with ACS, but the patient's oxygen saturation was not recorded; consequently, the appropriateness of oxygen in this particular admission cannot be assessed [2]. The addition of bisoprolol and arrangement of an outpatient echocardiogram suggest ongoing secondary-prevention planning. Longer-term cardiovascular risk reduction would ordinarily include review of lipid-lowering therapy, blood pressure and diabetes management, smoking status, exercise and rehabilitation, and patient-centred follow-up; this retrospective record does not confirm whether each element occurred [5].

Established pathways and emerging biomarkers

High-sensitivity troponin-based pathways have improved efficiency in emergency departments, but their performance depends on validated assay-specific cutoffs and appropriate sampling intervals [8,9]. Research into sex-specific thresholds shows why a single numerical cutoff cannot automatically be transferred across testing platforms or populations [10]. In complex patients with CKD, algorithmic tools can support, but do not replace, the interpretation of symptoms and objective evidence of injury. Our case illustrates the importance of reporting the exact assay, unit, and threshold, especially when a retrospectively quoted 'normal range' conflicts with the clinical conclusion.

Other proposed ACS biomarkers include inflammatory mediators, neurohormonal markers, and circulating non-coding RNAs. Although some may offer additional prognostic information, they have not displaced cardiac troponin, ECG assessment, or established risk-based coronary evaluation in routine acute care [11]. Their potential value in multimorbid patients remains an area for investigation rather than an explanation for the findings in this individual.

Limitations

The principal limitation is the incomplete underlying clinical record. Only one troponin T and one total CK result were supplied, with a troponin unit inferred from a printed reference interval rather than confirmed from the laboratory report. The assay-specific 99th-percentile upper reference limit, exact sample timing, serial biomarker results, creatinine and estimated glomerular filtration rate, oxygen saturation, GRACE score, full angiographic description, stent specification, and longer-term follow-up were not available.

Moreover, the source manuscript describes the troponin as positive whilst quoting a reference cutoff above the numerical result. We have retained both pieces of information and disclosed the inconsistency rather than altering either value. As a result, the case supports a diagnosis of clinically significant obstructive coronary disease in a patient managed for suspected ACS, but not definitive retrospective confirmation of NSTEMI under current biochemical criteria.

Conclusions

This case demonstrates how an apparently non-elevated troponin result relative to a reported reference range can coexist with severe coronary stenosis in a patient presenting with suspected non-ST-elevation ACS. Angiography revealed a critical right coronary artery lesion and enabled revascularisation. However, the patient's documented NSTEMI label cannot be independently verified using the limited biomarker information available, and unstable angina remains a plausible alternative classification.

Accurate interpretation of cardiac biomarkers requires a verified assay-specific threshold and serial results, considered alongside the clinical history, ECG, comorbidity burden, and risk stratification. Personalised ACS management should acknowledge both the danger of missing significant coronary disease and the risk of over-interpreting incomplete investigations. Transparent reporting of diagnostic uncertainty strengthens, rather than weakens, the educational value of this case.

Additional Information

Author Contributions

All authors have reviewed the final version to be published and agreed to be accountable for all aspects of the work.

Concept and design: Suki Bernstein, Maryam Borumand

Acquisition, analysis, or interpretation of data: Suki Bernstein, Maryam Borumand, Elham Sahibzada, Lahari Dammala, Natasha Sheelam

Drafting of the manuscript: Suki Bernstein, Maryam Borumand, Elham Sahibzada, Lahari Dammala, Natasha Sheelam

Critical review of the manuscript for important intellectual content: Suki Bernstein, Maryam Borumand, Elham Sahibzada, Lahari Dammala, Natasha Sheelam

Supervision: Suki Bernstein, Maryam Borumand

Disclosures

Human subjects: Informed consent for treatment and open access publication was obtained or waived by all participants in this study. **AI use statement:** The authors used ChatGPT (OpenAI, San Francisco, CA, USA) as follows: structure or formatting, language polishing in entire manuscript. Several drafts were written over several sittings and reviewed by different people. AI was only used to reformat and double-check grammar, spelling, and compliance with Cureus. The authors confirm that they have reviewed and verified all AI-assisted content and take full responsibility for the work. **Conflicts of interest:** In compliance with the ICMJE uniform disclosure form, all authors declare the following: **Payment/services info:** All authors have declared that no financial support was received from any organization for the submitted work. **Financial relationships:** All authors have declared that they have no financial relationships at present or within the previous three years with any organizations that might have an interest in the submitted work. **Other relationships:** All authors have declared that there are no other relationships or activities that could appear to have influenced the submitted work.

Acknowledgements

Dr. Maryam Borumand and Dr. Suki Bernstein contributed equally to this manuscript and share equal first-author standing.

References

1. Mills NL, Newby LK, Zaman S, et al.: Fifth universal definition of myocardial infarction (2026). J Am Coll Cardiol. 2026, 88:1314-68. 10.1016/j.jacc.2026.07.025
2. Byrne RA, Rossello X, Coughlan JJ, et al.: 2023 ESC guidelines for the management of acute coronary syndromes. Eur Heart J. 2023, 44:3720-826. 10.1093/eurheartj/ehad191
3. Braghieri L, Badwan OZ, Skoza W, Fares M, Menon V: Evaluating troponin elevation in patients with chronic kidney disease and suspected acute coronary syndrome. Cleve Clin J Med. 2023, 90:483-9. 10.3949/ccjm.90a.23012
4. Granger CB, Goldberg RJ, Dabbous O, et al.: Predictors of hospital mortality in the global registry of acute

coronary events. Arch Intern Med. 2003, 163:2345-53. 10.1001/archinte.163.19.2345
5. National Institute for Health and Care Excellence. Acute coronary syndromes (NG185) . (2020). Accessed: October 29, 2026: https://www.nice.org.uk/guidance/ng185.
6. National Institute for Health and Care Excellence. Recent-onset chest pain of suspected cardiac origin: assessment and diagnosis (CG95). (2010). Accessed: October 29, 2026: https://www.nice.org.uk/guidance/cg95.
7. Subherwal S, Bach RG, Chen AY, et al.: Baseline risk of major bleeding in non-ST-segment-elevation myocardial infarction: the CRUSADE (Can Rapid risk stratification of Unstable angina patients Suppress ADverse outcomes with Early implementation of the ACC/AHA Guidelines) bleeding score. Circulation. 2009, 119:1873-82. 10.1161/CIRCULATIONAHA.108.828541
8. Hughes AE, Forbriger A, May AM, Scott MG, Char D, Farnsworth CW: Implementation of high-sensitivity troponin with a rapid diagnostic algorithm reduces emergency department length of stay for discharged patients. Clin Biochem. 2023, 116:87-93. 10.1016/j.clinbiochem.2023.04.003
9. Lowry MT, Doudesis D, Boeddinghaus J, et al.: Troponin in early presenters to rule out myocardial infarction. Eur Heart J. 2023, 44:2846-58. 10.1093/eurheartj/ehad376
10. Shah AS, Griffiths M, Lee KK, et al.: High sensitivity cardiac troponin and the under-diagnosis of myocardial infarction in women: prospective cohort study. BMJ. 2015, 350:g7873. 10.1136/bmj.g7873
11. Katsioupa M, Kourampi I, Oikonomou E, et al.: Novel biomarkers and their role in the diagnosis and prognosis of acute coronary syndrome. Life (Basel). 2023, 13:1992. 10.3390/life13101992