Cureus
Part of SPRINGER NATURE

Open Access Case Report

Severe Hepatotoxicity During Treatment of Spinal Tuberculosis Mimicking Metastatic Cord Compression: A Case Report

Sohel Sohel [1]

1. Oncology, NIHR Southampton Clinical Research Facility and NIHR Southampton Biomedical Research Centre, University Hospital Southampton NHS Foundation Trust, Southampton, GBR

Corresponding author: Sohel Sohel, sohel.sohel@uhs.nhs.uk

Review began 10/29/2026
Review ended 11/18/2026
Published 11/23/2026

© **Copyright** 2026
Sohel. This is an open access article distributed under the terms of the Creative Commons Attribution License CC-BY 4.0., which permits unrestricted use, distribution, and reproduction in any medium, provided the original author and source are credited.

DOI: 10.7759/cureus.120118

Abstract

Spinal tuberculosis (TB) can closely mimic metastatic malignancy or lymphoma on imaging, creating diagnostic uncertainty in patients presenting with spinal cord compression. This is a case report of a previously healthy 35-year-old male who presented with a three-week history of progressive gait disturbance, thoracic-level sensory changes, and signs of upper motor neuron dysfunction. Magnetic resonance imaging (MRI) demonstrated extensive vertebral destruction, a large paraspinal soft tissue mass, and severe spinal cord compression at the T3/T4 level, raising initial concerns for metastatic malignancy or lymphoma. However, the patient's age, country of origin, and a remote history of a non-healing back ulcer broadened the differential diagnosis. Urgent spinal decompression was performed to prevent irreversible neurological injury and to obtain tissue for diagnosis. Histology revealed necrotising granulomatous inflammation with multinucleated giant cells, and molecular testing detected *Mycobacterium tuberculosis* complex, confirming spinal TB. Anti-tuberculous therapy was complicated by severe drug-induced liver injury, with alanine aminotransferase (ALT) rising to 1440 U/L. This required temporary cessation of first-line agents and a liver-sparing treatment regimen, followed by stepwise reintroduction of standard therapy. This case highlights the radiological overlap between spinal TB and metastatic disease, underscores the value of early tissue diagnosis in undifferentiated spinal lesions, and illustrates the management challenges of severe anti-tuberculous drug-induced hepatotoxicity in a patient at risk of permanent neurological disability.

Categories: Radiology, Internal Medicine, Infectious Disease
Keywords: anti-tuberculous therapy, drug-induced liver injury, pott's disease, spinal cord compression, spinal tuberculosis, tissue diagnosis

Introduction

Spinal tuberculosis (TB) is the most common form of musculoskeletal TB and remains an important cause of granulomatous spinal inflammation. It can cause vertebral destruction, paraspinal soft tissue masses, and spinal cord compression. On imaging, it can closely resemble other destructive spinal pathology. Metastatic disease and lymphoma classically present with localised back pain, radicular symptoms, sensory or motor deficit, or sphincter dysfunction as the cord or nerve roots are compressed [1-5]. Pyogenic and tuberculous spondylodiscitis are usually accompanied by fever and a raised inflammatory response, and distinguishing between them is a recognised diagnostic challenge [3-5]. When the presentation is subacute and lacks constitutional features, as in the patient described here, the clinical picture can be misleading and may suggest malignancy rather than infection. Confirming the diagnosis often requires tissue examination. This is complicated by the pauci-bacillary nature of extra-pulmonary TB, in which smear and culture may be negative. Hence, there is an increased reliance on histopathology and molecular methods such as polymerase chain reaction (PCR) [5]. Subtle historical findings, such as a previous non-healing skin lesion, may also point towards a chronic atypical infective process and should warrant active investigation.

The treatment of extra-pulmonary TB involves additional challenges. Anti-tuberculous therapy carries a substantial risk of drug-induced liver injury (DILI), which may force interruption of first-line drugs [6]. This is particularly problematic when there is extensive spinal disease and a risk of further neurological injury, since treatment cannot safely be paused.

This report focuses on a previously healthy 35-year-old male who presented with progressive thoracic myelopathy and imaging suggestive of extensive malignant spinal disease. He was ultimately diagnosed with tuberculous spondylodiscitis on surgical biopsy, and his treatment was complicated by severe DILI requiring a liver-sparing regimen. This case highlights the radiological overlap between spinal TB and metastatic disease, the value of a detailed history and of tissue diagnosis, and the practical management of severe anti-tuberculous DILI.

Case Presentation

A previously healthy 35-year-old male presented with a three-week history of altered sensation across the chest and progressive gait disturbance. He reported numbness extending from his chest down to both lower limbs developing over several days. He described the sensation as feeling like "an extra layer of skin" covering his body. Deterioration of his walking and balance progressed to a point where he required support from nearby objects to avoid falling while being outdoors. He denied falls, bladder or bowel dysfunction, visual symptoms, constitutional symptoms, skin rash, use of recreational drugs, smoking, and nitrous oxide misuse. Alcohol consumption was minimal, with his only travel in the seven months prior to presentation being a trip to his home country, the Philippines. He had no significant past medical history apart from three years old surgically treated non-healing ulcer on his back for which was not histologically scrutinised.

Neurological examination showed an ataxic gait with a sensory level around T10, and brisk lower limb reflexes with extensor plantar responses. Systemic and general examinations were unremarkable. An MRI was performed (Figures *1*, *2*) following non-clinically significant findings on routine laboratory tests and rheumatological screening. The MRI showed extensive vertebral destruction, paraspinal soft-tissue extension, and severe cord compression, raising concerns for malignant spinal disease or advanced spinal tuberculosis..



FIGURE 1: Sagittal STIR MRI showing high grade spinal canal stenosis at T3/T4 with cord compression

MRI showing features raising concern for malignant spinal disease including extensive vertebral destruction, paraspinal soft-tissue extension, and severe cord compression.

STIR: Short-TI Inversion Recovery; MRI: magnetic resonance imaging

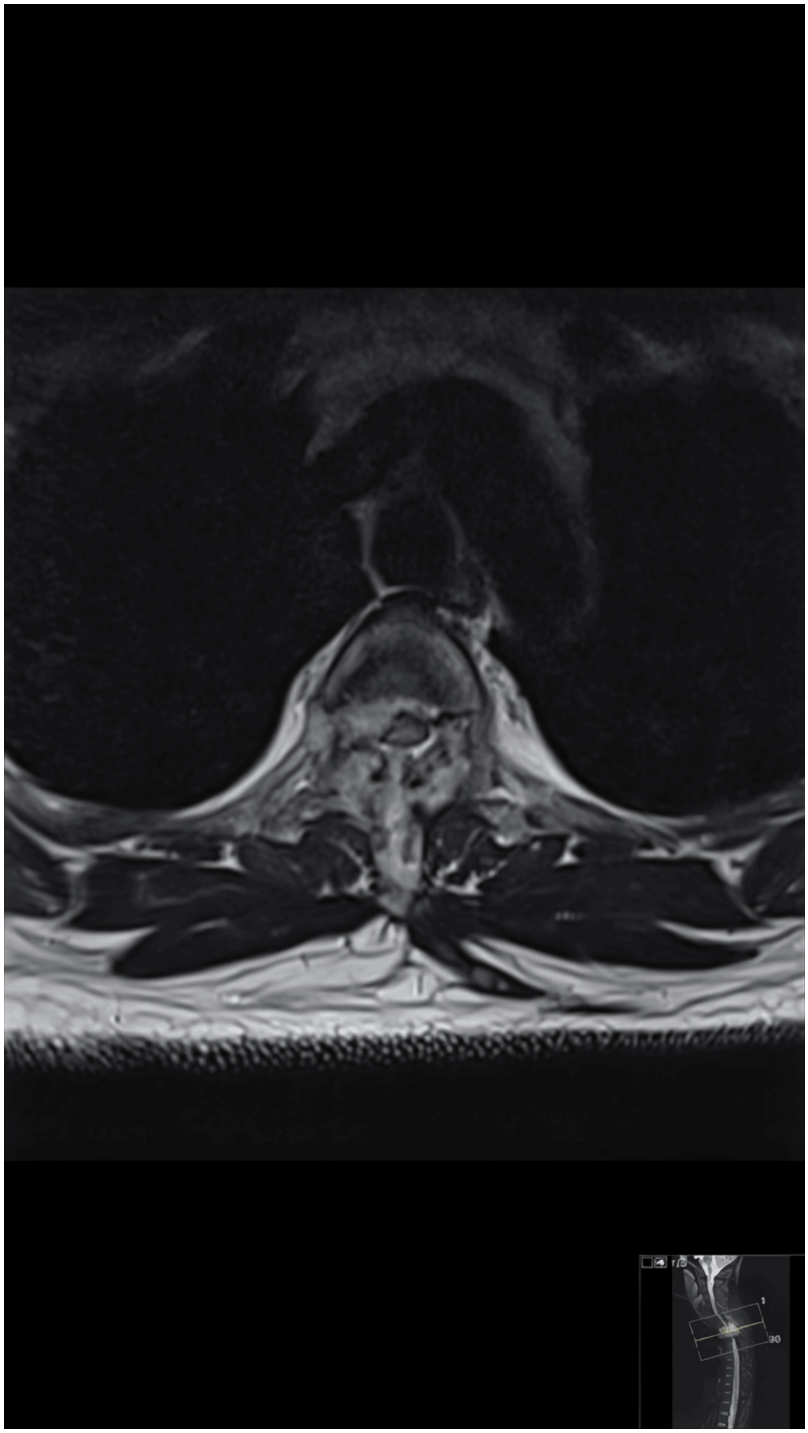

FIGURE 2: Axial T2W MRI showing extensive pathological soft tissue involving the vertebral bodies and posterior elements

MRI showing features of malignant spinal disease included extensive vertebral destruction, paraspinal soft-tissue extension, and severe cord compression.

T2W MRI: axial T2-weighted magnetic resonance imaging scan

During spinal surgery to prevent further neurological injury, biopsy of the MRI-detected spinal abnormality was performed. Bacterial and fungal cultures, PCR testing, tuberculosis culture, and histopathological examinations were performed to evaluate for malignancy, tuberculosis, and other infections. In this case, *Mycobacterium tuberculosis* complex was detected by PCR at low levels. Pauci-bacillary disease is common in extra-pulmonary tuberculosis. Bacterial culture did not detect any pathogens. The histology showed no evidence of malignancy but demonstrated necrotising granulomatous inflammation and giant cells,

consistent with tuberculous spondylodiscitis (Figure 3). Additionally, he underwent a mycological culture for fungal infection, which tested negative.

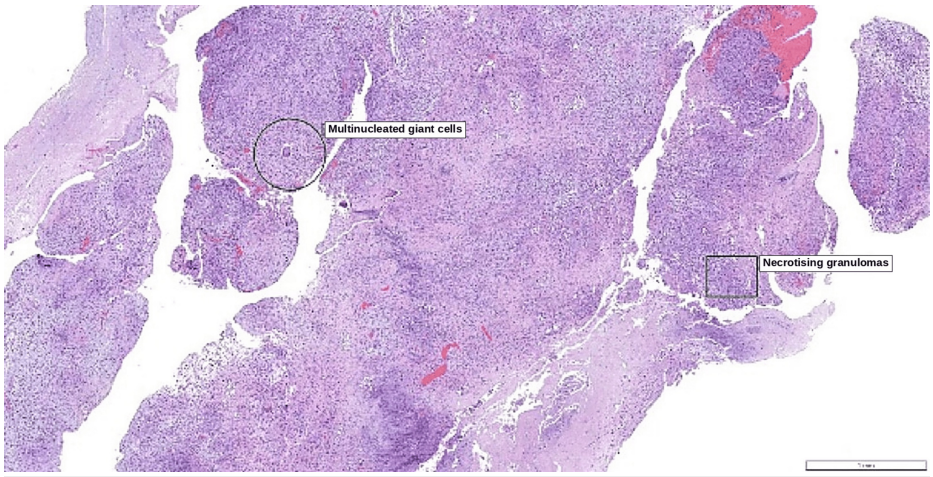

FIGURE 3: Histopathological studies showing multinucleated giant cells and necrotising granuloma suggesting Mycobacterium tuberculosis

A computed tomography (CT) scan of the chest, abdomen, and pelvis to evaluate for extraspinal tuberculosis or malignancy revealed no abnormalities outside the spine. The differential diagnosis includes metastatic malignancy (such as lymphoma), tuberculous spondylitis, and pyogenic osteomyelitis. Spinal metastases are an extension of neoplastic disease which most commonly present with localised back pain, followed by radicular pain, sensory/motor weakness, or bowel and bladder dysfunction when nerve roots or the spinal cord are compressed [1]. Lymphoma-induced spinal cord compression presents similarly to a malignancy [2]. Typically, both pyogenic osteomyelitis and spinal tuberculosis would be associated with fever and inflammatory response. Distinguishing between the two conditions may present a significant diagnostic challenge [3-5]. The history of a skin ulcer requiring surgical management raised the possibility of an atypical infection as the cause of his spinal pathology.

Treatment for *Mycobacterium tuberculosis* was commenced prior to surgery given the high suspicion of tuberculosis and severe presentation, with rifampicin, isoniazid plus pyridoxine, pyrazinamide, and moxifloxacin, which replaced ethambutol to provide pyogenic bacterial cover. Steroids were also given to treat central nervous system tuberculosis and reduce swelling and pressure on the spinal cord, in case of suspected malignancy or lymphoma. Drug-induced liver injury developed 10 days into tuberculosis treatment, with alanine aminotransferase (ALT) peaking at 1,440 U/L (normal: 0-49 U/L) and requiring discontinuation of therapy (Table 1).

Parameters	Liver profile		Reference Range
	day 10 after anti-tubercular treatment	After resolution of liver injury	
Albumin	35	42	35 - 50 g/L
ALT	1440	48	0 - 49 U/L
Bilirubin	6	9	0 - 20 umol/L
Alkaline Phosphatase	278	79	30 – 130 U/L

TABLE 1: Liver profile values on 10th day of anti-tubercular treatment commencement and later when liver injury resolved

ALT: alanine aminotransferase

A less hepatotoxic treatment regimen was started immediately rather than pausing treatment and restarting later, given the extensive nature of his spinal disease and risk of further neurological injury. He received moxifloxacin, linezolid, and ethambutol until his liver injury resolved, after which standard treatment was

reintroduced in a stepwise plan as per guidelines.Tuberculosis drug-induced liver injury is defined as either a three-fold rise in ALT and raised bilirubin (>2x upper limit of normal) or presence of symptoms, or a five-fold rise in ALT [6]. Given that elevated ALT alongside normal bilirubin indicates hepatocellular injury rather than acute biliary obstruction, he was thoroughly evaluated for autoimmune hepatitis, viral hepatitis, and other etiologies of liver dysfunction, all of which were excluded. The RUCAM (Roussel Uclaf Causality Assessment Method) score calculated for him was +8, further pointing to anti-tubercular drug therapy as the likely cause. Commencing an alternative liver-sparing regimen did show improvement in liver markers, and after confirming repeated normal levels of the liver profile, he was switched to standard therapy. A repeat liver profile confirmed that liver injury did not recur (Table *2*). He made a complete neurological recovery while on treatment, with no recurrence of neurological symptoms later on.

Parameter	Liver profile		Reference Range
	When liver sparing anti tubercular therapy was initiated	When standard anti tubercular therapy was re started	
Albumin	39	43	35 - 50 g/L
ALT	962	30	0 - 49 U/L
Bilirubin	9	9	0 - 20 umol/L
Alkaline Phosphatase	201	80	30 – 130 U/L

TABLE 2: Liver profile when liver sparing anti tubercular therapy was instated and when standard anti tubercular therapy was re started.

ALT: alanine aminotransferase

Discussion

Tuberculosis is the leading cause of granulomatous spinal inflammation, with the spine being the primary site of musculoskeletal tuberculosis [5]. The combination of progressive thoracic myelopathy and extensive soft tissue involvement, vertebraldestruction, and apparent multifocal neuro-axial disease on MRI raised concerns for malignant spinal disease in the patient. This diagnostic pitfall is already documented. Yuen and Loo reported an immunocompetent 28-year-old man whose multifocal skeletal TB mimicked widespread bony metastases. Imaging showed a pathological fracture, osteolytic lesions, non-contiguous spinal involvement, and posterior element disease, and cross-sectional imaging found no primary tumour [7]. Similarly, in the present case, the absence of constitutional features and of an identifiable primary lesion implied that imaging alone could not exclude malignancy. Both cases support the view that spinal TB should not be diagnosed or excluded on imaging features alone, and that tissue sampling is needed when the picture is atypical.

The patient's medical history suggested an etiology that was not strictly malignant. His age, his birth in a country where TB is endemic, and the lack of a primary tumour on CT of the chest, abdomen, and pelvis all broadened the differential diagnosis [8]. The earlier non-healing back ulcer, which was surgically treated but never examined histologically, also raised the possibility of a chronic atypical infection. No causal link can be established between the ulcer and the spinal disease, so it is noted only as a historical clue that broadened the differential diagnosis. This highlights the importance of evaluating a history of chronic or poorly healing lesions in cases of unexplained spinal pathology.

The microbiological findings in this case reflect the pauci-bacillary nature of extra-pulmonary TB. Although bacterial cultures returned negative, PCR detected low levels of Mycobacterium tuberculosis complex, and histology revealed necrotising granulomatous inflammation with giant cells. These findings align with published literature. In a prospective study of spinal TB biopsies, Xpert MTB/RIF Ultra had a sensitivity of 94.7% and a specificity of 100% against a reference standard of culture and histopathology, detecting more cases than culture alone in CT-guided samples. [9]. Matching the case in presentation, these findings suggest that molecular testing and histopathology should be requested alongside culture, and that a negative culture should not exclude TB.

Surgery served two purposes: it relieved cord compression, and it provided tissue for diagnosis. Spinal TB is now regarded largely as a medical disease in which anti-tubercular therapy is the most important determinant of outcome, with surgery reserved for neurological compromise, deformity or instability, compression by an abscess, or deterioration despite treatment [10]. The patient in this case met all these criteria and was started on anti-tubercular therapy before surgery because of the high clinical suspicion and

the severity of the presentation. Moxifloxacin was used in place of ethambutol to cover pyogenic bacteria while the diagnosis was unconfirmed, and steroids were given to reduce cord swelling should the lesion prove to be malignancy or lymphoma. Evidence for adjunctive steroids in spinal TB is limited, and their use in our case was empirical in the setting of diagnostic uncertainty [11].

The main complication of treatment was severe drug-induced liver injury (DILI), with ALT levels peaking at 1440 U/L, roughly 29 times the upper limit of normal. This far exceeds the thresholds used to define anti-tubercular DILI [6]. In a randomised trial of 175 patients with anti-tubercular DILI, three reintroduction strategies (simultaneous and two sequential approaches) did not differ significantly in the rate of recurrent liver injury [12]. Guidelines describe stopping the hepatotoxic first-line drugs and then reintroducing them, with an interim non-hepatotoxic regimen often needed when treatment cannot safely be paused [6,13]. In this patient, extensive spinal disease and the risk of further neurological injury meant that pausing treatment was not an option. He was therefore given a liver-sparing regimen of moxifloxacin, linezolid, and ethambutol until the liver injury had resolved, followed by reintroduction of standard drugs, which happened stepwise according to guidelines. This pragmatic approach is relevant for other patients with spinal or central nervous system TB, in whom an unplanned treatment interruption carries a high cost. Linezolid, however, carries its own risks of myelosuppression and neuropathy, which require monitoring when it is used for more than a short period [14].

This case report has limitations. Given the single-patient case, low PCR signal, and absence of histologic examination of the back ulcer, any connection to the spinal disease remains speculative. Despite this, the case shows that spinal TB can mimic metastatic disease on imaging, that a thorough history and tissue diagnosis are essential, and that severe anti-tubercular DILI can be managed without interrupting effective therapy.

Conclusions

Spinal tuberculosis can mimic metastatic malignancy on MRI, particularly when extensive vertebral destruction and paraspinal soft tissue masses are present. Subtle or overlooked elements of a patient's history can occasionally play a key role in clinical decision-making. In this case, a back ulcer that needed surgical management led the clinician to suspect a chronic atypical infectious process. Progressive myelopathy due to spinal cord compression requires urgent investigation and often surgical intervention. Histological demonstration of necrotising granulomatous inflammation should prompt urgent investigation for tuberculosis even when acid-fast bacilli are not identified. Molecular diagnostic techniques, such as PCR can rapidly confirm the diagnosis.Severe anti-tuberculous drug-induced liver injury may necessitate temporary withdrawal of first-line therapy and use of a liver-sparing treatment strategy under specialist supervision.

Additional Information

Author Contributions

All authors have reviewed the final version to be published and agreed to be accountable for all aspects of the work.

Concept and design: Sohel Sohel

Acquisition, analysis, or interpretation of data: Sohel Sohel

Drafting of the manuscript: Sohel Sohel

Critical review of the manuscript for important intellectual content: Sohel Sohel

Disclosures

Human subjects: Informed consent for treatment and open access publication was obtained or waived by all participants in this study. **Conflicts of interest:** In compliance with the ICMJE uniform disclosure form, all authors declare the following: **Payment/services info:** All authors have declared that no financial support was received from any organization for the submitted work. **Financial relationships:** All authors have declared that they have no financial relationships at present or within the previous three years with any organizations that might have an interest in the submitted work. **Other relationships:** All authors have declared that there are no other relationships or activities that could appear to have influenced the submitted work.

Acknowledgements

I have used Artificial Intelligence / large language model CLAUDE for this case report in phrasing and grammatical correction of the writing. LLM was not used to generate any evidence or results for this case report. The use was only limited to restructure or improve phrasing of sentences while maintaining

grammatical accuracy.

References

1. Perrin RG, Laxton AW: Metastatic spine disease: epidemiology, pathophysiology, and evaluation of patients . Neurosurg Clin N Am. 2004, 15:365-73. 10.1016/j.nec.2004.04.018
2. Gendreau JL, Patel N, Brown NJ, et al.: Surgical intervention for primary B-cell lymphoma of the spine: a systematic review and meta-analysis of clinical presentation, treatment, postoperative outcomes, and histologic markers. Clin Spine Surg. 2024, 37:296-304. 10.1097/BSD.0000000000001522
3. Chan KM, Leung PC, Lee SY, Ho YF, Leung KS: Pyogenic osteomyelitis of the spine--a review of 16 consecutive cases. J Spinal Disord. 1988, 1:224-31.
4. Garg RK, Somvanshi DS: Spinal tuberculosis: a review. J Spinal Cord Med. 2011, 34:440-54. 10.1179/2045772311Y.0000000023
5. Marian A, Vanţa OM, Danci V, et al.: Differentiating tuberculous and pyogenic spondylodiscitis: part I - epidemiology, clinical features, laboratory markers, and tissue-based diagnosis. Diagnostics (Basel). 2026, 16:2243. 10.3390/diagnostics16142243
6. Lim WS, Avery A, Kon OM, Dedicoat M: Anti-tuberculosis drug-induced liver injury. BMJ. 2023, 383:e074866. 10.1136/bmj-2023-074866
7. Yuen WL, Loo WL: Multifocal tuberculous osteomyelitis mimicking widespread bony metastases: review of literature and case report. Spinal Cord Ser Cases. 2022, 8:23. 10.1038/s41394-022-00496-9
8. World Health Organization: Global tuberculosis report 2025. (2025). Accessed: October 28, 2026: https://www.who.int/teams/global-programme-on-tuberculosis-and-lung-health/tb-reports/global-tuberculosis-report-2025.
9. Waters R, Laubscher M, Dunn RN, Adikary N, Coussens AK, Held M: Higher sensitivity of Xpert MTB/RIF Ultra over tuberculosis culture for the diagnosis of spinal tuberculosis with open or computed tomography-guided biopsies. Open Forum Infect Dis. 2024, 11:ofad621. 10.1093/ofid/ofad621
10. Ruparel S, Tanaka M, Mehta R, Yamauchi T, Oda Y, Sonawane S, Chaddha R: Surgical management of spinal tuberculosis—the past, present, and future. Diagnostics (Basel). 2022, 12:1307. 10.3390/diagnostics12061307
11. Thwaites G, Fisher M, Hemingway C, Scott G, Solomon T, Innes J: British Infection Society guidelines for the diagnosis and treatment of tuberculosis of the central nervous system in adults and children. J Infect. 2009, 59:167-87. 10.1016/j.jinf.2009.06.011
12. Sharma SK, Singla R, Sarda P, et al.: Safety of 3 different reintroduction regimens of antituberculosis drugs after development of antituberculosis treatment-induced hepatotoxicity. Clin Infect Dis. 2010, 50:833-9. 10.1086/650576
13. Saukkonen JJ, Cohn DL, Jasmer RM, et al.: An official ATS statement: hepatotoxicity of antituberculosis therapy. Am J Respir Crit Care Med. 2006, 174:935-52. 10.1164/rccm.200510-1666ST
14. Wasserman S, Brust JC, Abdelwahab MT, et al.: Linezolid toxicity in patients with drug-resistant tuberculosis: a prospective cohort study. J Antimicrob Chemother. 2022, 77:1146-54. 10.1093/jac/dkac019