Cureus
Part of SPRINGER NATURE

Open Access Case Report

UCLA Health
Published via Proceedings of the UCLA Department of Medicine

Progressive Lung Fibrosis After COVID-19 Pneumonia: A Report of Two Cases Posing a Differential Diagnostic Conundrum

Received 10/27/2026
Review began 11/02/2026
Review ended 11/11/2026
Published 11/21/2026

© Copyright 2026
Dolinay et al. This is an open access article distributed under the terms of the Creative Commons Attribution License CC-BY 4.0., which permits unrestricted use, distribution, and reproduction in any medium, provided the original author and source are credited.

DOI: 10.7759/cureus.120069

Tamas Dolinay [1], Peter L. Ven [2]

1. Department of Medicine, University of California, Los Angeles, Los Angeles, USA 2. First Department of Internal Medicine, Medical School, University of Pécs, Pécs, HUN

Corresponding author: Tamas Dolinay, tdolinay@mednet.ucla.edu

Abstract

Post-severe acute respiratory syndrome coronavirus 2 (SARS-CoV-2, COVID-19) interstitial lung disease (ILD) encompasses a heterogeneous spectrum of pulmonary abnormalities, ranging from resolving inflammatory changes to persistent fibrosis. Although most post-infectious abnormalities stabilize or regress over time, a subset of patients develop progressive pulmonary fibrosis (PPF). Distinguishing post-infectious sequelae from newly emerging or previously unrecognized PPF is a diagnostic challenge. We present two cases of PPF following severe COVID-19 pneumonia. The first patient, a 57-year-old man, developed persistent hypoxemic respiratory failure following COVID-19 infection in 2020. After several years of radiological stability, following a new-onset pneumonia, progressive restrictive lung disease developed, marked by fibrotic abnormalities on high-resolution computed tomography of the chest (HRCT). Despite corticosteroid and mycophenolate mofetil therapy, the patient continued to deteriorate, with the development of PPF. The second patient is a 64-year-old man who presented with predominantly ground-glass lung opacities and restrictive lung disease following severe COVID-19 pneumonia in 2021. Initial corticosteroid treatment resulted in substantial radiological improvement and subsequent stability. However, in 2025, new fibrotic changes, including subpleural honeycombing, emerged with significant physiological deterioration. In both patients, the diagnostic evaluation was limited by the absence of conclusive histopathological findings, but because of radiological and clinical progression, antifibrotic medication nintedanib was initiated, and the patients were referred for lung transplant evaluation. Our cases illustrate the heterogeneous and potentially progressive nature of pulmonary abnormalities following severe COVID-19 infection. PPF may develop several years after severe COVID-19 pneumonia, even with initial radiological improvement or prolonged stability. Because of the unpredictable course of the disease, the authors recommend continued evaluation with lung function testing and serial HRCT. For patients who progress despite medical therapy, early referral for lung transplant evaluation is advised.

Categories: Rheumatology, Pulmonology, Internal Medicine
Keywords: covid-19, covid-19 pneumonia, interstital lung disease, post-covid-19 interstitial lung disease, progressive pulmonary fibrosis

Introduction

The severe acute respiratory syndrome coronavirus 2 (SARS-CoV-2, COVID-19) pandemic resulted in health emergencies for millions worldwide. While many have recovered, the chronic sequelae of the disease continue to impact patients' lives. This is probably most apparent in those who survived severe COVID-19 pneumonia but develop interstitial lung disease (ILD), which often results in chronic disability.

Little is known about the origin of post-COVID-19 ILD, but preliminary research based on lung pathology [1] distinguishes four types of interstitial lung changes: diffuse alveolar damage (DAD), organizing pneumonia (OP), nonspecific interstitial pneumonia (NSIP), and usual interstitial pneumonia (UIP). While these entities were initially recognized on lung pathology, they are now commonly used in the clinical description of the disease based on imaging [2]. DAD and OP usually represent inflammatory changes early in the course of the disease, and fibrosis associated with NSIP or UIP may form later. However, the temporal and etiological relationship of these entities remains unknown. Progressive pulmonary fibrosis (PPF) is defined as clinical, physiological, and radiological progression of already established pulmonary fibrosis. Patients must meet at least two of three criteria in the past one year: 1) worsening respiratory symptoms; 2) a change in pulmonary function test (PFT) marked by more than 5% decline in forced vital capacity (FVC) absolute value and/or more than 10% reduction in diffusing capacity of the lung for carbon monoxide (DLCO) absolute value; 3) radiological progression in the extent or severity of bronchiectasis, formation of new ground-glass opacity (GGO) or reticulation, new or worsening honeycombing, or increase in lobar volume loss [3]. The purpose of this article is to present the diagnostic complexities of post-COVID-19 ILD and to provide a practical approach for these patients.

Case Presentation

Case 1

A 57-year-old gentleman with a medical history of multiple transient ischemic attacks (TIAs), previous cardiac surgery for atrial myxoma, gastroesophageal reflux disease (GERD), type 2 diabetes mellitus, obesity, and a 22-pack-year smoking history developed severe COVID-19 pneumonia in April 2020. The disease course is shown in Figure *1*. His occupational history was notable for asbestos exposure from work as a plumber, and he reported keeping two dogs at home. Although invasive ventilatory support was not required during the acute infection, he developed persistent hypoxemia requiring long-term oxygen therapy (LTOT). Initial PFT in October 2023 demonstrated restrictive ventilatory impairment marked by low FVC, low forced expiratory volume in 1 second (FEV_1), and severe reduction in DLCO. Post-hospitalization chest high-resolution computed tomography (HRCT) showed mild and stable post-inflammatory reticulation in 2024.

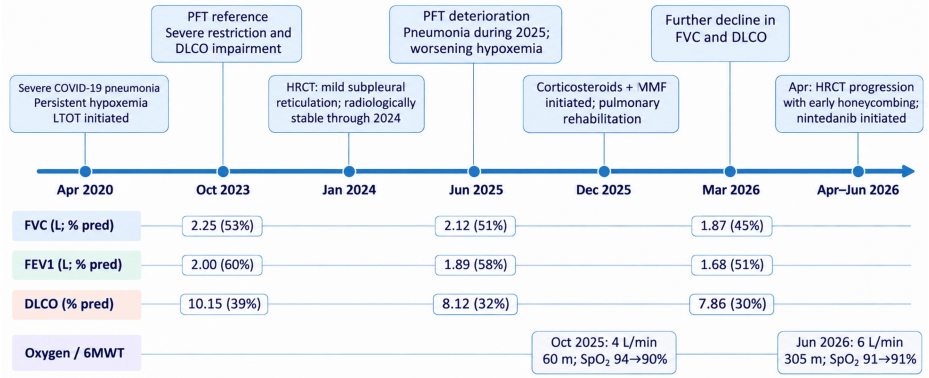

FIGURE 1: Clinical course of Case 1

Time course of disease progression from 2020 to 2026 with lung function and physiological testing.

DLCO: diffusing capacity of the lung for carbon monoxide; FEV_1: forced expiratory volume in 1 second; FVC: forced vital capacity; HRCT: high-resolution computed tomography; LTOT: long-term oxygen therapy; MMF: mycophenolate mofetil; PFT: pulmonary function test; SpO_2: peripheral oxygen saturation; 6MWT: six-minute walk test.

In March 2025, he developed pneumonia, which was treated with antibiotics and systemic corticosteroids as an outpatient. Following this episode, his preexisting hypoxemia worsened, and he was seen in our ILD clinic. HRCT of the chest demonstrated progressive lung disease with extensive fibrotic interstitial abnormalities without a particular pattern but primarily affecting the lower lobes. Neither traction bronchiectasis nor honeycombing was identified. A stable 9 mm pulmonary nodule was also present in the right upper lobe. Representative CT images are shown in Figure *2*.

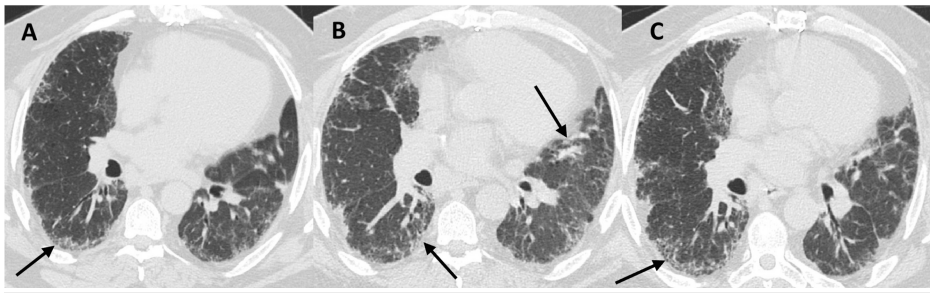

FIGURE 2: High-resolution computed tomography results of Case 1

A. Mild, subpleural reticulation in 2024; B. Peribronchovascular and subpleural progression in 2025; C. Early honeycombing in 2026. Arrows point to representative areas.

Given the patient's medical, occupational, and exposure history, post-inflammatory lung fibrosis, asbestosis, GERD-associated microaspiration, primary lung cancer, systemic autoimmune rheumatic disease-associated interstitial lung disease (SARD-ILD), and chronic hypersensitivity pneumonitis (CHP) were initially considered for the differential diagnosis of ILD. The differential diagnosis of ILD for Case 1 is shown in Table *1*.

ILD etiology	Typical HRCT distribution	Characteristic radiological findings	Features that do not support this diagnosis
Post-inflammatory fibrosis	Bilateral, predominantly peripheral and basal; sometimes peribronchovascular	Residual GGO, fine reticulation, parenchymal bands, traction bronchiectasis; honeycombing uncommon	Fibrotic-like abnormalities often stabilize; UIP pattern is uncommon
Asbestosis	Bilateral basal, posterior, and subpleural predominance	Pleural plaques, subpleural dots, subpleural curvilinear lines, intralobular reticulation, traction bronchiectasis, and advanced honeycombing	Missing pleural plaques and subpleural dots
GERD-related chronic microaspiration	Predominantly dependent regions, particularly posterior lower lobes; often airway-centered	Centrilobular nodules, tree-in-bud opacities, patchy GGO, bronchial wall thickening, bronchiectasis, and occasional consolidation; chronic injury may produce scarring	HRCT findings are not airway-centered; honeycombing is unlikely
Primary lung cancer	No typical distribution, often associated with lung mass and metastatic disease	Lymphangitic spread	No evidence of malignancy on biopsy
SARD-ILD	Bilateral GGO, fine reticulation, basal predominance, sometimes subpleural sparing (fibrotic NSIP)	Diffuse, lower lobe predominant reticulation with sparing of subpleural space	Development of UIP pattern
CHP	Variable; often diffuse, upper-lobe predominant	GGO, ill-defined centrilobular nodules, mosaic attenuation, air trapping, reticulation, traction bronchiectasis, and possible honeycombing in fibrotic CHP	Disease distribution is lower lobe dominant and shows subpleural predominance

TABLE 1: Differential diagnosis of COVID-19 interstitial lung disease in Case 1

CHP: chronic hypersensitivity pneumonitis; ILD: interstitial lung disease; HRCT: high-resolution computed tomography; GERD: gastroesophageal reflux disease; GGO: ground-glass opacity; NSIP: nonspecific interstitial pneumonia; SARD-ILD: systemic autoimmune rheumatic disease-associated interstitial lung disease; UIP: usual interstitial pneumonia.

Laboratory evaluation revealed only a low-titer positive antinuclear antibody (ANA; 1:40), while the remainder of the immunological work-up was unremarkable, suggesting against the presence of SARD-ILD. Both erythrocyte sedimentation rate (ESR) and C-reactive protein (CRP) levels were within the normal range. PFT demonstrated progressive, severe restrictive disease. During the six-minute walk test (6MWT), exercise capacity was impaired, and the patient was able to walk only 60 meters despite continuous supplemental oxygen.

To evaluate the right upper lobe nodule and the ILD, endobronchial ultrasound (EBUS)-guided transbronchial needle aspiration, core biopsy, and transbronchial cryobiopsy were performed. Lung tissue was obtained from the right upper and left lower lobes, and the mediastinal lymph nodes were also sampled. Histopathological and cytological examinations revealed no evidence of malignancy, excluded histological changes associated with asbestos-related lung disease, aspiration, and CHP, but did not provide an alternative diagnosis of the origin of the ILD. The bronchoalveolar lavage (BAL) was neutrophil-predominant without infectious agents.

Systemic corticosteroid therapy in combination with mycophenolate mofetil (MMF) was initiated in December 2025. Despite immunosuppressive treatment and completion of a pulmonary rehabilitation program, the patient's clinical condition continued to deteriorate, and his PFT declined in March 2026. HRCT of the chest in April 2026 demonstrated further radiological progression with early honeycombing. In view of the progressive fibrotic phenotype, antifibrotic therapy with nintedanib was started in April 2026.

Cardiovascular assessment with stress echocardiography demonstrated preserved left ventricular function without evidence of clinically significant cardiac dysfunction contributing to his functional limitation. At the same time, optimization of glycemic control with semaglutide was associated with a 5 kg reduction in body weight. The patient met criteria for PPF because of a reduction in exercise tolerance marked by increasing LTOT, decline in FVC, and worsening pulmonary fibrosis with new honeycombing on imaging. Given the progressive nature of the pulmonary fibrosis and the increasing home oxygen need up to 6 L/min by June 2026, the patient was referred for lung transplant evaluation.

Case 2

A 64-year-old never-smoker gentleman was evaluated in the ILD clinic. He had a complex medical history including Hodgkin lymphoma diagnosed in 1999, treated with chemotherapy and radiotherapy; hypothyroidism diagnosed in 2003; and a traumatic right-sided hydrothorax in 2007. In 2019, he developed diverticular disease requiring colostomy. His postoperative course was complicated by peritonitis necessitating reoperation in 2020, an incisional hernia with mesh repair, and another surgical intervention because of mesh-associated infection in October 2021.

In December 2021, the patient developed severe COVID-19 pneumonia. Following recovery from the acute infection, LTOT was prescribed because of recurrent episodes of hypoxemia. Follow-up chest HRCT demonstrated multifocal, upper-lobe-predominant GGOs without traction bronchiectasis, accompanied by subpleural architectural distortion, reticulation, and air trapping. PFT demonstrated a moderate restrictive ventilatory defect and a moderate reduction in DLCO. The disease course for Case 2 is shown in Figure *3*.

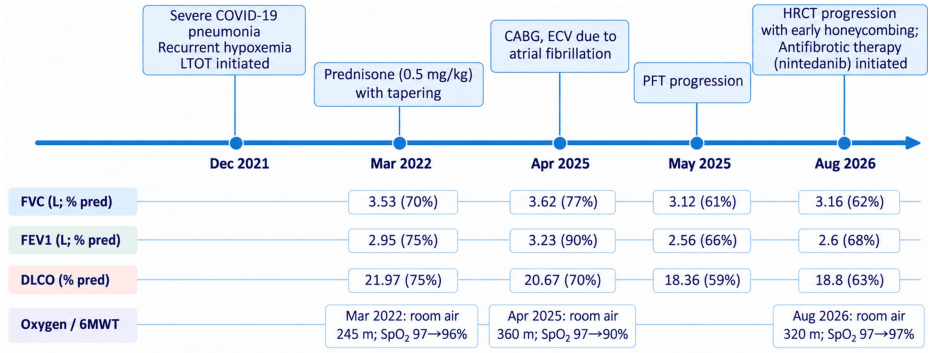

FIGURE 3: Clinical course of Case 2

Time course of disease progression from 2021 to 2026 with lung function and physiological testing.

CABG: coronary artery bypass grafting; DLCO: diffusing capacity of the lung for carbon monoxide; ECV: electrical cardioversion; FEV_1: forced expiratory volume in 1 second; FVC: forced vital capacity; HRCT: high-resolution computed tomography; LTOT: long-term oxygen therapy; PFT: pulmonary function test; SpO_2: peripheral oxygen saturation; 6MWT: Six-minute walk test.

Because of concomitant small-airway disease, inhaled corticosteroid/long-acting β2-agonist (ICS/LABA) therapy was initiated. In March 2022, the patient additionally received prednisone at a dose of 0.5 mg/kg/day for one month, followed by gradual tapering. A subsequent chest HRCT in May 2022 showed substantial regression of the GGO, with only mild residual post-inflammatory scarring.

After three years of disease stability, in April 2025, the patient underwent coronary artery bypass grafting (CABG) and synchronized electrical cardioversion for atrial fibrillation. Amiodarone was subsequently initiated for rhythm control. Following completion of cardiopulmonary rehabilitation, his cardiac function remained normal. However, there was a decline in lung function in May 2025. Amiodarone was stopped due to concerns for medication-induced ILD, but there was no evidence of radiological progression on repeat imaging. Initially, we considered amiodarone-induced pulmonary toxicity, chemotherapy-induced ILD, and radiation-induced lung injury for this patient, but because there was no temporal association between the exposures and ILD progression, these possibilities were excluded. The differential diagnosis for Case 2 is shown in Table *2*.

ILD etiology	Typical HRCT distribution	Characteristic radiological findings	Features that do not support this diagnosis
Amiodarone-induced pulmonary toxicity	Bilateral or asymmetric; often patchy peripheral or peribronchovascular involvement	GGO, consolidation, OP-like abnormalities, reticulation, septal thickening, and, occasionally, progressive fibrosis	Findings usually regress after amiodarone withdrawal
Chemotherapy-induced ILD	Variable, diffuse, or peripheral, depending on the drug	GGO, consolidation, OP, and occasionally, fibrotic remodeling	Disease distribution pattern is not typical for chemotherapy-induced ILD
Radiation-induced lung injury	Initially within the irradiated lung volume; may cross anatomical boundaries	Early GGO, consolidation; later sharply demarcated fibrosis, volume loss, traction bronchiectasis, and architectural distortion	Fibrotic abnormalities usually involve only the irradiated region, not bilateral, subpleural distribution

TABLE 2: Differential diagnosis of COVID-19 interstitial lung disease in Case 2

ILD: interstitial lung disease; GGO: ground-glass opacity; NSIP: nonspecific interstitial pneumonia; OP: organizing pneumonia.

Immunological laboratory investigations were also initiated to rule out a developing SARD-ILD, but immune serologies were within the normal range. By August 2026, chest CT demonstrated newly developed, early subpleural honeycombing in multiple lobes. In view of the newly developed fibrotic changes, lung biopsy was offered to further evaluate the etiology of lung fibrosis. The patient declined the biopsy and preferred initiation of treatment. Following shared decision-making, antifibrotic therapy with nintedanib was started in August 2026. The patient met criteria for PPF because of the decline in FVC and DLCO, and worsening pulmonary fibrosis with new honeycombing was noted on HRCT. Referral was made for lung transplant evaluation. Representative CT images are shown in Figure *4*.

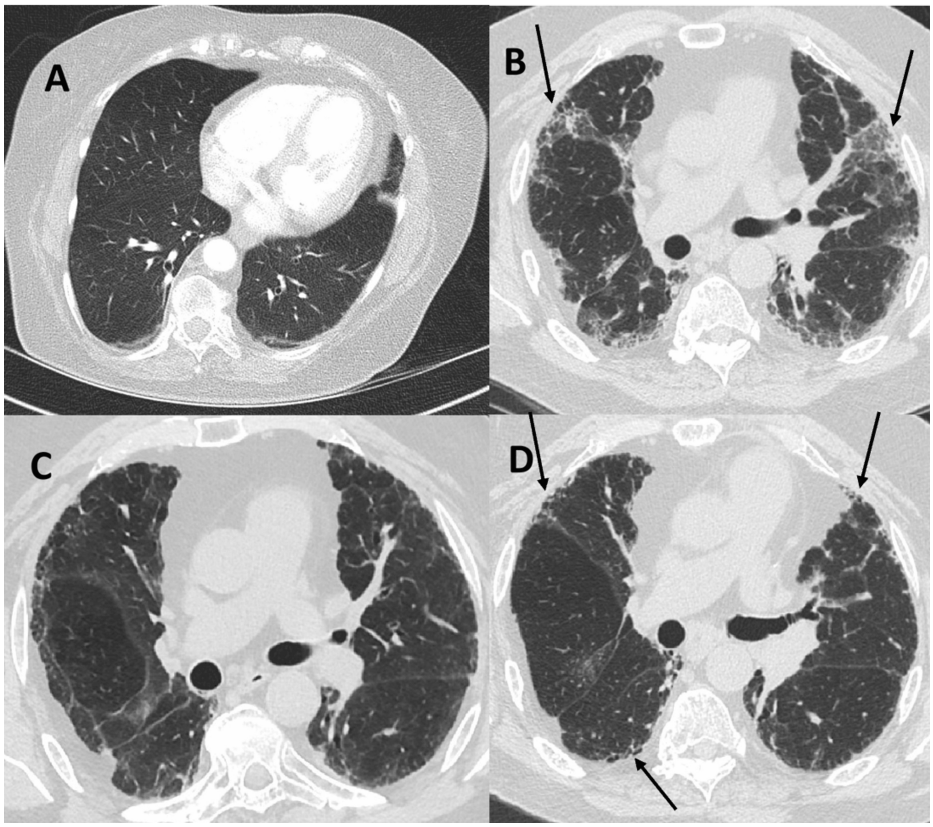

FIGURE 4: High-resolution computed tomography results of Case 2

A. No evidence of interstitial lung disease in 2007. B. Severe ground-glass opacities and subpleural reticulation after COVID-19 pneumonia in February 2022. C. Resolution of GGOs following corticosteroid therapy in May 2022. D. Early honeycombing in August 2026. Arrows point to representative areas.

Discussion

Post-COVID-19 ILD is currently a broad term that encompasses any interstitial abnormality following a COVID-19 infection. Based on the results of several population-based studies, the risk of developing ILD as a result of a COVID-19 infection increases by 3.6 to 11 times, although the accuracy of the data is based on diagnostic codes [4,5]. In the absence of additional test results (PFT, laboratory and histological findings), the accuracy of these data and the subtype of the resulting post-COVID-19 ILD cannot be determined. Currently, the most significant risk factor for fibrotic post-COVID-19 ILD is the severe disease course, especially the presence of acute respiratory distress syndrome (ARDS) [6], but age, male gender, and a history of smoking may contribute to the development of the disease [7].

During follow-up HRCT examinations, the presence of reticulations, traction bronchiectasis, and honeycombing may indicate the presence of fibrosis and, consequently, the development of ILD. While GGOs develop within a few weeks as a result of inflammatory processes and typically show regression over the course of months, fibrotic changes appear later and generally remain stagnant [8]. Respiratory symptoms and a decreased diffusion capacity are more likely to occur in conjunction with persistent pulmonary abnormalities [8].

The link between immunological diseases and post-COVID-19 conditions has been the focus of research for years. Based on the available data, COVID-19 infection may increase the risk of various autoimmune diseases [9,10]. However, the relationship between autoimmune diseases and post-COVID-19 ILD has yet to be fully elucidated. The reports on newly diagnosed cases of SARD-ILD following COVID-19 infection are purely observational. These case reports describe SARD-ILD following COVID-19 infection that was associated with rheumatoid arthritis, systemic sclerosis, myositis, or mixed connective tissue disease [11-14]. In the reviewed literature, lung biopsies were either not performed, or the biopsy did not contribute to the diagnosis, which makes it difficult to find an etiological relationship between COVID-19 infection and ILD.

The International Multisociety Consensus Statement, published in 2025, provides recommendations for managing post-COVID-19 CT abnormalities based on the available scientific data [15]. According to the consensus, a thin-slice HRCT scan is recommended 3-6 months after a moderate-to-severe COVID-19 infection, and the frequency of follow-up could be determined based on the clinical picture in accordance with the "as low as reasonably achievable" (ALARA) principle [15].

In a prospective cohort study, Hernandez-Argudo et al. found that persistent lung radiographic abnormalities on HRCT one year after COVID-19 pneumonia increased the risk of persistent lung fibrosis [16]. In their study, NSIP and OP were the most common imaging findings, but DAD, which is a presentation of ongoing ARDS, was also frequent. However, UIP, which is associated with PPF, was not common [16]. In contrast, Konopka et al. reported that nine of 18 lung biopsies performed 2-12 months post COVID-19 infection showed UIP pattern fibrosis [1]. The discrepancies between the radiographic and pathological findings are most likely the result of differences in the timing of sampling and also the distribution of ILD, which is not homogeneous in the lung. To overcome some of these diagnostic challenges, current guidelines do not recommend lung biopsy in patients with a typical UIP as it will not change the therapeutic approach [3]. In cases without a typical UIP on imaging, a lung biopsy can be useful, but its availability is often limited by the patient’s poor functional status. Table 3 shows the common pathological and imaging findings in post-COVID-19 ILD.

Pattern	Histology	Imaging appearance
DAD	Fibrotic phase: Replacement of normal alveolar architecture with thick, mature or organizing collagen fibers. Significant widening of the interstitium and alveolar septa	More diffuse or multifocal GGO and consolidation during acute injury; later reticulation, distortion, or traction-like change may resemble fibrotic interstitial lung disease.
OP	Fibrin and fibroblastic/myofibroblastic connective tissue plugs forming characteristic buds inside alveolar ducts and sacs (Masson bodies). The lung parenchyma remains intact.	Patchy peripheral or perilobular GGO and consolidation; sometimes reverse-halo appearance or parenchymal bands.
NSIP	Cellular NSIP: Dominated by a uniform, chronic interstitial inflammatory infiltrate (primarily lymphocytes and plasma cells) within the alveolar walls. Fibrotic NSIP: Dominated by uniform, collagen-rich interstitial fibrosis with varying degrees of residual chronic inflammation. Alveolar walls are thickened evenly throughout the affected region.	Bilateral, often lower-lung GGO and fine reticulation; possible traction bronchiectasis.
UIP	Classic dense subpleural/paraseptal fibrosis, patchy involvement, architectural distortion, fibroblast foci, and no alternative explanation	Basal, bilateral, and subpleural reticulation, architectural distortion, persistent traction bronchiectasis, and honeycombing.

TABLE 3: Common imaging and pathological findings in post-COVID-19 interstitial lung disease

Histological [1] and imaging [3] findings in post-COVID-19 interstitial lung disease.

DAD: diffuse alveolar damage; GGO: ground-glass opacity; OP: organizing pneumonia; NSIP: nonspecific interstitial pneumonia; UIP: usual interstitial pneumonia.

The treatment of PPF post-COVID-19 is also challenging. In the absence of clinical guidelines, the general approach follows the wisdom of non-COVID-19 ILD [17]. In primarily inflammatory disease, usually determined by more than 10% of GGO per lung surface on HRCT [3], we use immunosuppressive agents, including MMF, to prevent progression to fibrotic disease. In patients with primarily fibrotic disease with less than 10% of GGO on lung surface imaging, antifibrotic medication is preferred.

Antifibrotic medications have been studied in progressive post-COVID-19 lung fibrosis, including pirfenidone and nintedanib, but these did not show any significant improvement in outcomes [18,19]. However, these studies were criticized for their broad inclusion criteria. In the case of patients with progressive NSIP, the current guideline provides only conditional recommendations for treatment [18] because the initial radiological findings do not necessarily correspond with disease progression. Identifying subgroups that show potential for progression may help to pinpoint target populations in which antifibrotics can improve clinical outcomes.

While there are no guidelines on how to monitor patients with post-COVID-19 ILD, in our practice, we follow them similarly to those with non-COVID-19 ILD. PFT and 6MWT are performed every three to six months to monitor for stability, and a chest HRCT is recommended if lung function declines. We would like to emphasize that taking care of patients with ILD requires a multidisciplinary approach due to their multiple comorbidities. This usually includes primary care physicians, physical therapy, radiology, rheumatology, cardiology, and pulmonology. In cases with continued functional decline or a need for new home oxygen support despite medical therapy, early referral for lung transplant evaluation is recommended.

Conclusions

Post-COVID lung abnormalities mostly stabilize over time. However, in a small proportion of cases, progression and pulmonary fibrosis occur, accompanied by a decline in lung function and quality of life. Patients with progressive disease need close multidisciplinary monitoring. Our case series is limited by its purely descriptive nature, which does not allow broader interpretation. While we cannot draw long-term conclusions from our study, further investigations are needed to determine which subgroup of post-COVID-19 patients are at risk of progression and require early intervention.

Additional Information

Author Contributions

All authors have reviewed the final version to be published and agreed to be accountable for all aspects of the

work.

Concept and design: Tamas Dolinay, Peter L. Ven

Acquisition, analysis, or interpretation of data: Tamas Dolinay, Peter L. Ven

Drafting of the manuscript: Tamas Dolinay, Peter L. Ven

Critical review of the manuscript for important intellectual content: Tamas Dolinay, Peter L. Ven

Supervision: Tamas Dolinay

Disclosures

Human subjects: Informed consent for treatment and open access publication was obtained or waived by all participants in this study. **Conflicts of interest:** In compliance with the ICMJE uniform disclosure form, all authors declare the following: **Payment/services info:** All authors have declared that no financial support was received from any organization for the submitted work. **Financial relationships:** All authors have declared that they have no financial relationships at present or within the previous three years with any organizations that might have an interest in the submitted work. **Other relationships:** All authors have declared that there are no other relationships or activities that could appear to have influenced the submitted work.

References

1. Konopka KE, Perry W, Huang T, Farver CF, Myers JL: Usual interstitial pneumonia is the most common finding in surgical lung biopsies from patients with persistent interstitial lung disease following infection with SARS-CoV-2. EClinicalMedicine. 2021, 42:101209. 10.1016/j.eclinm.2021.101209
2. Ryerson CJ, Bankier A, Beasley MB, et al.: Standardized clinical terms and definitions for interstitial lung disease: A consensus statement from the Fleischner Society. Am J Respir Crit Care Med. 2025, 211:1756-74. 10.1164/rccm.202505-1142SO
3. Raghu G, Remy-Jardin M, Richeldi L, et al.: Idiopathic pulmonary fibrosis (an update) and progressive pulmonary fibrosis in adults: An official ATS/ERS/JRS/ALAT clinical practice guideline. Am J Respir Crit Care Med. 2022, 205:e18-47. 10.1164/rccm.202202-0399ST
4. Kim BG, Lee H, Jeong CY, et al.: Risk of newly diagnosed interstitial lung disease after COVID-19 and impact of vaccination: A nationwide population-based cohort study. Front Public Health. 2023, 11:1295457. 10.3389/fpubh.2023.1295457
5. Meng M, Wei R, Wu Y, et al.: Long-term risks of respiratory diseases in patients infected with SARS-CoV-2: A longitudinal, population-based cohort study. EClinicalMedicine. 2024, 69:102500. 10.1016/j.eclinm.2024.102500
6. Sturgill JL, Mayer KP, Kalema AG, et al.: Post-intensive care syndrome and pulmonary fibrosis in patients surviving ARDS-pneumonia of COVID-19 and non-COVID-19 etiologies. Sci Rep. 2023, 13:6554. 10.1038/s41598-023-32699-x
7. Shyam T, Atuaka C, Venigalla M, Sinokrot O: Scars from the pandemic: Understanding post-COVID-19 interstitial lung disease. Breathe (Sheff). 2025, 21:250037. 10.1183/20734735.0037-2025
8. Han X, Chen L, Guo L, et al.: Long-term radiological and pulmonary function abnormalities at 3 years after COVID-19 hospitalisation: A longitudinal cohort study. Eur Respir J. 2024, 64:2301612. 10.1183/13993003.01612-2023
9. Lim SH, Ju HJ, Han JH, Lee JH, Lee WS, Bae JM, Lee S: Autoimmune and autoinflammatory connective tissue disorders following COVID-19. JAMA Netw Open. 2023, 6:e2336120. 10.1001/jamanetworkopen.2023.36120
10. Gil AM, Barahona-Correa J, Flórez JB, Fernández-Ávila DG, Cucunubá ZM: Risk of new onset of immune-mediated diseases after SARS-CoV-2 infection: A systematic review and meta-analysis. Semin Arthritis Rheum. 2025, 74:152805. 10.1016/j.semarthrit.2025.152805
11. Oli P, Poudel P, Kc S, Kc A, Sah AK, Yadav P: Systemic sclerosis (positive anti-Ro 52 and anti-centromere antibodies) in a patient after COVID-19 infection: A rare case report. Ann Med Surg (Lond). 2024, 86:3663-6. 10.1097/MS9.0000000000002032
12. Moore J, Mahajan A, Gajjala S, Makkar P: A case of progressive dyspnea: Lymphocytic interstitial pneumonia in collagen vascular disease. Cureus. 2021, 13:e18427. 10.7759/cureus.18427
13. Chandra A, Kahaleh B: Systemic sclerosis (SSc) after COVID-19: A case report . Cureus. 2022, 14:e23179. 10.7759/cureus.23179
14. Bitrus R, Reichner CA: Post-COVID-19 development of myositis-associated interstitial lung disease . Chest. 2024, 166:A3180. 10.1016/j.chest.2024.06.1906
15. Yoon SH, Kanne JP, Ashizawa K, et al.: Best practice: International Multisociety consensus statement for post-COVID-19 residual abnormalities on chest CT scans. Radiology. 2025, 316:e243374. 10.1148/radiol.243374
16. Hernandez-Argudo M, Bordas-Martinez J, Vicens-Zygmunt V, et al.: A prospective cohort study for characterization and predictive factors of long-term POST-COVID interstitial changes. Respir Res. 2026, 27:219. 10.1186/s12931-026-03678-3
17. Johnson SR, Bernstein EJ, Bolster MB, et al.: 2023 American College of Rheumatology (ACR)/American College of Chest Physicians (CHEST) guideline for the treatment of interstitial lung disease in people with systemic autoimmune rheumatic diseases. Arthritis Care Res (Hoboken). 2024, 76:1051-69.

10.1002/acr.25348

18. Bermudo-Peloche G, Del Rio B, Vicens-Zygmunt V, et al.: Pirfenidone in post-COVID-19 pulmonary fibrosis (FIBRO-COVID): A phase 2 randomised clinical trial. Eur Respir J. 2025, 65:2402249. 10.1183/13993003.02249-2024

19. Mathai SK, Callahan SJ, Chang H, et al.: Nintedanib in post-COVID interstitial lung disease: A double-blind, randomized, placebo-controlled clinical trial. Ann Am Thorac Soc. 2026, aaoag159. 10.1093/annalsats/aaoag159