Cureus
Part of SPRINGER NATURE

Open Access Case Report

Malignant Bowel Obstruction Due to Delayed Recurrence of Endometrial Adenocarcinoma Mimicking Primary Colon Cancer: A Case Report

Patrícia Bárbara [1], Sónia Martins [2], Cristina Amado [3], Vitor Pardal [4], Miguel Coelho dos Santos [1]

1. General Surgery, Unidade Local de Saúde da Região de Leiria, Leiria, PRT 2. General and Colorectal Surgery, Unidade Local de Saúde da Região de Leiria, Leiria, PRT 3. Pathology, Unidade Local de Saúde da Região de Leiria, Leiria, PRT 4. Radiology, Unidade Local de Saúde da Região de Leiria, Leiria, PRT

Corresponding author: Patrícia Bárbara, patriciabarbara2021@gmail.com

Review began 11/11/2026
Review ended 11/20/2026
Published 11/22/2026

© **Copyright** 2026
Bárbara et al. This is an open access article distributed under the terms of the Creative Commons Attribution License CC-BY 4.0., which permits unrestricted use, distribution, and reproduction in any medium, provided the original author and source are credited.

DOI: 10.7759/cureus.120110

Abstract

Endometrial adenocarcinoma is the most common gynecologic malignancy, with recurrences typically occurring within the first three years following initial surgical treatment. A delayed recurrence presenting over a decade later as an acute malignant large bowel obstruction is exceptionally rare and clinically mimics primary colorectal cancer, often leading to initial diagnostic challenges.

A 65-year-old female presented to the emergency department with an 8-day history of severe bowel obstruction. Computed tomography of the abdomen revealed a constricting circumferential mass in the sigmoid colon causing massive upstream bowel dilation, with the cecum measuring up to 100 mm in diameter, and an apparently competent ileocecal valve. The patient underwent an emergent total colectomy with ileorectal anastomosis and a protective ileostomy. Surprisingly, histopathological and immunohistochemical analyses of the colonic tumor and resected lymph nodes did not show primary colonic neoplasia. Instead, the tissue was strongly positive for estrogen receptors (80%), confirming metastatic, well-differentiated endometrioid adenocarcinoma. This finding was traced back to early-stage (FIGO 2009 stage IB, grade 1, pN0) endometrial cancer treated with a total abdominal hysterectomy, bilateral salpingo-oophorectomy, and lymphadenectomy 20 years prior. Further molecular profiling revealed a loss of MSH2 and MSH6 nuclear expression, establishing a deficient mismatch repair (dMMR) status, which is highly suggestive of Lynch syndrome. Given the recurrent metastatic disease and the dMMR profile, and following multidisciplinary tumor board discussion, the patient was started on first-line chemoimmunotherapy with carboplatin, paclitaxel, and dostarlimab.

This case highlights the importance of considering metastatic disease in patients with a remote history of endometrial cancer, even when presenting with typical signs of a primary colorectal tumor, and the key role of multidisciplinary discussion in reaching the correct diagnosis. Moreover, it reinforces the value of accurate molecular profiling to identify dMMR status, ensuring patients can benefit from appropriate and highly effective immune checkpoint inhibitors and are referred for genetic counseling.

Categories: Obstetrics/Gynecology, General Surgery, Oncology
Keywords: delayed recurrence, dmmr, dostarlimab, endometrial adenocarcinoma, lynch syndrome, malignant bowel obstruction

Introduction

Endometrial adenocarcinoma is the most prevalent gynecologic malignancy, associated with excellent long-term survival rates following standard definitive surgical management for early-stage disease [1]. When disease recurrence does occur, it overwhelmingly develops within the first three years post-treatment, most frequently localizing to the vaginal vault, pelvis, or lungs [2].

Delayed recurrences, defined as relapses occurring more than a decade after initial curative therapy, are highly atypical [3,4]. Even more exceptional is an isolated distant metastasis presenting in the large intestine [3,5]. While the gastrointestinal tract can be secondarily involved through diffuse peritoneal carcinomatosis or direct local invasion, isolated intraluminal metastasis to the colon after a prolonged disease-free interval is an exceedingly rare phenomenon [1,2].

Endometrial cancer may reach the colon through several routes: direct pelvic extension, transcoelomic (peritoneal) spread, and lymphatic or hematogenous dissemination. The latter two can produce deposits that infiltrate the bowel wall from the serosa or submucosa toward the mucosa, without peritoneal carcinomatosis [2,5].

Clinically, these delayed colonic metastases frequently manifest as acute malignant bowel obstruction, perfectly masquerading as primary colorectal carcinomas [3,5,6]. Patients typically present with classic

obstructive symptoms, and subsequent radiological or endoscopic evaluations usually reveal a constricting, circumferential mass, making early diagnosis notoriously difficult [3,4]. Furthermore, clinicians and pathologists must differentiate these metastatic lesions from other uncommon localized pathologies, such as the malignant transformation of extra-gonadal or colonic endometriosis, which can present with an identical obstructive phenotype [7,8].

Accurate differentiation relies entirely on a high index of clinical suspicion combined with rigorous histopathological review and immunohistochemical staining, such as strong positivity for estrogen receptors, to establish the true origin of the tumor [1,4,6]. Performing subsequent molecular profiling to determine mismatch repair (MMR) status profoundly alters the therapeutic trajectory, allowing patients to bypass standard colorectal chemotherapy regimens in favor of immunotherapy [3,5]. MMR proteins (MLH1, PMS2, MSH2, and MSH6) correct DNA replication errors. Loss of their expression defines a deficient MMR (dMMR) phenotype, which is present in approximately 25-30% of endometrial carcinomas and predicts a high response to immune checkpoint inhibitors, monoclonal antibodies that restore antitumor T-cell activity by blocking the PD-1/PD-L1 pathway [9].

Similar to a limited number of documented cases in the literature, this report highlights the importance of considering metastatic disease in patients with a remote history of gynecological malignancy [2,5].

Case Presentation

A 65-year-old female presented to the emergency department with an 8-day history of severe constipation and vomiting of ingested food. Outpatient laxative and prokinetic therapy had proven ineffective. On admission, she was alert and oriented, hemodynamically stable (blood pressure 146/87 mmHg, heart rate 100 bpm), and eupneic on room air. The abdomen was markedly distended and tympanic, with diffuse tenderness on palpation but no guarding or signs of peritoneal irritation. A lower midline laparotomy scar was noted. Her past medical history was notable for an early-stage, well-differentiated endometrioid adenocarcinoma (FIGO 2009 stage IB [10], grade 1, pN0; originally staged as IC according to the FIGO 1988 classification [11] in use at the time) diagnosed 20 years earlier. She was treated at that time with a total abdominal hysterectomy, bilateral salpingo-oophorectomy, and extensive pelvic lymphadenectomy. A total colonoscopy performed approximately two years earlier (November 2023), with adequate bowel preparation, had revealed only uncomplicated sigmoid diverticulosis.

Initial laboratory investigations (Table *1*) demonstrated mild leukocytosis, mild hypokalemia, hyponatremia, and hypochloremia, consistent with vomiting and dehydration, with normal C-reactive protein and lactate. D-dimer was marginally elevated, a nonspecific finding in the setting of malignancy and acute illness. The elevated creatine kinase was considered most likely related to hypokalemia, dehydration, and ischemic changes of the distended colonic wall, which were later confirmed histologically. None of these findings altered management. Contrast-enhanced computed tomography of the abdomen and pelvis demonstrated a 48-mm circumferential parietal thickening in the sigmoid colon (Figure *1*). This lesion caused severe luminal narrowing and massive upstream bowel dilation, with the cecum significantly distended up to 100 mm in diameter behind an apparently competent ileocecal valve. The imaging also revealed irregular external tumor contours, pericolic fat stranding suggestive of invasion beyond the muscularis propria, and suspicious regional lymphadenopathy. An emergent flexible sigmoidoscopy encountered an impassable, ulcerated, and congestive stricture 20 cm from the anal verge. The stricture presented an eccentric morphology with no visible lumen, preventing any further proximal evaluation or decompression.

Parameter	Patient value	Reference range
Laboratory findings on admission		
WBC count	10.1 × 10^3/μL	4.0–10.0 × 10^3/μL
Neutrophils	7.9 × 10^3/μL (78.3%)	1.8–8.0 × 10^3/μL
Lymphocytes	1.5 × 10^3/μL (14.8%)	1.5–6.5 × 10^3/μL
Hemoglobin	14.3 g/dL	11.5–16.0 g/dL
Platelet count	230 × 10^3/μL	150–500 × 10^3/μL
PT	13.3 s	9.4–12.5 s
INR	1.12	0.80–1.20
aPTT	29.7 s	25.4–38.2 s
D-dimer	531 ng/mL	<500 ng/mL
Urea	4.5 mmol/L	2.8–7.2 mmol/L
Creatinine	73 μmol/L	45–84 μmol/L
eGFR (CKD-EPI)	79 mL/min/1.73 m^2	≥90 mL/min/1.73 m^2
Sodium	134 mmol/L	136–146 mmol/L
Potassium	3.0 mmol/L	3.5–5.1 mmol/L
Chloride	95 mmol/L	101–109 mmol/L
Total bilirubin	10.4 μmol/L	5.0–21.0 μmol/L
ALT	29 U/L	3–34 U/L
AST	32 U/L	15–35 U/L
CK	487 U/L	10–145 U/L
CRP	3.0 mg/L	≤5.0 mg/L
Lactate	1.8 mmol/L	0.5–2.2 mmol/L
Postoperative tumor markers		
CEA	2.1 ng/mL	<3.0 ng/mL
CA-125	11.1 U/mL	<35.0 U/mL

TABLE 1: Laboratory findings on admission and postoperative tumor markers

WBC: white blood cell; PT: prothrombin time; INR: international normalized ratio; aPTT: activated partial thromboplastin time; eGFR: estimated glomerular filtration rate; CKD-EPI: Chronic Kidney Disease Epidemiology Collaboration equation; ALT: alanine aminotransferase; AST: aspartate aminotransferase; CK: creatine kinase; CRP: C-reactive protein; CEA: carcinoembryonic antigen; CA-125: cancer antigen 125

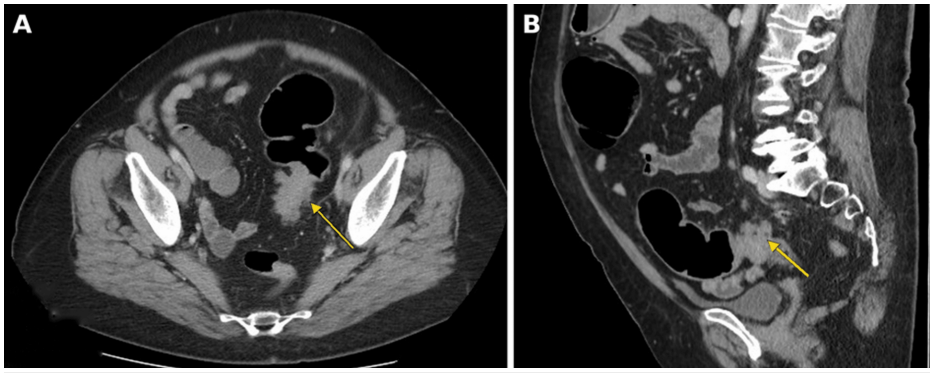

FIGURE 1: Contrast-enhanced computed tomography of the abdomen and pelvis: axial (A) and sagittal (B) images

The arrows indicate the circumferential parietal thickening of the sigmoid colon causing severe luminal narrowing, with marked upstream dilation of the large bowel.

The patient subsequently underwent an urgent total colectomy with ileorectal anastomosis and a protective ileostomy, followed by an uneventful postoperative recovery. Postoperative serum tumor markers, including carcinoembryonic antigen and CA-125, were within normal limits (Table *1*); preoperative values were not obtained due to the emergency setting. Histopathological examination of the surgical specimen revealed a well-differentiated adenocarcinoma that lacked the morphological hallmarks typical of primary colorectal carcinoma (Figure *2*). The tumor measured approximately 3.5 cm. The tumor showed no continuity with the overlying colonic mucosa, and there was a complete absence of adenomatous transformation or dysplastic changes. The mucosa proximal to the tumor exhibited ischemic changes, while the appendix showed only reactive lymphoid hyperplasia. Analysis of the resected lymph nodes confirmed metastatic disease in 6 of 30 regional lymph nodes.

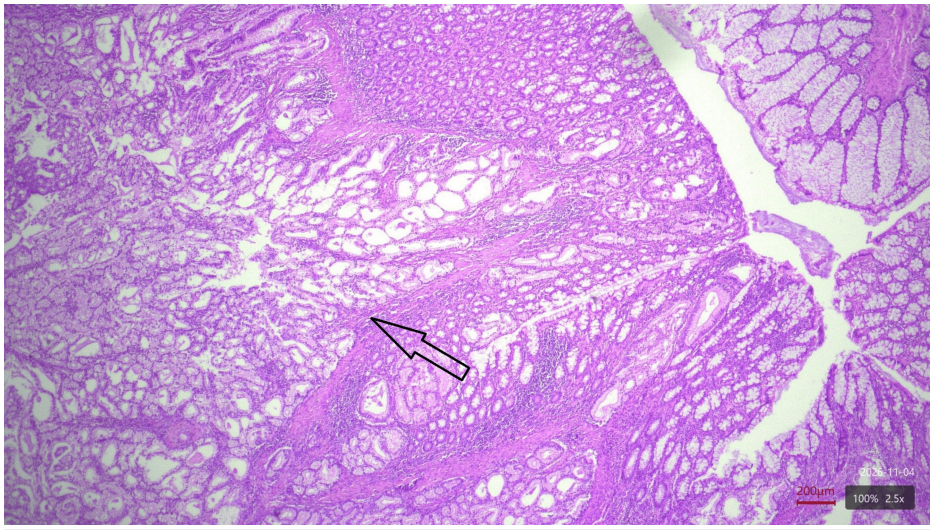

FIGURE 2: Histopathological examination of the resected colon (hematoxylin and eosin, original magnification ×2.5)

The arrow indicates infiltration of the colonic wall by well-differentiated endometrioid adenocarcinoma, contrasting with the adjacent normal colonic mucosa.

Given the patient's prior oncological history and the atypical histological features, the case was discussed with the Pathology department, and targeted immunohistochemical staining was performed. The tumor tissue demonstrated diffuse, strong nuclear positivity for estrogen receptors in approximately 80% of tumor cells (Figure *3*) and negativity for HER2, confirming a delayed colonic and nodal metastasis of her prior endometrioid adenocarcinoma. Mismatch repair protein status, assessed by immunohistochemistry, revealed loss of MSH2 and MSH6 nuclear expression with retained MLH1 and PMS2 expression and intact internal controls, establishing a deficient mismatch repair (dMMR) status. Because this pattern carries a high probability of Lynch syndrome, referral for genetic counseling and germline testing of MSH2 (and, if

negative, MSH6) was recommended; germline testing has not yet been performed.

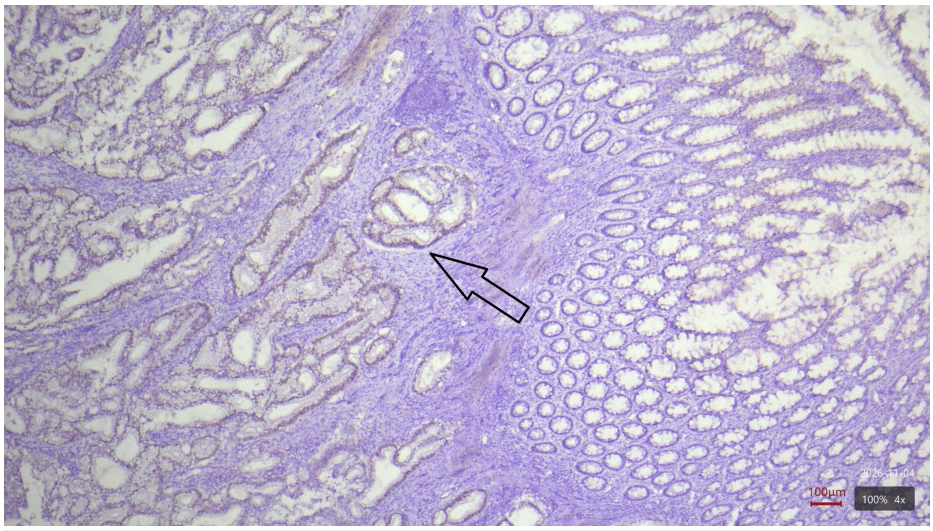

FIGURE 3: Immunohistochemical staining for estrogen receptors (original magnification ×4)

The arrow indicates nuclear positivity for estrogen receptors in the tumor glands, whereas the adjacent normal colonic crypts are negative.

Postoperative staging thoracic CT showed no distant metastases. A subsequent 18F-FDG PET/CT revealed a hypermetabolic right para-aortic lymph node (SUVmax 17.0), an indeterminate left para-aortic nodule, and nonspecific, mildly avid mediastinal-hilar lymph nodes. The disease was therefore classified as low-burden stage IV recurrence. The case was subsequently discussed at a multidisciplinary tumor board, and, based on the diagnosis of recurrent metastatic endometrial cancer with a dMMR profile, the patient was started on first-line treatment with carboplatin, paclitaxel, and dostarlimab for six cycles, to be followed by dostarlimab maintenance [9].

Discussion

Endometrial cancer recurrences typically occur within the first three years following definitive surgical management. A delayed recurrence, particularly one presenting as an isolated metastasis to the large bowel over a decade later, is an exceedingly rare occurrence [1,2]. When gastrointestinal involvement does occur, it is generally via direct local extension or diffuse peritoneal carcinomatosis rather than an isolated intraluminal metastasis mimicking a primary tumor [3,5].

Delayed colonic metastases frequently manifest as acute malignant bowel obstructions, clinically and radiologically indistinguishable from primary colorectal carcinomas [4,6]. The constricting, circumferential nature of these lesions often misleads initial diagnostic efforts [4]. In the present case, a complete colonoscopy with adequate bowel preparation performed approximately two years before presentation showed only diverticulosis, consistent with the extraluminal-to-intraluminal progression typical of metastatic deposits. These lesions characteristically infiltrate the bowel wall from the serosa or lymphatics, progressing rapidly before eventually ulcerating the mucosa [2,5]. In our patient, the colonic metastasis was accompanied by low-burden retroperitoneal nodal disease, without peritoneal carcinomatosis.

Definitive diagnosis relies on detailed histopathological and immunohistochemical profiling. Pathologists must differentiate these lesions not only from primary colon adenocarcinomas but also from the rare malignant transformation of deep-infiltrating colonic or extra-gonadal endometriosis, which can present with identical obstructive phenotypes and glandular crowding [7,8]. The absence of an adenomatous precursor lesion, the lack of continuity with the surrounding normal mucosa, and strong, diffuse positivity for estrogen receptors (ER) are definitive hallmarks that confirm a gynecological origin rather than a gastrointestinal one [1,3,6]. In this context, close communication between surgeons and pathologists is essential. In the present case, awareness of the patient's remote oncological history, together with direct multidisciplinary discussion with the Pathology team and subsequently at the tumor board, was decisive in guiding the immunohistochemical study and reaching the correct diagnosis.

Misidentifying a metastatic lesion as a primary colonic tumor can lead to inappropriate systemic treatments such as standard colorectal cytotoxic chemotherapy regimens [3,5]. Establishing the correct primary origin is therefore critical to prompt essential molecular profiling, specifically mismatch repair

(MMR) testing [12]. In patients with a deficient MMR (dMMR) status, the therapeutic paradigm shifts radically, as recognizing the tumor as a dMMR endometrial recurrence enables the deployment of immune checkpoint inhibitors like dostarlimab [5,9]. Ultimately, it allows the addition of dostarlimab to carboplatin-paclitaxel, which significantly improves progression-free and overall survival in this population, instead of colorectal-directed regimens [9].

Notably, isolated loss of MSH2/MSH6 expression is rarely caused by somatic epigenetic silencing, unlike MLH1/PMS2 loss, which is frequently due to MLH1 promoter hypermethylation. MSH2/MSH6 loss is therefore strongly suggestive of Lynch syndrome, and current guidelines recommend referral for genetic counseling and germline testing in all such patients [12]. Confirmation of Lynch syndrome has important implications: it increases the lifetime risk of a primary colorectal carcinoma, which further complicates the differential diagnosis in this setting; it mandates endoscopic surveillance of the remaining rectum after ileorectal anastomosis; and it allows cascade testing of first-degree relatives.

Conclusions

This case highlights the importance of considering metastatic disease in patients presenting with acute malignant bowel obstruction, even decades after the successful treatment of an early-stage gynecological malignancy. Differentiating a delayed colonic metastasis from a primary colorectal carcinoma requires a high index of clinical suspicion, a careful review of the patient's oncological history, and close multidisciplinary collaboration, particularly with pathology and the tumor board, supported by meticulous histopathological and immunohistochemical evaluation. Accurately identifying the true origin of the tumor is essential, as it prevents the administration of inappropriate colorectal chemotherapy regimens. Furthermore, this definitive diagnosis facilitates essential molecular profiling, ensuring that patients with deficient mismatch repair profiles can promptly access highly effective immunotherapy. Finally, loss of MSH2/MSH6 expression should prompt genetic counseling and germline testing for Lynch syndrome.

Additional Information

Author Contributions

All authors have reviewed the final version to be published and agreed to be accountable for all aspects of the work.

Concept and design: Patrícia Bárbara, Sónia Martins, Miguel Coelho dos Santos, Vitor Pardal, Cristina Amado

Acquisition, analysis, or interpretation of data: Patrícia Bárbara, Sónia Martins, Miguel Coelho dos Santos, Vitor Pardal, Cristina Amado

Drafting of the manuscript: Patrícia Bárbara

Critical review of the manuscript for important intellectual content: Patrícia Bárbara, Sónia Martins, Miguel Coelho dos Santos, Vitor Pardal, Cristina Amado

Supervision: Sónia Martins, Miguel Coelho dos Santos, Vitor Pardal, Cristina Amado

Disclosures

Human subjects: Informed consent for treatment and open access publication was obtained or waived by all participants in this study. **Conflicts of interest:** In compliance with the ICMJE uniform disclosure form, all authors declare the following: **Payment/services info:** All authors have declared that no financial support was received from any organization for the submitted work. **Financial relationships:** All authors have declared that they have no financial relationships at present or within the previous three years with any organizations that might have an interest in the submitted work. **Other relationships:** All authors have declared that there are no other relationships or activities that could appear to have influenced the submitted work.

References

1. Matías-García B, Mendoza-Moreno F, Díez-Alonso M, D'Angelo C, Gutiérrez-Calvo A: Malignant bowel obstruction due to intraluminal metastasis of endometrial adenocarcinoma located in the sigmoid colon after nine years of follow-up. Cureus. 2023, 15:e47937. 10.7759/cureus.47937
2. Yokoyama K, Miura T, Morohashi H, et al.: Sigmoid colon metastasis from endometrioid carcinoma after a long disease-free interval following radiotherapy for vaginal recurrence: a case report and review of the literature. Surg Case Rep. 2026, 12:cr.26-0134. 10.70352/scrj.cr.26-0134
3. Jauregui A, Gajendran M, Loganathan P, Padilla A, Qiao J, Elhanafi S: Rare distal metastasis of endometrial adenocarcinoma impersonating as primary colon cancer. J Investig Med High Impact Case Rep. 2021, 9:23247096211039943. 10.1177/23247096211039943
4. Foong HY, Blundell J, Law C, Warner R: Delayed metastatic endometrial carcinoma mimicking primary colon

adenocarcinoma: a surprise histopathological finding. Clin Case Rep. 2024, 12:e8925. 10.1002/ccr3.8925
5. Hamada Y, Yukimoto H, Ikenoyama Y, et al.: Small bowel metastasis from endometrial cancer presenting as a bowel obstruction: a case report with literature review. DEN Open. 2025, 5:e70117. 10.1002/deo2.70117
6. Shimura T, Fukushima N, Tsuboi K, Suzuki T, Kajimoto T: Serous endometrial carcinoma metastatic to the sigmoid colon masquerading as a primary colon cancer detected by bowel obstruction. Surg Case Rep. 2024, 10:273. 10.1186/s40792-024-02073-8
7. Fejes R, Balajthy Z, Góg C, Vajda Á, Hegedűs F, Simonka Z, Ábrahám S: Colonic endometriosis: from subtotal bowel obstruction to malignant transformation - a case series and literature review. World J Surg Oncol. 2025, 23:230. 10.1186/s12957-025-03888-x
8. Stoklosa A, Armbuster Y, Marshall L, et al.: Endometrioid adenocarcinoma of the colon arising from rare malignant transformation of extra-gonadal endometrioma. Gynecol Oncol Rep. 2025, 57:101664. 10.1016/j.gore.2024.101664
9. Mirza MR, Chase DM, Slomovitz BM, et al.: Dostarlimab for primary advanced or recurrent endometrial cancer. N Engl J Med. 2023, 388:2145-58. 10.1056/NEJMoa2216334
10. Pecorelli S: Revised FIGO staging for carcinoma of the vulva, cervix, and endometrium . Int J Gynaecol Obstet. 2009, 105:103-4. 10.1016/j.ijgo.2009.02.012
11. Creasman WT: Announcement, FIGO stages: 1988 revision. Gynecol Oncol. 1989, 35:125-7. 10.1016/0090-8258(89)90027-9
12. Concin N, Matias-Guiu X, Vergote I, et al.: ESGO/ESTRO/ESP guidelines for the management of patients with endometrial carcinoma. Int J Gynecol Cancer. 2021, 31:12-39. 10.1136/ijgc-2020-002230