Cureus
Part of SPRINGER NATURE

Open Access Case Report

Triple Disruption of the Superior Shoulder Suspensory Complex With Acromion Fracture and Early Loss of Acromial Fixation After a Second Fall Managed Without Revision: A Case Report

Rui Nobre Chaves [1, 2], Sara Neves [1], Sofia Neto [1], António Gomes Cruz [1], António Lemos-Lopes [1]

1. Orthopedics and Traumatology, Unidade Local de Saúde de Trás-os-Montes e Alto Douro, Vila Real, PRT 2. School of Medicine, University of Minho, Braga, PRT

Corresponding author: Rui Nobre Chaves, ranchaves@chtmad.min-saude.pt

Review began 10/27/2026
Review ended 11/20/2026
Published 11/26/2026

© Copyright 2026
Nobre Chaves et al. This is an open access article distributed under the terms of the Creative Commons Attribution License CC-BY 4.0., which permits unrestricted use, distribution, and reproduction in any medium, provided the original author and source are credited.

DOI: 10.7759/cureus.120280

Abstract

Triple disruptions of the superior shoulder suspensory complex (SSSC) are rare and are usually treated operatively. How to manage early postoperative loss of fixation is not well defined, particularly in patients at high risk of recurrent falls. We report the case of a 63-year-old right-hand-dominant man with Parkinson's disease who fell onto his right shoulder and sustained a displaced Kuhn type III acromion fracture (12 mm of inferior displacement; acromiohumeral distance 5.5 mm) with a Rockwood type III acromioclavicular (AC) dislocation (coracoclavicular distance 19.9 mm vs. 10.2 mm on the contralateral side). The acromion was fixed with three 4.0-mm cannulated screws, and the coracoclavicular and AC relationships were stabilized with non-absorbable sutures. On postoperative day 2, an in-hospital fall caused partial loss of acromial fixation: the screws backed out by about 4 mm and fragment displacement increased from 2 to 9 mm, while the coracoclavicular distance changed from 11.4 to 13.0 mm and the acromiohumeral distance changed from 9.0 to 8.0 mm. Because the subacromial space was preserved, the loss of coracoclavicular reduction was limited and the risk of further falls was high, revision surgery was not performed. At 29 months, the fracture had united with 8 mm of residual displacement, the radiographic measurements showed no clinically relevant progression, and the patient was pain-free with a Constant-Murley score of 90 (contralateral 96), an American Shoulder and Elbow Surgeons (ASES) score of 93.3, and a QuickDASH score of 9.1. In this patient, early loss of acromial reduction was compatible with a good functional result without revision. Whether the retained coracoclavicular stabilization contributed to this outcome remains a hypothesis.

Categories: Trauma, Orthopedics
Keywords: acromioclavicular dislocation, acromion fracture, fixation failure, parkinson's disease, scapular fracture, shoulder girdle, superior shoulder suspensory complex

Introduction

The superior shoulder suspensory complex (SSSC) is a ring-like osseoligamentous structure that suspends the upper limb from the axial skeleton. It comprises the glenoid process, coracoid process, coracoclavicular ligaments, distal clavicle, acromioclavicular (AC) joint, and acromion, held between a superior strut (the clavicle) and an inferior strut (the lateral scapular body and spine) [1]. Goss proposed that a single break in this ring is usually stable, whereas breaks at two or more sites may allow the fragments to displace, with potential consequences for shoulder-girdle alignment, fracture healing, and function [1,2]. This concept has been challenged: a clinical series of double disruptions reported good results with non-operative treatment, and biomechanical work suggests that instability requires additional ligamentous injury [3,4].

Triple and quadruple disruptions of the SSSC are uncommon and are described mainly in case reports and small series [5-10]. Acromion fractures are themselves rare. Kuhn et al. classified them as type I (minimally displaced), type II (displaced without reduction of the subacromial space), and type III (displaced with reduction of the subacromial space); type III fractures are generally considered for surgery because of the risk of impingement, nonunion, and loss of the deltoid lever arm [11-15]. AC dislocations are graded according to the Rockwood classification, in which type III corresponds to an increase in the coracoclavicular distance of 25-100% relative to the uninjured side. When an acromion fracture is associated with AC dislocation and coracoclavicular ligament injury, treatment must address both the fracture and the suspensory link.

Most published triple disruptions describe anatomical fixation of each injured component followed by an uneventful course [6-10]. There is little guidance on what to do when part of such a construct fails early, particularly in patients whose comorbidities make both recurrent falls and failure of a revision construct likely. We report a triple SSSC disruption in a patient with Parkinson's disease in whom acromial fixation was partly lost after an in-hospital fall on the second postoperative day, and we describe the clinical and radiographic course over 29 months without revision surgery.

How to cite this article
Nobre Chaves R, Neves S, Neto S, et al. (November 26, 2026) Triple Disruption of the Superior Shoulder Suspensory Complex With Acromion Fracture and Early Loss of Acromial Fixation After a Second Fall Managed Without Revision: A Case Report. Cureus 18(11): e120280. DOI 10.7759/cureus.120280

Case Presentation

A 63-year-old right-hand-dominant retired bricklayer fell onto his right shoulder at home, from standing height, while turning; there was no loss of consciousness or head injury. He had previously been independent in activities of daily living, with no history of shoulder pain, trauma, or surgery. Parkinson's disease had been diagnosed eight years earlier; it was treated with levodopa and a deep brain stimulator implanted two years before the injury. He reported freezing of gait and two falls in the preceding year, corresponding to Hoehn and Yahr stage III; a Mini-Mental State Examination performed at that time scored 28/30. Other comorbidities were arterial hypertension and hyperuricemia; he had no diabetes and did not smoke. Bone densitometry performed during follow-up (18 March 2025) showed osteopenia (femoral neck T-score of −1.6); osteoporosis had not been diagnosed previously.

On examination, he reported pain of 8/10 and had deformity and swelling over the acromion and the AC joint. Active motion was markedly limited by pain and was not quantified; strength testing was deferred. Distal sensation, motor function, and pulses were normal, and the skin was intact.

Plain radiographs and computed tomography (CT) showed a displaced acromion fracture with AC dislocation (Figures *1*, *2*). The acromial fragment was displaced inferiorly by 12 mm and the acromiohumeral distance was 5.5 mm, consistent with a Kuhn type III fracture. On bilateral Zanca views, the coracoclavicular distance was 19.9 mm on the right and 10.2 mm on the left, a 95% increase, corresponding to a Rockwood type III AC dislocation with coracoclavicular ligament injury. The injury was therefore interpreted as a triple disruption of the SSSC involving the acromion, AC joint, and coracoclavicular ligaments.

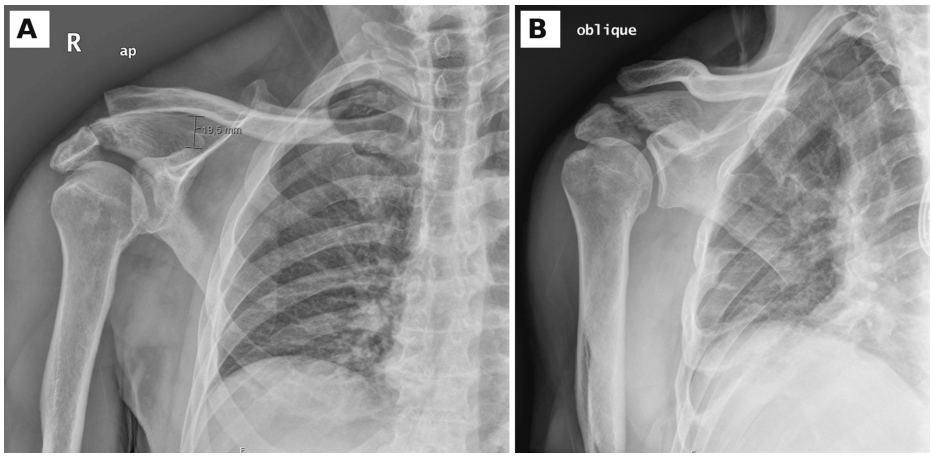

FIGURE 1: Initial radiographs of the right shoulder

(A) Anteroposterior and (B) oblique views showing a displaced acromion fracture (Kuhn type III) associated with acromioclavicular dislocation.

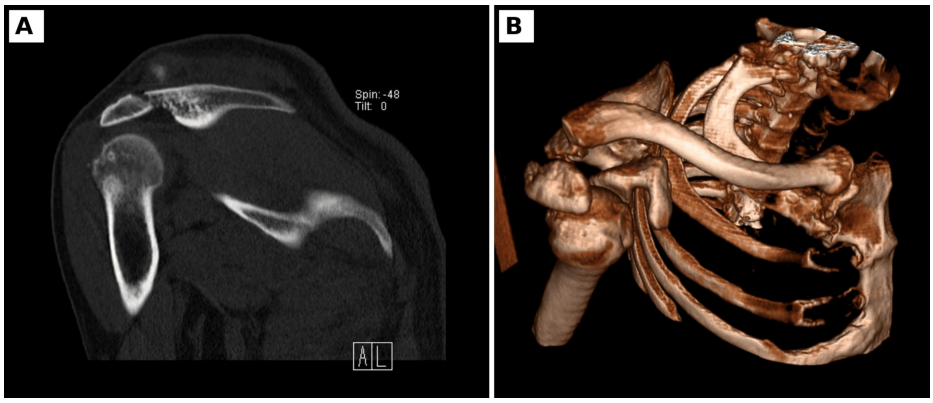

FIGURE 2: Preoperative computed tomography

(A) Coronal reformat and (B) three-dimensional reconstruction showing the displaced acromion fracture and acromioclavicular dislocation.

Surgical treatment was chosen to restore the subacromial space, preserve the deltoid lever arm, and re-establish the suspensory link. Surgery was performed three days after the injury through an open posterior approach centered on the acromion, preserving the deltoid insertion. The fracture was reduced and fixed with three 4.0-mm cannulated screws (32, 34, and 36 mm), each with a washer (Figure *3*). No implant crossed the AC joint. The coracoclavicular relationship was stabilized with two high-strength non-absorbable sutures passed under the base of the coracoid process and through two drill tunnels in the distal clavicle, with the knots tied over the superior aspect of the clavicle. The AC joint was also reinforced with a figure-of-eight suture. Disruption of the coracoclavicular ligaments was confirmed by direct intraoperative visualization. Routine implant removal was not planned. Postoperative bilateral Zanca views showed a coracoclavicular distance of 11.4 mm, an acromiohumeral distance of 9.0 mm, and about 2 mm of residual displacement of the acromial fragment (Figure *4*, Table *1*).

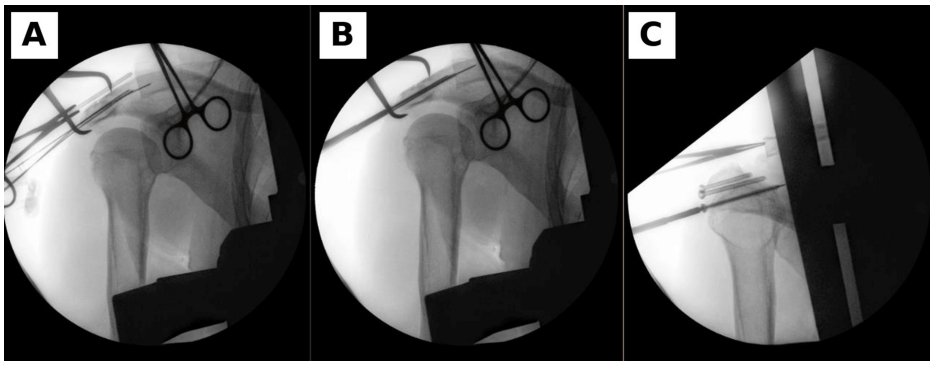

FIGURE 3: Intraoperative fluoroscopy

(A-C) Fluoroscopic views showing reduction of the acromion fracture and placement of the cannulated screws for acromial fixation.



FIGURE 4: Immediate postoperative radiograph

Anteroposterior view showing restoration of the acromial contour and of the acromioclavicular relationship.

Time point	Coracoclavicular distance, right (mm)	Increase over left side (10.2 mm)	Acromial fragment displacement (mm)	Acromiohumeral distance, right (mm)
Injury	19.9	95%	12	5.5
After surgery	11.4	12%	2	9
After second fall	13	27%	9	8
3 months	13.1	28%	8	8.1
29 months	13.2	29%	8	8.2

TABLE 1: Radiographic measurements at each time point

Coracoclavicular distance was measured on bilateral Zanca views. The contralateral acromiohumeral distance at 29 months was 9.0 mm.

On the second postoperative day, while still an inpatient, the patient fell when he tried to walk to the bathroom unassisted during an episode of psychomotor agitation; the fall was reported as a patient-safety incident. There was no head injury or other associated injury. After the fall, a bed alarm and assisted transfers were instituted; the medication chart confirmed that antiparkinsonian medication had been administered at the scheduled times, with no missed doses, and the mobilization plan was reviewed. Radiographs showed partial loss of acromial fixation: the screws had backed out by about 4 mm, and the fragment had displaced laterally and inferiorly to about 9 mm (Figure 5). The screws were intact and did not enter the subacromial space, but the acromial screw tip now projected beyond the lateral cortical margin, and there was mild widening of the AC joint. The coracoclavicular distance was 13.0 mm, and the acromiohumeral distance was 8.0 mm.

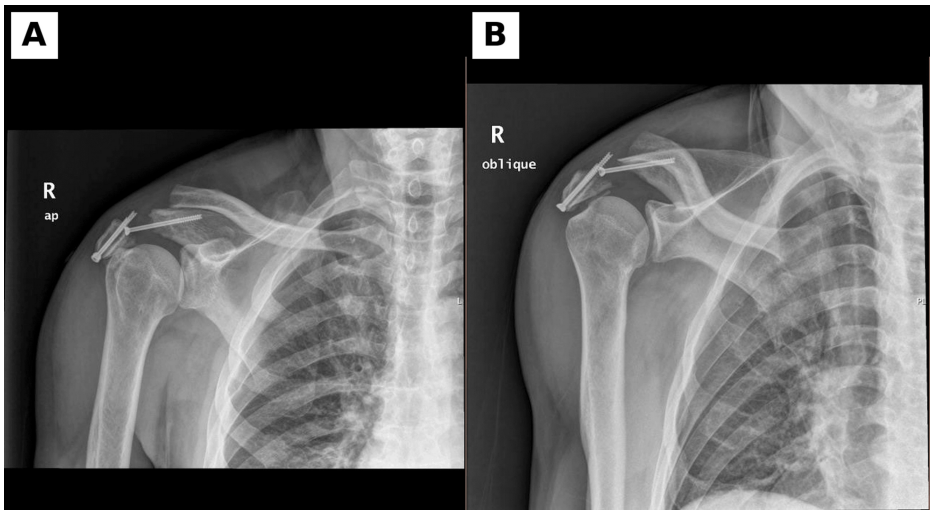

FIGURE 5: Radiographs after the second fall

(A) Anteroposterior and (B) oblique views showing loss of acromial fixation, with displacement of the lateral acromial fragment together with the implants.

Revision surgery was considered. Non-operative management was chosen because the acromiohumeral distance remained well above its preoperative value, the loss of coracoclavicular reduction was limited, and the risk of further falls and therefore of failure of a revision construct was high.

The arm was protected in a sling. Rehabilitation started two weeks after surgery with assisted motion and progressed to active motion; resisted strengthening was introduced only after radiographic evidence of healing. At five weeks, the patient reported no pain, had about 160° of active forward elevation, and was independent in activities of daily living. At three months, anteroposterior, bilateral Zanca, and axillary radiographs showed callus formation with a partly visible fracture line and no clinically relevant change from the post-fall radiographs (Figure 6, Table 1). The Constant-Murley score was 82/100.

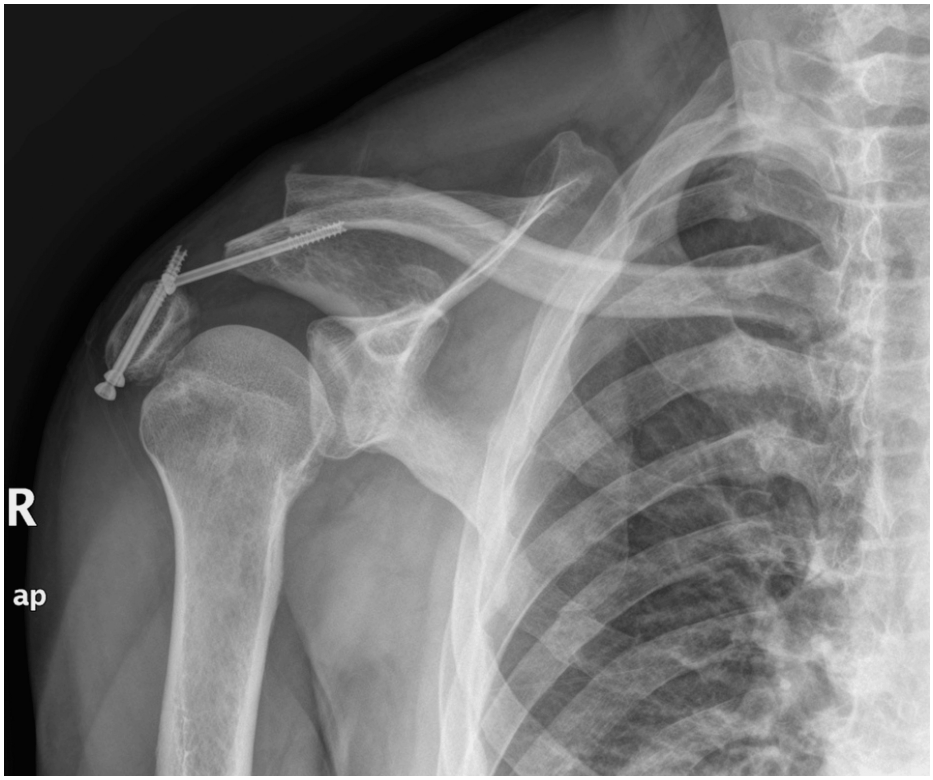

FIGURE 6: Radiograph at three months

Anteroposterior view showing no further displacement of the acromial fragment or of the acromioclavicular joint.

At the latest follow-up, 29 months after surgery, radiographs showed union of the acromion fracture with mild malunion, about 8 mm of stable residual displacement, intact screws without further migration, and no subacromial encroachment. The coracoclavicular distance was 13.2 mm on the right and 10.2 mm on the left; the acromiohumeral distance was 8.2 mm on the right and 9.0 mm on the left.

The patient reported pain of 0/10 at rest and during activity. There was no focal tenderness, clinical AC instability, or neurovascular deficit; slight scapular compensation was seen in the last degrees of elevation. Range of motion and strength are shown in Table *2*. Deltoid and supraspinatus strength was 4+/5 on the right, with 5/5 in the other muscle groups and in the contralateral shoulder. The Constant-Murley score was 90/100 on the right and 96/100 on the left, the American Shoulder and Elbow Surgeons (ASES) score was 93.3/100, and the QuickDASH score was 9.1/100 (Table *3*).

Measure	Right (injured)	Left
Forward elevation, active/passive	165°/175°	175°/180°
Abduction, active/passive	160°/170°	175°/180°
External rotation, arm at side	60°	70°
Internal rotation, vertebral level	T10	T7
Extension	50°	55°
Abduction strength in the scapular plane (kgf)	8.6	9.5

TABLE 2: Range of motion and strength at 29 months

Score	3 months, right	29 months, right	29 months, left
Constant-Murley, total (0-100)	82	90	96
Constant-Murley: pain (0-15)	15	15	15
Constant-Murley: activities of daily living (0-20)	18	20	20
Constant-Murley: mobility (0-40)	34	36	40
Constant-Murley: strength (0-25)	15	19	21
ASES (0-100)	88	93.3	Not assessed
QuickDASH (0-100)	15.9	9.1	Not assessed

TABLE 3: Functional scores

Lower QuickDASH scores indicate less disability.

ASES: American Shoulder and Elbow Surgeons score

Discussion

Goss described the SSSC as a bony and soft-tissue ring in which a double disruption may produce an unstable situation with adverse functional consequences [1]. This concept has guided the treatment of floating shoulder and complex scapular injuries for decades [2,16,17], and when several components of the ring are disrupted, surgery is usually considered in order to re-establish continuity and permit earlier rehabilitation [1,2,16]. The concept is not undisputed. Williams et al. showed in a cadaveric model that ipsilateral clavicle and glenoid neck fractures became unstable only when the coracoacromial and AC ligaments were also divided [4], and a clinical series of double disruptions reported good function after non-operative treatment, particularly when displacement was limited [3].

In this patient, the indication for surgery rested on two measured findings rather than on the number of disrupted sites alone: a Kuhn type III acromion fracture with an acromiohumeral distance of 5.5 mm and a Rockwood type III AC dislocation with a 95% increase in the coracoclavicular distance. Type III acromion fractures are commonly regarded as surgical injuries because malunion, nonunion, impingement, and loss of the deltoid lever arm may compromise function [11-15]. Ogawa and Naniwa emphasized the importance of fracture location around the acromion and lateral scapular spine [12]. Surgical series report good functional results and high union rates after fixation of displaced acromion and scapular process fractures, although the evidence is observational and limited to small numbers [13,14].

The choice of fixation deserves critical appraisal. Tension-band and plate constructs are the methods most often described for displaced acromion fractures [13-15], and a plate offers greater stiffness and rotational control than screws alone. Three cannulated screws with washers were chosen here to limit soft-tissue dissection and implant prominence on a thin acromion. In retrospect, in a patient with a movement disorder, osteopenia, and a history of falls, a plate or tension-band construct would probably have been more tolerant of a second injury. Residual displacement after the index operation was about 2 mm, and loss of reduction was documented only after the fall, so we attribute it to the new trauma; however, we cannot exclude that a stiffer construct would have survived it. This is, in our view, one of the main lessons of the case. Perioperative falls prevention is the other: in patients with Parkinson's disease, supervised mobilization and bed alarms should be in place from the first postoperative hour rather than after an incident.

After the fall, most of the reduction achieved by surgery was lost (fragment displacement increased from 2 to 9 mm, approaching the 12 mm displacement present at injury). We distinguish this loss of reduction from loss of fixation: the hardware itself failed only partially because the screws remained in bone, the fragment did not return to its original position, and, most importantly, the acromiohumeral distance remained 8.0 mm, compared with 5.5 mm before surgery and 9.0 mm on the contralateral side. The coracoclavicular distance increased from 11.4 to 13.0 mm, that is, from 12% to 27% above the uninjured side. The coracoclavicular stabilization therefore did not remain anatomically intact: some reduction was lost. What the serial bilateral Zanca views show is that this loss was limited and showed no clinically relevant progression over 29 months (Table *1*). Horizontal AC stability was not assessed with an Alexander view, and the sutures are radiolucent, so their integrity can only be inferred from these measurements.

The decision not to revise was based on the preserved subacromial space, the limited and non-progressive loss of coracoclavicular reduction, and the patient's risk profile. Parkinson's disease with freezing of gait,

two falls in the preceding year, and a further fall within 48 hours of surgery made failure of a revision construct a realistic prospect. The fracture went on to unite in mild malunion, and at 29 months, the patient was pain-free with a Constant-Murley score of 90, six points below the contralateral shoulder, the difference being confined to the mobility and strength subscores.

Several explanations for this result are possible, and a single case cannot distinguish between them. First, the retained coracoclavicular stabilization may have preserved enough of the suspensory link for the shoulder girdle to function. This is a hypothesis; it is consistent with the stable coracoclavicular distance but is not demonstrated by it. Second, the result may reflect the natural history of the injuries. Many Rockwood type III AC dislocations achieve good function without surgery [18], and displaced acromion fractures and double disruptions can do well with non-operative treatment [3,15]. Third, the patient's functional demands were modest, and early rehabilitation may have contributed. The case therefore raises the question of whether the index operation was necessary at all. We believe surgery was justified by the preoperative acromiohumeral distance of 5.5 mm, which the operation, even after partial loss of fixation, improved to about 8 mm; but we acknowledge that a comparable result without surgery cannot be excluded.

Triple SSSC disruptions are particularly rare. Mulawka et al. described patients with triple and quadruple disruptions and emphasized the frequency of associated injuries and the role of operative stabilization in selected cases [5]. Other authors have reported individual triple-disruption patterns, most describing anatomical fixation of every disrupted component [6-10]. Tuor et al. reported five cases of multiple SSSC disruption involving at least a coracoid fracture and AC dislocation, again underlining the rarity of these patterns and the absence of comparative evidence [19]. To our knowledge, the management of early loss of fixation in such a reconstruction has rarely been addressed.

This report has limitations. It is a retrospective description of a single patient and is subject to reporting bias. No CT was obtained after the second fall or at follow-up, so union and residual displacement were assessed on plain radiographs only. Horizontal AC stability was not assessed with an Alexander view. The integrity of the coracoclavicular sutures is inferred from serial measurements rather than shown directly. Displaced implants were retained; they have caused no symptoms to date, but later irritation cannot be excluded. Bone density was measured only during follow-up. Only a selection of the radiographs is reproduced as figures; the measurements made on bilateral Zanca views and at the latest follow-up are reported in Table *1*. Preoperative functional scores were not available, and Parkinson's disease may itself influence shoulder strength and the scores obtained. These findings cannot be generalized.

Conclusions

Triple disruption of the SSSC is a rare injury that is commonly treated with surgical stabilization. In this patient with Parkinson's disease, partial loss of acromial fixation after a fall on the second postoperative day was managed without revision. The fracture united in mild malunion, the subacromial space was preserved, and the coracoclavicular distance showed no clinically relevant progression on serial radiographs. At 29 months, the patient was pain-free with a Constant-Murley score of 90. Radiographic loss of reduction after SSSC reconstruction may therefore not always require immediate revision in selected patients at high risk of recurrent falls, provided that the subacromial space is preserved, function is recovering, and close clinical and radiographic surveillance is maintained. The findings of a single case cannot be generalized.

Additional Information

Author Contributions

All authors have reviewed the final version to be published and agreed to be accountable for all aspects of the work.

Concept and design: Rui Nobre Chaves, António Lemos-Lopes

Acquisition, analysis, or interpretation of data: Rui Nobre Chaves, Sara Neves, Sofia Neto, António Gomes Cruz

Drafting of the manuscript: Rui Nobre Chaves

Critical review of the manuscript for important intellectual content: Rui Nobre Chaves, Sara Neves, Sofia Neto, António Gomes Cruz, António Lemos-Lopes

Supervision: António Lemos-Lopes

Disclosures

Human subjects: Informed consent for treatment and open access publication was obtained or waived by all participants in this study. **Conflicts of interest:** In compliance with the ICMJE uniform disclosure form, all authors declare the following: **Payment/services info:** All authors have declared that no financial support

was received from any organization for the submitted work. **Financial relationships:** All authors have declared that they have no financial relationships at present or within the previous three years with any organizations that might have an interest in the submitted work. **Other relationships:** All authors have declared that there are no other relationships or activities that could appear to have influenced the submitted work.

References

1. Goss TP: Double disruptions of the superior shoulder suspensory complex . J Orthop Trauma. 1993, 7:99-106. 10.1097/00005131-199304000-00001
2. Oh W, Jeon IH, Kyung S, Park C, Kim T, Ihn C: The treatment of double disruption of the superior shoulder suspensory complex. Int Orthop. 2002, 26:145-9. 10.1007/s00264-001-0325-1
3. Edwards SG, Whittle AP, Wood GW 2nd: Nonoperative treatment of ipsilateral fractures of the scapula and clavicle. J Bone Joint Surg Am. 2000, 82:774-80. 10.2106/00004623-200006000-00003
4. Williams GR Jr, Naranja J, Klimkiewicz J, Karduna A, Iannotti JP, Ramsey M: The floating shoulder: a biomechanical basis for classification and management. J Bone Joint Surg Am. 2001, 83:1182-7. 10.2106/00004623-200108000-00007
5. Mulawka B, Jacobson AR, Schroder LK, Cole PA: Triple and quadruple disruptions of the superior shoulder suspensory complex. J Orthop Trauma. 2015, 29:264-70. 10.1097/BOT.0000000000000275
6. Kim SH, Chung SW, Kim SH, Shin SH, Lee YH: Triple disruption of the superior shoulder suspensory complex. Int J Shoulder Surg. 2012, 6:67-70. 10.4103/0973-6042.96999
7. Badam VK, Harsha TS, Sankineani SR, Rachakonda KR, Bodanki C, Reddy AV: Triple disruption of the superior shoulder suspensory complex - a case report. J Orthop Case Rep. 2019, 9:39-42. 10.13107/jocr.2250-0685.1410
8. Wu K, Wu XM, Zha XL, Wang QG: Anatomic restoration of triple disruption of the superior shoulder suspensory complex: a case report and review of the literature. Orthop Surg. 2020, 12:1526-30. 10.1111/os.12764
9. Jaën M, Sayer L, Fornaciari P: Triple disruption of the superior shoulder suspensory complex - review and surgical technique. J Orthop Case Rep. 2023, 13:121-6. 10.13107/jocr.2023.v13.i06.3720
10. Nguyen MK, Nguyen VH, Le HG, Cao DB: Multiple disruptions of superior suspensory shoulder complex: a case report. Int J Surg Case Rep. 2024, 124:110385. 10.1016/j.ijscr.2024.110385
11. Kuhn JE, Blasier RB, Carpenter JE: Fractures of the acromion process: a proposed classification system . J Orthop Trauma. 1994, 8:6-13. 10.1097/00005131-199402000-00002
12. Ogawa K, Naniwa T: Fractures of the acromion and the lateral scapular spine . J Shoulder Elbow Surg. 1997, 6:544-8. 10.1016/s1058-2746(97)90087-2
13. Anavian J, Wijdicks CA, Schroder LK, Vang S, Cole PA: Surgery for scapula process fractures: good outcome in 26 patients. Acta Orthop. 2009, 80:344-50. 10.3109/17453670903025394
14. Hill BW, Anavian J, Jacobson AR, Cole PA: Surgical management of isolated acromion fractures: technical tricks and clinical experience. J Orthop Trauma. 2014, 28:e107-13. 10.1097/BOT.0000000000000040
15. Hess F, Zettl R, Welter J, Smolen D, Knoth C: The traumatic acromion fracture: review of the literature, clinical examples and proposal of a treatment algorithm. Arch Orthop Trauma Surg. 2019, 139:651-8. 10.1007/s00402-019-03126-6
16. Cole PA, Gauger EM, Schroder LK: Management of scapular fractures . J Am Acad Orthop Surg. 2012, 20:130-41. 10.5435/JAAOS-20-03-130
17. Limb D: Scapula fractures: a review . EFORT Open Rev. 2021, 6:518-25. 10.1302/2058-5241.6.210010
18. Canadian Orthopaedic Trauma Society: Multicenter randomized clinical trial of nonoperative versus operative treatment of acute acromio-clavicular joint dislocation. J Orthop Trauma. 2015, 29:479-87. 10.1097/BOT.0000000000000437
19. Tuor P, Dietrich M, Grüninger P: Surgical management of multiple superior shoulder suspensory complex disruptions involving at least a coracoid fracture and an acromioclavicular dislocation: a report of five cases. SAGE Open Med Case Rep. 2023, 11:2050313X231166776. 10.1177/2050313X231166776