Cureus
Part of SPRINGER NATURE

Open Access Case Report

Vaginal Bleeding During Pregnancy From the Non-gravid Side of a Didelphys Uterus Managed With a Bakri Balloon: A Case Report

Alexandra Dailey [1], Jana Van Beckum [1]

1. Obstetrics and Gynecology, Kettering Health, Dayton, USA

Corresponding author: Alexandra Dailey, alexdailey331@gmail.com

Review began 10/31/2026
Review ended 11/22/2026
Published 11/23/2026

© Copyright 2026
Dailey et al. This is an open access article distributed under the terms of the Creative Commons Attribution License CC-BY 4.0., which permits unrestricted use, distribution, and reproduction in any medium, provided the original author and source are credited.

DOI: 10.7759/cureus.120145

Abstract

We present a case of a 24-year-old G2P1011 patient at 30 weeks zero days' gestation who presented to labor and delivery triage with vaginal bleeding and mild cramping. On speculum exam, an area adjacent to the cervix was identified as the source of bleeding and was thought to be a ruptured vaginal cyst, as a Gartner's duct cyst was also observed in this area. A Bakri balloon placed in the vaginal canal was required to tamponade the bleeding. On MRI, the patient was noted to have a didelphys uterus with an intrauterine pregnancy on the right side and a dilated left cervix with blood products in the left uterus. This anomaly was previously thought to be a bicornuate uterus on a dating ultrasound performed at 12 weeks three days' gestation, with the pregnancy located in the right horn. The bleeding resolved, and the patient subsequently presented at 39 weeks two days with a recurrence of vaginal spotting. The decision was made to proceed with induction of labor. A primary cesarean section was performed without complications due to a persistent category II fetal heart tracing, and a 3290 g male fetus with one- and five-minute Apgar scores of eight and nine was delivered.

Categories: Obstetrics/Gynecology, Anatomy
Keywords: bakri balloon, bicornuate uterus, müllerian duct anomaly, uterine didelphys, vaginal bleeding

Introduction

Uterine didelphys is aMüllerianduct anomaly resulting from incomplete fusion of theMüllerianductsduring embryogenesis, producing two separate hemiuteri with two endometrial cavities, two cervices, and usually a longitudinal vaginal septum or two vaginas. This anatomic variation is believed to account for 5% of allMüllerianduct anomalies and can be difficult to distinguish from other anomalies, such as a bicornuate uterus or septate uterus [1]. Patients with a vaginal septum or two vaginas usually present with difficulties with intercourse or tampon insertion. These anomalies can typically be observed on physical exams. Bicornuate or septate uteri are usually asymptomatic but may be identified after recurrent pregnancy loss or incidentally during a transvaginal ultrasound. A unicollis bicornuate uterus involves two uterine cavities, designated as uterine horns, that meet in the lower uterine segment and drain through one cervix. The external contour of the uterus shows a fundal cleft of at least 1 cm, creating a heart shape. A subtype of bicornuate uterus is a bicollis bicornuate uterus, which has similar anatomic features to a unicollis bicornuate uterus but with two separate cervices. The external contour appears the same. A septate uterus develops when the septum between the fused Müllerianducts fails to resorb and can be indicated in early pregnancy loss due to implantation difficulties [1]. The external contour appears like a normal uterus, without a cleft. After a pregnancy develops in a uterus with the above-mentioned anomalies, the pregnancy will appear to be in its own cavity. This could occur in a septate, bicornuate, or didelphys uterus. To distinguish these anomalies from one another, the presence or absence of two cervices, as well as a uterine cleft, must be evaluated. These features can be difficult to appreciate on transvaginal ultrasound because ultrasound has limited ability to capture external uterine characteristics and because optimizing planes is difficult when two cervices are present. Uterine didelphys can be seen independently or within a syndrome called OHVIRA (Obstructed Hemivagina and Ipsilateral Renal Agenesis), also known as Herlyn-Werner-Wunderlich syndrome. Obstetric risks are similar to the risks of allMüllerianduct anomalies and include preterm birth, fetal malpresentation, and pregnancy loss [1].

In patients with a didelphys or bicollis bicornuate uterus, bleeding from the non-gravid uterus or uterine horn during pregnancy is an uncommon presentation and is challenging to identify. A separate cervix may not be easily visualized on physical exam, which presents a significant diagnostic challenge. We present a case of third-trimester bleeding in which the source was initially thought to originate from a vaginal wall lesion, but magnetic resonance imaging (MRI) helped to identify the likely source as the displaced cervix of the non-gravid uterus. This unusual cause of bleeding was temporarily tamponaded with an intravaginal Bakri balloon while imaging was being obtained.

Case Presentation

The patient had no relevant medical history. Obstetric history included one previous spontaneous abortion

that occurred at around six weeks six days' gestation. The patient was noted to have a possible uterine anomaly on ultrasound at that time, but no other risk factors were identified, and it was difficult to identify whether there was one or two cervices. During the patient's second pregnancy, her initial prenatal vaginal culture was suggestive of bacterial vaginosis, and she was treated with oral metronidazole. Cell-free DNA testing resulted in a low-risk male, and carrier screening was negative. A dating ultrasound at 12 weeks three days' gestation was consistent with her last menstrual period. An intrauterine pregnancy was observed in the right uterine horn of what appeared to be a bicornuate uterus. Only one cervix was visualized and was measured at a length of 4.20 cm. A previous transvaginal ultrasound performed one year prior for pelvic pain noted a uterine anomaly that was either bicornuate or didelphys, likely bicornuate, with the right horn measuring 8.2 x 4.2 x 3.7 cm and the left horn measuring 8.3 x 4.8 x 4.0 cm (Figures *1*-*3*).

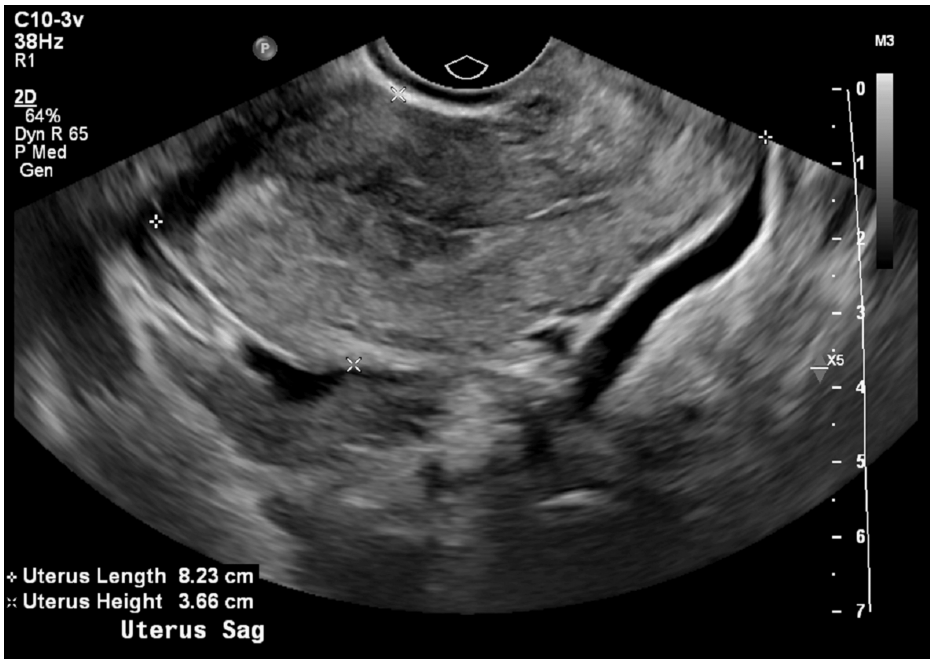

FIGURE 1: Transvaginal ultrasound of the right uterus of a didelphys uterus

Sagittal view of the right uterus of the patient's didelphys uterus, measuring 8.23 cm × 3.7 cm, originally thought to be the right horn of a bicornuate uterus. The asterisks denote the edges of the uterus that were used as points to calculate this measurement.



FIGURE 2: Transvaginal ultrasound of the left uterus of a didelphys uterus

Sagittal view of the left uterus of the patient's didelphys uterus, measuring 8.34 cm × 4.00 cm, previously thought to be the left horn of a bicornuate uterus. The asterisks denote the edges of the uterus that were used as points to calculate this measurement.

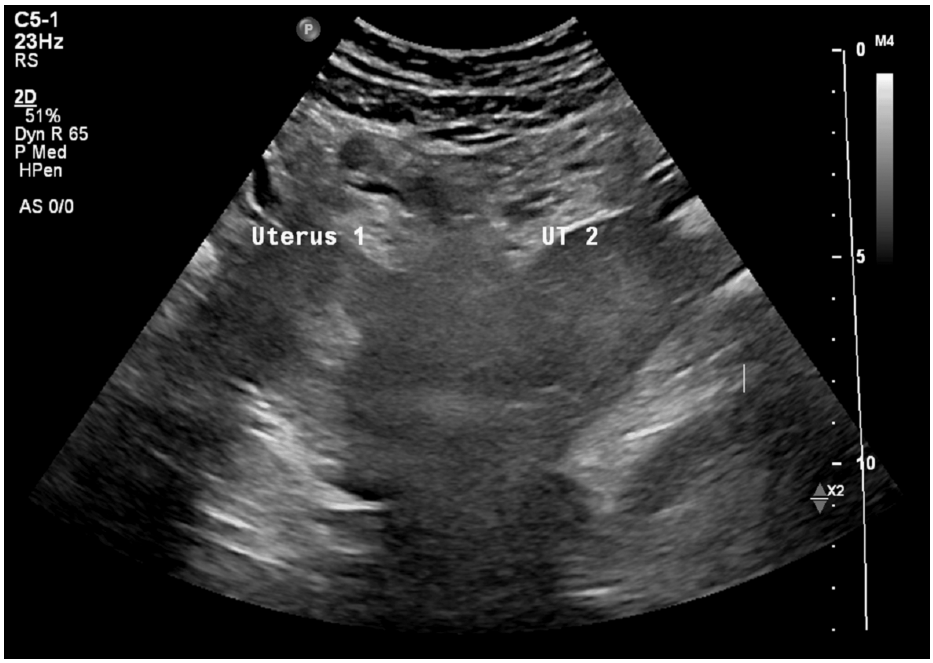

FIGURE 3: Transvaginal ultrasound of the right and left uteri of a didelphys uterus

Transverse view of the right and left uteri of the patient's didelphys uterus. The right uterus is labeled as Uterus 1 and the left as UT 2. Two uterine bodies and endometrial cavities can be observed, but two separate cervices were unable to be visualized throughout the imaging.

A fetal anatomy scan performed at 19 weeks six days' gestation showed normal fetal anatomy with a posterior placenta and fetus in a breech position. A bicornuate uterus was noted again, withonly one cervix

appreciated. The patient was evaluated for an episode of bright red vaginal bleeding at 29 weeks six days' gestation in labor and delivery triage. The bleeding had decreased on presentation, and a speculum exam revealed a scant amount of dark red blood appearing to originate from a left vaginal wall abrasion. No active bleedingwas observed, and fetal status was reassuring with a reactive nonstress test and an 8/8 biophysical profile. The patient was discharged with return precautions.

One day later, the patient presented to labor and delivery triage at 30 weeks zero days' gestation and reported an increase in vaginal bleeding along with mild cramping but no contractions. On speculum exam, a 2-3 cm left vaginal wall opening was seen with active bright red bleeding, blood clots, and tissue pouring into the speculum. Thetissuewas cleared using ring forceps,andbloodwas cleared withseveral large rayon swabs. A tissue sample was collected and sent to pathology. Labs were collected. Placental abruption, uterine rupture, cervical polyp, vaginal laceration, ruptured vaginal cyst, placenta previa, and vasa previa were included in the initial differential diagnoses. Placenta previa and vasa previa were low on the differential list given previous ultrasounds without these findings. A vaginal laceration alone wasloweron the list as well, although asmall vaginal abrasion was noted on exam one day prior. This small abrasion would be unlikely to cause the amount of bleeding that was observed, with an estimated blood loss around 200 cc, and the patient reported no recent intercourse or trauma. Further, the abrasion was likely the same area as the opening in the vaginal wall that was now expelling tissue and blood clots. Although the patient denied contractions or severe pain, she did report some mild cramping. There was high suspicion for placental abruption or uterine rupture initially due to the amount of active bleeding seen on speculum exam. After the bleeding was cleared with multiple large rayon swabs and the source of bleeding was identified as an area adjacent to the cervix, an intrauterine cause was not as high on the differential list. A cervix was observed 90 degrees posterior and to the left of this opening and was visually closed with no bleeding. There were no cervical polyps noted, but there was a left-sided Gartner's duct cyst. The working diagnosis then became a possible ruptured vaginal cyst, with placental abruption and uterine rupture still considered until they could be ruled out. Complete blood count and coagulation labs, including PTT, PT-INR, and fibrinogen, were all grossly unremarkable. Hemoglobin was 11.8. The patient's vital signs were stable, with a heart rate ranging from 75 to 103 beats per minute and a blood pressure of 110/53. Fetal status was reassuring with a reactive nonstress test with no decelerations.

At this time, a urinary catheter was placed, followed by a Bakri balloon in the vaginal canal, not the cervix, that was instilled with 120 cc of saline to tamponade the bleeding. This off-label use of a Bakri balloon was chosen due to the ease of placement and mechanism of use. The vaginal mucosa is rich in blood vessels, and bleeding from this surface usually stems from many small vessels. The Bakri balloon was able to conform to the vaginal canal and apply even pressure to tamponade the bleed. After placement, no additional bleeding was observed. An MRI scanof the pelvis without contrast was orderedwith the Bakri balloon in placeto further evaluate the uterine anatomy and source of bleeding. The MRI showed two separate uterine cavities, with the fetus in the right uterus and blood products in the left uterus, with a dilated and hypoplastic left cervix (Figures *4*-*6*).

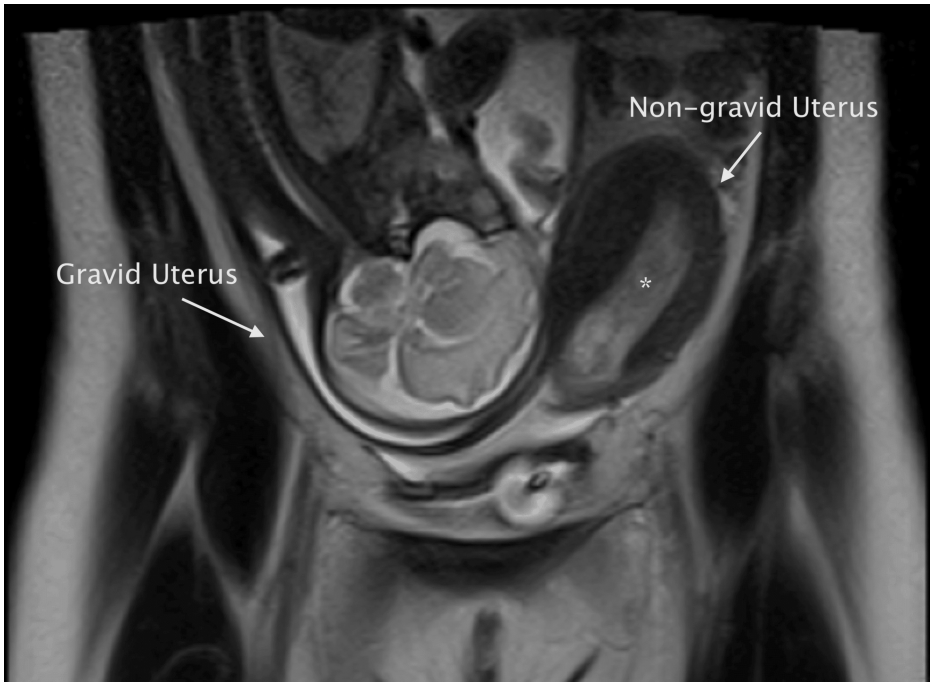

FIGURE 4: Magnetic resonance imaging (MRI) of the gravid uterus and non-gravid uterus of a didelphys uterus

Coronal view of the patient's MRI of the pelvis without contrast demonstrating the gravid uterus at 30 weeks zero days' gestation and the non-gravid uterus with blood products (asterisk) in the uterine cavity.

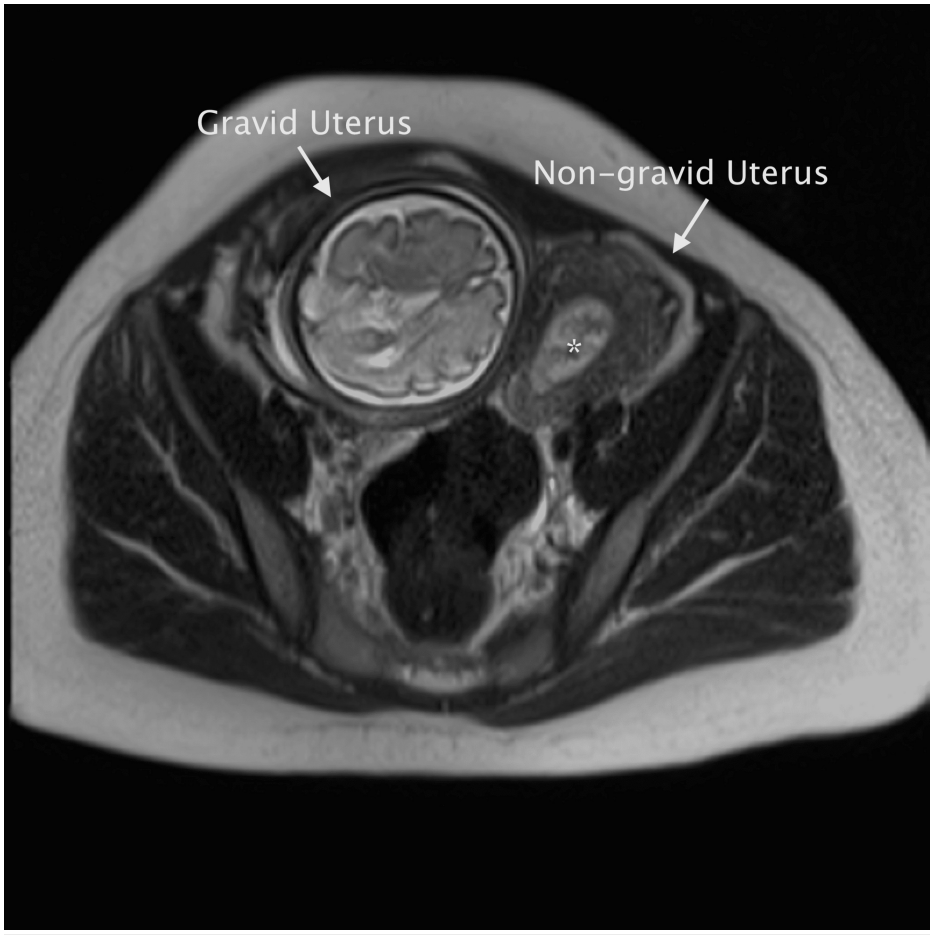

FIGURE 5: Transverse view of the gravid and non-gravid uteri of a didelphys uterus

Transverse view of the patient's MRI of the pelvis without contrast showing two separate uterine cavities with the gravid uterus containing a 30-week zero-day pregnancy and the non-gravid uterus containing blood products (asterisk).

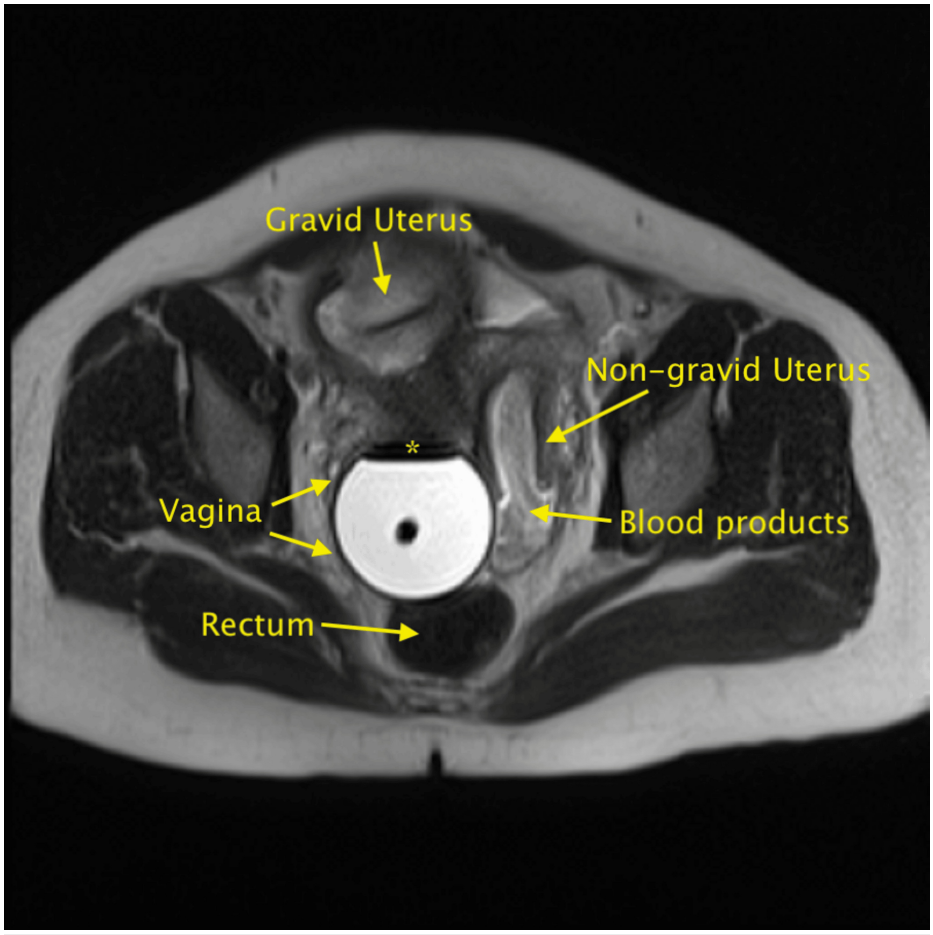

FIGURE 6: Lower uterine segment of the gravid side of a didelphys uterus with blood products in the non-gravid segment and a Bakri balloon in the vaginal canal

Transverse view of the patient's MRI of the pelvis without contrast demonstrating the lower uterine segment of the gravid uterus anteriorly (labeled Gravid Uterus) and blood products in the non-gravid uterus (labeled Non-gravid Uterus and Blood products), adjacent to a saline-instilled Bakri balloon in the vaginal canal. The vaginal canal is depicted with arrows and labeled as "Vagina," and the Bakri balloon within it is labeled with an asterisk. Below the vagina, the rectum is labeled "Rectum."

The blood products were able to be traced down to the level of the Bakri balloon in the vagina on imaging. This uterine anomaly was originally diagnosed as a bicornuate uterus again, although two cervices wereappreciatedthis time. The images were discussed among the Maternal Fetal Medicine and radiology teams, and the diagnosis of uterine didelphys was agreed upon due to the external surface of the non-gravid uterus extending caudally all the way to the vaginal fornix. The likely source of the bleeding was identified as the non-gravid left uterus, and the suspected ruptured cyst appeared to be the hypoplastic left cervix, difficult to fully appreciate on previous ultrasounds due to the cervices' location to one another. Several small, intact Gartner's duct cysts were also seen on MRI, strengthening the interpretation that the vaginal opening was correctly reidentified as the hypoplastic left cervix. The imaging did not show any clear cause of bleeding.

Following the MRI, the patient began developing contractions that were observed on the tocodynamometry monitor every 2-3 minutes. The decision was made to transfer the patient to a facility with a Level III Neonatal Intensive Care Unit to admit her for further workup of vaginal bleeding with uncertain etiology and preterm contractions. The patient received prophylactic antenatal corticosteroids for fetal lung maturity, magnesium sulfate for fetal neuroprotection, and oral Procardia 10 mg every 10 minutes for three doses for tocolysis in case the patient's cervix of the gravid uterus began to dilate and delivery became imminent. After the patient was transferred, she reported that her contractions had subsided and no contractions were noted on tocodynamometry on arrival. She had minimal bleeding noted on her pad at this time. Repeat hemoglobin values were stable at 11.1 and 11.4.

Given the MRI findings of uterine didelphys, the recommendation was made to begin deflating the Bakri

balloon incrementally after the patient's second course of steroids. Completion of the two-dose steroid course was still recommended at this time since the patient was at an increased risk of preterm delivery based on the presence of a uterine anatomic anomaly. The pathology report from the expelled tissue resulted as endometrial tissue, further strengthening the idea that the non-gravid uterus was the source of bleeding. The etiology was thought to be a collection of residual endometrial material that began to spontaneously pass, although definitive etiology remains unclear. She received her second dose of steroids 24 hours after the first dose. Thirty-six hours after the balloon was placed, the deflation process began, with plans to remove 20 cc of fluid at a time. There was no additional bleeding after the first60 cc of fluid was removed. After 80 cc was removed, a nickel-sized blood clot was noted on the patient's pad. No active bleeding was observed, and no additional bleeding occurred after the remaining fluid was removed. A speculum exam was performed following the Bakri balloon's removal, and no bleeding, lacerations, vaginal septum, second cervix, or opening in the vaginal wall could be appreciated. A single, closed, thick cervix was noted. The patient was monitored for 48 hours post-removal of the Bakri balloon. Follow-up transvaginal ultrasound performedon the day of dischargedemonstrated normal fetal growth and amniotic fluid index, uterine didelphys with the fetus in the right uterus, and a malpositioned, dilated left cervix (Figures *7*, *8*).

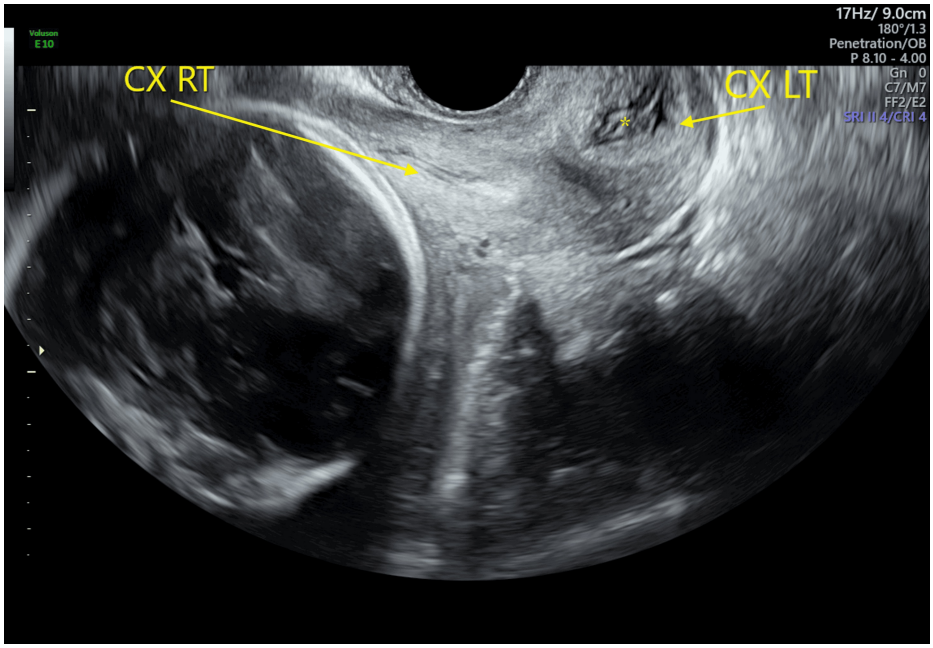

FIGURE 7: Gravid right uterus and cervix of a didelphys uterus with a hypoplastic, dilated left cervix

Transvaginal ultrasound performed at 30 weeks three days' gestation showing a gravid right uterus and cervix (CX RT, for Cervix Right). The hypoplastic left cervix (CX LT, for Cervix Left) is dilated and contains blood products (asterisk).

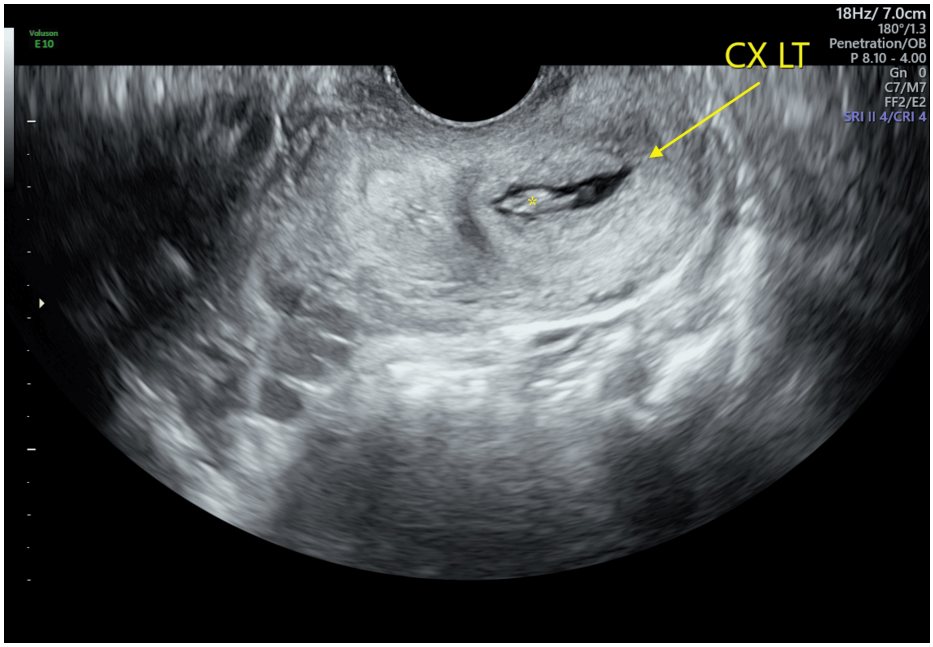

FIGURE 8: Hypoplastic, dilated left cervix of a didelphys uterus containing blood products

Transvaginal ultrasound performed at 30 weeks three days' gestation showing a hypoplastic, malpositioned, and dilated left cervix (CX LT, for Cervix Left) with blood products (asterisk).

The patient was discharged in stable condition and counseled that the bleeding may recur and to present to labor and delivery if this occurs. As the bleeding did not recur, the patient was managed expectantly for the remainder of thepregnancy with twice-weekly antenatal fetal surveillanceusing nonstress tests and biophysical profiles. These tests were reassuring. On the day of herscheduled induction of labor at 39 weekstwo days' gestation, the patient arrived early,reportingvaginal spotting. On exam, there was scant blood noted, with no blood visualized coming from the right cervix. The left cervix could not be visualized or palpated on exam. The patient's right cervix was 1/50/-3, fetal heart tracing was category I, and hemoglobin was stable at 11.9. The decision was made to begin induction at that time.

Over the course of her induction, she received six doses of oral misoprostol 25 mcg and made a cervical change to 1.5/50/-3. She subsequently developeda persistent category II fetal heart tracingwith nonspecific and late decelerations. The decision was made to proceed with a primary low-transverse cesarean section, which was performed without complications, and a3290 g male fetus with one- and five-minute Apgar scores of eight and nine was delivered. The total quantitative blood loss from the cesarean delivery was 475 cc. The uterus was exteriorized during the procedure, and both uteri were grossly visualized. The uteri were observed with separate funduses and bodies and were able to be traced down individually into the pelvis. The smaller left uterus was located posterior to the right uterus.

On bimanual exam following delivery, both cervices could be easily palpated, which had been difficult on cervical exams during pregnancy. The presented outcome cannot be attributed to the acute management of the patient's vaginal bleeding, as the etiology still remains unclear. The management of vaginal bleeding using an intravaginal Bakri balloon was an unconventional method to tamponade bleeding in a patient who presented originally with minor bleeding that subsequently increased over the course of one day and was visualized as blood clots and tissue being expelled from a vaginal wall opening. The patient was found to have a didelphys uterus on MRI, with the non-gravid uterus as the likely source of the bleeding.

Discussion

Uterine didelphys and otherMüllerianduct anomalies are associated with an increased risk of several adverse maternal and fetal outcomes, including preterm birth, fetal malpresentation, cesarean section, cervical insufficiency, and pregnancy loss. In one study measuring obstetric outcomes in the United States in patients with known uterine anomalies, those with a didelphys uterus experienced the highest preterm birth rate and periviable birth rate, at 34.5% and 6.9%, respectively [2]. Severe maternal morbidity, defined using a composite of Centers for Disease Control and Prevention (CDC)-defined indicators, occurred in 4.2% of all patients with uterine didelphys. In a large Swedish study that covered >98% of births in the country over 12 years of prospectively collected data, uterine anomalies were strongly statistically associated with an increased risk of preterm premature rupture of membranes (PPROM), preterm birth under 34 weeks of

gestation, breech presentation, placental abruption, stillbirth, and small for gestational age (SGA) [3]. Uterine didelphys was grouped into other doubled uterus anomalies and was unable to be studied independently; however, this subgroup, which included didelphys uterus, was found to have an emergency cesarean section rate of 30.4% and experienced increased rates of all the complications previously mentioned in this study. Uterine anomalies are also a risk factor for cervical insufficiency and can be associated with recurrent pregnancy loss and managed with cerclage placement in subsequent pregnancies [1].

Several case reports highlight unique complications of pregnancies with uterine didelphys, several of which involved vaginal bleeding [4-10]. The severity of bleeding ranged from spontaneous resolution to uterine rupture and placenta percreta, causing massive hemorrhage and hemoperitoneum. Exceedingly rare pregnancies have resulted from a didelphys uterus, including a spontaneous dichorionic-diamniotic gestation with one fetus in each uterus [11]. These complications occur too infrequently to infer statistically increased risks but are important to document because they may be difficult to diagnose or misdiagnosed. In one case, uterine rupture of a didelphys uterus occurred at 17 weeks' gestation, causing a 2500 mL intraperitoneal hemorrhage, but was initially misdiagnosed as acute appendicitis in the setting of a reassuring fetal status [8]. In our case, the patient had severalprior ultrasounds that indicated a uterine anomaly that appeared to be either bicornuate or didelphys, but only a single cervix was able to be appreciated on initial imaging, resulting in a diagnosis of a bicornuate uterus. In the setting of vaginal bleeding, this resulted in the working diagnosis of either an intrauterine cause involving a gravid uterus or a vaginal wall etiology. This anomaly was easier to identify on imaging once the hypoplastic non-gravid cervix became dilated and was actively bleeding. Thedifficulty in visualizing the second cervix initially demonstrates how these anomalies can be missed.

A case report documented bySoh and Lim [9]highlights a similar case of a 35-year-old with a known didelphys uterus who presented with painless vaginal bleeding at 28 weeks' gestation, but the source of bleeding was unableto be identified on exam. At 31 weeks, the bleeding recurred with pelvic cramping. The bleeding was then noted tooriginatefrom the non-gravid cervix. On ultrasound, fetal growth was normal; there was no evidence of placenta previa, and there was a thick decidua noted in an enlarged non-gravid uterus. The bleeding subsided, and the patient was managed expectantly with tocolysis and antenatal corticosteroids. Fetal surveillance was reassuring, and the cramping ultimately subsided after the patient passed a decidual cast blood clot measuring 7x3x2 cm at 32 weeks' gestation. The gravid uterus was soft and non-tender at that time. Serial growth ultrasounds, amniotic fluid index, and umbilical artery Dopplers remained reassuring. She subsequently underwent an uncomplicated delivery via planned cesarean section at 38 weeks.

Our case is similar in that our patient presentedwithmostlypainless vaginal bleeding, had a reassuring fetal status, the bleeding subsided, and the patient was able to be managed expectantly without complications until delivery at term. Vaginal bleeding in the setting of uterine anomalieshas various presentations, and individualized management is necessary. In our case, the decision was made to place a Bakri balloon in the vagina to tamponade bleeding to obtain further imaging, as the cervix of the gravid uterus was not bleeding on exam, the patient was stable, and there was a reassuring fetal status. MRI assisted with accurate differentiation of the uterine anatomy, although the exact etiology of the bleeding was not diagnosed. The patient's anatomy resulted indifficulty visualizing the second cervixdue to its positioning and underdevelopment, whichrepresents a unique diagnostic challenge that resulted in adelayed diagnosis. Individualized clinical judgment in cases of unclear sources of bleeding in pregnancy is particularly crucial in uterine anatomic anomalies to clarify any indication for expedited delivery.

Conclusions

Thiscase report presents an unusual cause of vaginal bleeding in pregnancy andunique uterine anatomy. The patient was diagnosed with uterine didelphys after an MRI was performed secondary to active vaginal bleedingwith an unclear source. She had previously been diagnosed with a bicornuate uterus based on transvaginal ultrasound imaging, which was unable to detect the second, hypoplastic cervix due to its location being roughly 90 degrees from the first cervix and more caudally placed in the vaginal canal. This cervix was also not appreciated on the cervical exam for this reason, as it appeared to be on the left vaginal sidewall and was difficult to visualize until it was dilated and actively expelling blood and tissue. Even at this time, it presented as a cyst or other vaginal etiology due to its location. A Bakri balloon was placed intravaginally to tamponade the bleeding temporarily for further diagnostic evaluation and an antenatal steroid course. After MRI, it was determined that the source of bleeding was originating from the left, non-gravid uterus. The bleeding subsided, and the patient was able to be managed expectantly with twice-weekly antenatal fetal surveillance until delivery by cesarean section for an unrelated indication at 39 weeks two days' gestation. Both uteri were able to be exteriorized and visualized grossly during the procedure, and both cerviceswere identified on cervical exam after delivery. In this case, MRI and physical exam supported the likely source of third-trimester vaginal bleeding as the non-gravid uterus. A displaced second cervix was originally thought to be a vaginal wall lesion. The proposed mechanism of bleeding was residual endometrial tissue spontaneously passing, and although the exact etiology was unknown, the bleeding was temporarily stopped with an intravaginal Bakri balloon to allow for further investigation, and no further bleeding was observed after the balloon was deflated.

Additional Information

Author Contributions

All authors have reviewed the final version to be published and agreed to be accountable for all aspects of the work.

Concept and design: Alexandra Dailey, Jana Van Beckum

Acquisition, analysis, or interpretation of data: Alexandra Dailey, Jana Van Beckum

Drafting of the manuscript: Alexandra Dailey

Critical review of the manuscript for important intellectual content: Alexandra Dailey, Jana Van Beckum

Disclosures

Human subjects: Informed consent for treatment and open access publication was obtained or waived by all participants in this study. Kettering Health Network IRB issued approval KHN-2026-202. This activity was deemed exempt from IRB submission. Written consent was obtained from the subject for publication of de-identified data, including the images in the manuscript. **Conflicts of interest:** In compliance with the ICMJE uniform disclosure form, all authors declare the following: **Payment/services info:** All authors have declared that no financial support was received from any organization for the submitted work. **Financial relationships:** All authors have declared that they have no financial relationships at present or within the previous three years with any organizations that might have an interest in the submitted work. **Other relationships:** All authors have declared that there are no other relationships or activities that could appear to have influenced the submitted work.

Acknowledgements

We thank Drs. Paul Pawlosky, Hind Moussa, Annette Bombrys, and Trisha Pachiano for their clinical guidance and imaging review.

References

1. Cunningham FG, Leveno KJ, Dashe JS, Hoffman BL, Spong CY, Casey BM: Williams Obstetrics (26th ed.). McGraw Hill, New York (NY); 2022. https://accessmedicine.mhmedical.com/book.aspx?bookid=2977.
2. Mandelbaum RS, Anderson ZS, Masjedi AD, et al.: Obstetric outcomes of women with congenital uterine anomalies in the United States. Am J Obstet Gynecol MFM. 2024, 6:101396. 10.1016/j.ajogmf.2024.101396
3. Ulfsdottir H, Åberg K, Jonsson M, Ekéus C: Pregnancy outcomes in women with uterine anomaly: a Swedish nationwide cohort study. J Matern Fetal Neonatal Med. 2026, 39:2690755. 10.1080/14767058.2026.2690755
4. Ćwiertnia A, Borzyszkowska D, Golara A, et al.: The impact of uterus didelphys on fertility and pregnancy . Int J Environ Res Public Health. 2022, 19:10.3390/ijerph191710571
5. Tuştaş Haberal E, Çekmez Y, Ulu İ, Divlek R, Göçmen A: Placenta percreta with concomitant uterine didelphys at 18 weeks of pregnancy: a case report and review of the literature. J Matern Fetal Neonatal Med. 2016, 29:3445-8. 10.3109/14767058.2015.1130819
6. Hornová M, Žižka Z, Přáda J, Fanta M: Successful pregnancy in a conserved uterus following hemi-hysterectomy in a case of uterus didelphys. Ceska Gynekol. 2024, 89:391-5. 10.48095/cccg2024391
7. Muraoka A, Tsuda H, Kotani T, Kikkawa F: Severe hemoperitoneum during pregnancy with obstructed hemivagina and ipsilateral renal anomaly syndrome: a case report. J Reprod Med. 2016, 61:290-4.
8. Shi L, Lin X, Sha S, Yao L, Zhu X, Shao Y: Delayed presentation of uterine rupture in a didelphys uterus misdiagnosed as appendicitis: a case report and review of the literature. Arch Gynecol Obstet. 2017, 296:1015-6. 10.1007/s00404-017-4522-6
9. Soh EB, Lim JM: An unusual cause of antepartum haemorrhage . Aust N Z J Obstet Gynaecol. 1999, 39:389-90. 10.1111/j.1479-828x.1999.tb03428.x
10. Tsegaye MA, Mekonnen ZA, Lemma DT, Adugna AN, Tesfay RH: Second-trimester uterine rupture in bicornuate uterus: a case report. Case Rep Womens Health. 2025, 45:e00676. 10.1016/j.crwh.2024.e00676
11. Woolcock Martinez H, Haghighi N, Booker WA: Di-cavitary twin pregnancy in didelphys uterus with associated renal agenesis. AJP Rep. 2025, 15:e53-7. 10.1055/a-2562-1607