Cureus
Part of SPRINGER NATURE

Open Access Case Report

Published via University of Louisville Neurosurgery

Modified Kraske Approach to Posterior Sacrectomy for Recurrent Rectal Adenocarcinoma With Sacral Involvement: An Illustrative Case

Andrea Becerril-Gaitan [1], Aashka Sheth [2], Samer Al-Quran [3], Dale Ding [1], Nicholas Dietz [1], Brian J. Williams [1]

1. Neurosurgery, University of Louisville Hospital, Louisville, USA 2. Neurosurgery, University of Louisville School of Medicine, Louisville, USA 3. Pathology, University of Louisville Hospital, Louisville, USA

Corresponding author: Andrea Becerril-Gaitan, andrea.becerrilgaitan@louisville.edu

Received 10/22/2026
Review began 10/25/2026
Review ended 11/19/2026
Published 11/23/2026

© Copyright 2026
Becerril-Gaitan et al. This is an open access article distributed under the terms of the Creative Commons Attribution License CC-BY 4.0., which permits unrestricted use, distribution, and reproduction in any medium, provided the original author and source are credited.

DOI: 10.7759/cureus.120147

Abstract

Sacral involvement in recurrent rectal adenocarcinoma presents a complex surgical challenge that often requires multidisciplinary management and complex reconstruction. We present a 74-year-old man with a history of T3N2 metastatic rectal adenocarcinoma who presented for surgical intervention for local recurrence with sacral involvement extending to the presacral space. Preoperative imaging demonstrated a 5.9 x 6.3 x 4.9 cm presacral soft tissue mass invading the lower sacrum at the S3 segment and extending through the seminal vesicles and posterior bladder wall. Sacrectomy at S3 with a modified posterior Kraske approach was performed to truncate the tumor specimen for safe gross-total resection. Postoperatively, the patient returned to baseline functional mobility without new neurological deficits. Surgical intervention for carefully selected patients with recurrent colorectal cancer and sacral involvement may be achieved through a posterior modified Kraske approach with subsequent anterior reconstruction. Patient selection and multidisciplinary planning are essential for achieving meaningful local control while preserving postoperative function.

Categories: Neurosurgery
Keywords: modified kraske, partial sacrectomy, rectal adenocarcinoma, sacral metastasis, sacral tumor, spinal oncology

Introduction

Sacral tumors are relatively uncommon, accounting for 1-7% of all primary spinal tumors, with most tumors being secondary to metastatic disease [1]. Locally recurrent rectal adenocarcinoma (LRRC) involving the sacrum poses a significant surgical challenge, particularly in patients who have undergone previous pelvic surgery, radiation therapy, or systemic treatment [2,3].

En bloc resection with negative margins is associated with the lowest local recurrence rates, whereas intralesional resection has an 83% recurrence rate, compared with 5-60% following wide-margin resection for malignant lesions [4-7]. Although total sacrectomy with extensive resection is associated with prolonged survival time, this method encompasses a higher risk of injury to surrounding structures, such as ureters, nerves, blood vessels, and parts of the intestine, as well as a higher risk of pelvic instability and wound complications [8,9]. Selection of the surgical approach is based on tumor location and extent of disease. While the anterior approach is usually indicated for tumors above S4 without nerve involvement, as it allows identification and proper exposure of important structures such as anterior blood vessels and the rectum, it provides limited access for nerve root dissection and sacral osteotomy. In contrast, a posterior approach allows direct access to the sacrum but requires extensive dissection to separate the tumor from the rectum, lateral soft tissue, and ligamentous attachments. The modified Kraske procedure, which consists of a posterior mid sacrectomy with coccygectomy, allows en bloc tumor resection with wide tumor-free margins [10-12]. However, this approach is associated with longer operative exposure and higher rates of wound-related complications, including dehiscence, infection, and delayed healing [11,12]. Therefore, combined anteroposterior approaches are often used to achieve complete tumor resection while minimizing operative morbidity.

We present a case of LRRC with sacral invasion managed through a modified posterior Kraske approach with multidisciplinary anterior reconstruction.

Case Presentation

A 74-year-old man with a history of T3N2 rectal adenocarcinoma diagnosed eight years prior presented for surgical intervention for local recurrence with presacral involvement. The patient's prior oncology history was significant for abdominoperineal resection with permanent colostomy, followed by adjuvant chemoradiation and FOLFOX (folinic acid (leucovorin), fluorouracil, and oxaliplatin) therapy. Presacral recurrence was noted three years earlier and was treated with additional chemotherapy. One year before

presentation, pulmonary metastases were identified and treated with wedge resection. Given progression of the presacral mass and bladder involvement, the patient was started on FOLFIRI (folinic acid (leucovorin), fluorouracil, and irinotecan); however, only a subtle response was observed after six cycles. Follow-up imaging four months before surgery demonstrated only a slight size decrease of the presacral mass (Figure *1*), which was deemed amenable to resection. The patient was subsequently referred to neurosurgery for evaluation and multidisciplinary surgical planning.

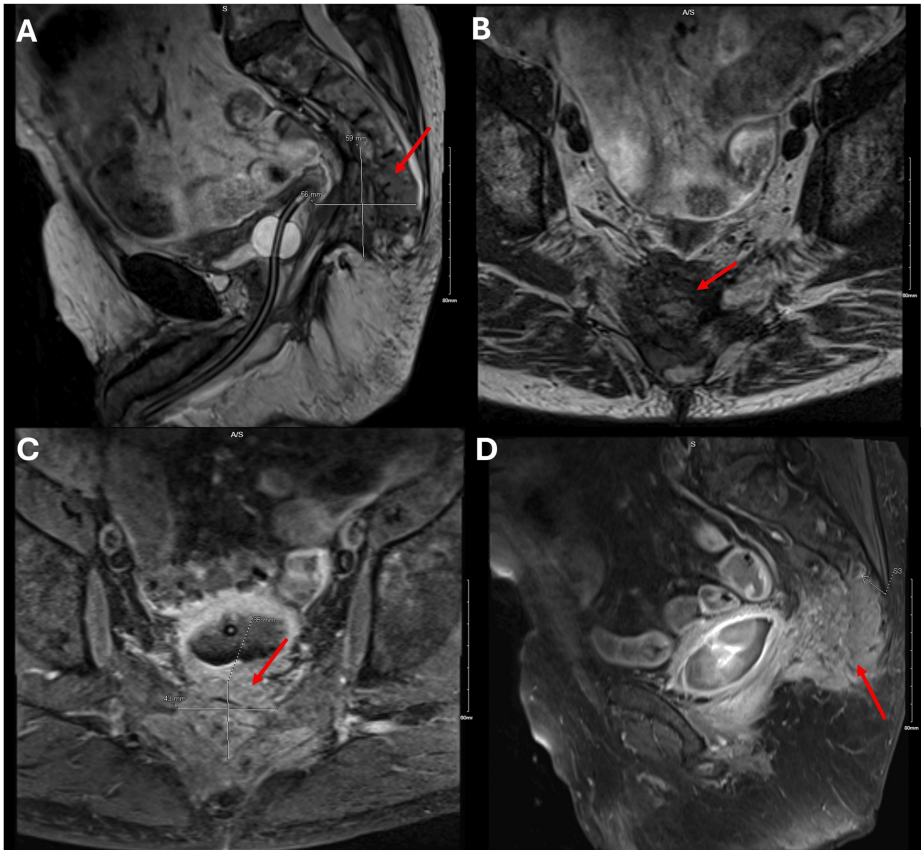

FIGURE 1: Magnetic resonance imaging (MRI) of the pelvis without and with contrast.

T2 sagittal and axial (panels A and B, respectively) of the abdomen/pelvis without contrast demonstrating a large mass (red arrow) in the presacral space with invasion of the lower sacrum at the S4 segment and caudally. T1 axial and sagittal (panels C and D, respectively) of the abdomen/pelvis with contrast showing a 4.3 x 7.3 x 6.3 cm mass (red arrow) with invasion of the lower sacrum and extension through the seminal vesicles into the posterior bladder wall. Presence of abnormal enhancement of the bilateral ischial coccygeal muscles, concerning for involvement (panel C).

On initial evaluation, the patient had no focal weakness or sensory changes on exam, but he reported chronic erectile and bladder dysfunction requiring long-term indwelling Foley catheter placement. His Karnofsky performance score was 90 preoperatively. Computed tomography (CT) of the pelvis, completed two months after initial MRI, demonstrated a 5.9 x 6.3 x 4.9 cm presacral soft tissue mass invading the lower sacrum at the S4 segment, extending caudally and through the seminal vesicles into the posterior bladder wall (Figure *2*, panels A-B).

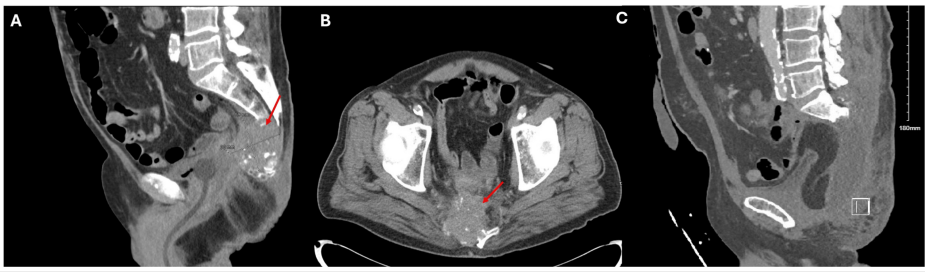

FIGURE 2: Pre- and post-operative computed tomography (CT) of the abdomen and pelvis.

Sagittal abdomen/pelvis CT with contrast demonstrates a soft tissue mass with calcifications in the posterior pelvis measuring 5.9 x 6.3 x 4.9 cm (panel A, red arrow). Axial abdomen/pelvis CT with contrast shows invasion of the sacrum at the S4 segment and absence of tissue planes between the sacral mass (red arrow) and the posterior wall of the bladder (panel B). Post-operative CT without contrast demonstrates complete absence of large portions of the sacrum as well as the entire coccyx, with bony destructive changes of the residual sacrum below the level of S1 noted (panel C).

After multidisciplinary discussion, the patient presented for an elective posterior sacrectomy followed by pelvic exenteration, small bowel resection with isoperistaltic anastomosis, ileal conduit creation, and myocutaneous flap reconstruction. A modified posterior Kraske approach was used for the sacrectomy. The patient was flipped into the prone position with all pressure points padded appropriately. A dorsal longitudinal midline incision extending from the lumbosacral junction to the coccyx was made. The spinous processes were dissected, exposing the lateral aspect of the sacrum and inferiorly to the tip of the coccyx. Intraoperative X-rays were then obtained to identify the L5-S1 level. The bone of the S1 lamina was thinned using a high-speed drill, and the epidural plane was dissected from the bone. The S2 nerve roots were identified, and the foramen was exposed and unroofed. Circumferential dissection was performed around the thecal sac below the S2 nerves, and the thecal sac was then tied off and sharply cut. The ventral epidural plexus was cauterized. A half-inch osteotome was used to incise the area of the sacrum with tumor involvement below the S2 nerve roots. Gross tumor was encountered within the sacrum. At this stage, the decision was made to truncate the tumor specimen due to concerns regarding safe transplevic delivery. The ventral sacrum was dissected, and the anterior attachments of the sacrum were disarticulated, while carefully protecting the S2 nerves. The tumor was removed predominantly as a single large specimen. The resection cavity was inspected, confirming no gross residual tumor. Hemostasis was achieved, and the wound was irrigated with an antibiotic solution. The inferior aspect of the incision was left open for subsequent colorectal access and completion of the surgical plan.

Following completion of the sacrectomy, the patient was repositioned into lithotomy, and a midline abdominal incision was made. Colorectal Surgery and Urology proceeded with the creation of an ileal conduit, parastomal hernia repair, and ventral rectus muscle flap creation. Estimated blood loss was 6 L with a total surgical time of 11 hours.

Histopathological examination of the sacral mass was positive for metastatic adenocarcinoma (Figure *3*). Metastatic adenocarcinoma with focal osseous metaplasia was identified in the bladder, prostate, and seminal vesicles. A biopsy of the right pelvic wall was also positive for metastatic adenocarcinoma.

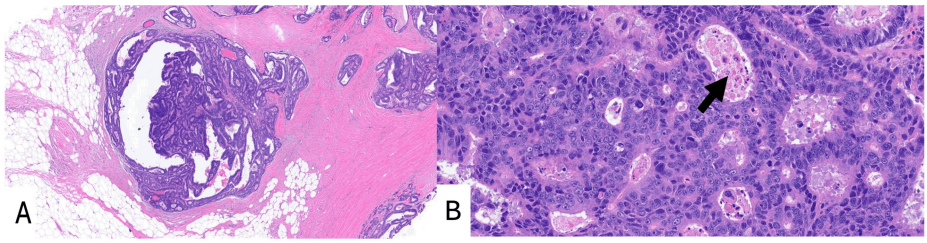

FIGURE 3: Histopathological examination of the sacral mass.

Hematoxylin and eosin (H&E)-stained sections from the sacrum demonstrate fibroadipose tissue infiltrated by metastatic adenocarcinoma (panel A, ×5). High-power magnification reveals a cribriform glandular architecture with central dirty necrosis (black arrow) (panel B, ×40), characteristic of colorectal adenocarcinoma.

Postoperatively, the patient remained intubated and was admitted to the intensive care unit due to prolonged surgical time, vasopressor requirements, and the need for massive transfusion protocol with 10

packed red blood cells, 10 units of fresh frozen plasma, and 2 units of platelets intraoperatively. The patient was successfully extubated on postoperative Day 4. His clinical condition continued to improve, and he was discharged home 14 days after surgery. At one-month follow-up, he was ambulating with a walker and recovering without new neurological deficits. Outpatient physical therapy was recommended to assist in regaining strength and mobility. The patient's surveillance CT three months after surgery (Figure *2*, panel C) demonstrated complete absence of large portions of the sacrum and the entire coccyx. Clinically, the patient had reported significant improvement in pain and ambulatory capacity.

At nine-month follow-up, the patient reported worsening pelvic and sacral pain, accompanied by difficulty tolerating prolonged sitting. An increase in circulating tumor DNA (ctDNA) prompted further evaluation with a PET/CT, which demonstrated findings concerning for recurrent pelvic disease. Given these findings and the patient's worsening symptoms, palliative systemic therapy was initiated, which he continues to tolerate.

Discussion

Locally recurrent rectal adenocarcinoma with sacral invasion presents a significant clinical challenge, particularly in patients who have undergone prior pelvic surgery, radiotherapy, or other systemic treatments [2,5]. Although surgery is usually reserved for primary sacral tumors, carefully selected patients with metastatic or recurrent pelvic malignancies may benefit from surgical resection. In the present case, the patient had progressive presacral disease despite chemotherapy but maintained a high functional status, which supported the consideration of an operative intervention despite a history of metastatic disease.

Surgical management of sacral tumors requires multidisciplinary planning, often with oncology, radiation oncology, neurosurgery, colorectal surgery, and plastic surgery to determine the optimal treatment approach and reconstructive surgical strategy [13]. Sacrectomies are rare and technically challenging because these lesions are often diagnosed at advanced stages and present as large masses with poorly defined margins, frequently invading neural, visceral, and vascular structures [10]. Additionally, prior pelvic surgeries and radiotherapy increase surgical complexity by distorting tissue planes and increasing the risk of wound-related complications. These factors require individualized surgical planning to balance oncologic goals with preservation of function and overall quality of life.

The extent of sacral and presacral involvement is key in determining surgical approach. Total sacrectomies (i.e., combined anteroposterior) are recommended for tumors extending above and below S4, where the anterior approach allows for the tumor to be carefully dissected from the rectum and internal iliac vessels. In contrast, the posterior approach allows tumor removal with increased stability [13,14]. In contrast, posterior-only approaches may provide adequate exposure for selected lower sacral lesions while avoiding the morbidity associated with an initial anterior dissection [14]. In this patient, tumor invasion was mainly at the S4 level, allowing a posterior sacrectomy approach with preservation of bilateral S2 nerves.

Historically, the Kraske operation described in 1885 was used to access mid-rectal and low rectal cancers, consisting of a posterior trans-sacral approach to the presacral space with the possibility of low sacral/coccyx bone resection to facilitate access to the underlying pathology [13,15]. The modified Kraske technique comprises a larger posterior corridor and osteotomy with partial sacrectomy to treat locally osteodestructive sacral tumors with extension to the presacral space while minimizing associated morbidity [10,11]. In the present case, the modified Kraske approach was pursued with exposure of the sacrum through a dorsal midline approach that allowed skeletonization of S2 nerve roots, ligation of the thecal sac below this level, and controlled osteotomies through the involved sacrum at S3 [10,14-16]. This modified procedure provides a targeted sacral resection with neoplastic-appropriate margins while limiting unnecessary disruption of uninvolved sacral structures. Although en bloc resection remains the preferred oncologic approach, recurrent tumors within a previously treated pelvis present a substantial anatomical challenge. Intraoperative findings and concerns regarding safe posterior transpelvic delivery of the specimen prompted a modification of the planned resection to prevent a higher risk of vascular, visceral, or neurological injury.

A key technical consideration during sacrectomy is sacral nerve root preservation when feasible. Functional outcomes following surgery are strongly influenced by the level of nerve root sacrifice, with preservation of at least one S2 nerve root associated with improved bowel and bladder function [13,17]. Although this patient had preexisting bladder and erectile dysfunction, preservation of bilateral S2 nerve roots was prioritized to maximize postoperative independence and functional mobility.

Sacrectomy is associated with considerable peri- and post-operative morbidity; the present case illustrates these challenges, as this patient required transfusion, vasopressor support, and extended hospital stay. Generally, postoperative considerations include bed rest to allow for wound stabilization, scar formation, and decreased risk of pelvic instability. Traditionally, sacrectomy is complicated by reoperation in 5.8-27% of cases due to hardware failures or anatomical complications [18]. In addition, infection rates have been reported to be up to 27% within the first 30 days postoperatively when flap reconstruction is performed [18]. Despite the complexity of his postoperative course, the patient demonstrated progressive functional recovery, with improved pain and ambulatory capacity during early follow-up and no new neurologic

deficits.

However, this case also highlights the limitations of surgical resection in the management of aggressive and locally recurrent tumors. For instance, despite extensive surgical resection, the patient in this case developed worsening pain and was found to have recurrent disease within nine months. Although achieving complete resection remains an important objective, long-term outcomes are also influenced by tumor biology and the effectiveness of systemic disease control. Further investigation into patient selection, tumor biology, and the optimal sequencing of local and systemic therapies is needed to improve long-term outcomes for this challenging patient population.

Conclusions

This case highlights the challenges of managing locally recurrent rectal adenocarcinoma involving the sacrum in a patient who had already undergone multiple prior treatments. The modified Kraske approach provides direct posterior exposure of the involved sacrum while allowing sequential identification of the sacral canal and bilateral S2 nerve roots before completion of S3 osteotomies. Although en bloc resection remains the preferred oncologic objective, intraoperative modification of the surgical plan may be necessary to adapt to patient anatomy. This case demonstrated the technical feasibility of a modified posterior approach and the potential for meaningful early recovery. However, subsequent disease recurrence highlights the limitations of surgical resection alone in managing aggressive recurrent disease. Careful patient selection, multidisciplinary planning, and continued advances in multimodal treatments remain essential for improving functional and long-term oncologic outcomes.

Additional Information

Author Contributions

All authors have reviewed the final version to be published and agreed to be accountable for all aspects of the work.

Concept and design: Andrea Becerril-Gaitan, Dale Ding, Nicholas Dietz, Aashka Sheth, Brian J. Williams, Samer Al-Quran

Acquisition, analysis, or interpretation of data: Andrea Becerril-Gaitan, Nicholas Dietz

Drafting of the manuscript: Andrea Becerril-Gaitan, Aashka Sheth

Critical review of the manuscript for important intellectual content: Andrea Becerril-Gaitan, Dale Ding, Nicholas Dietz, Aashka Sheth, Brian J. Williams, Samer Al-Quran

Supervision: Brian J. Williams

Disclosures

Human subjects: Informed consent for treatment and open access publication was obtained or waived by all participants in this study. **Conflicts of interest:** In compliance with the ICMJE uniform disclosure form, all authors declare the following: **Payment/services info:** All authors have declared that no financial support was received from any organization for the submitted work. **Financial relationships:** All authors have declared that they have no financial relationships at present or within the previous three years with any organizations that might have an interest in the submitted work. **Other relationships:** All authors have declared that there are no other relationships or activities that could appear to have influenced the submitted work.

References

1. Cini C, Asunis E, Griffoni C, et al.: Surgical management of sacral bone tumors: a retrospective analysis of outcomes, complications, and survival. Diagnostics (Basel). 2025, 15:917. 10.3390/diagnostics15070917
2. Kim KR, Kim KH, Park JY, et al.: Surgical strategy for sacral tumor resection. Yonsei Med J. 2021, 62:59-67. 10.3349/ymj.2021.62.1.59
3. Pendharkar AV, Ho AL, Sussman ES, Desai A: Surgical management of sacral chordomas: illustrative cases and current management paradigms. Cureus. 2015, 7:e301. 10.7759/cureus.301
4. Phang ZH, Saw XY, Nor NF, Ahmad ZB, Ibrahim SB: Rare case of neglected large sacral chordoma in a young female treated by wide en bloc resection and sacrectomy. BMC Cancer. 2018, 18:1112. 10.1186/s12885-018-5012-3
5. Fiani B, Runnels J, Rose A, Kondilis A, Wong A, Musch BL: Clinical manifestations, classification, and surgical management of sacral tumors and the need for personalized approach to sacrectomy. Surg Neurol Int. 2021, 12:209. 10.25259/SNI_133_2021
6. Schroeder C, de Lomba WC, Leary OP, et al.: Multidisciplinary surgical considerations for en bloc resection of sacral chordoma: review of recent advances and a contemporary single-center series. Neurosurg Focus. 2024, 56:E7. 10.3171/2024.2.FOCUS23926

7. Zang J, Guo W, Yang R, Tang X, Li D: Is total en bloc sacrectomy using a posterior-only approach feasible and safe for patients with malignant sacral tumors?. J Neurosurg Spine. 2015, 22:563-70. 10.3171/2015.1.SPINE14237
8. Pu F, Zhang Z, Wang B, Wu Q, Liu J, Shao Z: Total sacrectomy with a combined antero-posterior surgical approach for malignant sacral tumours. Int Orthop. 2021, 45:1347-54. 10.1007/s00264-021-05006-4
9. Branco E Silva M, Branco E Silva M, Conceição Maia Martins S, Voltan Garofo K, Eduardo Hideo Hanasilo C, Etchebehere M: Analysis of morbidity and mortality in patients with primary bone tumors who underwent sacrectomy: a systematic review. J Bone Oncol. 2022, 35:100445. 10.1016/j.jbo.2022.100445
10. Gonçalves VM, Lima A, Gíria J, Carvalho N, Parreira J, Cunha E Sá M: Modified kraske procedure with mid-sacrectomy and coccygectomy for en bloc excision of sacral giant cell tumors. Case Rep Surg. 2014, 2014:834537. 10.1155/2014/834537
11. Sweeney WB, Deshmukh N: Modified Kraske approach for disease of the mid-rectum . Am J Gastroenterol. 1991, 86:75-8.
12. Ghellal A, Trilling B, Faucheron JL: The Kraske procedure: no more indications for benign lesions? . Tech Coloproctol. 2019, 23:607-8. 10.1007/s10151-019-02005-x
13. Aranda-Narváez JM, González-Sánchez AJ, Montiel-Casado C, Sánchez-Pérez B, Jiménez-Mazure C, Valle-Carbajo M, Santoyo-Santoyo J: Posterior approach (Kraske procedure) for surgical treatment of presacral tumors. World J Gastrointest Surg. 2012, 4:126-30.
14. Farrokhi MR, Nouraei H, Hosseini SV, et al.: Sacrectomy with posterior-only approach in sacral tumors: an analysis of 26 cases and review of literature. World Neurosurg. 2023, 179:e288-95. 10.1016/j.wneu.2023.08.078
15. Aubert M, Mege D: Kraske approach to retrorectal tumors: surgical technique . J Visc Surg. 2022, 159:229-33. 10.1016/j.jviscsurg.2022.01.009
16. Onaitis M, Ludwig K, Perez-Tamayo A, et al.: The Kraske procedure: a critical analysis of a surgical approach for mid-rectal lesions. J Surg Oncol. 2006, 94:194-202. 10.1002/jso.20591
17. Zileli M, Hoscoskun C, Brastianos P, Sabah D: Surgical treatment of primary sacral tumors: complications associated with sacrectomy. Neurosurg Focus. 2003, 15:E9.
18. Bulut H, Ozkan K: Complications and clinical outcomes of oncologic Sacrectomy: a systematic review and meta-analysis. J Orthop. 2026, 71:252-8. 10.1016/j.jor.2025.10.006