Cureus
Part of SPRINGER NATURE

Open Access Case Report

# Scabies Surrepticius Presenting As Psoriasiform Dermatitis

Emelyn A. Dizon [1], Philip R. Cohen [2, 1]

1. Dermatology, Touro University California, Vallejo, USA 2. Dermatology, University of California Davis Medical Center, Sacramento, USA

**Corresponding author:** Emelyn A. Dizon, edizon@student.touro.edu

**Review began** 11/07/2026
**Review ended** 11/20/2026
**Published** 11/23/2026

© **Copyright** 2026
Dizon et al. This is an open access article distributed under the terms of the Creative Commons Attribution License CC-BY 4.0., which permits unrestricted use, distribution, and reproduction in any medium, provided the original author and source are credited.

**DOI:** 10.7759/cureus.120144

## Abstract

Scabies is a highly contagious parasitic dermatologic condition caused by the mite *Sarcoptes scabiei* var. *hominis*. It commonly presents with pruritic, erythematous burrows at the sites of skin invasion; however, atypical lesions may occur, a presentation referred to as scabies surrepticius. A 77-year-old man with multiple medical comorbidities presented with persistent pruritus and new lesions resembling psoriasiform dermatitis on his abdomen, back, arms, and legs after a prolonged hospitalization. His symptoms were initially attributed to uremic pruritus; however, scabies was suspected, and he was started on empiric topical therapy with permethrin 5% cream. His lesions persisted after treatment with topical antiscabetic therapy; this may have resulted from improper application of the medication. Shortly after the patient developed symptoms, his sister began to develop similar pruritic lesions. Scabies was strongly suspected based on the sister's development of similar symptoms and lesions; scabies infestation was confirmed by identifying mites in mineral oil preparations from multiple lesions. The patient also acquired a secondary *Staphylococcus aureus* infection, which presented as a purulent abscess on his right breast. Both the scabies infestation and bacterial infection were successfully treated with systemic agents, including ivermectin for the mite infestation and doxycycline for the bacterial infection. His sister also received oral ivermectin; her symptoms and skin lesions resolved. In summary, scabies surrepticius is a term used to classify scabies infestations with atypical clinical presentations. Inaccurate diagnosis and delayed treatment can lead to secondary complications and necessitate prolonged therapy, as seen in this patient. Accurate diagnosis of scabies can be challenging because of its varied clinical presentations; however, a definitive diagnosis can be confirmed by identifying mites, scybala (fecal pellets), or eggs. Based on this patient's unique presentation, scabies presenting as psoriasiform dermatitis may be considered a morphologic variant of scabies surrepticius.

**Categories:** Family/General Practice, Infectious Disease, Dermatology
**Keywords:** abscess, dermatitis, ivermectin, mineral oil, mite, pruritus, psoriasis, scabies, scybala, surrepticius

## Introduction

*Sarcoptes scabiei* var. *hominis* causes scabies in humans. Infestation classically presents with extreme pruritus and burrows where the mite has invaded; lesions are typically found below the neck. Management may include topical therapy, systemic therapy, or both [1].

Scabies surrepticius describes variants of scabies that present with atypical morphology and lesion patterns; thus, the clinical manifestations of scabies surrepticius can masquerade as many other dermatological conditions or even systemic diseases [2]. Scabies diagnosis is classified into three levels of diagnostic certainty. A definitive diagnosis of scabies infestation is made by visualizing either the mite, its eggs, or its feces. Clinical and suspected diagnoses of mite infestation depend on the patient's history and clinical findings [1].

The non-classic appearance of scabies surrepticius can make the infestation more difficult to diagnose accurately. Diagnostic difficulties may be particularly pronounced in immunocompromised patients. In some patients, the diagnosis of scabies is delayed; in these individuals, secondary complications can arise, and management may require prolonged treatment [3].

This report describes the unique clinical manifestations of scabies in an immunocompromised older man who developed symptoms of scabies during hospitalization. His skin lesions presented as psoriasiform dermatitis, and his symptoms were initially attributed to uremic pruritus. His clinical course included persistent infestation after topical antiscabetic therapy and the development of an infestation-related bacterial infection. His sister, who arrived to assist in his care, also developed pruritic skin lesions. The man's scabies infestation was successfully treated with a prolonged course of oral therapy; his secondary bacterial infection resolved after a course of oral antibiotics. It is important to emphasize that once scabies is suspected, obtaining a definitive diagnosis should be prioritized; additionally, initiating appropriate systemic treatment should not be delayed after topical antiscabetic therapies are ineffective.

**How to cite this article**
Dizon E A, Cohen P R (November 23, 2026) Scabies Surrepticius Presenting As Psoriasiform Dermatitis. Cureus 18(11): e120144. DOI 10.7759/cureus.120144

## Case Presentation

A 77-year-old man presented with worsening pruritus, diffuse skin lesions, and an abscess on the right breast. The patient was hospitalized for four months due to COVID-19. During his hospitalization, he developed generalized itching and skin lesions. After discharge, he developed a skin infection involving his right breast.

His medical history was notable for atrial fibrillation, type 2 diabetes mellitus, and end-stage renal disease; he had no prior history of psoriasis or psoriasiform dermatitis. His current medications included apixaban, aspirin (enteric-coated), cetirizine, docusate, gabapentin, hydralazine, isosorbide mononitrate, metoprolol succinate (extended-release), pantoprazole, sevelamer, and sitagliptin. He received hemodialysis three times per week. His surgical history was notable for cardiac pacemaker implantation.

Initially, his itching was attributed to uremic pruritus. His symptoms persisted after hospital discharge, and he was evaluated by his primary care physician. He was empirically treated for scabies with permethrin 5% cream, which he applied to himself, and he also received topical triamcinolone acetonide 0.1% cream for symptom relief. His sister came to visit from Chile to help with his care after hospital discharge; she subsequently developed pruritus and new skin lesions on her hands and abdomen.

Cutaneous examination showed psoriasiform erythematous plaques covering over 80% of his body surface area, including the abdomen, chest, back, arms, and legs (Figure *1A*-*1B*); this clinical presentation was not typical for scabies. Burrows were present in the interdigital web spaces (Figure *2A*-*2B*). He had an abscess on his right breast; excoriated, crusted, lichenified plaques were also present around his dialysis port on the proximal left arm (Figure *3A*-*3B*). The man also had suprapubic and scrotal papules. A mineral oil preparation was performed at multiple locations. These included not only his interdigital web spaces but also his left anterior shoulder and left chest. Mineral oil preparations from all sampled sites revealed scabies mites (Figure *4*).

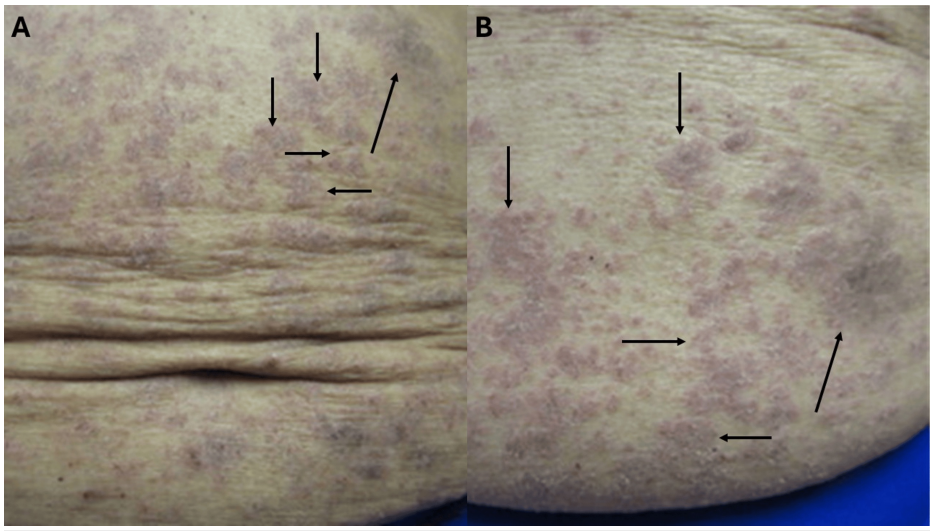


**FIGURE 1: Scabies surrepticius presenting as a psoriasiform dermatitis**

Distant (A) and close-up (B) views of psoriasiform lesions (black arrows) on the man's abdomen.

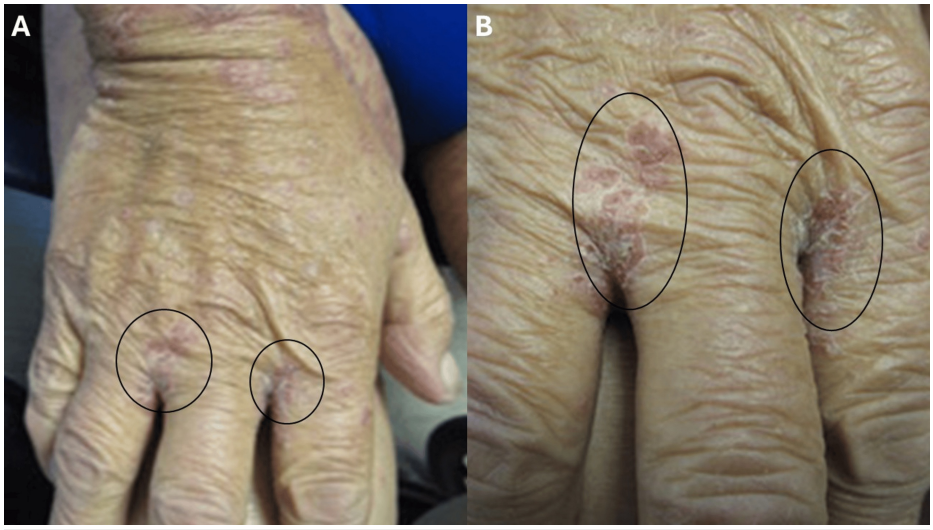


**FIGURE 2: Scabies mite burrows and mite infestation-related psoriasiform dermatitis of the interdigital web spaces on the man's right hand**

Distant (A) and close-up (B) views of the burrows and psoriasiform lesions on the web spaces (black ovals) between the second and third digits and between the third and fourth digits of the man's right hand.

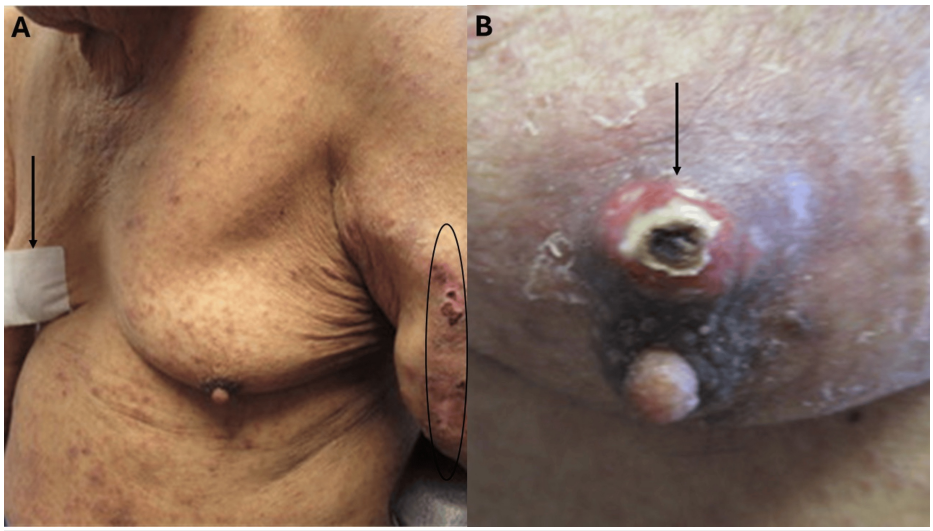


**FIGURE 3: Bacterial abscess on the right breast and crusted skin surrounding the hemodialysis port on the left arm**

Distant (A) and close-up (B) views of a *Staphylococcus aureus* abscess on the right breast. The patient initially presented with a bandage (black arrow) covering the abscess (A); the crusted, pus-draining abscess (black arrow) was readily observed after the bandage was removed (B). The skin surrounding his hemodialysis port (red oval) on the proximal left upper extremity was lichenified and crusted (A).



**FIGURE 4: Positive mineral oil preparation demonstrating a scabies mite**

A *Sarcoptes scabiei* mite (black arrow) and adjacent keratinocytes (red arrows) were observed on the mineral oil preparations from a burrow in the patient's interdigital web spaces. Additionally, mineral oil preparations from the man's plaques, which morphologically presented as psoriasiform dermatitis (on his left anterior shoulder and left chest), also showed similarly appearing mites.

The patient's scabies infestation was treated with oral ivermectin; the treatment dose was 200 micrograms per kilogram. The patient weighed 173 pounds (78 kilograms) and received a dose of 15 milligrams. The medication was available as 3-mg tablets; therefore, five tablets were administered per dose. He received a total of eight doses of the drug. Because a longer duration of treatment may be necessary in patients who are immunocompromised (such as this man with dialysis-dependent chronic renal disease) or have extensive and persistent mite infestations (such as this man with over 80% body surface area involvement for at least two months), the medication was administered on two consecutive days each week for four weeks. He was prescribed 15 milligrams of oral ivermectin, which he took on days 1, 2, 8, 9, 15, 16, 22, and 23.

Cutaneous examination of the patient's sister showed xerosis and fissures on her distal fingers (Figure *5A*-*5B*). She also had pruritic papules on her abdomen. Mineral oil preparation was negative for mites, scybala, and eggs after scraping her fingers and abdominal papules. Her clinical history and skin lesions were consistent with both scabies (based on the definitive diagnosis of mite infestation in her brother) and new-onset hand dermatitis (from repeatedly washing her hands while caring for her brother). She weighed 158 pounds (71 kilograms) and was also prescribed oral ivermectin at a dose of 15 milligrams following the same eight-dose treatment regimen as her brother.

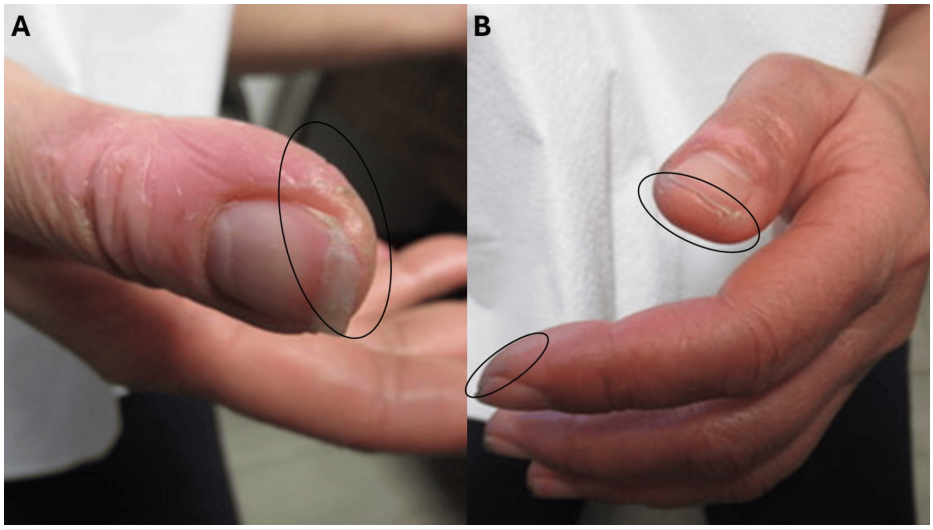


**FIGURE 5: Erythematous skin lesions consistent with hand dermatitis on the thumb and fingertips of the patient's sister**

The woman washed her hands multiple times each day after she began assisting with her brother's care. The right hand (A) and the left hand (B) show erythema of the distal digits with dryness and fissures (black ovals). Mineral oil preparations were negative for scabies mites, scybala, and eggs.

The man's right breast abscess was spontaneously draining, and a bacterial culture was performed. It grew *Staphylococcus aureus*. He was treated with doxycycline 100 milligrams twice daily for 30 days. The right breast abscess completely resolved. For symptomatic relief, he was also prescribed triamcinolone 0.1% ointment to apply twice daily. All of the man's skin lesions resolved, and he had no mites on subsequent follow-up visits. His sister's symptoms and skin lesions similarly resolved after treatment.

## Discussion

Scabies typically presents as burrows and papules on the skin. Lesions are usually found in the interdigital web spaces and on the umbilicus, nipples, areolae, and wrists [1]. Occasionally, nodules can be present on the scrotum or vulva; in some cases, these lesions contain mites, whereas in others, they represent a nonspecific reaction to the mite infestation [4].

Scabies surrepticius is characterized by various morphologic variants. The lesions may occur above the neck; they may be crusted or bullous, or they may mimic certain systemic conditions, including Langerhans cell histiocytosis and urticaria pigmentosa, particularly in newborns and infants [5]. Scabies surrepticius can also mimic other cutaneous diseases, including pityriasis rosea and psoriasis [6]. The patient's skin lesions had the morphologic appearance of psoriasiform dermatitis.

The scabies lesions in this report were unique in that they presented as well-demarcated, erythematous, scaly plaques that varied in size and clinically mimicked psoriasis; psoriasis is an autoimmune papulosquamous condition of the skin that can have associated systemic findings such as arthritis. Psoriasiform dermatitides are conditions characterized by a psoriasiform pattern of skin reactions and papulosquamous lesions that morphologically mimic psoriasis. In addition to these lesions, the man also had typical burrows and scrotal papules, which are characteristic of classic scabies. When scabies presents clinically as psoriasiform dermatitis, the histological features observed on microscopic evaluation of a lesion biopsy usually enable differentiation of psoriasiform dermatitides from a mite infestation [7].

The patient presented with severe pruritus that developed during his recent hospitalization. Although his pruritus was initially attributed to uremia, the possibility of scabies infestation was eventually considered. Although his symptoms and skin lesions did not resolve with topical antiscabetic therapy, his diagnosis of mite infestation was subsequently confirmed with a mineral oil preparation [8]. Because of our patient's atypical presentation of scabies, we categorized his mite infestation as scabies surrepticius.

The diagnosis of scabies infestation can be confirmed by observing mites, scybala, or eggs. During the patient's evaluation, a mineral oil preparation can be performed to attempt to establish the diagnosis. Alternatively, a skin biopsy can be performed to evaluate for mites in the stratum corneum. Other methods, depending on investigator expertise, can also be used, including dermoscopic examination [1].

Scabies is extremely contagious. Patients with crusted scabies can have hundreds of mites on their skin;

immunosuppressed patients can also have more mites present [9]. Given the man's scabies diagnosis confirmed by mineral oil preparation, his sister's pruritus and new skin lesions were epidemiologically consistent with scabies infestation. Although the mineral oil preparations of the sister's lesions were negative, she responded to antiscabetic therapy with complete resolution of her symptoms and skin lesions. Her hand dermatitis improved after decreasing the frequency of hand washing and applying moisturizing cream.

Treatment of scabies infestation can include topical therapy (such as permethrin cream or spinosad lotion) or systemic drugs [4,10]. Permethrin 5% cream can be applied from the neck to the toes overnight and washed off the following morning. The cream should be applied to all areas of the skin, including beneath the fingernails and toenails. Permethrin topical therapy is usually performed on day one and day eight of treatment [4].

Oral systemic therapy for scabies infestation can be used in both immunocompetent and immunosuppressed individuals. An individual treated with oral ivermectin is prescribed a dose of 200 micrograms per kilogram. Since ivermectin is not ovicidal, it is recommended that the patient receive ivermectin on two occasions, usually on day one and day eight of treatment. However, in some immunosuppressed patients or those with extensive and persistent infestations, a longer duration of treatment may be necessary, with the medication taken on days 1, 2, 8, 9, 15, 16, 22, and possibly 23 (or longer on consecutive days each subsequent week). Our patient was successfully treated with oral ivermectin for an extended period of therapy [4].

Scabies may be associated with complications, including secondary bacterial infections [11]. Bacterial infections may occur due to excessive itching caused by mite infestation, leading not only to secondary impetiginization but also to bona fide impetigo and abscesses, as in the reported patient. *Staphylococcus aureus* and *Streptococcus pyogenes* are the most common bacterial pathogens; therefore, prompt identification and treatment of scabies can prevent excessive pruritus, which can lead to secondary bacterial infection. These complications are more common in the pediatric age group; however, our elderly patient developed a *Staphylococcus aureus* skin abscess, which resolved after appropriate oral antibiotics [12].

## Conclusions

Scabies is a common condition typically presenting with pruritus and skin lesions. Although the lesions classically present as burrows in the skin, they can also present with alternative morphologies, making scabies more difficult to diagnose. In the latter situation, the condition may be referred to as scabies surrepticius. Topical therapy, systemic therapy, or both may be necessary for successful management, depending on the severity of the infestation. Scabies may be complicated by other conditions such as bacterial infection; in these circumstances, appropriate systemic antibiotic coverage may be warranted.

An immunocompromised man with scabies-associated lesions presenting as a psoriasiform dermatitis who acquired a secondary bacterial infection, as well as his sister who developed similar symptoms of pruritus and cutaneous lesions, is described in this report. Therefore, scabies should be considered in the differential diagnosis for those individuals presenting with a pruritic psoriasiform dermatitis. In summary, scabies is extremely contagious. The presence of similar skin lesions and pruritus in family members can strongly suggest scabies infestation. It is optimal to establish a definitive diagnosis of scabies. After confirmation of the diagnosis of scabies or when a clinical or suspected diagnosis of a mite infestation is considered appropriate, prompt treatment should be initiated to reduce the risk of secondary complications, minimize the need for prolonged treatment, and prevent further community spread.

## Additional Information

### Author Contributions

All authors have reviewed the final version to be published and agreed to be accountable for all aspects of the work.

**Concept and design:** Emelyn A. Dizon, Philip R. Cohen

**Acquisition, analysis, or interpretation of data:** Emelyn A. Dizon, Philip R. Cohen

**Drafting of the manuscript:** Emelyn A. Dizon, Philip R. Cohen

**Critical review of the manuscript for important intellectual content:** Emelyn A. Dizon, Philip R. Cohen

**Supervision:** Philip R. Cohen

### Disclosures

**Human subjects:** Informed consent for treatment and open access publication was obtained or waived by all participants in this study. **Conflicts of interest:** In compliance with the ICMJE uniform disclosure form, all

authors declare the following: **Payment/services info:** All authors have declared that no financial support was received from any organization for the submitted work. **Financial relationships:** All authors have declared that they have no financial relationships at present or within the previous three years with any organizations that might have an interest in the submitted work. **Associate Editor authorship:** Philip R. Cohen was an Associate Editor for the Cureus Journal of Medical Science at the time of submission. To minimize potential bias, this manuscript was handled independently by an alternate Associate Editor with no conflict of interest, and the author was blinded to and had no access to the peer review process, reviewer identities, or editorial decision-making for this submission. **Other relationships:** All authors have declared that there are no other relationships or activities that could appear to have influenced the submitted work.

## References

1. Engelman D, Yoshizumi J, Hay RJ, et al.: The 2020 International Alliance for the control of scabies consensus criteria for the diagnosis of scabies. Br J Dermatol. 2020, 183:808-20. 10.1111/bjd.18943
2. Cohen PR: Classic and non-classic (surrepticius) scabies: diagnostic and treatment considerations . Cureus. 2020, 12:7419. 10.7759/cureus.7419
3. Fernando DD, Mounsey KE, Bernigaud C, et al.: Scabies. Nat Rev Dis Primers. 2024, 10:74. 10.1038/s41572-024-00552-8
4. Uzun S, Durdu M, Yürekli A, et al.: Clinical practice guidelines for the diagnosis and treatment of scabies . Int J Dermatol. 2024, 63:1642-56. 10.1111/ijd.17327
5. Cohen PR, Crowley C, Erickson C, Calame A: Non-classic (surrepticius) Scabies presenting as erythematous painful palmar pustules in an octagenarian. Cureus. 2020, 12:9542. 10.7759/cureus.9542
6. Stiff KM, Cohen PR: Scabies surrepticius: scabies masquerading as pityriasis rosea . Cureus. 2017, 9:1961. 10.7759/cureus.1961
7. Fernandez-Figueras M, Puig L: Histopathological diagnosis of psoriasis and psoriasiform dermatitides . Diagn Histopathol. 2025, 31:87-97. 10.1016/j.mpdhp.2024.11.005
8. Kim DH, Kim Y, Yun SY, Yu HS, Ko HC, Kim M: Risk factors for scabies in hospital: a systematic review . BMC Infect Dis. 2024, 24:353. 10.1186/s12879-024-09167-6
9. El Yamani L, Hormi O, Zerrouki N, Zizi N: Crusted scabies mimicking psoriasis in a patient with Down syndrome: a case report. Cureus. 2026, 18:111106. 10.7759/cureus.111106
10. Ankad BS, Patil SR, Bansal DP: Spinosad 0.9% lotion for scabies on skin of color: an interventional study by polarized and UV-induced fluorescence dermoscopy. Cureus. 2026, 18:107968. 10.7759/cureus.107968
11. Iyengar L, Chong AH, Steer AC: Scabies: a clinical update . Med J Aust. 2024, 221:558-63. 10.5694/mja2.52505
12. Meena A, Arora K, Kumar S: Scabies with secondary impetiginization. Indian J Pediatr Dermatol. 2025, 26:297-98. 10.4103/ijpd.ijpd_17_25