Cureus
Part of SPRINGER NATURE

Open Access Case Report

Epignathus Caused by an Immature Teratoma With Rapid and Extensive Intracranial Extension: A Case Report

Review began 10/23/2026
Review ended 11/09/2026
Published 11/22/2026

© **Copyright** 2026
Miyagawa et al. This is an open access article distributed under the terms of the Creative Commons Attribution License CC-BY 4.0., which permits unrestricted use, distribution, and reproduction in any medium, provided the original author and source are credited.

DOI: 10.7759/cureus.120100

Kazunori Miyagawa [1], Shun Yasuda [2], Yuki Sato [3], Misa Sugeno [2], Ryo Matsuoka [4], Toma Fukuda [5], Akiko Yamaguchi [2], Rei Sekine [6], Erina Suzuki [6], Yuichiro Kiko [7], Yuko Hashimoto [6], Keiya Fujimori [2]

1. Obstetrics and Gynecology, Takeda General Hospital, Aizuwakamatsu, JPN 2. Obstetrics and Gynecology, Fukushima Medical University, Fukushima, JPN 3. Obstetrics and Gynecology, Shirakawa Kosei General Hospital, Shirakawa, JPN 4. Obstetrics and Gynecology, Iwase General Hospital, Sukagawa, JPN 5. Obstetrics and Gynecology, Ohta Nishinouchi Hospital, Koriyama, JPN 6. Diagnostic Pathology, Fukushima Medical University, Fukushima, JPN 7. Diagnostic Pathology, Takeda General Hospital, Aizuwakamatsu, JPN

Corresponding author: Shun Yasuda, room335@fmu.ac.jp

Abstract

Epignathus is a rare congenital tumor arising from the palate or pharyngeal region. Most epignathi are histologically mature teratomas, whereas cases caused by immature teratomas with extensive intracranial extension are exceptionally rare. We report a case of epignathus caused by an immature teratoma that showed rapid growth during the second half of pregnancy with extensive intracranial extension.

A 21-year-old primigravida was referred at 23 weeks of gestation after fetal ultrasonography identified an irregular mass in the left maxillary region. Serial ultrasonography and MRI demonstrated rapid tumor enlargement, progressive replacement of intracranial structures, and severe polyhydramnios. Although ex utero intrapartum treatment was considered, the extensive disruption of the normal brain architecture pointed to an extremely poor prognosis. The pregnancy was continued in accordance with the patient's wishes, and cesarean delivery was performed at 29 weeks and six days of gestation. The neonate died approximately two hours after birth. Histopathological examination confirmed an immature teratoma with immature neuroepithelial components.

In this case, serial prenatal imaging showed the tumor progressing from a localized mass to extensive replacement of the intracranial structures within approximately four weeks. This case highlights the importance of serial prenatal imaging, assessment of tumor extension patterns, and shared decision-making involving perinatal palliative care in severe fetal conditions.

Categories: Obstetrics/Gynecology, Radiology, Pathology
Keywords: epignathus, fetal mri, immature teratoma, intracranial extention, perinatal palliative care, prenatal diagnosis

Introduction

Epignathus is a rare congenital teratoma arising from the palate or pharyngeal region. Its incidence ranges from one in 35,000 to one in 200,000 live births, which makes it an exceptionally uncommon fetal condition [1,2]. Teratomas are germ cell tumors composed of tissues derived from more than one germ layer. They are classified as mature or immature depending on whether immature tissue components are present. In children, about two-thirds are mature, and one-third are immature [3]. Epignathus caused by an immature teratoma is rare, and high-grade forms are exceptionally rare [4,5]. Epignathus may grow rapidly, causing severe airway obstruction and feeding difficulties after birth [1,2]. When the tumor is confined to the oral cavity, survival may be achieved with perinatal airway management and surgical resection [2].

Intracranial extension of epignathus through the skull base has been reported only rarely and is generally associated with a poor prognosis [6]. Perinatal intracranial tumors may fill the entire cranial cavity, and their outcomes depend on tumor size, location, and resectability [7]. No survivors of epignathus with intracranial invasion have been reported [8]. Prenatal ultrasonography enables detection of epignathus, and fetal MRI is useful for evaluating extension through the skull base into the cranial cavity [8,9]. However, detailed descriptions of the growth patterns and extent of intracranial involvement remain limited. We report a rare case of epignathus caused by an immature teratoma that demonstrated rapid fetal growth and extensive intracranial extension. The rare histological subtype and unusual progression pattern make this case clinically and pathologically noteworthy.

Case Presentation

A 21-year-old primigravida (gravida 1, para 0; BMI 20.4 kg/m^2) was referred to our institution at 23 weeks and two days of gestation after fetal ultrasonography revealed an irregular mass in the left maxillary region.

She had no notable medical or family history, allergies, or medication use, and her spontaneously conceived pregnancy had progressed without complications. Fetal ultrasonography revealed a heterogeneous mass (approximately 34 mm) on the left orbital floor. Fetal MRI revealed that the left maxilla was replaced by a tumor (Figure *1a*). Based on these findings, epignathus was suspected, and the patient was referred to our department for further evaluation.

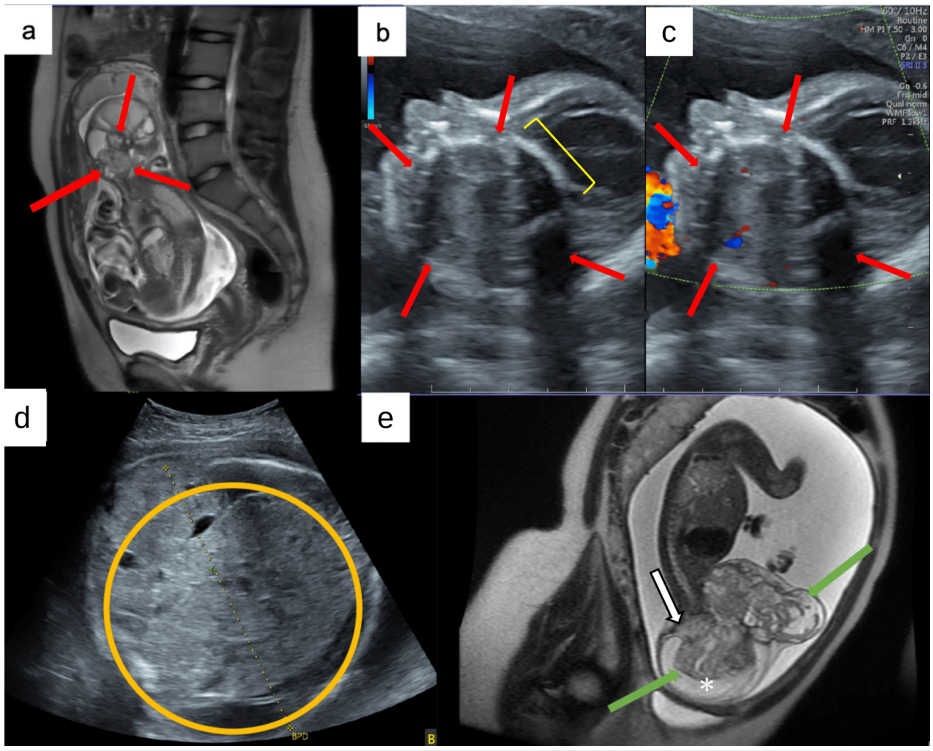

FIGURE 1: Fetal ultrasonography and fetal MRI findings

(a) Near-coronal T2-weighted SSFSE fetal MRI at 23 weeks and two days of gestation demonstrating a tumor replacing the left maxilla; the red arrows indicate the extent of the tumor, raising suspicion of epignathus. (b) Sagittal grayscale fetal ultrasonography at 24 weeks and one day of gestation showing the tumor occupying the region deep to the left cheek (red arrows indicate the extent of the tumor) and the skull base bone (yellow bracket); continuity of the skull base bone was preserved throughout the entire skull base on ultrasonographic examination, with no definite intracranial extension identified. (c) Sagittal color Doppler image of the same section obtained at the same examination as (b); the red arrows indicate the extent of the tumor. (d) Axial (transverse) fetal ultrasonography at 27 weeks and six days of gestation at the level of the BPD measurement showing marked tumor enlargement with intracranial extension; the intracranial space is largely occupied by a heterogeneous tumor, and normal brain structures could no longer be identified (yellow circle). (e) Sagittal T2-weighted SSFSE fetal MRI at 28 weeks and zero days of gestation demonstrating extensive intracranial extension of the tumor. The white arrow indicates the site where the tumor extends beyond the skull base, and the asterisk indicates the intracranial tumor; normal brain tissue can no longer be identified, and the intracranial space is occupied by tumor tissue. The green arrows indicate the extent of the tumor, including prominent extracranial protrusion from the facial region

MRI: magnetic resonance imaging; SSFSE: single-shot fast spin-echo; BPD: biparietal diameter

At 24 weeks and one day of gestation, the estimated fetal body weight (EFBW) was +1.09 standard deviations (SDs), and the biparietal diameter (BPD) was +1.18 SDs. Of the 65-mm BPD, 45 mm was occupied by the tumor component. The amniotic fluid index (AFI) was 19 cm, within the normal range. The tumor appeared localized, and protrusion into the pharyngeal cavity was suspected; however, ultrasonographic examination of the entire skull base showed preserved continuity of the skull base bone, and no definite intracranial extension was observed (Figures *1b*, *1c*). The family wished to pursue aggressive treatment, and ex utero intrapartum treatment (EXIT) was considered for airway management at delivery.

At 25 weeks and one day of gestation, the EFBW was +1.54 SDs, the BPD was +2.9 SDs (71.2 mm), and the AFI was 20.9 cm. At 27 weeks and six days of gestation, fetal ultrasonography demonstrated rapid tumor enlargement extending into the facial region and intracranial space. The brain parenchyma appeared replaced by tumor, with marked cranial expansion. Tumor extension toward the cervical region was observed, and severe polyhydramnios developed with an AFI of 40 cm (Figure *1d*). These findings suggested swallowing impairment attributable to mechanical airway obstruction and central dysfunction.

Subsequent fetal MRI at 28 weeks and zero days of gestation showed extensive intracranial tumor extension.

Given the marked disruption of normal brain structures, the prognosis was considered extremely poor, even if airway management was achieved using EXIT or tracheostomy. On T2-weighted fetal MRI at 23 weeks of gestation, the tumor was well-demarcated, and the normal brain architecture could be clearly distinguished from the epignathus. However, by 28 weeks, these previously distinct boundaries were no longer identifiable because of rapid tumor growth. Moreover, the rapid cranial enlargement and an irregularly shaped tumor protruding externally suggested that a vaginal delivery would be challenging (Figure *1e*). Nonetheless, the patient wished to continue the pregnancy.

Because severe polyhydramnios caused significant maternal discomfort, 1,400 mL of amniotic fluid was removed at 28 weeks. At 29 weeks and one day of gestation, the EFBW had markedly increased to +10.2 SDs (3,100 g), and the BPD had increased to +15.5 SDs (124 mm). Because these measurements included the tumor and the markedly deformed cranium, they should be interpreted with caution as indicators of fetal size; the actual birth weight was 2,784 g. After further discussion, the patient expressed a wish to proceed with the delivery and provide palliative care for the neonate. After multidisciplinary ethics review, a management plan consistent with the patient's wishes was adopted.

An emergency cesarean section was performed at 29 weeks and six days of gestation following spontaneous rupture of the membranes. A male infant weighing 2,784 g was delivered. Apgar scores were 2 at one minute (heart rate: 1; muscle tone: 1) and 1 at five minutes (heart rate: 1). Umbilical arterial blood gas analysis indicated a pH of 7.202. The neonate died approximately two hours after birth (Figures *2a*, *2b*). The maternal postoperative course was uneventful, and the patient was discharged on postoperative day four.

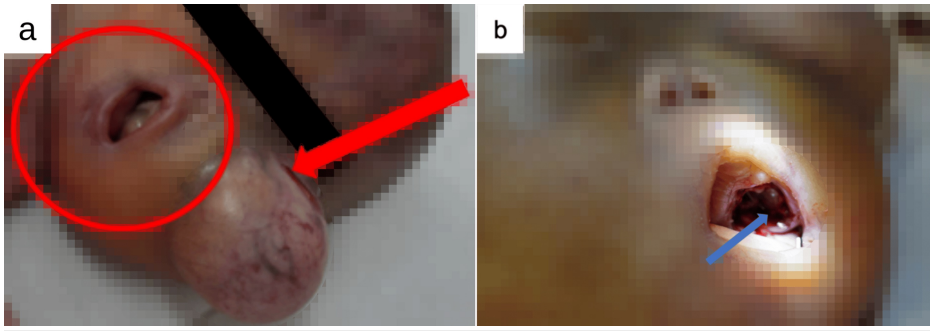

FIGURE 2: Photographs of the neonate after delivery

(a) Close-up view of the face showing a tumor extending to just beneath the skin of the left cheek (red arrow), with tumor exposure within the oral cavity (red circle) and from the left orbit. (b) Intraoral view (blue arrow) demonstrating the site where a biopsy was obtained with maternal consent

A full autopsy was not performed at the family's request. However, histopathological examination of tissue from the exposed portion of the tumor was conducted. The specimens contained components of the gastric foveolar epithelium, retina, cartilage, liver tissue, and neuroepithelium. Immature neuroepithelial components with mitotic figures were identified, and the tumor was diagnosed as an immature teratoma (Figures *3a*-*3f*). The chronological course of the imaging findings and clinical management is summarized in Table *1*.

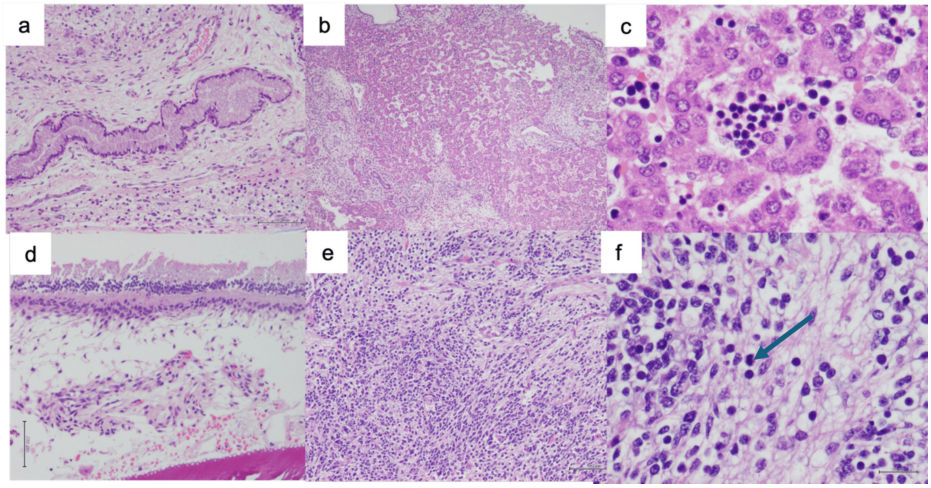

FIGURE 3: Histopathological findings of the biopsy specimens

(a) Gastric foveolar epithelium (H&E staining, ×40). (b) Hepatocytes (H&E staining, ×40). (c) Hepatocytes (H&E staining, ×100). (d) Retinal tissue (H&E staining, ×40). (e) Immature neuroepithelium (H&E staining, ×40). (f) Immature neuroepithelium with immature nerve cells showing nuclear division (blue arrow) (H&E staining, ×100)

H&E: hematoxylin and eosin

Gestational age	Examination	Findings/events
23 weeks 2 days	Ultrasonography; fetal MRI (near-coronal SSFSE)	Heterogeneous mass (approximately 34 mm) on the left orbital floor; tumor replacing the left maxilla; tumor well-demarcated from normal brain architecture
24 weeks 1 day	Ultrasonography (sagittal grayscale and color Doppler)	EFBW +1.09 SD; BPD 65 mm (+1.18 SD), 45 mm occupied by tumor; AFI 19 cm; continuity of the skull base bone preserved throughout the entire skull base on ultrasonography; no definite intracranial extension; EXIT considered
25 weeks 1 day	Ultrasonography	EFBW +1.54 SD; BPD 71.2 mm (+2.9 SD); AFI 20.9 cm
27 weeks 6 days	Ultrasonography (axial)	Rapid tumor enlargement into the facial region and intracranial space; normal brain structures no longer identifiable; extension toward the cervical region; AFI 40 cm
28 weeks 0 days	Fetal MRI (sagittal SSFSE)	Skull base destruction; extensive intracranial extension; external protrusion from the facial region
28 weeks	Amnioreduction	1,400 mL of amniotic fluid removed
29 weeks 1 day	Ultrasonography	EFBW 3,100 g (+10.2 SD); BPD 124 mm (+15.5 SD); measurements included the tumor
29 weeks 6 days	Emergency cesarean section	Spontaneous rupture of membranes; male infant, 2,784 g; Apgar scores 2 (1 minute) and 1 (5 minutes); umbilical arterial pH 7.202; neonatal death approximately two hours after birth

TABLE 1: Chronological summary of prenatal imaging findings and clinical course

MRI: magnetic resonance imaging; SSFSE: single-shot fast spin-echo; EFBW: estimated fetal body weight; SD: standard deviation; BPD: biparietal diameter; AFI: amniotic fluid index; EXIT: ex utero intrapartum treatment

Discussion

Epignathus is clinically significant primarily because it can cause critical airway obstruction at birth, and perinatal outcomes are strongly influenced by tumor size, growth rate, and direction of extension [8,10]. When the lesion is confined to the oral cavity or protrudes externally, survival may be achieved through appropriate airway management during delivery, followed by surgical excision [10,11]. Several case reports

have described favorable outcomes, including neonatal airway stabilization and tumor resection by conventional surgical approaches, advanced craniofacial reconstruction, or endoscopic skull base techniques [9,12-14]. These reports highlight that preservation of intracranial structures and complete tumor removal are critical determinants of prognosis.

Recent advances in fetal therapy have expanded the management options for selected cases of epignathus without intracranial involvement. Successful in utero tumor resection by operative fetoscopy has been reported in a case of oral teratoma without intracranial invasion [10]. Intrauterine laser coagulation of a rapidly growing epignathus and its feeding vessel has also been attempted; however, the tumor subsequently invaded the cranium, and the authors suggested that such treatment may be effective only in the absence of intracranial invasion [8]. These approaches are therefore limited to selected cases and are not applicable when extensive intracranial extension is present.

Intracranial involvement is a critical turning point in prognosis. Malignant or aggressive epignathus, including immature teratomas, is associated with markedly poorer outcomes even when postnatal surgical management is attempted [15]. In a review of 250 perinatal brain tumors, the overall survival rate was 28%, teratomas carried the worst prognosis, and outcome depended on tumor size, location, histological type, and resectability [7]. Antenatally diagnosed intracranial teratomas have also been reported to have poor outcomes [16].

Cases of epignathus with intracranial extension have been reported sporadically. Some reports have described antenatally diagnosed intracranial teratomas coexisting with oral or pharyngeal masses, often connected through the skull base [4,17]. Hosoda reported early cases in which epignathus was associated with intracranial teratomas, suggesting a shared developmental origin that frequently involves the sellar or parasellar region [17]. More recent case reports have described epignathus with intracranial extension but without direct invasion of the brain parenchyma. In these cases, the intracranial component was relatively small, encapsulated, or separated from functional brain tissue, and normal brain architecture was largely preserved [4,5,18]. Pellegrini et al. described an epignathus caused by a high-grade (grade 3) immature teratoma with destruction of the oropharynx and noted that such high-grade cases are exceptionally rare [5].

In contrast, in the present case, serial prenatal ultrasonography and MRI showed replacement of most of the intracranial contents and loss of normal brain structures during late gestation. Among previously reported cases of epignathus with intracranial extension, including giant lesions, near-total replacement of the normal intracranial architecture, as observed on imaging in the present case, has rarely been documented [5,8,18]. The case reported by Tavares de Sousa et al. is the most comparable to ours: an intracranial cystic structure appeared at 24 weeks and six days of gestation after laser coagulation at 16 weeks; MRI at 26 weeks and one day confirmed tumor invasion through the skull base, the pregnancy was terminated, and histopathological examination revealed an immature teratoma [8]. However, because a full autopsy was not performed in the present case and histopathological examination was limited to the exposed portion of the tumor, direct invasion of the brain parenchyma could not be confirmed histologically, and the extent of intracranial involvement was assessed by imaging alone.

The natural history of this case is noteworthy. The most striking feature was the rapid change in intracranial involvement over approximately four weeks: at 24 weeks and one day of gestation, the skull base was continuous, and no intracranial extension was observed; at 27 weeks and six days, normal brain structures could no longer be identified on ultrasonography; and at 28 weeks and zero days, MRI demonstrated destruction of the skull base with extensive intracranial extension. Many reported cases of epignathus with intracranial involvement, including the case reported by Tavares de Sousa et al., were diagnosed earlier in gestation and ended in termination of pregnancy, potentially before extensive brain destruction became apparent [4,5,8,17,18]. Continuation of pregnancy in this case allowed direct observation of rapid intracranial progression, providing rare insight into the evolution of disease in late gestation. These observations suggest that, in addition to histological immaturity and the direction of tumor growth, the extent and tempo of intracranial extension, and not only its presence, should be assessed when evaluating fetal prognosis.

This case underscores the importance of ethical decision-making and perinatal palliative care in managing lethal fetal conditions. International guidelines emphasize that, when the prognosis is extremely poor, care plans should prioritize parental values, comfort-focused management, and avoidance of non-beneficial interventions [19]. In this case, multidisciplinary discussions and an institutional ethics conference supported a care plan aligned with the family's wishes, resulting in delivery and postnatal palliative care. This approach represents an appropriate and compassionate model for managing similar cases in the future [19].

Conclusions

The direction and pattern of tumor extension in the epignathus due to an immature teratoma critically affect prognosis. Rapid and extensive intracranial involvement may irreversibly disrupt normal brain structures and preclude meaningful survival, even if airway management at birth is technically feasible. Accumulating more cases may help improve understanding of disease progression and support clinical decision-making in

severe cases. Serial prenatal imaging is crucial for reassessing disease progression, and individualized perinatal management, shared decision-making, and perinatal palliative care are needed for fetuses with severe life-limiting conditions.

Additional Information

Author Contributions

All authors have reviewed the final version to be published and agreed to be accountable for all aspects of the work.

Concept and design: Shun Yasuda, Kazunori Miyagawa

Acquisition, analysis, or interpretation of data: Shun Yasuda, Kazunori Miyagawa, Yuki Sato, Misa Sugeno, Ryo Matsuoka, Akiko Yamaguchi, Toma Fukuda, Rei Sekine, Yuichiro Kiko, Erina Suzuki, Yuko Hashimoto, Keiya Fujimori

Drafting of the manuscript: Shun Yasuda, Kazunori Miyagawa

Critical review of the manuscript for important intellectual content: Shun Yasuda, Yuki Sato, Misa Sugeno, Ryo Matsuoka, Akiko Yamaguchi, Toma Fukuda, Rei Sekine, Yuichiro Kiko, Erina Suzuki, Yuko Hashimoto, Keiya Fujimori

Supervision: Shun Yasuda, Yuko Hashimoto, Keiya Fujimori

Disclosures

Human subjects: Informed consent for treatment and open access publication was obtained or waived by all participants in this study. **Conflicts of interest:** In compliance with the ICMJE uniform disclosure form, all authors declare the following: **Payment/services info:** All authors have declared that no financial support was received from any organization for the submitted work. **Financial relationships:** All authors have declared that they have no financial relationships at present or within the previous three years with any organizations that might have an interest in the submitted work. **Other relationships:** All authors have declared that there are no other relationships or activities that could appear to have influenced the submitted work.

References

1. Holt GR, Holt JE, Weaver RG: Dermoids and teratomas of the head and neck . Ear Nose Throat J. 1979, 58:520-31.
2. Levine AB, Alvarez M, Wedgwood J, Berkowitz RL, Holzman I: Contemporary management of a potentially lethal fetal anomaly: a successful perinatal approach to epignathus. Obstet Gynecol. 1990, 76:962-6. 10.1097/00006250-199011000-00061
3. Lo Curto M, D'Angelo P, Cecchetto G, et al.: Mature and immature teratomas: results of the first paediatric Italian study. Pediatr Surg Int. 2007, 23:315-22. 10.1007/s00383-007-1890-1
4. Kirishima M, Yamada S, Shinya M, et al.: An autopsy case of epignathus (immature teratoma of the soft palate) with intracranial extension but without brain invasion: case report and literature review. Diagn Pathol. 2018, 13:99. 10.1186/s13000-018-0776-y
5. Pellegrini V, Colasurdo F, Guerriero M: Epignathus with oropharynx destruction. Autops Case Rep. 2021, 11:e2021293. 10.4322/acr.2021.293
6. Chiang YC, Shih JC, Peng SS, Hsu WC, Lee CN: Tongue teratoma--a rare form of fetal extragonadal teratoma diagnosed at 30 weeks' gestation. Ultrasound Obstet Gynecol. 2006, 28:737-41. 10.1002/uog.3824
7. Isaacs H Jr: II. Perinatal brain tumors: a review of 250 cases . Pediatr Neurol. 2002, 27:333-42. 10.1016/s0887-8994(02)00459-9
8. Tavares de Sousa M, Chaoui R, Herrmann J, Hecher K: Intrauterine laser coagulation of rapidly growing epignathus with autonomous cardiac activity. Ultrasound Obstet Gynecol. 2024, 63:419-20. 10.1002/uog.27477
9. Takagi MM, Bussamra LC, Araujo Júnior E, et al.: Prenatal diagnosis of a large epignathus teratoma using two-dimensional and three-dimensional ultrasound: correlation with pathological findings. Cleft Palate Craniofac J. 2014, 51:350-3. 10.1597/12-222
10. Kontopoulos EV, Gualtieri M, Quintero RA: Successful in utero treatment of an oral teratoma via operative fetoscopy: case report and review of the literature. Am J Obstet Gynecol. 2012, 207:e12-5. 10.1016/j.ajog.2012.04.008
11. Okafor CI, Okafor CO, Odike MA: Congenital teratoma of the face . J Obstet Gynaecol. 2004, 24:828-9. 10.1080/01443610400009667
12. Nguyen PT, Lavisha P, Lynn KH, Jitendrakumar VS: Case report: congenital palatal teratoma (epignathus) leading to neonatal airway obstruction. Int J Surg Case Rep. 2023, 109:108518. 10.1016/j.ijscr.2023.108518
13. Gonzalez-Cantu CM, Moreno-Peña PJ, Salazar-Lara MG, García PP, Montes-Tapia FF, Cervantes-Kardasch VH, Castro-Govea Y: Surgical management of palatal teratoma (epignathus) with the use of virtual reconstruction and 3D models: a case report and literature review. Arch Plast Surg. 2021, 48:518-23. 10.5999/aps.2021.00318

14. Prevedello DM, Kassam AB, Carrau RL, et al.: Transpalatal endoscopic endonasal resection of a giant epignathus skull base teratoma in a newborn. Case report. J Neurosurg. 2007, 107:266-71. 10.3171/PED-07/09/266
15. Too S, Ahmad Sarji S, Yik Y, Ramanujam T: Malignant epignathus teratoma . Biomed Imaging Interv J. 2008, 4:e18. 10.2349/biij.4.2.e18
16. Ng HN, Ong CL: Two case reports of intracranial teratoma diagnosed antenatally . Ann Acad Med Singap. 1993, 22:823-5.
17. Hosoda Y: A case of epignathus associated with intracranial teratoma in a new-born infant: with a review of related Japanese literature. Keio J Med. 1963, 12:61-82. 10.2302/kjm.12.61
18. Wang AC, Gu YQ, Zhou XY: Congenital giant epignathus with intracranial extension in a fetal . Chin Med J (Engl). 2017, 130:2386-7. 10.4103/0366-6999.215343
19. American College of Obstetricians and Gynecologists: Perinatal palliative care: ACOG Committee Opinion, Number 786. Obstet Gynecol. 2019, 134:e84-9. 10.1097/AOG.0000000000003425