Cureus
Part of SPRINGER NATURE

Open Access Case Report

A Rare Case of Lichen Striatus Mimicking Linear Psoriasis in an Adult Woman

Falah M. Alajmi [1], Alsadat Mosbeh [2, 1], Abdulaziz Alkandari [3], Salman M. Albathali [4], Abeer Albazali [1]

1. Dermatology, Farwaniya Hospital, Farwaniya, KWT 2. Dermatology/Dermatopathology, Faculty of Medicine, Al-Azhar University, Cairo, EGY 3. Primary Healthcare, Ministry of Health, Kuwait City, KWT 4. Dermatology, Kuwait Institute for Medical Specializations, Sulaibikhat, KWT

Corresponding author: Falah M. Alajmi, dr.fmalajmi@gmail.com

Review began 10/28/2026
Review ended 11/11/2026
Published 11/21/2026

© Copyright 2026
Alajmi et al. This is an open access article distributed under the terms of the Creative Commons Attribution License CC-BY 4.0., which permits unrestricted use, distribution, and reproduction in any medium, provided the original author and source are credited.

DOI: 10.7759/cureus.120063

Abstract

Lichen striatus is a benign, self-limited inflammatory skin disease that follows the lines of Blaschko. It is typically seen in children and is uncommon in adults, in whom it can resemble other linear dermatoses. We report a previously healthy 35-year-old woman who presented with a two-month history of mildly itchy lesions on the right lower limb. Examination showed erythematous, scaly, grouped papules and plaques arranged in a linear band along the posterior leg and extending to the ankle and medial hindfoot. Routine laboratory tests were largely unremarkable. Because of the linear distribution and scaling, the clinical diagnosis was linear psoriasis, with inflammatory linear verrucous epidermal nevus as the main alternative, and she was referred for skin biopsy. Histopathology showed interface dermatitis with a band-like lichenoid infiltrate and a perieccrine lymphohistiocytic infiltrate, which confirmed lichen striatus. She was treated with topical betamethasone and reviewed after two weeks, when the lesions had improved markedly. This case shows that lichen striatus should be considered in adults with unilateral, linear, scaly eruptions, and that skin biopsy is valuable when the clinical picture overlaps with linear psoriasis and inflammatory linear verrucous epidermal nevus.

Categories: Dermatology
Keywords: adult, inflammatory linear verrucous epidermal nevus, lichen striatus, linear psoriasis, lines of blaschko

Introduction

Lichen striatus is an acquired, benign, self-limited inflammatory dermatosis. It presents with a sudden eruption of small erythematous or skin-colored papules that coalesce into a continuous or interrupted linear band along the lines of Blaschko [1,2]. It is seen mainly in children, and the limbs are the most frequent site. The lesions are usually asymptomatic or mildly itchy and tend to resolve spontaneously within months to a few years [2,3].

The cause is unknown. The Blaschko-linear distribution suggests that the affected skin carries a genetically distinct clone of cells, and an environmental trigger such as a viral infection, vaccination, or trauma is thought to provoke an immune reaction against it [1,4]. Histologically, lichen striatus shows a lichenoid and spongiotic pattern with a perivascular and often peri-appendageal lymphocytic infiltrate [5,6].

Adult cases are uncommon and are sometimes labelled differently. In 1990, Grosshans and Marot described a similar eruption in adults under the name "blaschkitis" [7]. Later clinicopathological studies found little to separate the two, and many authors now regard them as one entity [8-10]. In a Korean series of 40 adult-onset Blaschko-linear inflammatory dermatoses, 27 of which were lichen striatus, the mean age at onset was 31.6 years, the leg was the most common site, and women were affected more often than men [10].

Therefore, adult lichen striatus can constitute a diagnostic challenge. Linear psoriasis, inflammatory linear verrucous epidermal nevus (ILVEN), and linear lichen planus can all produce linear, erythematous, scaly lesions, and their clinical and histological features overlap [11-13].

Case Presentation

A 35-year-old woman, previously healthy and on no regular medication, presented to our dermatology clinic with a two-month history of mildly itchy skin lesions on the right lower limb. The lesions started as small red papules that gradually grouped and merged into plaques. She reported no pain, no systemic symptoms, and no similar lesions elsewhere on the body.

On examination, there were erythematous, scaly, grouped papules and small plaques arranged in a linear band on the posterior aspect of the right leg (Figure *1*). The band ran from the mid-calf distally toward the ankle and extended onto the medial side of the ankle and hindfoot, where fine scaling and mild peeling were noted. The distribution was unilateral and followed a linear pattern.

How to cite this article
Alajmi F M, Mosbeh A, Alkandari A, et al. (November 21, 2026) A Rare Case of Lichen Striatus Mimicking Linear Psoriasis in an Adult Woman. Cureus 18(11): e120063. DOI 10.7759/cureus.120063

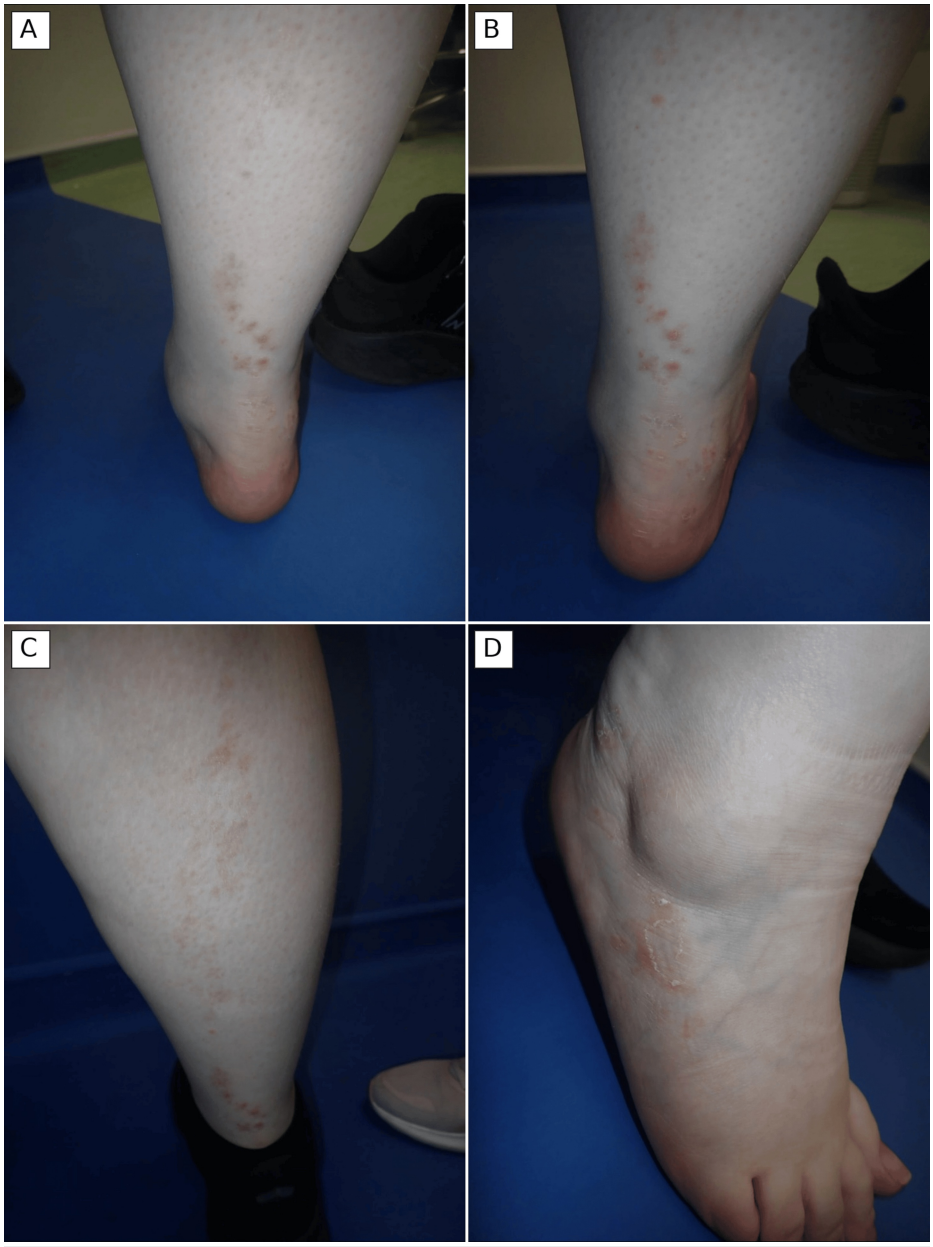

FIGURE 1: Clinical photographs of the right lower limb.

(A) Posterior view of the leg and ankle showing grouped erythematous papules forming a linear band toward the ankle, with scaling at the medial heel. (B) Closer view of the band with coalescing papules and fine scale. (C) Lateral view of the calf showing the linear distribution extending proximally. (D) Medial ankle and hindfoot with erythematous, scaly plaques and peeling edges.

Investigations

The blood group was O positive. The results of the laboratory investigations are shown in Table *1*. All values were within the reference ranges except for a mildly low serum creatinine (48 µmol/L; reference range, 53-97 µmol/L).

Test	Patient result	Reference range
Complete blood count		
White blood cell count (WBC)	8.9 × 10^9/L	3.9-11.1
Hemoglobin	125 g/L	118-148
Hematocrit (Hct)	0.368 L/L	0.36-0.44
Platelets	355 × 10^9/L	150-450
Coagulation profile		
Prothrombin time (PT)	11.20 seconds	10-13.5
International normalized ratio (INR)	0.95	-
Activated partial thromboplastin time (APTT)	31.8 seconds	23.1-38.7
APTT ratio	1.11	-
Renal function and electrolytes		
Urea	3.5 mmol/L	2.5-6.4
Creatinine	48 µmol/L	53-97
Estimated glomerular filtration rate (eGFR, calculated)	107 mL/min/1.73 m^2	-
Sodium	138 mmol/L	136-146
Potassium	4.2 mmol/L	3.5-5.2
Liver function		
Alanine aminotransferase (ALT)	12 IU/L	10-60
Aspartate aminotransferase (AST)	26 IU/L	10-42
Alkaline phosphatase (ALP)	52 IU/L	42-98
Albumin	37 g/L	35-48
Total bilirubin	16.8 µmol/L	3-20
Lipid profile		
Total cholesterol	5.01 mmol/L	3.1-5.2
Triglycerides	1.31 mmol/L	0-1.7
High-density lipoprotein (HDL) cholesterol	1.31 mmol/L	1.29-1.69
Low-density lipoprotein (LDL) cholesterol	3 mmol/L	0-3.4

TABLE 1: Laboratory investigations of the patient at presentation, with reference ranges

Differential diagnosis

Based on the linear distribution, erythema, and scaling, the initial clinical diagnosis was linear psoriasis. The main alternative considered was ILVEN. The patient was referred for skin biopsy to establish the diagnosis.

Histopathology

The skin biopsy confirmed the diagnosis of lichen striatus. Low-power examination showed a lichenoid infiltrate with interface dermatitis, associated with a perieccrine inflammatory infiltrate (Figure *2A*). At higher power, there was a band-like dermal infiltrate composed predominantly of lymphocytes and histiocytes mixed with melanophages. The epidermis showed hyperkeratosis and atrophy with elongation of the rete ridges, vacuolar alteration of the basal cell layer, and dyskeratotic cells at the dermoepidermal junction (Figure *2B*). The perieccrine infiltrate was composed of lymphohistiocytic cells (Figure *2C*).

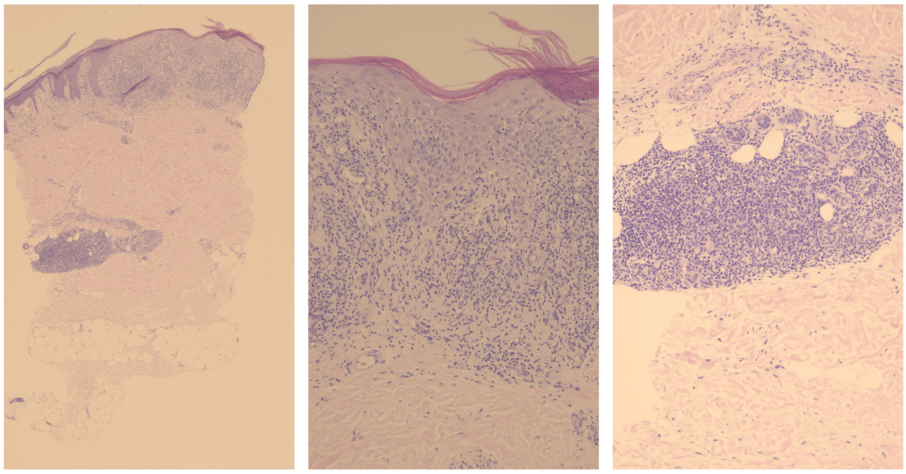

FIGURE 2: Histopathology of the skin biopsy (H&E).

(A) Low-power view showing a lichenoid infiltrate with interface dermatitis and a perieccrine inflammatory infiltrate. (B) Band-like dermal infiltrate of lymphocytes and histiocytes mixed with melanophages, with hyperkeratosis, epidermal atrophy with elongated rete ridges, vacuolar alteration of the basal layer, and dyskeratotic cells at the dermoepidermal junction. (C) Perieccrine lymphohistiocytic infiltrate (original magnification × 20).

Management

The patient was treated with topical betamethasone, a common first-line choice for symptomatic lesions, and was reviewed after two weeks. On follow-up examination, the patient demonstrated significant clinical improvement, with marked regression of the skin lesions.

Discussion

This case is notable for the patient's adult age and for a presentation that closely resembled linear psoriasis. Her age, sex, and the leg as the site of involvement match the pattern reported in adult series [10]. The unilateral linear arrangement of erythematous, scaly papules and plaques, together with mild itching, led to an initial diagnosis of linear psoriasis.

Linear psoriasis and ILVEN both present as linear, erythematous, scaly eruptions and were the principal differential diagnoses. Linear psoriasis is a rare mosaic form of psoriasis that has been described in case series [12], and it may occur in patients with psoriasis elsewhere or a psoriatic history. ILVEN is a persistent, itchy, linear eruption that usually begins in infancy or early childhood [14]. The clinical and histological features of ILVEN and psoriasis overlap, and immunohistochemical markers such as keratin 16, keratin 10, and elastase-positive cells have been proposed to help separate them [11]. Linear lichen planus is a further consideration and can be distinguished from lichen striatus by comparing clinicopathological features and the immunoprofile of the infiltrate [13]. Because the clinical features overlap and the treatment and prognosis differ, histological confirmation was important here.

Explanation of the diagnosis

Lichen striatus is diagnosed from the combination of a linear distribution, acute onset of small papules, and a self-limited course, supported by a compatible biopsy. In this patient, the unilateral band of grouped papules following a line down the limb fits the Blaschko-linear pattern, which reflects the migration pattern of embryonic skin cells. The two-month duration and mild itch are also consistent. The scaling, which first suggested psoriasis, is a common feature of lichen striatus (Table *2*).

Feature	Lichen striatus	Linear psoriasis	ILVEN
Typical age at onset	Childhood, rarely adults	Any age, usually with psoriasis elsewhere	Early childhood
Onset and course	Sudden; resolves spontaneously	Chronic, relapsing	Persistent, rarely resolves
Itch	Absent or mild	Variable	Often marked
Distribution	Unilateral, Blaschko-linear	Linear, may follow Blaschko lines	Unilateral, Blaschko-linear
Typical histology	Spongiotic dermatitis with lichenoid changes and a perivascular and perifollicular lymphocytic infiltrate	Regular acanthosis, parakeratosis, loss of the granular layer, neutrophils in the stratum corneum	Alternating parakeratosis with absent granular layer and orthokeratosis with hypergranulosis

TABLE 2: Typical features of the conditions considered in the differential diagnosis (general features, not findings from this patient)

ILVEN: inflammatory linear verrucous epidermal nevus.

References [5,6,11,12].

The biopsy was decisive because the clinical features of the three conditions overlap. In this patient, it showed an interface dermatitis with a band-like lichenoid infiltrate, vacuolar change of the basal layer, and dyskeratotic cells, together with a perieccrine lymphohistiocytic infiltrate (Figure *2*). Interface dermatitis and dyskeratosis are not expected in psoriasis or ILVEN, in which the epidermal change is psoriasiform [11,12]. The perieccrine extension of the infiltrate fits the peri-appendageal pattern that is typical of lichen striatus and is common in adult series [5,6,10]. Lichenoid interface changes also occur in linear lichen planus, so the histology has to be read together with the acute onset and the linear distribution [13].

Pathogenesis and possible triggers

The pathogenesis of lichen striatus is not fully understood. The prevailing view is that a postzygotic mutation produces a mosaic clone of keratinocytes along a Blaschko line, and that an environmental trigger then provokes a T-cell-mediated reaction against that clone [1,4]. Reported triggers include varicella infection [15], trauma [16], and interferon therapy [17].

Adult blaschkitis

Some authors would classify an adult eruption like this one as adult blaschkitis. Because the clinicopathological differences between lichen striatus and adult blaschkitis are small and mostly limited to age at onset and the number of sites involved, the distinction has little practical value [8-10].

Management and prognosis

Lichen striatus is self-limited, and treatment is directed mainly at itching and cosmetic concerns. In adults, topical calcineurin inhibitors such as pimecrolimus and tacrolimus have been reported to help [18,19], and a short course of low-dose systemic corticosteroid has been used in an adult patient [20]. Systemic therapy is rarely needed, and reassurance about the benign course is an important part of management. Our patient was treated with topical betamethasone, a common first-line choice for symptomatic lesions, and was reviewed after two weeks, at which point she demonstrated significant clinical improvement. Because lichen striatus often resolves without treatment, the response to any therapy is difficult to separate from the natural course, and the evidence for specific treatments comes mostly from case reports and small series.

Conclusions

We described a 35-year-old woman with a two-month history of mildly itchy, erythematous, scaly papules and plaques arranged in a linear band along the right lower limb, with laboratory results that were largely unremarkable. The unilateral linear distribution and scaling led to a clinical diagnosis of linear psoriasis, and inflammatory linear verrucous epidermal nevus was the main alternative.

Skin biopsy was essential in this case. It showed interface dermatitis with a band-like lichenoid infiltrate,

basal vacuolar change, dyskeratotic cells, and a perieccrine lymphohistiocytic infiltrate, which established lichen striatus and excluded the diagnoses considered clinically. Without histological confirmation, the eruption could have been treated as a chronic condition such as psoriasis.

Lichen striatus should therefore be included in the differential diagnosis of any adult with a unilateral, linear, erythematous, scaly eruption, together with linear psoriasis, inflammatory linear verrucous epidermal nevus, and linear lichen planus. Once the diagnosis is confirmed, management can be conservative: reassurance about the benign, self-limited course, symptomatic treatment such as topical corticosteroids when itching or inflammation is troublesome, and follow-up to confirm resolution.

Additional Information

Author Contributions

All authors have reviewed the final version to be published and agreed to be accountable for all aspects of the work.

Concept and design: Falah M. Alajmi, Alsadat Mosbeh, Abdulaziz Alkandari, Salman M. Albathali, Abeer Albazali

Acquisition, analysis, or interpretation of data: Falah M. Alajmi, Alsadat Mosbeh, Abdulaziz Alkandari, Salman M. Albathali, Abeer Albazali

Drafting of the manuscript: Falah M. Alajmi, Alsadat Mosbeh, Abdulaziz Alkandari, Salman M. Albathali, Abeer Albazali

Critical review of the manuscript for important intellectual content: Falah M. Alajmi, Alsadat Mosbeh, Abdulaziz Alkandari, Salman M. Albathali, Abeer Albazali

Supervision: Falah M. Alajmi, Alsadat Mosbeh, Abdulaziz Alkandari, Salman M. Albathali, Abeer Albazali

Disclosures

Human subjects: Informed consent for treatment and open access publication was obtained or waived by all participants in this study. **Conflicts of interest:** In compliance with the ICMJE uniform disclosure form, all authors declare the following: **Payment/services info:** All authors have declared that no financial support was received from any organization for the submitted work. **Financial relationships:** All authors have declared that they have no financial relationships at present or within the previous three years with any organizations that might have an interest in the submitted work. **Other relationships:** All authors have declared that there are no other relationships or activities that could appear to have influenced the submitted work.

References

1. Taieb A, el Youbi A, Grosshans E, Maleville J: Lichen striatus: a Blaschko linear acquired inflammatory skin eruption. J Am Acad Dermatol. 1991, 25:637-42. 10.1016/0190-9622(91)70245-w
2. Mendieta-Eckert M, González-Hermosa MR, Fernández Flores Á, Fonseca Capdevila E: Lichen striatus: etiological, clinical and diagnostic review [article in Spanish]. Piel. 2023, 38:322-8. 10.1016/j.piel.2022.04.003
3. Hauber K, Rose C, Bröcker EB, Hamm H: Lichen striatus: clinical features and follow-up in 12 patients . Eur J Dermatol. 2000, 10:536-9.
4. Lipsker D, Cribier B, Girard-Lemaire F, Flori E, Grosshans E: Genetic mosaicism in an acquired inflammatory dermatosis following the lines of Blaschko. Arch Dermatol. 2000, 136:805-7. 10.1001/archderm.136.6.805
5. Gianotti R, Restano L, Grimalt R, Berti E, Alessi E, Caputo R: Lichen striatus--a chameleon: an histopathological and immunohistological study of forty-one cases. J Cutan Pathol. 1995, 22:18-22. 10.1111/j.1600-0560.1995.tb00734.x
6. Zhang Y, McNutt NS: Lichen striatus. Histological, immunohistochemical, and ultrastructural study of 37 cases. J Cutan Pathol. 2001, 28:65-71. 10.1034/j.1600-0560.2001.280202.x
7. Grosshans E, Marot L: Blaschkitis in adults [article in French] . Ann Dermatol Venereol. 1990, 117:9-15.
8. Hofer T: Lichen striatus in adults or 'adult blaschkitis'?. There is no need for a new naming . Dermatology. 2003, 207:89-92. 10.1159/000070955
9. Müller CS, Schmaltz R, Vogt T, Pföhler C: Lichen striatus and blaschkitis: reappraisal of the concept of blaschkolinear dermatoses. Br J Dermatol. 2011, 164:257-62. 10.1111/j.1365-2133.2010.10053.x
10. Baek YS, Seo JY, Seo SH, et al.: Adult-onset lichen striatus versus adult blaschkitis: a clinicopathological review of 40 cases of acquired blaschkolinear inflammatory dermatosis. Eur J Dermatol. 2019, 29:281-6. 10.1684/ejd.2019.3556
11. de Jong E, Rulo HF, van de Kerkhof PC: Inflammatory linear verrucous epidermal naevus (ILVEN) versus linear psoriasis. A clinical, histological and immunohistochemical study. Acta Derm Venereol. 1991, 71:343-6. 10.2340/0001555571343346
12. Say M, Boralévi F, Lenormand C, et al.: Clinical and therapeutic aspects of linear psoriasis: a study of 30

cases. Am J Clin Dermatol. 2018, 19:609-15. 10.1007/s40257-018-0354-9
13. Zhou Y, Yu ZZ, Peng J, Yang PP, Li SJ, Fan YM: Lichen striatus versus linear lichen planus: a comparison of clinicopathological features, immunoprofile of infiltrated cells, and epidermal proliferation and differentiation. Int J Dermatol. 2016, 55:e204-10. 10.1111/ijd.13143
14. Altman J, Mehregan AH: Inflammatory linear verrucose epidermal nevus. Arch Dermatol. 1971, 104:385-9. 10.1001/archderm.1971.04000220043008
15. Hafner C, Landthaler M, Vogt T: Lichen striatus (blaschkitis) following varicella infection. J Eur Acad Dermatol Venereol. 2006, 20:1345-7. 10.1111/j.1468-3083.2006.01691.x
16. Ishikawa M, Ohashi T, Yamamoto T: Lichen striatus following influenza infection. J Dermatol. 2014, 41:1133-4. 10.1111/1346-8138.12684
17. Shepherd V, Lun K, Strutton G: Lichen striatus in an adult following trauma. Australas J Dermatol. 2005, 46:25-8. 10.1111/j.1440-0960.2005.00132.x
18. Brennand S, Khan S, Chong AH: Lichen striatus in a pregnant woman. Australas J Dermatol. 2005, 46:184-6. 10.1111/j.1440-0960.2005.00176.x
19. Mask-Bull L, Vangipuram R, Carroll BJ, Tarbox MB: Lichen striatus after interferon therapy. JAAD Case Rep. 2015, 1:254-6. 10.1016/j.jdcr.2015.05.002
20. Lora V, Kanitakis J, Latini A, Cota C: Lichen striatus associated with etanercept treatment of rheumatoid arthritis. J Am Acad Dermatol. 2014, 70:e90-2. 10.1016/j.jaad.2013.11.039