Cureus
Part of SPRINGER NATURE

Open Access Case Report

Periorbital Necrotizing Fasciitis in Adults Without Classic Risk Factors: A Report of Two Cases

Review began 11/06/2026
Review ended 11/15/2026
Published 11/20/2026

© **Copyright** 2026
Sá Araújo et al. This is an open access article distributed under the terms of the Creative Commons Attribution License CC-BY 4.0., which permits unrestricted use, distribution, and reproduction in any medium, provided the original author and source are credited.

DOI: 10.7759/cureus.120014

Vera Sá Araújo [1, 2], Daniel Abilheira [1], Cristina Freitas [1], Carla Ferreira [1], Cátia Azenha [1]

1. Ophthalmology, Unidade Local de Saúde de Braga, Braga, PRT 2. School of Medicine, University of Minho, Braga, PRT

Corresponding author: Vera Sá Araújo, veraaraujo1999@gmail.com

Abstract

Periorbital necrotizing fasciitis is a rare and rapidly progressive soft tissue infection that may initially resemble periorbital cellulitis. We describe two men without classic risk factors who developed periorbital necrotizing fasciitis caused by *Streptococcus pyogenes*. A 66-year-old man presented with severe pain, tense edema, bullae, and crepitus of the left upper eyelid, with extension into the superior extraconal orbit, a relative afferent pupillary defect, and optic disc edema. He underwent early debridement of the upper eyelid and received intravenous antibiotics, later adjusted to penicillin. The eyelid healed by secondary intention with preserved levator function, but he developed optic atrophy with an altitudinal visual field defect and a hypertropia with diplopia. A 44-year-old man presented with painful edema and crepitus of the left hemiface extending to the neck and chest, with necrosis of the lower eyelid and mandibular region. He required multiple debridements, including two procedures on the lower eyelid, admission to the intensive care unit, and prolonged antibiotic therapy. At 12 months, the lower eyelid remained stable, with mild skin retraction, without lagophthalmos or functional impairment. Periorbital necrotizing fasciitis can occur in adults without predisposing conditions and without recalled trauma. Severe pain, crepitus, and early skin necrosis should prompt urgent surgical evaluation. After early debridement and targeted antibiotic therapy, the eyelids healed without reconstruction in both patients, but orbital extension was associated with permanent visual loss in one of them.

Categories: Ophthalmology
Keywords: eyelid necrosis, optic neuropathy, orbital infection, periorbital necrotizing fasciitis, secondary intention healing, streptococcus pyogenes, surgical debridement

Introduction

Necrotizing fasciitis is a life-threatening bacterial soft tissue infection characterized by a fulminant inflammatory process that spreads along the fascial planes, leading to rapid tissue devitalization and a substantial risk of systemic compromise. It is uncommon in the head and neck and particularly rare in the periorbital region, a feature generally attributed to the rich vascular supply of this area [1-3]. This extensive arterial and venous network enhances tissue perfusion, promotes the delivery of immune cells, and facilitates the clearance of bacteria and toxins, thereby limiting ischemia and the progression of necrosis [3]. Bacterial toxins and the host inflammatory response cause thrombosis of small vessels, ischemia, and liquefactive necrosis of the subcutaneous fat and fascia, which allows rapid spread of the infection [1,3].

Periorbital necrotizing fasciitis typically presents with erythema, edema extending beyond the visible margins of erythema, severe pain, crepitus, skin bullae, and necrosis. In its early stages, it may closely mimic more common inflammatory conditions of the periorbital region, such as cellulitis [2,4,5]. This clinical overlap can delay recognition, which is of particular concern in emergency and ophthalmic settings. Unlike preseptal and orbital cellulitis, which usually respond to antibiotics alone, necrotizing fasciitis requires prompt surgical debridement, and delayed diagnosis increases the risk of extensive tissue loss, visual loss, and death [1,2].

Risk factors for necrotizing fasciitis include alcoholism, diabetes mellitus, rheumatologic disease, systemic malignancy, corticosteroid use, intravenous drug use, and the use of nonsteroidal anti-inflammatory drugs. However, the condition may also occur in otherwise healthy individuals [6], and about half of the published cases of periocular necrotizing fasciitis have occurred in previously healthy patients [7].

Data on the surgical management and the eyelid and visual outcomes in this group remain limited. We report two cases of periorbital necrotizing fasciitis caused by *Streptococcus pyogenes* in men without classic risk factors and discuss the diagnosis, the surgical management, and the eyelid and visual outcomes.

Case Presentation

In both cases, the day of admission is reported as day 0 (D0) and the subsequent days of hospitalization as D1, D2, and so on. Follow-up is reported in months after admission (M).

Case 1

A 66-year-old man with a history of hypertension, dyslipidemia, ischemic heart disease (two myocardial infarctions in 2009), and polycythemia under investigation presented to the emergency department with a two-day history of fever, severe pain, edema, and erythema of the left upper eyelid. He had no history of diabetes mellitus, immunosuppression, or nonsteroidal anti-inflammatory drug use. There was no history of recent trauma to the eyelids, forehead, or scalp.

At admission (D0), his temperature was 40.3°C, blood pressure 135/70 mmHg, and heart rate 90 bpm. He had tense left periorbital edema preventing spontaneous eyelid opening, skin bullae, purulent exudate, and crepitus on palpation. Mild edema and erythema were also present over the malar and zygomatic areas (Figure *1A*).

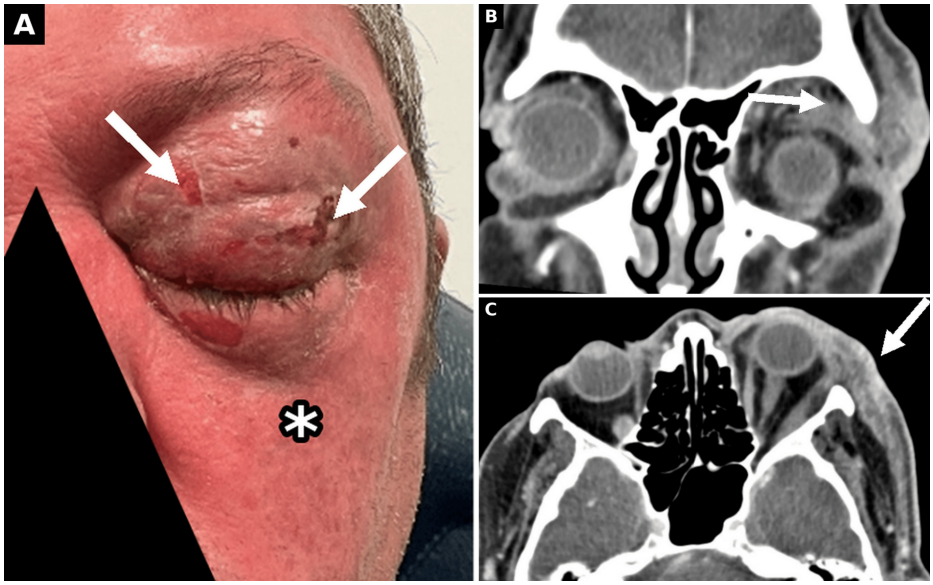

FIGURE 1: Case 1 at admission (D0)

(A) Left hemiface. The arrows indicate skin bullae and early necrosis of the upper eyelid, with tense periorbital edema preventing eyelid opening. The asterisk marks the edema and erythema extending to the malar and zygomatic regions. (B, C) Contrast-enhanced computed tomography of the orbits, coronal (B) and axial (C) images. The arrow in (B) indicates inflammatory infiltration of the superior extraconal orbital space adjacent to the lacrimal gland. The arrow in (C) indicates marked swelling of the left preseptal and periorbital soft tissues.

Ophthalmological examination revealed proptosis and inferior dystopia of the left eye. Best-corrected visual acuity (BCVA), measured on forced eyelid opening, was 0.00 logMAR in the right eye and 0.52 logMAR in the left eye. There was a left relative afferent pupillary defect. Ocular motility of the left eye was limited in levoversion, with mild limitation in supraversion and infraversion, and he reported binocular diplopia. Intraocular pressure was 12 mmHg in the right eye and 22 mmHg in the left eye, and there was no resistance to retropulsion. The anterior segment showed mild conjunctival chemosis and was otherwise unremarkable. Fundoscopy showed mild optic disc edema in the left eye and was normal in the right eye.

Laboratory tests showed leukocytosis (23.2 × 10^3/μL) with 94.9% neutrophils, an elevated C-reactive protein (CRP, 66.30 mg/L), and a glucose level of 137 mg/dL, with normal renal function and coagulation (Table *1*). Cultures of the purulent eyelid exudate and blood were collected. Computed tomography (CT) showed extensive edema of the left periorbital soft tissues and both eyelids, with extension into the extraconal orbital space in the superior orbit, adjacent to the lacrimal gland, without orbital abscess (Figures *1B*, *1C*). The optic nerve sheath complex was of normal thickness, and the cavernous sinuses were normal. There was mild ethmoid mucosal thickening, without sinus opacification.

Parameter (unit)	Reference range	Case 1	Case 2
Hemoglobin (g/dL)	13.5–17.0	18.9	15.9
Hematocrit (%)	40.0–49.5	53.7	43.3
Leukocytes (× 10³/μL)	4.0–11.0	23.2	9.5
Neutrophils (× 10³/μL)	1.8–7.1	22.0 (94.9%)	9.1 (95.7%)
Lymphocytes (× 10³/μL)	1.2–3.4	0.7 (2.9%)	0.2 (1.8%)
Band forms	Absent	Not reported	Present
Platelets (× 10³/μL)	150–400	192	209
Prothrombin time (s)	8.0–14.0	13.7	Not measured
International normalized ratio	0.8–1.2	1.16	Not measured
Activated partial thromboplastin time (s)	25.0–37.0	30.8	Not measured
Glucose (mg/dL)	82–115/74–106[a]	137	127
Urea (mg/dL)	19–49	34	177
Creatinine (mg/dL)	0.70–1.20	1.2	2.9
Sodium (mmol/L)	136–145	135	128
Potassium (mmol/L)	3.5–5.1	3.6	3.1
Chloride (mmol/L)	98–107	100	95
C-reactive protein (mg/L)	< 5.0	66.30	433.44
LRINEC score (points)	< 6	1	8
Blood cultures	Negative	Negative	*S. pyogenes*
Wound or tissue culture	Negative	*S. pyogenes*	*S. pyogenes*

TABLE 1: Laboratory findings at admission (D0)

[a] Reference range of the hospital laboratory at the time of each admission (Case 1/Case 2).

LRINEC: Laboratory Risk Indicator for Necrotizing Fasciitis, calculated from C-reactive protein, leukocyte count, hemoglobin, sodium, creatinine, and glucose (range 0–13), with a score of 6 or more suggesting necrotizing fasciitis [8]. D0: day of admission.

The patient was admitted and started on intravenous ceftriaxone 1 g every 12 hours and clindamycin 600 mg every eight hours on D0. On D1, despite intravenous antibiotics, progressive maceration and necrosis of the left upper eyelid skin developed, and urgent surgical debridement was decided. He underwent surgical debridement under general anesthesia, with necrosectomy of the devitalized skin and subcutaneous tissue, drainage of purulent material, and drain placement (Figure *2A*). Intraoperatively, the fascia was grey and necrotic, with thin, dishwater-like fluid, absence of bleeding from the affected tissues, and easy separation of the tissue planes. In collaboration with the infectious diseases team, intravenous vancomycin 500 mg every 12 hours was added, and the ceftriaxone dose was increased to 2 g every 12 hours.

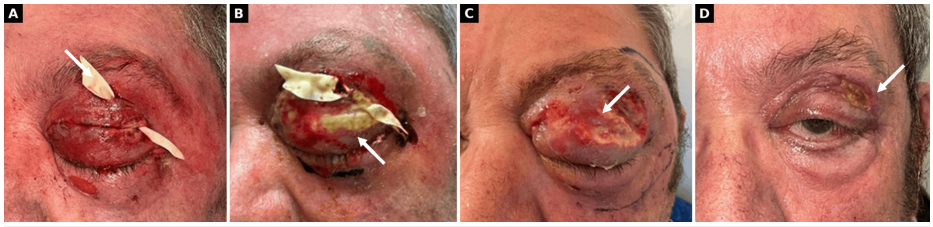

FIGURE 2: Case 1, clinical course during hospitalization

(A) D1, immediately after surgical debridement, necrosectomy, and drainage of purulent material. The arrow indicates the drain placed in the upper eyelid wound. (B) D3. The arrow indicates fibrinous exudate and early granulation tissue on the wound bed. (C) D7, after drain removal. The arrow indicates the granulating upper eyelid wound, with no new areas of ischemia. (D) D28, at discharge. The arrow indicates the residual crust at the lateral upper eyelid, with the eyelid open.

The wound was cleaned and dressed daily, with further bedside debridement of devitalized tissue as needed. CRP decreased from 128.30 mg/L on D3 to 31.60 mg/L on D5, when the leukocytosis had resolved. HIV serology was negative. On D6, culture of the purulent exudate grew *S. pyogenes*, which was susceptible to penicillin and all other antibiotics tested. Blood cultures were negative. Antibiotic therapy was then de-escalated to intravenous benzylpenicillin 4 million units every four hours, which was given for nine days (D6 to D14), followed by oral amoxicillin 1 g every eight hours for seven days (D15 to D21). The wound showed progressive granulation (Figure *2B*), with no new areas of ischemia, and the drain was removed on D7 (Figure *2C*). CRP decreased further to 6.10 mg/L on D9 and was negative on D13. Visual acuity, pupillary reactions, and intraocular pressure were assessed daily.

Despite the favorable local and laboratory course, a follow-up CT on D9 showed progression of the orbital component, with thickening and stranding of the superior and lateral extraconal fat, enlargement of the superior rectus and levator palpebrae superioris complex suggestive of myositis, and marked proptosis with straightening of the orbital segment of the optic nerve and left parotid sialadenitis, without abscess or cavernous sinus thrombosis. At that time, CRP was decreasing, and the leukocytosis had resolved. As the infection was controlled and antibiotic therapy had been adjusted to culture results, topical corticosteroid and antibiotic drops were started on D14 and oral prednisolone 20 mg daily on D15 to reduce the orbital inflammation, increased to 60 mg daily on D23. A further CT on D17 showed marked improvement, with residual postseptal involvement. He was discharged on D28, with a tapering course of oral prednisolone over 15 days. At discharge, BCVA was 0.00 logMAR in the right eye and 0.49 logMAR in the left eye, with a mild relative afferent pupillary defect, mild ptosis, limited abduction of the left eye, and residual proptosis (Hertel exophthalmometry 20 mm in the right eye and 23 mm in the left eye, base 122 mm).

He was followed in the oculoplastics and orbit clinic. At two months (M2), BCVA in the left eye had improved to 0.10 logMAR, with a persistent relative afferent pupillary defect and loss of the superior visual hemifield. At six months (M6), BCVA remained 0.10 logMAR. The upper eyelid had healed with preserved levator function (levator excursion of 12 mm), mild retraction, and a discrete scar in the eyelid crease, without lagophthalmos (Figure *3*). Fundoscopy showed pallor of the left optic disc, and Humphrey 24-2 perimetry showed a superior altitudinal visual field defect in the left eye. Proptosis had resolved (Hertel exophthalmometry 21 mm in the right eye and 22 mm in the left eye). He had constant vertical and torsional binocular diplopia, with a left hypertropia of 15 prism diopters on the Hess chart and limitation of infraduction and abduction of the left eye, consistent with restrictive strabismus. At one year (M12), the eyelid remained stable, without late cicatricial complications. As the deviation was too large for prismatic correction, he underwent strabismus surgery at M22, with recession of the right inferior rectus, with marked improvement of diplopia.



FIGURE 3: Case 1 at six months (M6)

Periocular view, with the fellow eye masked. The arrow indicates the healed left upper eyelid, with mild retraction and a discrete scar in the eyelid crease, without lagophthalmos.

Case 2

A previously healthy 44-year-old man presented with a two-day history of severe pain, edema, and erythema of the left hemiface. He had no history of diabetes mellitus, immunosuppression, or nonsteroidal anti-inflammatory drug use, and he denied trauma or alcohol abuse. No portal of entry, such as a skin wound, insect bite, or recent dental or upper respiratory tract infection, was identified.

At admission (D0), his temperature was 39.1°C, blood pressure 90/41 mmHg, and heart rate 110 bpm. Examination revealed erythema and tense edema of the left hemiface extending to the ipsilateral cervical and thoracic regions, with palpable crepitus. Necrotic lesions were present in the mandibular region and the lower eyelid (Figure *4A*).

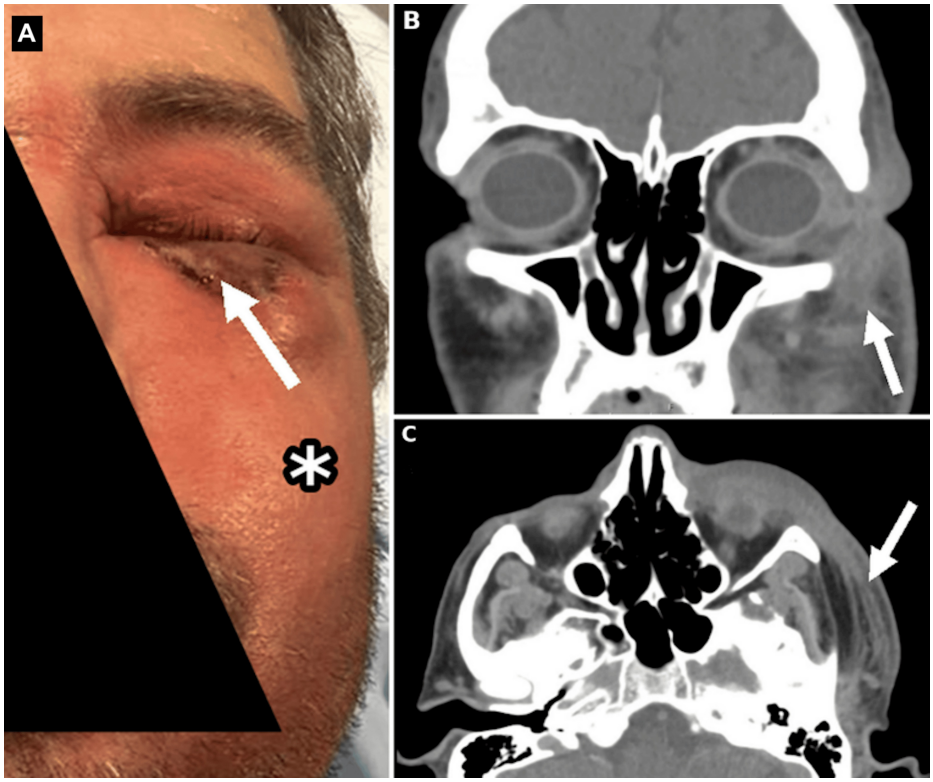

FIGURE 4: Case 2 at admission (D0)

(A) Left hemiface. The arrow indicates the dusky, necrotic area of the left lower eyelid. The asterisk marks the tense erythema and edema of the left hemiface. (B, C) Computed tomography, coronal (B) and axial (C) images. The arrows indicate marked subcutaneous edema and fat stranding in the left malar and facial soft tissues, without fluid collections or postseptal extension.

Ophthalmological examination showed edema and erythema of both left eyelids, with necrosis of the lower eyelid skin. BCVA was 0.00 logMAR in both eyes. Pupils were equal and reactive, without a relative afferent pupillary defect. Ocular motility was full and painless in both eyes, without diplopia, and there was no proptosis. Intraocular pressure was 12 mmHg in the right eye and 13 mmHg in the left eye. The anterior segment and fundoscopy were normal in both eyes.

Laboratory tests showed a normal leukocyte count (9.5 × 10^3/µL) with 95.7% neutrophils, band forms, and marked lymphopenia (0.2 × 10^3/µL), a markedly elevated CRP (433.44 mg/L), hyponatremia (128 mmol/L), hypokalemia (3.1 mmol/L), and raised creatinine (2.9 mg/dL) and urea (177 mg/dL) (Table *1*). CT showed marked subcutaneous edema of the left hemiface, involving the periorbital, frontal and malar regions and extending to the submandibular and submental regions, without organized fluid collections or postseptal extension (Figures *4B*, *4C*).

Given the established skin necrosis, crepitus, and signs of sepsis, he was started on empirical intravenous piperacillin-tazobactam at standard doses and underwent urgent surgical debridement by the general surgery team on D0, with excision of the necrotic tissue of the mandibular and cervical regions. In the same procedure, the ophthalmology team debrided the necrotic skin and subcutaneous tissue of the lower eyelid, preserving the eyelid margin, and placed a surgical drain (Figures *5A*, *5B*). Given the extent of the debridement and hemodynamic instability, he was admitted to the intensive care unit. His course was complicated by sepsis with acute kidney injury, without need for vasopressor support.

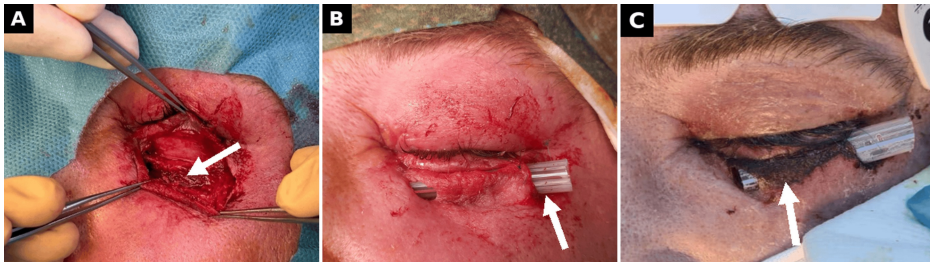

FIGURE 5: Case 2, surgical management

(A) D0, intraoperative debridement of the left lower eyelid. The arrow indicates the debrided subcutaneous plane after excision of the necrotic tissue. (B) D0, end of the procedure. The arrow indicates the surgical drain. (C) D4, before the second debridement of the lower eyelid. The arrow indicates the dark necrotic eschar along the lower eyelid that prompted the second procedure.

On D4, a second ophthalmological procedure was needed for progression of the lower eyelid necrosis (Figure *5C*). Further debridements of the mandibular and cervical regions were performed by the general surgery team on D5 and D8. The drain was removed on D7, and the eyelid wound was left to heal by secondary intention. *S. pyogenes* was isolated from blood and tissue cultures. He completed 12 days of piperacillin-tazobactam (D0 to D11), after which antibiotic therapy was de-escalated to intravenous penicillin at standard doses, which was continued for four weeks. He was transferred from the intensive care unit to the ward on D15. The clinical course was favorable, with no new areas of ischemia and improvement in imaging findings. Inflammatory markers and renal function had normalized by discharge. Visual acuity, pupillary reactions, and ocular motility remained normal throughout hospitalization. He was discharged six weeks after admission.

He was followed in the oculoplastics and orbit clinic. At two months (M2), he had no visual complaints but reported paresthesia of the left lower eyelid. BCVA was 0.00 logMAR in both eyes, and intraocular pressure was 11 mmHg in the right eye and 12 mmHg in the left eye. The wound had healed well, with preserved eyelid dynamics, mild retraction of the lower eyelid skin, and discrete inferior scleral show, without ectropion or lagophthalmos. The loss of the lower eyelid fat pads caused slight hollowing of the lower eyelid, without aesthetic or functional impact (Figure *6*). Slit-lamp examination of the left eye showed mild inferior superficial punctate keratopathy, and fundoscopy was normal in both eyes. At one year (M12), the eyelid remained stable, without late cicatricial complications.

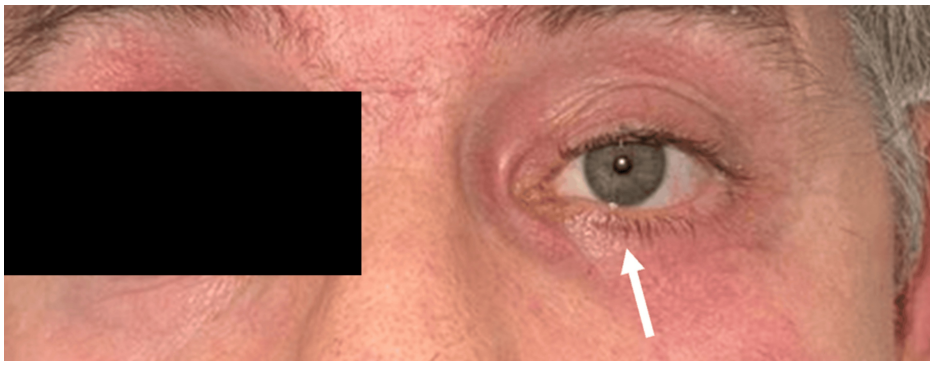

FIGURE 6: Case 2 at two months (M2)

Periocular view, with the fellow eye masked. The arrow indicates the healed left lower eyelid, with mild skin retraction and hollowing due to loss of the lower eyelid fat pads, without ectropion.

Discussion

Periorbital necrotizing fasciitis affects the subcutaneous fat and fascia, may extend to the underlying muscle, and leads to necrosis of the overlying skin. Necrotizing fasciitis is traditionally classified into two types according to its microbiology. Type 1 is polymicrobial, involving aerobic and anaerobic organisms, and occurs more often in older or immunocompromised patients and in those with comorbidities. Type 2 is monomicrobial and is most commonly caused by group A *Streptococcus* and, less often, *Staphylococcus aureus* [1,6]. In the periorbital region, β-hemolytic streptococci are the predominant organisms. They were identified in about half of the cases in an earlier review [2], and *S. pyogenes* was the main pathogen in 79.8% of cases in a recent systematic review [7]. Both of our patients had a monomicrobial infection caused by *S.*

pyogenes, consistent with type 2 disease.

Trauma, particularly penetrating or surgical injury, is the most frequently reported trigger. Other predisposing conditions include upper respiratory tract infections, acute or chronic sinusitis, recent periocular or ocular infections, and systemic infections [1,2,9]. In the systematic review, wound-related infection accounted for 44.8% of cases, but 40.8% occurred spontaneously [7]. Neither of our patients recalled any trauma. The initiating injury may be minimal and therefore not remembered by the patient [1].

The differential diagnosis of a rapidly progressive periorbital infection includes preseptal cellulitis, orbital cellulitis, and necrotizing soft tissue infections of other etiologies. Preseptal cellulitis is confined anterior to the orbital septum and causes eyelid erythema and edema with preserved visual acuity, normal pupillary reactions, and full ocular motility. Orbital cellulitis, most often secondary to ethmoid sinusitis, is distinguished by proptosis, painful or restricted ocular motility, chemosis, and, in severe cases, optic nerve dysfunction; CT shows postseptal inflammation or a subperiosteal or orbital abscess [10]. Both forms of cellulitis usually progress more slowly, cause less severe pain, and leave the skin intact [4,11]. Necrotizing infections of other etiologies must also be considered. Polymicrobial (type 1) necrotizing fasciitis and clostridial myonecrosis more often affect older or immunocompromised patients and may produce soft tissue gas on imaging [6]. Rhino-orbital mucormycosis, angioedema, herpes zoster ophthalmicus, and erysipelas are additional differential diagnoses [7].

In both patients, severe pain, rapidly progressive edema with crepitus, and early skin necrosis favored necrotizing fasciitis over these conditions. In the first patient, proptosis, a relative afferent pupillary defect, restricted motility with diplopia, and extraconal involvement on CT raised the possibility of orbital cellulitis, but the absence of significant sinus disease or orbital abscess and the presence of bullae, crepitus, and early skin necrosis pointed to a necrotizing infection of the eyelid with secondary orbital extension. In the second patient, the involvement extended well beyond the periorbital region, with normal visual function and no postseptal disease, a pattern more consistent with a necrotizing soft tissue infection of the face than with primary orbital disease. The monomicrobial growth of *S. pyogenes* and the lack of diabetes or immunosuppression, with negative HIV serology in the first patient, argued against polymicrobial infection and fungal disease. The diagnosis of necrotizing fasciitis is primarily clinical and is suggested by pain out of proportion to the physical findings, edema extending beyond the visible erythema, poorly defined margins, crepitus, early skin necrosis, and systemic toxicity [2,6,12,13]. In our patients, the diagnosis was based on the clinical and intraoperative findings and supported by the isolation of *S. pyogenes*. The debrided tissue was not submitted for histopathological examination, which provides definitive confirmation of fascial necrosis.

Laboratory findings help to assess the severity of the disease. The Laboratory Risk Indicator for Necrotizing Fasciitis (LRINEC) score combines CRP, leukocyte count, hemoglobin, sodium, creatinine, and glucose, and a score of 6 or more raises the suspicion of necrotizing fasciitis [8]. The LRINEC score at admission was 1 in the first patient and 8 in the second (Table *1*). The low score in the first patient, despite early skin necrosis, illustrates the limited sensitivity of the score in early or localized disease, such as periorbital involvement, as it was developed mainly in patients with necrotizing infections of the limbs and trunk [8,12]. A low score should therefore not delay surgical exploration. In the second patient, the score was driven by the markedly elevated CRP, hyponatremia, and raised creatinine, while the leukocyte count was normal despite severe sepsis, with marked neutrophilia and lymphopenia. Laboratory and imaging findings should not delay surgical management, as early intervention is critical for the outcome [3,5,12].

Treatment relies on antimicrobial therapy and surgical source control. Empirical antibiotics should be started promptly and cover *S. pyogenes*, *S. aureus* (including methicillin-resistant strains), Gram-negative organisms, and anaerobes. The Infectious Diseases Society of America recommends vancomycin or linezolid combined with piperacillin-tazobactam, a carbapenem, or ceftriaxone plus metronidazole, adjusted to local resistance patterns and individual risk factors [2,5]. Therapy should then be guided by culture and susceptibility results [5]. Both patients received broad-spectrum intravenous antibiotics at presentation, which were de-escalated to penicillin after *S. pyogenes* was identified. This allowed pathogen-specific treatment while limiting unnecessary antimicrobial exposure.

Surgical debridement is the cornerstone of treatment of necrotizing fasciitis in most anatomical sites, and current recommendations favor intervention as early as possible, ideally within six hours of presentation [5,14]. Periorbital necrotizing fasciitis may nevertheless represent a distinct entity. When the infection is limited to the eyelids, without orbital involvement or systemic toxicity, prompt antibiotic therapy with nonaggressive debridement of necrotic tissue after demarcation has achieved good results without immediate extensive surgery [15]. A good outcome with medical management alone has also been reported in eyelid necrotizing fasciitis caused by group A *Streptococcus* [16], and Jordan and Kanda treated six patients with intravenous antibiotics and adjunctive hypochlorous acid irrigation, without periocular debridement [17]. These reports are small and uncontrolled, and most published patients were treated surgically. In a multicenter series, 74% of patients required surgical debridement, with up to five procedures to control the disease [18], and 89.6% of patients in a recent systematic review underwent at least one debridement [7]. Recent case series have also emphasized early and aggressive surgical debridement as critical for infection control [13,19]. In our patients, an aggressive surgical approach was chosen because of the severity of the local disease, its rapid progression, and the marked systemic inflammatory response. Early debridement

aimed to achieve prompt infection control and to prevent further local extension. In the second patient, a further eyelid procedure was needed on D4, as necrosis progressed after the initial debridement. This approach is not without risk. Extensive periorbital surgery may disrupt the orbital septum and allow postseptal spread, a particular concern in the second patient, in whom CT showed no postseptal extension at presentation.

Published series of periocular necrotizing fasciitis show a consistent pattern. In the multicenter series of Rajak et al., which included 29 patients, group A *Streptococcus* was isolated in 86%, 74% underwent debridement, 41% required reconstruction, 14% had visual loss, and one patient died [18]. Tambe et al. reported 11 patients, of whom one died and eight of the ten survivors needed further surgery for eyelid malposition [20]. All nine patients described by Oliver-Gutierrez et al. underwent debridement; two developed toxic shock syndrome, and outcomes ranged from preserved visual acuity to exenteration, without deaths [13]. In the Manchester series, all five patients required reconstruction; three developed orbital compartment syndrome, and two had no light perception at the end of follow-up [21]. The systematic review of 183 patients found *S. pyogenes* in 79.8%, debridement in 89.6%, blindness of the affected eye in 18.2%, and a mortality rate of 4.9% [7]. Our patients are consistent with these series in their microbiology, the need for early and repeated debridement, and the risk of optic nerve damage with orbital extension, but differ in that neither required eyelid reconstruction.

Late complications, such as cicatricial eyelid retraction, ectropion, ptosis, lagophthalmos, and exposure keratopathy, often require reconstructive surgery. The proportion of patients who need reconstruction varies widely across published series, from approximately 41% to 80% [18,20] and reached 100% in a recent series of five patients [21]. The decision between healing by secondary intention and early reconstruction depends on the extent and depth of tissue loss, the integrity of the eyelid margin, tarsus, and levator aponeurosis, and the protection of the cornea. Early grafting or flap reconstruction during the acute phase carries a risk of graft failure in an infected, poorly demarcated wound bed, and the extent of viable tissue is often underestimated before demarcation is complete. The rich vascular supply of the eyelids, which makes necrotizing fasciitis rare in this region, also favors granulation and contraction of the wound, and a substantial proportion of patients may heal satisfactorily without reconstruction. Blanchard et al. described a patient with involvement of all four eyelids who underwent debridement and later healed by secondary intention, with an excellent result and no reconstruction [22]. Early reconstruction is mainly indicated when tissue loss leaves the cornea exposed, such as with full-thickness eyelid defects, loss of the eyelid margin, or lagophthalmos with exposure keratopathy, and temporary measures such as intensive lubrication, a moisture chamber, or tarsorrhaphy may bridge the period until definitive surgery. In both of our patients, the debridement spared the eyelid margin, the tarsus, and the levator function; eyelid closure was preserved, and the cornea remained protected. For these reasons, the wounds were left to heal by secondary intention, with reconstruction deferred until the outcome of healing could be assessed. Both eyelids healed without reconstruction and remained stable at one year, in keeping with previous reports of healing by secondary intention after debridement [22]. Limited tissue loss, early infection control, preservation of the eyelid margin and levator function, and the absence of significant comorbidities may have contributed to this outcome, although two cases do not allow these factors to be assessed.

Eyelid healing, however, does not reflect the overall outcome. Orbital involvement exposes the optic nerve to compression and ischemia. Orbital compartment syndrome occurs when an acute rise in orbital volume, from edema, inflammation, hemorrhage, or abscess, increases orbital pressure within the fixed bony orbit and compromises the perfusion of the optic nerve and retina. It presents with decreased visual acuity, a relative afferent pupillary defect, painful proptosis, a tense orbit with resistance to retropulsion, elevated intraocular pressure, and ophthalmoplegia, and requires immediate lateral canthotomy and cantholysis, as irreversible ischemic damage may develop within hours [23].

In the first patient, the infection extended into the superior extraconal orbit, and he presented with a relative afferent pupillary defect and optic disc edema. Intraocular pressure was only mildly elevated in the affected eye (22 mmHg), the orbit was not tense, and there was no resistance to retropulsion, so orbital compartment syndrome was not suspected and canthotomy was not performed. Although the local infection and the inflammatory markers improved, a follow-up CT on D9 showed progression of the orbital disease, with myositis of the superior rectus and levator complex, marked proptosis, and straightening of the optic nerve. Systemic corticosteroids were started once the infection was controlled to reduce the orbital inflammation, although their benefit in this setting has not been established. He developed optic atrophy with a superior altitudinal visual field defect, which persisted although visual acuity recovered to 0.10 logMAR by M2. The mechanism of the optic neuropathy cannot be established with certainty. Compression and stretching of the optic nerve by the orbital inflammatory process were the most likely causes, but the altitudinal pattern of the field defect also suggests a possible ischemic component through inflammatory involvement of the posterior ciliary circulation. The restrictive hypertropia was attributed to the myositis of the superior rectus and levator complex documented on CT, with subsequent cicatricial restriction, and required strabismus surgery. Visual loss is a recognized complication of periorbital necrotizing fasciitis. Blindness of the affected eye occurred in 18.2% of cases in the systematic review [7] and visual loss in 14% of patients in the multicenter series [18]. Orbital involvement at presentation should therefore prompt close and repeated monitoring of visual acuity, pupillary reactions, color vision, intraocular pressure, and orbital tension during the acute phase, with a low threshold for canthotomy and cantholysis if signs of orbital

compartment syndrome develop. In contrast, the second patient had no orbital involvement and retained normal visual function and full ocular motility, with only mild inferior punctate keratopathy.

This report has limitations. It describes only two patients, retrospectively, and the debrided tissue was not submitted for histopathological examination. The favorable eyelid outcome after secondary intention healing and the mechanism of the optic neuropathy in the first patient therefore cannot be generalized, and larger series are needed to define which patients can safely avoid early reconstruction.

Our experience supports individualized management of periorbital necrotizing fasciitis, guided by the clinical presentation, disease extent, imaging, and response to treatment, with close follow-up and multidisciplinary collaboration to reduce the risk of systemic complications [20].

Conclusions

Periorbital necrotizing fasciitis can occur in adults without classic risk factors and without recalled trauma. Clinical signs such as severe pain, crepitus, and early skin necrosis should prompt urgent surgical evaluation, even when laboratory scores are low. In our two patients with *S. pyogenes* infection, early debridement, targeted antibiotic therapy, and multidisciplinary care controlled the infection, and the eyelids healed by secondary intention without reconstruction, as the eyelid margin, tarsus, and levator function were preserved and the cornea remained protected. Orbital extension in one patient was followed by permanent optic nerve damage despite infection control. Visual function should therefore be monitored closely when the orbit is involved, and surgical decisions should be individualized.

Additional Information

Author Contributions

All authors have reviewed the final version to be published and agreed to be accountable for all aspects of the work.

Concept and design: Vera Sá Araújo, Daniel Abilheira, Carla Ferreira

Acquisition, analysis, or interpretation of data: Vera Sá Araújo, Daniel Abilheira, Cristina Freitas, Carla Ferreira, Cátia Azenha

Drafting of the manuscript: Vera Sá Araújo

Critical review of the manuscript for important intellectual content: Vera Sá Araújo, Daniel Abilheira, Cristina Freitas, Carla Ferreira, Cátia Azenha

Supervision: Cátia Azenha

Disclosures

Human subjects: Informed consent for treatment and open access publication was obtained or waived by all participants in this study. **Conflicts of interest:** In compliance with the ICMJE uniform disclosure form, all authors declare the following: **Payment/services info:** All authors have declared that no financial support was received from any organization for the submitted work. **Financial relationships:** All authors have declared that they have no financial relationships at present or within the previous three years with any organizations that might have an interest in the submitted work. **Other relationships:** All authors have declared that there are no other relationships or activities that could appear to have influenced the submitted work.

References

1. Amrith S, Hosdurga Pai V, Ling WW: Periorbital necrotizing fasciitis - a review . Acta Ophthalmol. 2013, 91:596-603. 10.1111/j.1755-3768.2012.02420.x
2. Lazzeri D, Lazzeri S, Figus M, et al.: Periorbital necrotising fasciitis. Br J Ophthalmol. 2010, 94:1577-85. 10.1136/bjo.2009.167486
3. Ahmadzada S, Rao A, Ghazavi H: Necrotizing fasciitis of the face: current concepts in cause, diagnosis and management. Curr Opin Otolaryngol Head Neck Surg. 2022, 30:270-5. 10.1097/MOO.0000000000000820
4. Raff AB, Kroshinsky D: Cellulitis: a review. JAMA. 2016, 316:325-37. 10.1001/jama.2016.8825
5. Stevens DL, Bisno AL, Chambers HF, et al.: Practice guidelines for the diagnosis and management of skin and soft tissue infections: 2014 update by the Infectious Diseases Society of America. Clin Infect Dis. 2014, 59:e10-52. 10.1093/cid/ciu296
6. Hua C, Urbina T, Bosc R, et al.: Necrotising soft-tissue infections. Lancet Infect Dis. 2023, 23:81-94. 10.1016/S1473-3099(22)00583-7
7. Oliver-Gutierrez D, Ros-Sanchez E, Segura-Duch G, et al.: A closer look at periocular necrotizing fasciitis: a systematic review of literature. Diagnostics (Basel). 2025, 15:1181. 10.3390/diagnostics15091181
8. Wong CH, Khin LW, Heng KS, Tan KC, Low CO: The LRINEC (Laboratory Risk Indicator for Necrotizing

Fasciitis) score: a tool for distinguishing necrotizing fasciitis from other soft tissue infections. Crit Care Med. 2004, 32:1535-41. 10.1097/01.ccm.0000129486.35458.7d
9. Flavahan PW, Cauchi P, Gregory ME, Foot B, Drummond SR: Incidence of periorbital necrotising fasciitis in the UK population: a BOSU study. Br J Ophthalmol. 2014, 98:1177-80. 10.1136/bjophthalmol-2013-304735
10. Chandler JR, Langenbrunner DJ, Stevens ER: The pathogenesis of orbital complications in acute sinusitis . Laryngoscope. 1970, 80:1414-28. 10.1288/00005537-197009000-00007
11. Tsai YH, Chen HY, Huang TY, Chen JL, Hsiao CT, Huang KC: Bullous skin signs and laboratory surgical indicators can quickly and effectively differentiate necrotizing fasciitis from cellulitis. Int J Infect Dis. 2023, 128:41-50. 10.1016/j.ijid.2022.12.012
12. Borschitz T, Schlicht S, Siegel E, Hanke E, von Stebut E: Improvement of a clinical score for necrotizing fasciitis: 'pain out of proportion' and high CRP levels aid the diagnosis. PLoS One. 2015, 10:e0132775. 10.1371/journal.pone.0132775
13. Oliver-Gutierrez D, van der Veen RL, Ros-Sánchez E, et al.: Periorbital necrotizing fasciitis: clinical perspectives on nine cases. Eur J Clin Microbiol Infect Dis. 2024, 43:2053-9. 10.1007/s10096-024-04908-6
14. McDermott J, Kao LS, Keeley JA, Grigorian A, Neville A, de Virgilio C: Necrotizing soft tissue infections: a review. JAMA Surg. 2024, 159:1308-15. 10.1001/jamasurg.2024.3365
15. Luksich JA, Holds JB, Hartstein ME: Conservative management of necrotizing fasciitis of the eyelids . Ophthalmology. 2002, 109:2118-22. 10.1016/S0161-6420(02)01257-5
16. Lee Hooi L, Hou BA, Lay Leng S: Group A Streptococcus necrotizing fasciitis of the eyelid: a case report of good outcome with medical management. Ophthalmic Plast Reconstr Surg. 2012, 28:e13-5. 10.1097/IOP.0b013e31821282ee
17. Jordan DR, Kanda P: Hypochlorous acid as an adjunctive treatment for periocular necrotizing fasciitis . Ophthalmic Plast Reconstr Surg. 2026, 42:473-82. 10.1097/IOP.0000000000003170
18. Rajak SN, Figueira EC, Haridas AS, et al.: Periocular necrotising fasciitis: a multicentre case series. Br J Ophthalmol. 2016, 100:1517-20. 10.1136/bjophthalmol-2015-307445
19. Baur ID, Habert I, Markstaller M, Hartmann K, Mueller A: Streptococcal periorbital necrotizing fasciitis: case series on a rare but potentially life-threatening entity. Heliyon. 2025, 11:e41420. 10.1016/j.heliyon.2024.e41420
20. Tambe K, Tripathi A, Burns J, Sampath R: Multidisciplinary management of periocular necrotising fasciitis: a series of 11 patients. Eye (Lond). 2012, 26:463-7. 10.1038/eye.2011.241
21. Hopkins A, Ng JK, Ku JY, Bull A, Pilson Q, Cook A: Periorbital necrotizing fasciitis: the Manchester experience. BMC Ophthalmol. 2025, 25:221. 10.1186/s12886-025-04062-3
22. Blanchard CC, Gupta L, Timoney PJ: Secondary intention healing after debridement for bilateral periorbital necrotizing fasciitis. Ophthalmic Plast Reconstr Surg. 2024, 40:e164-6. 10.1097/IOP.0000000000002673
23. Lima V, Burt B, Leibovitch I, Prabhakaran V, Goldberg RA, Selva D: Orbital compartment syndrome: the ophthalmic surgical emergency. Surv Ophthalmol. 2009, 54:441-9. 10.1016/j.survophthal.2009.04.005