Cureus
Part of SPRINGER NATURE

Open Access Case Report

Probable Parvovirus B19-Associated Optic Neuritis and Prolonged Viral DNA Detection During Subsequent Pregnancy in an Immunocompetent Adult

Review began 10/23/2026
Review ended 11/21/2026
Published 11/26/2026

© Copyright 2026
Faria et al. This is an open access article distributed under the terms of the Creative Commons Attribution License CC-BY 4.0., which permits unrestricted use, distribution, and reproduction in any medium, provided the original author and source are credited.

DOI: 10.7759/cureus.120311

Flávia Faria [1], Filipa P. Ferreira [1], Joana Cardoso [1], Soraia Almeida [1, 2], Ana Cipriano [1]

1. Department of Infectious Diseases, Unidade Local de Saúde de Santo António, Porto, PRT 2. Department of Infection Prevention and Control and Antimicrobial Resistance, Unidade Local de Saúde de Santo António, Porto, PRT

Corresponding author: Flávia Faria, ffaria82@hotmail.com

Abstract

Human parvovirus B19 (PVB19) can cause neurological manifestations, although optic neuritis is rarely reported. We describe a 39-year-old immunocompetent pediatrician with antiphospholipid syndrome (APS) not receiving immunosuppressive therapy, who presented with acute unilateral visual loss following recent occupational exposure to PVB19. Clinical, ophthalmological, and neuroimaging findings supported a diagnosis of right optic neuritis. PVB19 DNA was detected in cerebrospinal fluid (CSF) by a qualitative polymerase chain reaction (PCR) assay. Initial PVB19 serology was IgM-positive and IgG-negative, followed by IgG seroconversion; a maculopapular rash developed six days after symptom onset. Visual recovery occurred after intravenous immunoglobulin (IVIG) was added to high-dose corticosteroid therapy. During follow-up, the patient experienced two first-trimester miscarriages, approximately two and nine months after the acute infection. At approximately 14 months after the initial infection, when the patient was 10 weeks pregnant, serum PVB19 deoxyribonucleic acid (DNA) was quantified for the first time at 2,055 copies/mL; IgM and IgG remained positive. After multidisciplinary discussion, IVIG was not administered because its benefit was uncertain and its potential thrombotic risk was considered. Serial obstetric ultrasound examinations were normal, and a healthy term infant was delivered.

This case highlights the importance of considering PVB19 in the differential diagnosis of acute optic neuritis and the challenge of interpreting prolonged IgM positivity and prolonged serum DNA detection after acute infection, particularly during a subsequent pregnancy. Molecular results should be interpreted alongside clinical, virological, and obstetric findings rather than as proof of active infection.

Categories: Obstetrics/Gynecology, Neurology, Infectious Disease
Keywords: immunocompetent adult, optic neuritis, parvovirus b19, pregnancy, prolonged viral dna detection

Introduction

Human parvovirus B19 (PVB19) is a ubiquitous, single-stranded deoxyribonucleic acid (DNA) virus transmitted mainly through respiratory droplets, although vertical transmission, blood transfusion, and solid organ transplantation are also recognized routes of transmission. Seroprevalence increases with age, reflecting cumulative lifetime exposure. Infection may be asymptomatic or present with hematologic, dermatologic, rheumatologic, and systemic manifestations. Maternal infection during pregnancy can be associated with fetal complications, including anemia, hydrops, and pregnancy loss [1-3]. Neurological involvement is uncommon but has been reported in both the central and peripheral nervous systems [4-7]. Optic neuritis may be idiopathic or occur in association with multiple sclerosis, neuromyelitis optica spectrum disorder (NMOSD), myelin oligodendrocyte glycoprotein antibody-associated disease (MOGAD), or infection [8,9]. Optic nerve involvement has rarely been reported in association with PVB19 infection [10,11].

Diagnosis of acute infection relies on serology and molecular testing. PVB19-specific IgM generally supports recent infection and remains detectable for three to four months, whereas IgG indicates previous exposure and immune response [1-3]. Polymerase chain reaction (PCR) can detect PVB19 DNA in cerebrospinal fluid (CSF) and other specimens, but a positive result alone does not establish ongoing viral replication and should be interpreted in the clinical and serological context [1,3-5,12].

We report a case of probable PVB19-associated optic neuritis in an immunocompetent adult, followed by two first-trimester miscarriages and prolonged IgM positivity with low-level serum PVB19 DNA detection during a subsequent pregnancy. This case illustrates the diagnostic challenge of assessing optic neuritis in the context of recent PVB19 exposure and the uncertain clinical significance of prolonged serological and molecular findings, particularly during pregnancy. The longitudinal virological and obstetric follow-up provides a framework for individualized assessment of possible fetal risk and treatment decisions.

How to cite this article
Faria F, Ferreira F P, Cardoso J, et al. (November 26, 2026) Probable Parvovirus B19-Associated Optic Neuritis and Prolonged Viral DNA Detection During Subsequent Pregnancy in an Immunocompetent Adult. Cureus 18(11): e120311. DOI 10.7759/cureus.120311

The optic neuritis component of this case was previously presented as a poster at the 35th Congress of the European Society of Clinical Microbiology and Infectious Diseases (ESCMID Global), held in Vienna, Austria, on April 11-15, 2025. The present report adds longitudinal virological and obstetric follow-up.

Case Presentation

A 39-year-old paediatrician with antiphospholipid syndrome (APS), diagnosed in 2007 after right lower limb deep vein thrombosis complicated by pulmonary embolism and managed with chronic anticoagulation, presented to the emergency department with sudden visual loss in the right eye and mild ocular discomfort, without pain on eye movements. She reported recent occupational contact with children diagnosed with PVB19 infection, but the interval between exposure and symptom onset could not be established. She was not receiving immunosuppressive therapy.

Neurological and ophthalmological assessment revealed reduced right visual acuity and a right relative afferent pupillary defect. Best-corrected visual acuity was 0.32 (approximately 20/63; logMAR 0.50) in the right eye and 1.0 (20/20; logMAR 0.00) in the left eye. Ishihara colour vision testing showed 0/10 correct responses in the right eye, consistent with marked dyschromatopsia. Funduscopic examination and optical coherence tomography (OCT) of the macula and optic nerve head showed no retinal or macular abnormalities and symmetric retinal nerve fibre layer thickness. Formal visual field testing was not performed at initial presentation.

Brain and orbital magnetic resonance imaging (MRI) demonstrated thickening of the intraorbital segment of the right optic nerve, with hyperintensity on the T2-weighted fluid-attenuated inversion recovery (T2-FLAIR) sequence and focal enhancement on the postcontrast T1-weighted sequence (Figures *1A*, *1B*). No demyelinating lesions were identified in the brain or spinal cord. CSF obtained during the initial assessment showed mild pleocytosis (7 leukocytes/µL) with normal protein and glucose levels. Oligoclonal bands were absent in CSF, and free kappa light chains were normal in serum and absent in CSF. Blood tests revealed mild anaemia, with a haemoglobin concentration of 11.7 g/dL; other reported results were unremarkable.

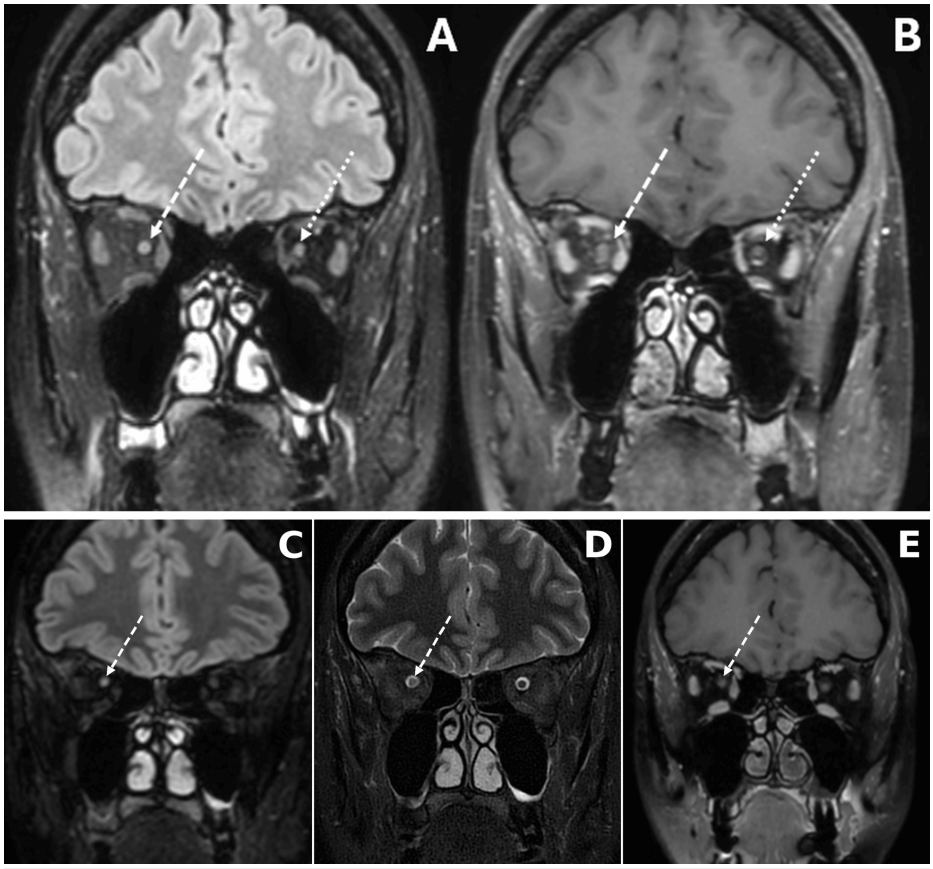

FIGURE 1: Orbital magnetic resonance imaging (MRI) at presentation (top row) and at the six-month follow-up (bottom row).

Coronal images. (A) At presentation, increased signal intensity of the right intraorbital optic nerve on the T2-weighted fluid-attenuated inversion recovery (T2-FLAIR) sequence, with (B) corresponding right optic nerve enhancement on the postcontrast T1-weighted sequence. At the six-month follow-up, (C) coronal reformatted three-dimensional FLAIR (3D FLAIR) and (D) short tau inversion recovery (STIR) images show a mild residual focal hyperintensity of the right intraorbital optic nerve, with persistent mild asymmetry of the T2 signal compared with the left; (E) the postcontrast fat-saturated 3D T1-weighted sequence shows no optic nerve enhancement, and there is no evidence of optic nerve atrophy. STIR was not acquired at baseline and is shown as additional follow-up information. Because the MRI sequences were not identical between examinations, comparisons are qualitative (presence or absence of findings) rather than quantitative. Dashed arrows indicate the right optic nerve; dotted arrows (A, B) indicate the left optic nerve.

Based on clinical, ophthalmological, and MRI findings, a diagnosis of right optic neuritis was established, and intravenous methylprednisolone was started at 1 g daily for five days in an outpatient clinic. After three days of treatment, right-eye visual acuity had decreased to a nadir of 0.2 with correction (20/100; logMAR 0.70). The CSF multiplex real-time PCR viral panel detected PVB19 DNA, with the result reported qualitatively. No other viruses targeted by the panel were detected. Given the persistent visual symptoms and the positive CSF PVB19 PCR result, she was admitted for further management, and IVIG was added at 0.4 g/kg/day for five days.

Serological testing showed positive PVB19 IgM and negative IgG, a pattern consistent with recent primary infection. Autoimmune and infectious investigations, including antinuclear antibodies, anti-double-stranded DNA antibodies, complement levels, immunoglobulins (IgMs), syphilis serology and human immunodeficiency virus testing were unremarkable. Antibodies to aquaporin-4 (AQP4) and myelin oligodendrocyte glycoprotein (MOG) were assessed using a fixed cell-based assay (Euroimmun, EUROIMMUN Medizinische Labordiagnostika AG, Lübeck, Germany) with indirect immunofluorescence. The same method was used for all three samples, collected before corticosteroid and IVIG administration, on day 2 of IVIG, and three weeks after the first IVIG dose, respectively. All three yielded uninterpretable results because of laboratory-reported interference, the cause of which could not be determined. These results were not interpreted as negative.

On day 6 after symptom onset, corresponding to day three of IVIG administration, a maculopapular rash developed on the arms and abdomen. On the final day of IVIG treatment, at hospital discharge, right visual acuity was 1.0 with contact lenses (20/20; logMAR 0.00), and no residual dyschromatopsia was documented

in the right eye. A faint right relative afferent pupillary defect remained. Formal perimetry was not performed during the acute episode. During subsequent Neurology and Clinical Immunology follow-up, she reported no further visual or other neurological symptoms. However, she did not attend ophthalmology follow-up, making the discharge assessment the last available quantitative visual acuity measurement. At the six-month follow-up, MRI showed mild residual T2 signal asymmetry in the intraorbital right optic nerve, without contrast enhancement or optic nerve atrophy (Figures *1C*-*1E*).

Two and nine months after the acute infection, the patient experienced first-trimester miscarriages, each occurring at approximately six to seven weeks' gestation. Histopathological examination of products of conception after the second miscarriage documented a retained first-trimester pregnancy loss, without morphological evidence of trophoblastic disease or other specific fetal abnormalities. No PVB19-specific testing was performed on the products of conception. No histopathological examination was performed after the first miscarriage. Both losses occurred while the patient was receiving enoxaparin (60 mg twice daily), aspirin (150 mg daily), and hydroxychloroquine (400 mg daily), a regimen also used during a successful pregnancy five years before the PVB19 infection.

The first serological reassessment after the acute episode, performed at month 8, showed an IgM index of 30.0 and an IgG concentration of 63.87 IU/mL, documenting IgG seroconversion.

The patient subsequently became pregnant approximately 12 months after the acute infection. To further optimise prophylaxis against APS-related pregnancy loss, low-dose oral prednisolone (10 mg daily) was added to her existing APS regimen during the first trimester. Enoxaparin, aspirin, and hydroxychloroquine were maintained throughout pregnancy. She was referred for infectious diseases assessment at 10 weeks' gestation, approximately 14 months after the acute infection. At that time, IgM and IgG remained positive, and serum PVB19 DNA was quantified for the first time using monoplex quantitative real-time PCR, yielding 2,055 copies/mL. Both antibodies remained positive, and serum PVB19 DNA remained detectable throughout pregnancy; at month 20, approximately at the time of delivery, the IgM index was 14.7 (Figure *2*).

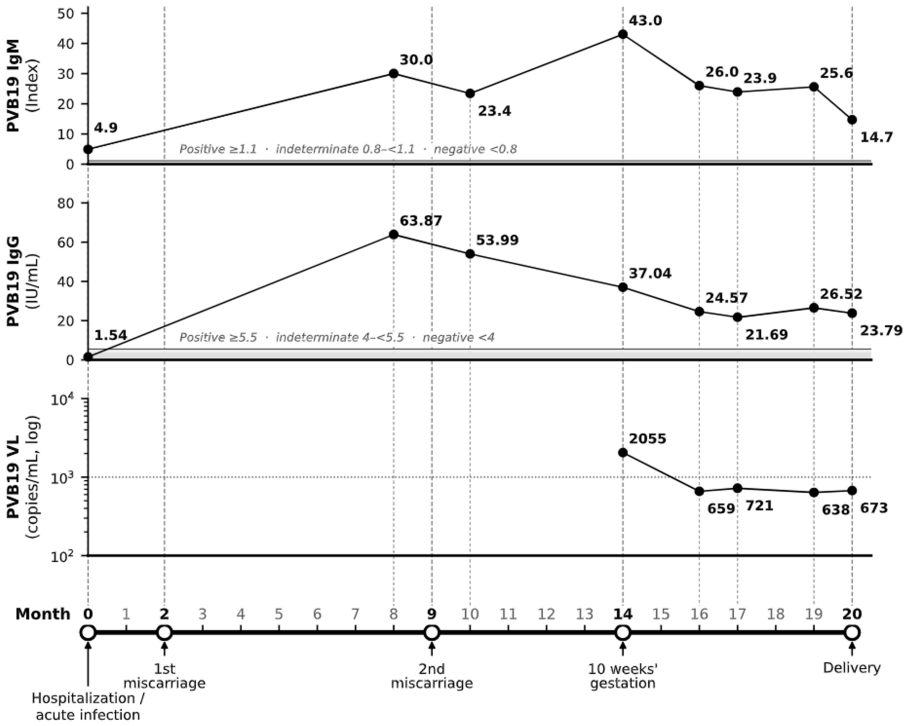

FIGURE 2: Longitudinal serum parvovirus B19 serological and molecular results after the acute episode.

PVB19 IgM (index), PVB19 IgG (IU/mL) and serum PVB19 DNA viral load (copies/mL, logarithmic scale) are shown in separate panels sharing a common time axis. Numerical labels indicate the measured value at each time point. The timeline at the bottom shows months after the acute episode (month 0, hospitalization/acute infection). Open circles and arrows mark clinical events, with the corresponding months shown in bold: first miscarriage (month 2), second miscarriage (month 9), assessment at 10 weeks' gestation (approximately month 14), and delivery (approximately month 20). Darker vertical dashed lines extend from each clinical event across all panels; lighter vertical dashed lines align each measurement with its month on the timeline. Serum PVB19 DNA was not measured before month 14; the absence of earlier measurements does not indicate negative results. Lines connect available measurements and do not represent continuous monitoring. IgM values <0.8 were classified as negative, 0.8 to <1.1 as indeterminate, and ≥1.1 as positive. IgG values <4 IU/mL were classified as negative, 4 to <5.5 IU/mL as indeterminate, and ≥5.5 IU/mL as positive.

Abbreviations: PVB19, parvovirus B19; IgM, immunoglobulin M; IgG, immunoglobulin G; DNA, deoxyribonucleic acid; IU, international units; VL, viral load.

A multidisciplinary discussion was held to consider IVIG in view of prolonged PVB19 IgM positivity, detectable serum DNA, and the two preceding miscarriages. Following an individual risk-benefit assessment, IVIG was not administered.

Close surveillance with serial obstetric ultrasound examinations was maintained throughout gestation. The pregnancy progressed without reported complications, and an elective cesarean delivery was performed at 39 weeks' gestation. A healthy male infant was delivered, weighing 3,430 g, with Apgar scores of 9 at one, five, and 10 minutes. The infant was not tested for PVB19. Mother and infant remained asymptomatic at the six-month follow-up.

Discussion

Although neurological involvement in PVB19 infection is uncommon, it may affect both the central and peripheral nervous systems [4-7], and optic neuritis has rarely been reported [10,11]. In the present patient, acute unilateral visual loss, a relative afferent pupillary defect, red dyschromatopsia, and orbital MRI findings of optic nerve T2-FLAIR hyperintensity, thickening, and focal enhancement supported a diagnosis of optic neuritis [8]. The absence of typical brain or spinal cord demyelinating lesions and negative CSF oligoclonal bands made multiple sclerosis less likely, but it could not be excluded [13]. Ophthalmological assessment, including OCT, did not identify retinal or macular pathology.

The temporal association with recent PVB19 infection is supported by occupational exposure, an initial IgM-positive/IgG-negative serological profile followed by IgG seroconversion, a subsequent exanthem, and detection of PVB19 DNA in CSF [1-3]. The exact pathogenesis of PVB19-associated neurological disease

remains uncertain; proposed mechanisms include direct viral involvement and immune-mediated injury [4,7]. CSF PCR documents viral DNA in the sampled compartment, but does not establish direct optic nerve injury or distinguish direct infection from an immune-mediated process [1,4,5]. Taken together, these findings support a diagnosis of probable PVB19-associated optic neuritis, although causation cannot be definitively established.

The lack of interpretable AQP4 and MOG antibody results because of sample-related interference limited the assessment of NMOSD and MOGAD. No optic disc oedema was documented, and neuroimaging showed unilateral, focal intraorbital optic nerve involvement without chiasmal or posterior visual pathway involvement or additional central nervous system lesions. These findings were atypical for both MOGAD, which more frequently involves bilateral anterior optic nerve involvement with optic disc oedema, and NMOSD, which more frequently involves posterior optic pathways, including the chiasm, and may be associated with characteristic brain or spinal cord lesions [8,9]. Although these atypical features made both diagnoses less likely, they could not be definitively excluded because antibody results were uninterpretable.

No standardised treatment has been established for PVB19-associated neurological disease. Corticosteroids and IVIG have been reported in individual cases and case series, but these observations do not establish treatment efficacy [4,6]. In this patient, visual recovery occurred after IVIG was added to corticosteroids. Because treatment was combined and optic neuritis may improve spontaneously or in response to corticosteroids, the individual contributions of IVIG, corticosteroids, and spontaneous recovery cannot be determined [8].

Quantitative serum PCR was first performed approximately 14 months after the acute infection, when the patient was 10 weeks pregnant and asymptomatic, showing 2,055 copies/mL. Subsequent measurements at months 16, 17, 19, and 20 were 659, 721, 638, and 673 copies/mL, respectively; IgM and IgG remained positive. The IgM index increased from 23.4 at month 10 to 43.0 at month 14, but the significance of this fluctuation remains uncertain. The available data do not establish reinfection or distinguish biological variation in persistent IgM reactivity from analytical variability or assay interference. These findings, together with the preceding miscarriages, raised concern about possible persistent infection.

However, prolonged low-level detection of PVB19 DNA may reflect residual viral genetic material rather than active replication, including in immunocompetent individuals [1,5,12,14]. No quantitative serum measurements were available during the acute episode or at either miscarriage, preventing assessment of acute-phase viral load kinetics or confirmation of continuous DNA detection from the acute infection onward. The available results, therefore, document prolonged detection of serum DNA but do not establish persistent active infection.

Two first-trimester miscarriages occurred approximately two and nine months after the acute infection, both at six to seven weeks' gestation. Although maternal PVB19 infection can be associated with pregnancy loss [1-3], APS, a thrombophilia associated with thrombosis and pregnancy loss, provides an important alternative explanation, even during antithrombotic treatment [15]. Histopathology, available only after the second loss, did not establish a specific aetiology; neither PVB19-specific testing of the products of conception nor maternal viral-load measurements at either miscarriage were available. These limitations preclude reliable distinction between APS-related pregnancy loss and a possible viral or inflammatory contribution, particularly for the second loss, which occurred more remotely from the acute infection.

The subsequent pregnancy began approximately 12 months after the acute infection. Management included anticoagulation, aspirin, hydroxychloroquine, and first-trimester low-dose prednisolone to further reduce the risk of APS-related pregnancy loss [15]. The expected benefit of IVIG was uncertain because prolonged PVB19 DNA detection did not establish active infection, its contribution to the preceding miscarriages remained unclear, and there were no maternal symptoms or documented fetal abnormalities. This uncertainty, weighed against the potential thrombotic risk of IVIG in a patient with established thrombotic APS, favoured surveillance over treatment.

Despite prolonged low-level serum PVB19 DNA detection, the subsequent pregnancy was not accompanied by reported maternal symptoms or detected fetal abnormalities and resulted in the delivery of a healthy term infant.

Conclusions

PVB19 infection should be considered in the differential diagnosis of acute optic neuritis when clinical, epidemiological, serological, and molecular findings are compatible. This case also illustrates the challenge of interpreting prolonged IgM positivity and low-level serum PVB19 DNA detection after acute infection, particularly in a patient with subsequent pregnancy loss. Molecular results should therefore be interpreted alongside symptoms, available viral-load measurements, serology, and obstetric findings, rather than as proof of active infection. In comparable clinical scenarios, management decisions should ideally be informed by prospective evidence and multidisciplinary input, including maternal-fetal medicine and infectious diseases expertise, to avoid unnecessary treatment while maintaining appropriate surveillance.

Additional Information

Author Contributions

All authors have reviewed the final version to be published and agreed to be accountable for all aspects of the work.

Concept and design: Flávia Faria, Filipa P. Ferreira, Joana Cardoso, Soraia Almeida, Ana Cipriano

Acquisition, analysis, or interpretation of data: Flávia Faria

Drafting of the manuscript: Flávia Faria, Filipa P. Ferreira

Critical review of the manuscript for important intellectual content: Joana Cardoso, Soraia Almeida, Ana Cipriano

Supervision: Soraia Almeida, Ana Cipriano

Disclosures

Human subjects: Informed consent for treatment and open access publication was obtained or waived by all participants in this study. **Conflicts of interest:** In compliance with the ICMJE uniform disclosure form, all authors declare the following: **Payment/services info:** All authors have declared that no financial support was received from any organization for the submitted work. **Financial relationships:** All authors have declared that they have no financial relationships at present or within the previous three years with any organizations that might have an interest in the submitted work. **Other relationships:** All authors have declared that there are no other relationships or activities that could appear to have influenced the submitted work.

Acknowledgements

The authors thank the Immunology, Neurology, Ophthalmology and Neuroradiology teams of Unidade Local de Saúde de Santo António, Porto, Portugal, for their valuable contributions to the diagnostic assessment and management of this case. All images included in this manuscript are original.

References

1. Broliden K, Tolfvenstam T, Norbeck O: Clinical aspects of parvovirus B19 infection. J Intern Med. 2006, 260:285-304. 10.1111/j.1365-2796.2006.01697.x
2. Dittmer FP, Guimarães CM, Peixoto AB, Pontes KF, Bonasoni MP, Tonni G, Araujo Júnior E: Parvovirus B19 infection and pregnancy: review of the current knowledge. J Pers Med. 2024, 14:139. 10.3390/jpm14020139
3. Servey JT, Reamy BV, Hodge J: Clinical presentations of parvovirus B19 infection. Am Fam Physician. 2007, 75:373-6.
4. Barah F, Whiteside S, Batista S, Morris J: Neurological aspects of human parvovirus B19 infection: a systematic review. Rev Med Virol. 2014, 24:154-68. 10.1002/rmv.1782
5. Douvoyiannis M, Litman N, Goldman DL: Neurologic manifestations associated with parvovirus B19 infection. Clin Infect Dis. 2009, 48:1713-23. 10.1086/599042
6. Jun JS, Moon J, Byun JI, et al.: Clinical manifestations and treatment outcomes of parvovirus B19 encephalitis in immunocompetent adults. J Neurovirol. 2017, 23:903-7. 10.1007/s13365-017-0568-2
7. Veintimilla C, Catalán P, Estévez A, Alonso R, Valerio M, Muñoz P: Neurologic manifestations associated with parvovirus B19 epidemic, Madrid, Spain, 2024. Emerg Infect Dis. 2025, 31:1621-4. 10.3201/eid3108.250278
8. Wilhelm H, Schabet M: The diagnosis and treatment of optic neuritis . Dtsch Arztebl Int. 2015, 112:616-25; quiz 626. 10.3238/arztebl.2015.0616
9. Chen JJ, Pittock SJ, Flanagan EP, Lennon VA, Bhatti MT: Optic neuritis in the era of biomarkers . Surv Ophthalmol. 2020, 65:12-7. 10.1016/j.survophthal.2019.08.001
10. Barash J, Dushnitzky D, Sthoeger D, Bardenstein R, Barak Y: Human parvovirus B19 infection in children: uncommon clinical presentations. Isr Med Assoc J. 2002, 4:763-5.
11. Wilhelm H, Hartmann C, Boesche-Abele V: Optic neuropathy after erythema infectiosum (Article in German). Klin Monbl Augenheilkd. 1998, 213:355-7. 10.1055/s-2008-1035002
12. Pedranti MS, Barbero P, Wolff C, Ghietto LM, Zapata M, Adamo MP: Infection and immunity for human parvovirus B19 in patients with febrile exanthema. Epidemiol Infect. 2012, 140:454-61. 10.1017/S0950268811000823
13. Nilsson P, Larsson EM, Maly-Sundgren P, Perfekt R, Sandberg-Wollheim M: Predicting the outcome of optic neuritis: evaluation of risk factors after 30 years of follow-up. J Neurol. 2005, 252:396-402. 10.1007/s00415-005-0655-9
14. Molenaar-de Backer MW, Russcher A, Kroes AC, Koppelman MH, Lanfermeijer M, Zaaijer HL: Detection of parvovirus B19 DNA in blood: viruses or DNA remnants?. J Clin Virol. 2016, 84:19-23. 10.1016/j.jcv.2016.09.004
15. Tektonidou MG, Andreoli L, Limper M, Tincani A, Ward MM: Management of thrombotic and obstetric antiphospholipid syndrome: a systematic literature review informing the EULAR recommendations for the management of antiphospholipid syndrome in adults. RMD Open. 2019, 5:e000924. 10.1136/rmdopen-2019-

000924