Cureus
Part of SPRINGER NATURE

Open Access Case Report

Multisystem Syphilis Mimicking Malignancy, Sarcoidosis, and IgG4-Related Disease: A Diagnostic Challenge

Katherine Irwin [1], Nilofar Samadi [1], Lucy Main [1]

1. Dermatology, Torbay Hospital, Torquay, GBR

Corresponding author: Katherine Irwin, kerirwin@gmail.com

Review began 11/11/2026
Review ended 11/16/2026
Published 11/20/2026

© Copyright 2026
Irwin et al. This is an open access article distributed under the terms of the Creative Commons Attribution License CC-BY 4.0., which permits unrestricted use, distribution, and reproduction in any medium, provided the original author and source are credited.

DOI: 10.7759/cureus.120007

Abstract

A 66-year-old man had a 16 mm right lower lobe pulmonary nodule identified on a computed tomography (CT) scan performed as part of the lung cancer screening program. Biopsy of the pulmonary lesion demonstrated granulomatous inflammation, and sarcoidosis was considered the most likely diagnosis. Subsequent positron emission tomography (PET) imaging, performed as part of the evaluation of the pulmonary nodule, identified high uptake of the pulmonary nodule as well as multiple metabolically active cutaneous lesions that had not been the primary focus of his initial presentation. Clinical examination revealed multiple annular erythematous skin lesions, and biopsy again demonstrated granulomatous inflammation, further supporting a diagnosis of sarcoidosis.

He subsequently developed bilateral testicular lesions and underwent right orchidectomy. Histopathological examination of the testis raised the possibility of IgG4-related disease. Despite multidisciplinary review of the pulmonary, cutaneous, and testicular findings, no unifying diagnosis was established. The patient improved following treatment with prednisolone, with resolution of the pulmonary nodule and marked improvement in his cutaneous lesions and respiratory symptoms. However, the underlying diagnosis remained uncertain for more than two years.

Further investigation demonstrated positive syphilis serology, with a rapid plasma reagin titer of 1:16. Re-examination of tissue specimens from the lung, skin, and testis identified spirochetes, confirming multisystem syphilitic involvement. Serum IgG4 levels and subclasses were normal, and HIV testing was negative. The patient was treated with intravenous ceftriaxone 2 g daily for 14 days. Follow-up ultrasonography demonstrated complete resolution of the contralateral testicular lesion, with skin lesions almost completely resolving one month after treatment with antibiotics.

Categories: Urology, Pulmonology, Dermatology
Keywords: cutaneous granulomatous disease, pet-avid pulmonary nodule, pulmonary nodule, syphilis, tertiary syphilis, testicular gummata

Introduction

Syphilis is a multisystem infection caused by the Gram-negative spirochete *Treponema pallidum* [1]. It is primarily transmitted through sexual contact, although vertical transmission from mother to fetus and, rarely, transmission via blood products can occur [2].

Syphilis is classified as early disease (within the first year following inoculation) and late disease (more than one year after inoculation) [3]. The clinical course of untreated symptomatic syphilis classically progresses through primary, secondary, latent, and tertiary stages [4].

Primary syphilis typically develops approximately 21 days after exposure and most commonly presents as a painless chancre at the site of inoculation, usually involving the anogenital region [5].

Secondary syphilis reflects the systemic dissemination of *T. pallidum*, usually occurring between 2 and 12 weeks after the development of the primary lesion [4,5]. Clinical manifestations are highly variable and may include a diffuse non-vesicular rash, mucocutaneous lesions, generalized lymphadenopathy, constitutional symptoms, and neurological involvement [5].

Following secondary disease, patients may enter a latent phase during which infection persists in the absence of clinical symptoms. Without treatment, syphilis can progress to tertiary disease, which may occur years to decades after the initial infection. Tertiary syphilis can affect multiple organ systems, giving rise to neurosyphilis, cardiovascular syphilis, and gummatous disease [5].

The usual first-line treatment for syphilis is penicillin, most commonly intramuscular benzathine benzylpenicillin, with the regimen depending on the stage of disease [2]. Timely treatment is highly

effective at preventing disease progression and onward transmission.

The incidence of syphilis has increased substantially in the United Kingdom over the past decade, with rising rates reported among men who have sex with men, heterosexual individuals, and pregnant women [6].

Despite its well-recognized clinical spectrum, syphilis can occasionally present with atypical multisystem involvement, posing considerable diagnostic challenges. Pulmonary involvement is uncommon and may present with non-specific radiological findings, mimicking infective, inflammatory, or malignant processes. Testicular involvement is also rare and may present with focal lesions that clinically and radiologically resemble testicular malignancy. Bilateral testicular involvement is particularly unusual and broadens the differential diagnosis to include systemic infective and inflammatory conditions [1]. The concurrent pulmonary, cutaneous, and bilateral testicular involvement in this case represents a distinctive multisystem presentation, highlighting the diagnostic challenges associated with atypical manifestations of syphilis. This case emphasizes the importance of considering syphilis in the differential diagnosis of patients presenting with multisystem disease that may otherwise suggest malignancy or granulomatous inflammatory disorders.

Case Presentation

Month 0: initial presentation and investigation of a pulmonary nodule

A 66-year-old man with a past medical history of coronary artery disease, thoracic and abdominal aortic aneurysms, and emphysema underwent low-dose, non-contrast computed tomography (CT) of his chest as part of the lung cancer screening program. He was a current smoker with a 38 pack-year smoking history.

The low-dose CT of the thorax demonstrated a 16 mm right lower lobe pulmonary nodule, alongside established emphysema and known thoracic aortic dilatation (Figure *1*). At respiratory review, he described six months of dyspnea and unintentional weight loss of 6 kg. A positron emission tomography (PET) scan was requested to further characterize the pulmonary lesion.



FIGURE 1: Low-dose CT of the thorax performed as part of the lung cancer screening program, demonstrating a right lower lobe pulmonary nodule

PET imaging was subsequently reviewed at the lung cancer multidisciplinary team (MDT) meeting. It demonstrated intense uptake within the right lower lobe nodule, without additional pulmonary uptake. In addition, cutaneous uptake involving the head, neck, and upper back was identified (Figure *2*).

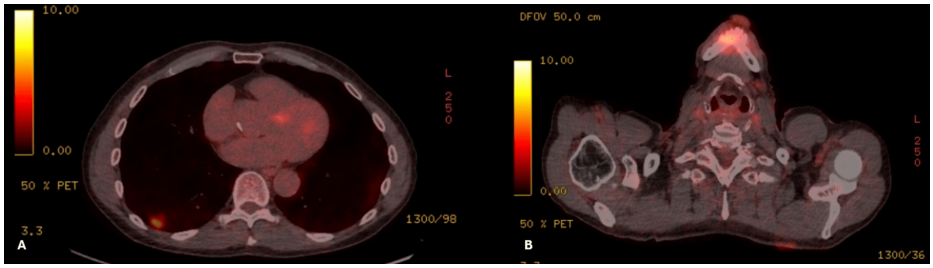

FIGURE 2: Positron emission tomography (PET) scan

(A) A 17 mm solid, non-calcified nodule in the posterior subpleural region of the right lower lobe, demonstrating intense FDG uptake with a maximum standardized uptake value (SUVmax) of 6.8. (B) An FDG-avid cutaneous focus at the level of T1 in the posterior left upper back.

The nodule raised concern for pulmonary malignancy, and a non-contrast CT-guided biopsy of the lesion was arranged, which subsequently demonstrated granulomatous inflammation without evidence of malignancy (Figure *3*). Although pulmonary sarcoidosis was considered, the presence of a solitary pulmonary nodule without associated lymphadenopathy or other radiological features of sarcoidosis was considered atypical. Further MDT discussion concluded that the histology taken was definitely representative of the nodule and therefore unlikely to be a malignancy. Interval CT surveillance was planned.

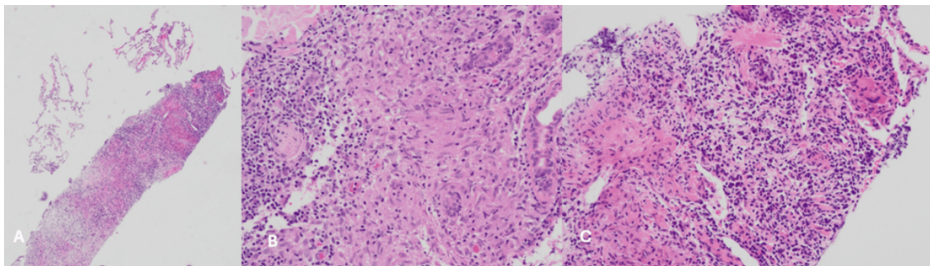

FIGURE 3: Histology from the core biopsy of the right lung nodule

(A) Low-power view demonstrating granulomatous inflammation within the lung tissue. (B) Higher-power view showing granulomatous inflammation with multinucleated giant cells. (C) Higher-power view demonstrating granulomatous inflammation without evidence of central necrosis.

All sections were stained with hematoxylin and eosin (H&E). Original magnifications: (A) ×40, (B) ×100, (C) ×100.

Month 2 (after initial presentation): assessment of cutaneous lesions by dermatology

This gentleman was referred to dermatology given the cutaneous findings on the PET scan. At this appointment, the patient reported a six-month history of pink-red, annular lesions distributed across his body. The lesions were raised and rubbery to palpation, with intermittent scaling. The first lesion had appeared on his left thigh and subsequently resolved, leaving residual induration. On examination, multiple active lesions were present on the back, scalp, neck, and upper back (Figure *4*) measuring approximately 5-40 mm in diameter. Dermoscopy was reported as "featureless," and there was no palpable lymphadenopathy.



FIGURE 4: Skin lesion on the upper back, with the black circle indicating the site of the 6 mm-deep punch biopsy

Differential diagnoses included cutaneous lymphoma, cutaneous sarcoidosis, and cutaneous lupus erythematosus. An urgent 6 mm skin punch biopsy was performed. The histology demonstrated a granulomatous dermatitis, which was extremely extensive (Figure *5*). Special stains for microorganisms were negative, and the pattern was interpreted to be consistent with sarcoidosis. Topical corticosteroids were prescribed.

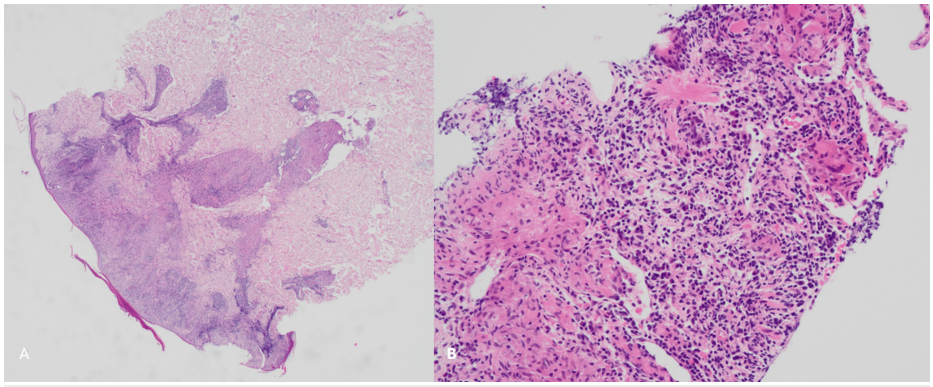

FIGURE 5: 6 mm punch biopsy of the upper back skin

(A) Low-power view demonstrating a granulomatous inflammatory infiltrate within the dermis. (B) Higher-power view showing well-formed, non-caseating granulomas.

Sections stained with hematoxylin and eosin (H&E). Original magnifications: (A) ×40; (B) ×100.

Month 4: development of bilateral testicular lesions

Two months later, the patient presented to the emergency department with a two-week history of right testicular swelling. Examination revealed an enlarged, hard, and painless right testis with a palpable mass. There were no clinical features of epididymitis, no inguinal hernia, and no abdominal tenderness. He denied genital skin changes, urethral discharge, or urinary symptoms. He did report weight loss but no night sweats or fevers. He reported no new sexual partners and that he lived with his wife, whom he had been married to for many years.

Urological assessment included serum tumor markers alpha-fetoprotein, human chorionic gonadotropin, lactate dehydrogenase, and testicular ultrasonography.

Imaging demonstrated bilateral testicular lesions, with a substantial right-sided mass and a smaller lesion in the left testis (Figure *6*). Tumor markers came back normal. These results were discussed with the Urological Cancer MDT, and based on his previous pulmonary and skin investigations being suggestive of sarcoidosis, the patient was given the choice between a biopsy of the right testicle or a right orchidectomy for diagnostic purposes and to rule out malignancy. Given the large size of the right-testicular lesion that occupied most of the right testis, the patient decided to have a right orchidectomy. Surveillance of the left testicular lesion was planned.

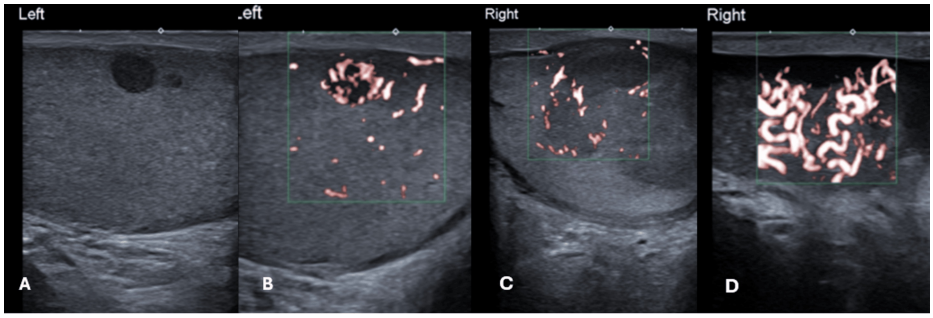

FIGURE 6: Ultrasonography of the testes demonstrating bilateral testicular tumors

(A) Left testicle containing a 5 mm solid hypoechoic lesion. (B) Vascular nature of the left testicular lesion. (C) Right testicle containing a 3.5 cm heterogeneous solid mass within it. (D) Vascular nature of the right testicular lesion.

Month 7: diagnostic uncertainty and consideration of IgG4-related disease

Following orchidectomy, the testicular histology was reported: the sections of the testicular tumor showed extensive areas of nodular fibrosis with a perivascular disposition intercalated with an inflammatory infiltrate of lymphocytes and plasma cells (Figure 7). Immunohistochemical staining demonstrated an IgG4-positive plasma cell infiltrate, and the report concluded that features were considered consistent with IgG4 disease. At subsequent respiratory review, the working diagnosis was pulmonary and cutaneous sarcoidosis, with possible IgG4-related testicular disease. At this appointment, the patient also described severe morning ocular discomfort. He was referred for ophthalmological review. Although the pulmonary disease alone would not ordinarily have warranted systemic treatment, prednisolone was commenced because of concern regarding possible ocular involvement. The steroid weaning plan was prednisolone 20 mg daily for four weeks, followed by 15 mg daily for two weeks, and then a gradual reduction of 5 mg every two weeks, with a maintenance dose of 5 mg daily pending reassessment.

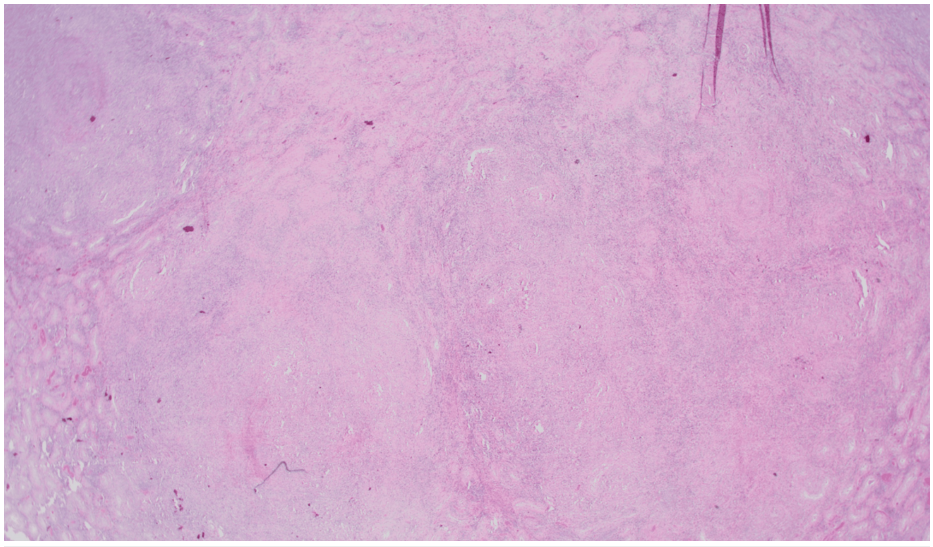

FIGURE 7: Histology of the right testicular tumor

Low-power view demonstrating granulomatous inflammation within the testicular tissue. Section stained with hematoxylin and eosin (H&E). Original magnification: ×40.

Given the differing histopathological interpretations across the affected organs, further review of the skin and testicular specimens was requested to establish whether a single underlying diagnosis could explain the findings. The patient was also referred for specialist review of the suspected IgG4-related disease.

The patient reported considerable clinical improvement during corticosteroid treatment, with substantial improvement in his skin lesions, increased weight, and improvement in his breathlessness. Follow-up CT of

the thorax a month after starting oral steroids demonstrated complete resolution of the right lower lobe pulmonary nodule (Figure 8). These improvements reinforced the working diagnosis of sarcoidosis.



FIGURE 8: CT of the thorax one month after the start of oral steroids, showing almost complete resolution of inflammatory changes at the right lung base

Subsequent specialist IgG4 MDT discussion reviewed the imaging and histopathology of the right testicular tumor. Although areas of IgG4-positive plasma cells had been identified, the overall histological pattern was not considered consistent with IgG4-related disease. Systemic granulomatous disorder, particularly sarcoidosis, remained a possible explanation. Further investigations including serum immunoglobulin levels and syphilis serology were recommended.

Month 9: confirmation of syphilis

Syphilis serology returned positive, and serum immunoglobulin levels including IgG4 came back within normal limits (Table 1).

Investigation	Patient result	Reference range
Alpha-fetoprotein (AFP)	1	0-6 IU/mL
Serum human chorionic gonadotropin (hCG)	<1	0-2 IU/L
Lactate dehydrogenase (LDH)	235	135-225 IU/L
Rapid plasma reagin (RPR)	Positive (1:16)	Negative
Treponema pallidum particle agglutination (TPPA)	Positive	Negative
T. pallidum IgG	Positive	Negative
T. pallidum IgM	Negative	Negative
Hepatitis B serology	Negative	Negative
Hepatitis C serology	Negative	Negative
HIV serology	Negative	Negative
Serum IgG4	0.46	0.01-1.3 g/L

TABLE 1: Summary of relevant serological results

Ophthalmological assessment was undertaken following his reports of ocular discomfort. The patient had recently received results of positive treponemal serology. Examination demonstrated no evidence of ocular inflammation, with quiet anterior chambers, no vitreous cells, and normal fundoscopic and macular optical coherence tomography findings. There was no evidence of chorioretinitis or retinal vasculitis to suggest ocular syphilis. A right-sided nuclear and cortical cataract was identified, which was not considered relevant to his likely syphilis diagnosis.

The positive syphilis serology prompted reassessment of the previously obtained tissue specimens. Subsequent review of all the biopsies with addition of Warthin-Starry staining demonstrated spirochetes in all three tissue sites: pulmonary, skin, and testicular (Figure *9*), suggesting multisystem syphilitic involvement.

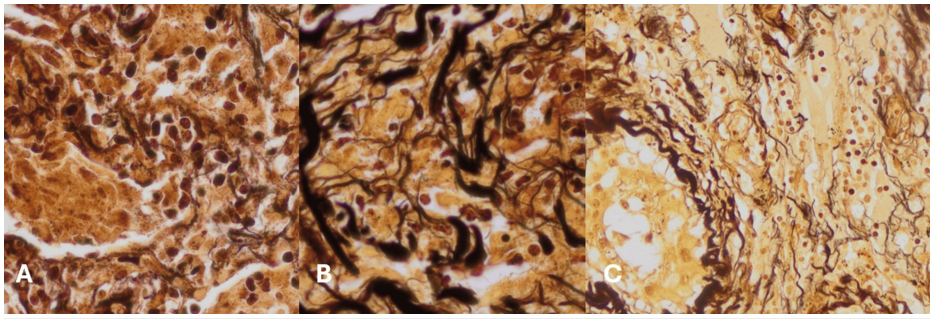

FIGURE 9: Retrospective Warthin-Starry (WS) staining demonstrating spirochetes in the histological specimens: (A) pulmonary nodule; (B) skin biopsy; and (C) right testicle

The patient was referred for review by the sexual health service, and a diagnosis of tertiary syphilis was made on the basis of positive serology and the histopathological findings. At this appointment, the patient denied any previous historical symptoms suggestive of primary syphilis. In view of the multisystem presentation and concern for possible cardiovascular and neurological involvement, intravenous ceftriaxone was selected as the anti-treponemal regimen. Ceftriaxone has established activity against *T. pallidum*, with good cerebrospinal fluid penetration. Since the patient had not yet received a neurology review or lumbar puncture for cerebrospinal fluid analysis, it was considered prudent to cover for tertiary, cardiovascular, and neuro-syphilis. He was treated with intravenous ceftriaxone 2 grams once daily for 14 days. Given the suspected late-stage, multisystem involvement, corticosteroid prophylaxis was considered prudent to mitigate the potential for an exaggerated inflammatory response (Jarisch-Herxheimer reaction) and associated clinical deterioration; prednisolone 60 mg orally once daily for three days was administered

alongside the antibiotics.

Considering cardiovascular involvement and follow-up

The patient had a background of significant cardiovascular disease, including chronic right coronary artery occlusion, recurrent atypical chest pain, and dilatation of the ascending aorta and aortic root. Previous CT imaging had demonstrated thoracic aortic dilatation with the ascending aorta measuring approximately 4.5 cm on most recent assessment. An abdominal aortic aneurysm was also under surveillance with the most recent imaging, documenting a diameter of approximately 5.3 cm.

He had undergone inpatient and outpatient cardiology assessment for recurrent atypical chest pain with no associated troponin elevation. CT angiography demonstrated chronic right coronary artery occlusion. He was managed with secondary cardiovascular prevention and antianginal medication but continued to experience chest pain on most days. In view of the confirmed diagnosis of tertiary syphilis and his aortic abnormalities, possible cardiovascular syphilis was considered. However, a causal relationship between the infection and his coronary artery disease or aortic aneurysms was not established, particularly given his substantial pre-existing atherosclerotic risk factors.

In order to investigate further for syphilis as a cause of his aortic disease, he had a CT aortogram, which showed no atypical features to indicate infection. Clinic letters following this concluded that the images did not suggest he was at a point to consider surgical replacement of his aorta, nor did the images particularly suggest active syphilitic aortitis given that there was no thickening of the aortic wall.

The follow-up plan included repeat syphilis serology at 3, 6, and 12 months, testing of his partner, and further cardiology MDT review to assess his ongoing chest pain and aortic disease. Urology was informed of the diagnosis, with a recommendation to consider surveillance of the previously identified left testicular lesion. Respiratory follow-up was arranged for the pulmonary nodule, and continued vascular surveillance of the abdominal aortic aneurysm was planned.

Following completion of antibiotic treatment, the patient's respiratory symptoms, including breathlessness, resolved and remained absent at subsequent follow-up. Repeat CT imaging of the chest demonstrated no residual focal pulmonary lesions. The cutaneous lesions also improved rapidly following treatment, while repeat testicular ultrasonography one month after treatment demonstrated complete resolution of the previously identified left testicular lesion, which was under surveillance.

Discussion

This case illustrates the diagnostic challenges associated with multisystem syphilis, presenting with pulmonary, cutaneous, and bilateral testicular abnormalities investigated over nearly a year before a unifying diagnosis was established. The diverse clinical and histopathological manifestations initially raised suspicion of malignancy, sarcoidosis, and IgG4-related disease, highlighting the importance of considering syphilis in the differential diagnosis of unexplained multisystem inflammatory disease.

Pulmonary involvement in syphilis is rare and can present with a variety of radiological abnormalities, including solitary or multiple pulmonary nodules, masses, consolidation, and pleural effusions [7]. David et al. described a case of secondary pulmonary syphilis presenting with multiple cavitating pulmonary nodules in a gentleman who was HIV-positive. He also had constitutional symptoms of weight loss, night sweats, and fatigue. This prompted extensive investigation to exclude alternative diagnoses, including opportunistic infections, malignancy (lymphoma, Kaposi Sarcoma, and metastatic carcinoma), and systemic inflammatory conditions such as sarcoidosis and granulomatosis with polyangiitis [7].

In our patient, a significant smoking history, emphysema, and constitutional symptoms appropriately raised initial concern for pulmonary malignancy. Subsequent histological findings of granulomatous inflammation prompted consideration of sarcoidosis before syphilis was diagnosed. An unusual feature was the complete radiological resolution of the pulmonary nodule following oral corticosteroid therapy, before syphilis was diagnosed and treated. Although corticosteroids may have suppressed the inflammatory response, spontaneous regression cannot be excluded. This highlights that improvement following immunosuppressive treatment does not necessarily establish a non-infective inflammatory diagnosis or exclude an underlying infection.

The bilateral testicular masses provided a further example of syphilis mimicking malignancy and inflammatory disease. Testicular involvement is a rare manifestation of syphilis, with presentations including orchitis and gummatous lesions [8]. Mackenzie et al. described a 47-year-old man with painful unilateral testicular swelling who underwent radical orchidectomy following persistent suspicious ultrasonographic findings. Histopathological examination excluded malignancy and confirmed tertiary syphilis [8]. This case is particularly relevant to ours, in which bilateral testicular abnormalities similarly raised concern for malignancy and ultimately resulted in orchidectomy.

Other reports have demonstrated that orchidectomy may be avoidable when syphilis is recognized before surgery. Teo and Fairley described a patient with a painless testicular mass, positive syphilis serology, and negative tumor markers who was successfully managed conservatively with doxycycline. Serial ultrasonography demonstrated complete resolution of the lesion at 10 months [9]. Similarly, Miyazaki et al. reported syphilitic orchitis in a 28-year-old man with multiple intratesticular lesions suspicious for malignancy. Following positive syphilis serology, the patient was managed conservatively with oral amoxicillin, with serial imaging demonstrating progressive reduction in lesion size and enhancement over 16 months, although residual nodules persisted [10]. These cases highlight the importance of considering syphilis in the differential diagnosis of testicular masses, particularly when tumor markers are negative and serological findings support syphilis infection. In our patient, however, the extensive bilateral abnormalities and wider multisystem presentation contributed to diagnostic uncertainty, and orchidectomy was ultimately performed before the underlying diagnosis was established.

The cutaneous manifestations of syphilis are highly variable and can mimic a broad range of dermatological, inflammatory, and malignant conditions [11]. Whiting et al. emphasize the diverse clinical and histopathological cutaneous presentations of syphilis, which can make recognition challenging, particularly in atypical or late-stage disease [11]. In our patient, the cutaneous lesions formed part of a wider multisystem presentation involving pulmonary nodules and bilateral testicular abnormalities. Although sarcoidosis is an important alternative diagnosis in patients presenting with granulomatous cutaneous and pulmonary disease, syphilis should also be considered.

Cardiovascular involvement was also considered in view of the CT aortogram findings, which demonstrated dilatation of the ascending aorta and aortic root, alongside an abdominal aortic aneurysm. Syphilitic aortitis is a recognized manifestation of tertiary syphilis, classically affecting the ascending thoracic aorta through obliterative endarteritis of the vasa vasorum, resulting in medial destruction and subsequent aneurysmal dilatation [12]. However, the absence of aortic wall thickening or other radiological features of active aortitis in our patient meant that a syphilitic etiology could not be established. Nevertheless, the aortic abnormalities were noteworthy in the context of the patient's multisystem syphilitic involvement.

This case highlights several important histopathological diagnostic pitfalls in the assessment of granulomatous inflammation. Granulomatous inflammation is a non-specific tissue reaction pattern and should not, in isolation, be considered diagnostic of sarcoidosis, as infectious etiologies, including syphilis, must also be excluded [13]. Similarly, the presence of IgG4-positive plasma cells requires interpretation within the broader histological context; their presence alone is insufficient to establish IgG4-related disease, which requires correlation with characteristic tissue architecture, including storiform fibrosis, obliterative phlebitis, and an increased IgG4-positive to total IgG-positive plasma cell ratio where appropriate [14]. In our case, initial histopathological assessment of the right testicular lesion demonstrated extensive nodular fibrosis with a perivascular lymphoplasmacytic infiltrate and positive IgG4 immunostaining. These features raised the possibility of IgG4-related disease, which was initially favored in the histopathology report. However, the report did not quantify IgG4-positive plasma cells or provide an IgG4/IgG ratio, limiting assessment against established histopathological criteria [14]. Furthermore, although fibrosis was extensive, storiform fibrosis and obliterative phlebitis were not specifically documented. Subsequent specialist review did not support IgG4-related disease, and the findings were reconsidered in the context of the patient's syphilis serology.

Additionally, following positive syphilis serology, retrospective review and additional Warthin-Starry silver staining demonstrated spirochetes within all three tissue specimens. The sensitivity of tissue staining methods is variable, with Warthin-Starry and Steiner silver stains reported to have a sensitivity of approximately 41%, compared with 71% for treponemal immunohistochemistry [13]. Consequently, negative Warthin-Starry Silver staining does not exclude syphilis, and organisms may be overlooked on initial histological assessment. Furthermore, silver staining can be affected by non-specific staining artefacts, necessitating careful interpretation alongside tissue morphology, serology, and clinical findings. Molecular techniques, including polymerase chain reaction, may provide additional diagnostic support where available but were not carried out in our case as the histological diagnosis was supported by concordant positive treponemal and non-treponemal serology [13] (Table *1*). This case illustrates the importance of reconsidering initial histopathological interpretations when subsequent clinical and serological findings suggest an alternative diagnosis, and highlights syphilis as an important differential diagnosis in unexplained multisystem granulomatous disease.

A limitation of this case was the difficulty establishing the timing of syphilis acquisition. On further history, the patient considered it likely that infection had occurred more than 15 years prior to his diagnosis. He reported no new sexual partners outside his long-term marriage and denied any known history of a chancre. However, in the absence of previous serological testing, the timing of infection could not be independently established. Nevertheless, the reported duration of infection is compatible with the recognized timeframe for the development of gummatous lesions [15].

With regard to disease staging, according to the British Association for Sexual Health and HIV (BASHH) guidelines, tertiary syphilis encompasses gummatous, cardiovascular, and late neurological disease [15]. The histopathological features of syphilis vary according to the stage of infection, and tertiary syphilis is

classically associated with gummatous inflammation, characterized by granuloma formation, epithelioid histiocytes, and multinucleated giant cells, with variable central necrosis and an accompanying lymphoplasmacytic inflammatory infiltrate. Fibrosis and perivascular inflammation may also be prominent [13]. In our patient, despite the absence of documented characteristic granulomatous features, including central necrosis and multinucleated giant cells, the extensive nodular fibrosis and perivascular lymphoplasmacytic inflammation observed in the testicular specimen were considered compatible with this spectrum of pathology. When considered alongside the reported history of longstanding infection and multisystem involvement, these findings support the possibility of tertiary syphilis with gummatous involvement.

Conclusions

Overall, this case demonstrates the protean manifestations of syphilis and its ability to mimic malignancy and systemic inflammatory disorders. Syphilis should be considered in the differential diagnosis of unexplained granulomatous inflammation, particularly when multiple organ systems are involved.

Early syphilis serological testing in this context, alongside effective communication between clinical teams and histopathologists, may facilitate earlier recognition of this treatable infection, reduce diagnostic delay, and inform subsequent management. Although this case cannot establish whether earlier diagnosis would have avoided orchidectomy, it highlights the importance of considering syphilis before irreversible surgical intervention where clinically appropriate. Earlier syphilis serological testing may also have avoided unnecessary investigations and inappropriate immunosuppression.

Additional Information

Author Contributions

All authors have reviewed the final version to be published and agreed to be accountable for all aspects of the work.

Concept and design: Katherine Irwin

Acquisition, analysis, or interpretation of data: Katherine Irwin, Nilofar Samadi, Lucy Main

Drafting of the manuscript: Katherine Irwin

Critical review of the manuscript for important intellectual content: Katherine Irwin, Nilofar Samadi, Lucy Main

Disclosures

Human subjects: Informed consent for treatment and open access publication was obtained or waived by all participants in this study. **Conflicts of interest:** In compliance with the ICMJE uniform disclosure form, all authors declare the following: **Payment/services info:** All authors have declared that no financial support was received from any organization for the submitted work. **Financial relationships:** All authors have declared that they have no financial relationships at present or within the previous three years with any organizations that might have an interest in the submitted work. **Other relationships:** All authors have declared that there are no other relationships or activities that could appear to have influenced the submitted work.

References

1. Lafond RE, Lukehart SA: Biological basis for syphilis . Clin Microbiol Rev. 2006, 19:29-49. 10.1128/CMR.19.1.29-49.2006
2. Syphilis. (2025). Accessed: 02/11/2026: https://www.who.int/news-room/fact-sheets/detail/syphilis.
3. Kingston M, French P, Higgins S, et al.: UK national guidelines on the management of syphilis 2015 . Int J STD AIDS. 2016, 27:421-46. 10.1177/0956462415624059
4. Chevalier FJ, Bacon O, Johnson KA, Cohen SE: Syphilis: a review. JAMA. 2025, 334:1927-40. 10.1001/jama.2025.17362
5. O'Byrne P, MacPherson P: Syphilis. BMJ. 2019, 365:l4159. 10.1136/bmj.l4159
6. Tracking the syphilis epidemic in England: 2013 to 2023 . (2024). Accessed: 02/11/2026: https://www.gov.uk/government/publications/tracking-the-syphilis-epidemic-in-england/tracking-the-syphilis-epidemic-i....
7. David G, Perpoint T, Boibieux A, et al.: Secondary pulmonary syphilis: report of a likely case and literature review. Clin Infect Dis. 2006, 42:e11-5. 10.1086/499104
8. Mackenzie H, Mahmalji W, Raza A: The gumma and the gonad: syphilitic orchitis, a rare presentation of testicular swelling. Int J STD AIDS. 2011, 22:531-3. 10.1258/ijsa.2009.009442
9. Teo SY, Fairley I: P169 Don't whip it out until syphilis is ruled out . Sex Transm Infect. 2012, 88:A66.1. 10.1136/sextrans-2012-050601c.169
10. Miyazaki S, Ueda T, Tamai R, Ueno A, Nakamura T: Syphilitic orchitis with long-term imaging follow-up and conservative treatment. Urol Case Rep. 2023, 49:102447. 10.1016/j.eucr.2023.102447

11. Whiting C, Schwartzman G, Khachemoune A: Syphilis in dermatology: recognition and management . Am J Clin Dermatol. 2023, 24:287-97. 10.1007/s40257-022-00755-3
12. Kallash M, Frishman W: Cardiovascular syphilis . Cardiol Rev. 2025, 10.1097/CRD.0000000000000863
13. Pathology Outlines. Syphilis . (2020). Accessed: 09/11/2026: https://www.pathologyoutlines.com/topic/skinnontumorsyphilis.html.
14. Deshpande V, Zen Y, Chan JK, et al.: Consensus statement on the pathology of IgG4-related disease . Mod Pathol. 2012, 25:1181-92. 10.1038/modpathol.2012.72
15. Kingston M, Apea V, Evans C, et al.: BASHH UK guidelines for the management of syphilis 2024 . Int J STD AIDS. 2024, 35:1142-60. 10.1177/09564624241280406