Cureus
Part of SPRINGER NATURE

Open Access Case Report

Fatal Combination of Poisoning and Hanging: A Case Report of Complex Suicide

Vikas Vaibhav [1], Prahalad R. Prajapat [2], Varun Chandran A [1], Muskan Malviya [1]

1. Forensic Medicine and Toxicology, All India Institute of Medical Sciences, Jammu, IND 2. Forensic Medicine, All India Institute of Medical Sciences, Jammu, IND

Corresponding author: Prahalad R. Prajapat, prajapat.prahalad10@gmail.com

Review began 10/26/2026
Review ended 10/28/2026
Published 11/02/2026

© Copyright 2026
Vaibhav et al. This is an open access article distributed under the terms of the Creative Commons Attribution License CC-BY 4.0., which permits unrestricted use, distribution, and reproduction in any medium, provided the original author and source are credited.

DOI: 10.7759/cureus.119028

Abstract

Complex suicide refers to the use of more than one potentially lethal suicidal method, either simultaneously or sequentially. Determining the contribution and sequence of individual methods requires correlation of the death scene, autopsy findings, and toxicological evidence. A 39-year-old man weighing 54 kg and measuring 172 cm was found hanging from a tree by a rope and was brought for medicolegal autopsy. An oblique, incomplete, reddish-brown, dry, and parchmentized ligature mark was present above the thyroid cartilage. Additional findings included dribbling of saliva, protrusion and biting of the tongue, and cyanosis of the nail beds. The tissues beneath the ligature mark were pale and parchmentized, and the viscera were congested. The stomach contained approximately 200 mL of white liquid with a pungent odor; the gastric mucosa was congested and showed submucosal hemorrhage. An empty poison container with a similar odor and a curd-based mixture were recovered from the scene. Toxicological examination identified a synthetic pyrethroid consistent with bifenthrin 10% emulsifiable concentrate. The case records support a complex suicidal event involving insecticide ingestion and hanging, with ingestion preceding suspension. The available records attribute the immediate cause of death to hanging (mechanical asphyxia), while poisoning represented an additional suicidal modality. The case highlights the need for cautious, evidence-based reconstruction of complex suicide through comprehensive correlation of scene findings, autopsy observations, and toxicological evidence.

Categories: Forensic Medicine, Psychiatry
Keywords: bifenthrin, complex suicide, forensic autopsy, hanging, medicolegal investigation, poisoning, synthetic pyrethroid, toxicology

Introduction

Complex suicide is generally defined as a suicidal act in which more than one potentially lethal method is employed, either simultaneously or sequentially [1]. The literature distinguishes planned (primary) complex suicide, in which multiple methods are selected as part of the same suicidal plan, from unplanned (secondary) complex suicide, in which an additional method is adopted after the first method fails, proves insufficient, or becomes intolerable [1-3].

This distinction matters because the sequence of events may influence the interpretation of cause and manner of death. Published cases have described combinations of poisoning, foreign-body ingestion, hanging, and other forms of self-harm and have emphasized the difficulty of reconstructing the sequence when more than one method could independently contribute to death [1-4].

The present case is of forensic interest because the scene, autopsy, and toxicological findings document two suicidal modalities: ingestion of a bifenthrin-containing insecticide and hanging. The principal interpretive challenge is not merely to identify both methods but to determine their temporal relationship and relative contribution to the cause of death.

Case Presentation

The authors confirm that the medicolegal autopsy was performed in accordance with applicable legal and institutional requirements. The authors removed all potentially identifying information from the manuscript and obtained consent from the deceased patient's next of kin (family member/legal representative) to publish this case report, including relevant clinical details and associated images. All applicable ethical and legal requirements for publishing this forensic autopsy case were met.

Scene examination

A 39-year-old man weighing 54 kg and measuring 172 cm was found suspended from a tree by a rope and was brought for medicolegal autopsy. The deceased was suspended with the knees touching the ground (Figure *1*). The clothing was intact. No suicide note was reported at the scene. An empty poison container was recovered and emitted a pungent odor similar to that described in the gastric contents. A curd-based mixture was also recovered from the scene (Figure *2*).



FIGURE 1: Scene photograph showing the deceased suspended from a tree with the knees touching the ground



FIGURE 2: Poison container and curd-based mixture recovered from the scene

External examination

A reddish-brown, dry, parchmentized ligature mark was present obliquely across the neck, extending backward and upward without completely encircling it (Figure *3*). The mark was situated above the level of the thyroid cartilage. Dribbling of saliva was observed over the lower lip. The tongue was protruding, blackened, and showed evidence of biting (Figure *4*). The nail beds were cyanosed. No other significant external injuries were documented.



FIGURE 3: Oblique, reddish-brown, dry, parchmentized ligature mark incompletely encircling the neck, above the thyroid cartilage



FIGURE 4: External facial findings showing saliva dribbling, tongue protrusion, and evidence of tongue biting

Internal examination

The tissues beneath the ligature mark were pale and parchmentized. The carotid artery showed a transverse tear in the intima (Amusat's sign) (Figure *5*). The viscera were congested. The stomach contained approximately 200 mL of white liquid material with a pungent odor (Figure *6*). The gastric mucosa was congested and showed submucosal hemorrhage (Figure *7*).



FIGURE 5: Transverse tear in the intima of the carotid artery (Amusat's sign), a finding associated with antemortem hanging



FIGURE 6: Stomach containing approximately 200 mL of white liquid material with a pungent odor

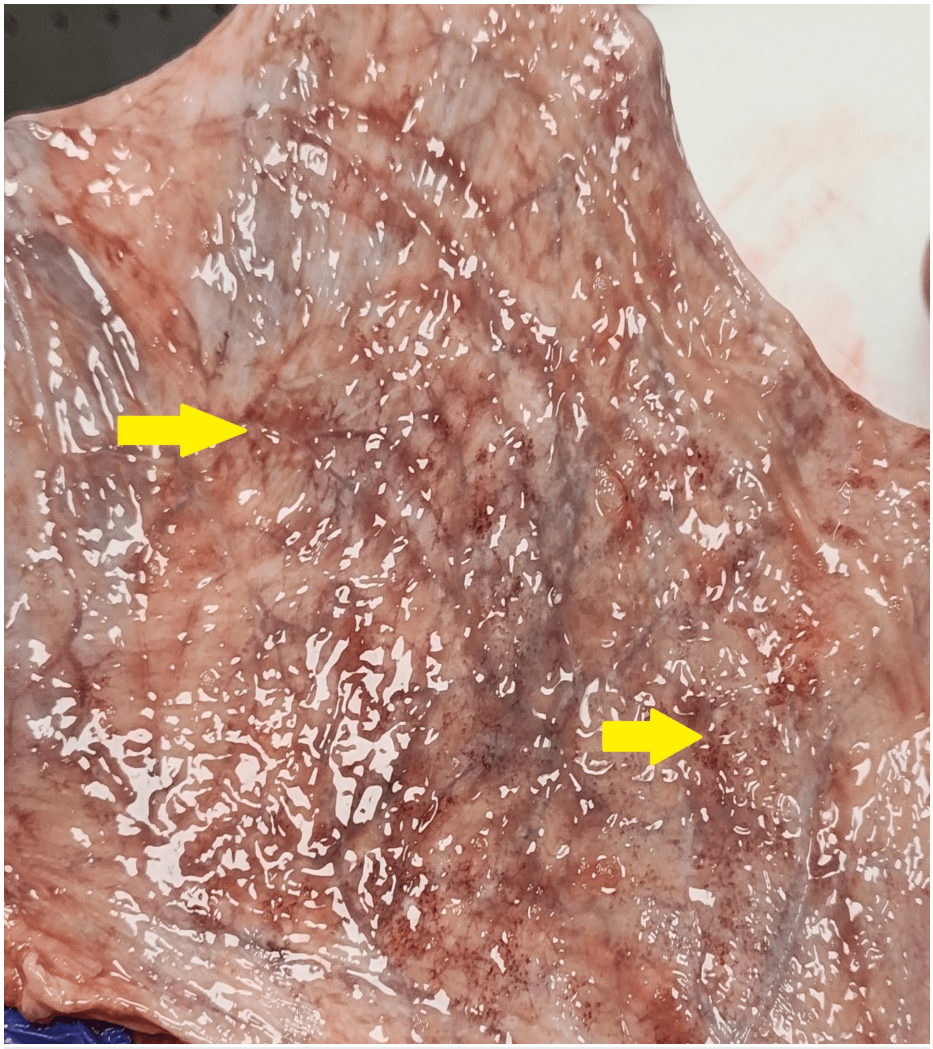

FIGURE 7: Congested gastric mucosa with submucosal hemorrhage

Toxicological findings

A toxicological examination identified a synthetic pyrethroid broad-spectrum insecticide, reported in the supplied case material as bifenthrin 10% emulsifiable concentrate. The gastric contents, the recovered poison container, and the toxicological finding together support antecedent ingestion of the insecticide. The supplied records do not provide the analytical method or measured concentration.

Forensic interpretation

Based on the autopsy findings, including a ligature mark consistent with antemortem hanging, visceral congestion, and a transverse tear in the intima of the carotid artery (Amusat's sign), the immediate cause of death was attributed to hanging (mechanical asphyxia). Prior ingestion of a bifenthrin-containing insecticide represents an additional suicidal modality. The overall findings are therefore best characterized as a complex suicide involving poisoning and hanging, with the evidence supporting ingestion before suspension.

Discussion

The present case fulfills the practical forensic definition of a complex suicide because two potentially lethal modalities, poisoning and hanging, are documented in the same death. Complex suicides may occur through simultaneous use of methods or through sequential use, and their interpretation can be difficult when the methods have different mechanisms and time courses [1-3].

The literature includes reports from India in which poisoning or ingestion preceded hanging. Jayanth et al. described an unplanned complex suicide involving insecticide mixed with crushed glass particles followed by hanging [2]. Phanjoubam et al. reported kerosene ingestion associated with hanging [4]. Another study by Chauhan et al. described a case in which foreign-body ingestion was followed by delayed hanging, illustrating that multiple suicidal acts may occur sequentially when an earlier act does not result in

immediate death [3]. These reports support the relevance of considering a sequential relationship in the present case, although they do not by themselves establish the sequence in an individual case.

The available evidence suggests that ingestion occurred before suspension. Approximately 200 mL of strongly odorous liquid was present in the stomach, an empty poison container with a similar odor was recovered from the scene, and toxicological examination identified a synthetic pyrethroid consistent with bifenthrin 10% emulsifiable concentrate. No information was available regarding the deceased's intentions during either act. Based on the available evidence, the case is best characterized as a complex suicide involving poisoning and hanging, with ingestion preceding suspension.

The hanging findings require integrated interpretation. The ligature mark was oblique, incomplete, and situated above the thyroid cartilage, with parchmentization of the underlying tissues. Dribbling of saliva and protrusion and biting of the tongue are compatible with hanging, but no single external finding should be interpreted in isolation. The suspension position, ligature, point of suspension, clothing, associated injuries, internal neck findings, and circumstantial evidence should be considered together [1,3].

Other published complex suicides demonstrate why the presence of two methods does not automatically establish their exact sequence. Vidhate et al. reported a planned combination of wrist-cutting and corrosive acid ingestion in which the sequence remained difficult to determine because either method could independently cause death [5]. Martínez and Ballesteros described two planned complex suicides involving petroleum distillate ingestion and subsequent hanging and emphasized the value of scene examination, autopsy observations, and toxicological analysis in reconstructing the lethal chain of events [6].

The toxicological finding is also important because synthetic pyrethroids are widely used insecticides, and clinically significant human poisoning has been described [7]. In the present case, the laboratory identification provides objective evidence for exposure, while the gastric findings and recovered container provide scene-to-autopsy concordance. The absence of a reported analytical method, quantitative concentration, or documented ingestion-to-suspension interval limits further interpretation of the toxicological contribution. Bodwal et al. likewise reported a planned combination of hanging and drowning, demonstrating the wide range of method combinations encountered in complex suicide [8].

Palmiere et al. reported an unusual case of unplanned complex suicide involving self-inflicted ligature strangulation and multiple sharp-force injuries. The case illustrated the difficulty of distinguishing suicide from homicide when injuries or mechanisms commonly associated with homicidal violence are encountered. It also emphasized the importance of evaluating the pattern of injuries in conjunction with the scene findings and the deceased's medical and psychosocial history. The presence of multiple injuries or more than one potentially fatal mechanism should not, by itself, lead to a conclusion of homicide [9].

Germerott et al. described another unusual case involving a 48-year-old man who died following self-inflicted ligature strangulation combined with ingestion of plaster material. Autopsy revealed a circumferential ligature mark, congestion-related petechial hemorrhages within the neck musculature, and a partially solidified plaster mass obstructing the laryngeal inlet. Death was attributed to the combined effects of neck compression and upper airway obstruction. The deceased also had a history of a suicide attempt and persistent suicidal ideation, which provided important circumstantial support for determining the manner of death as suicide. This report further illustrates how unusual combinations of methods can complicate the assessment of the mechanism and manner of death [10].

A 12-year retrospective study conducted in Athens, Greece (2011-2022), identified 14 cases of complex suicide (3.9%) among 360 suicidal deaths examined during 5,568 autopsies. The most common combination involved sharp-force injuries followed by jumping from a height (42.8%), while poisoning combined with hanging accounted for 21.4% of cases. Males constituted 78.6% of the victims, and only half had a documented psychiatric diagnosis. The study emphasized the importance of integrating scene investigation, circumstantial history, detailed autopsy findings, and toxicological analysis to accurately establish the cause and manner of death in complex suicides [11].

Dominic et al. reported two cases of complex suicide involving poisoning followed by hanging. The first involved a 33-year-old male who ingested an organophosphorus compound before hanging himself with a cloth, while the second involved a 20-year-old male who consumed kerosene before hanging with a plastic rope. In both cases, the suicidal manner of death was established through correlation of scene findings, autopsy observations, and information obtained from relatives. These cases highlight the importance of comprehensive medicolegal investigation in distinguishing complex suicide from other manners of death and avoiding unwarranted suspicion of homicide [12].

A further medicolegal concern is the possibility of misinterpretation or scene staging. The present findings therefore need to be interpreted as a single evidentiary sequence: the body position and ligature findings support hanging; the gastric contents and recovered container support antecedent insecticide ingestion; and toxicological examination provides laboratory corroboration of exposure. The available records do not document evidence of an alternative homicidal mechanism, but the final opinion should always remain

based on the complete medicolegal record rather than on any isolated finding.

Conclusions

This case illustrates a complex suicidal death involving insecticide ingestion and hanging. Its forensic significance lies in the importance of integrating scene circumstances, body position, ligature findings, gastric contents, and toxicological evidence rather than attributing death to a single method solely because its findings are more prominent at autopsy. When two suicidal modalities are present, the temporal sequence and relative contribution of each method should be reconstructed cautiously and only to the extent supported by the medicolegal evidence. Complex suicide should be considered when more than one potentially lethal suicidal modality is identified. Complete correlation of scene, autopsy, and toxicological findings is essential when evaluating possible homicide, staging, or competing explanations.

Additional Information

Author Contributions

All authors have reviewed the final version to be published and agreed to be accountable for all aspects of the work.

Concept and design: Prahalad R. Prajapat, Vikas Vaibhav, Varun Chandran A, Muskan Malviya

Acquisition, analysis, or interpretation of data: Prahalad R. Prajapat, Vikas Vaibhav, Varun Chandran A, Muskan Malviya

Drafting of the manuscript: Prahalad R. Prajapat, Vikas Vaibhav, Varun Chandran A, Muskan Malviya

Critical review of the manuscript for important intellectual content: Prahalad R. Prajapat, Vikas Vaibhav, Varun Chandran A, Muskan Malviya

Supervision: Prahalad R. Prajapat, Vikas Vaibhav, Varun Chandran A, Muskan Malviya

Disclosures

Human subjects: Informed consent for treatment and open access publication was obtained or waived by all participants in this study. **Conflicts of interest:** In compliance with the ICMJE uniform disclosure form, all authors declare the following: **Payment/services info:** All authors have declared that no financial support was received from any organization for the submitted work. **Financial relationships:** All authors have declared that they have no financial relationships at present or within the previous three years with any organizations that might have an interest in the submitted work. **Associate Editor authorship:** Vikas Vaibhav was an Associate Editor for the Cureus Journal of Medical Science at the time of submission. To minimize potential bias, this manuscript was handled independently by an alternate Associate Editor with no conflict of interest, and the author was blinded to and had no access to the peer review process, reviewer identities, or editorial decision-making for this submission. **Other relationships:** All authors have declared that there are no other relationships or activities that could appear to have influenced the submitted work.

References

1. Simonit F, Bassan F, Scorretti C, Desinan L: Complex suicides: a review of the literature with considerations on a single case of abdominal self stabbing and plastic bag suffocation. Forensic Sci Int. 2018, 290:297-302. 10.1016/j.forsciint.2018.07.027
2. Jayanth SH, Singh A, Hugar B: Unplanned complex suicide—poisoning followed by hanging . J Indian Acad Forensic Med. 2022, 44:99-101. 10.5958/0974-0848.2022.00092.6
3. Chauhan MS, Behera C, Naagar S, Sreenivas M: Ingestion of safety razor blade and delayed hanging in a complex suicide. Med Leg J. 2016, 84:215-8. 10.1177/0025817216661118
4. Phanjoubam M, Devi HR, Nalo A, Devi TM: Complex suicide—a case report. J Indian Acad Forensic Med. 2019, 41:132-133. 10.5958/0974-0848.2019.00044.7
5. Vidhate SG, Pathak H, Parchake M, Sukhadeve R, Meshram V: A planned complex suicide: cut injury to the wrist with corrosive acid poisoning. Egypt J Forensic Sci. 2016, 6:478-80. 10.1016/j.ejfs.2015.11.002
6. Martínez MA, Ballesteros S: Toxicological findings in two planned complex suicide cases: ingestion of petroleum distillates and subsequent hanging. J Anal Toxicol. 2009, 33:336-42. 10.1093/jat/33.6.336
7. Ramchandra AM, Chacko B, Victor PJ: Pyrethroid poisoning. Indian J Crit Care Med. 2019, 23:267-71. 10.5005/jp-journals-10071-23304
8. Bodwal J, Chauhan M, Behera C, Kumar J: Planned complex suicide by hanging and drowning in a water drum inscribed with suicide note. J Forensic Med Toxicol. 2021, 38:99-104. 10.5958/0974-4568.2021.00043.0
9. Palmiere C, Risso E, van Hecke O, La Harpe R: Unplanned complex suicide by self-strangulation associated with multiple sharp force injuries: a case report. Med Sci Law. 2007, 47:269-73. 10.1258/rsmmsl.47.3.269
10. Germerott T, Jaenisch S, Hatch G, Albrecht UV, Guenther D: Planned complex suicide: self-strangulation and plaster ingestion. Forensic Sci Int. 2010, 202:35-7. 10.1016/j.forsciint.2010.04.053
11. Alexandri M, Tsellou M, Kapsali A, et al.: Forensic investigation of complex and complicated suicides in Attica, Greece: a 12-year retrospective study. Forensic Sci Med Pathol. 2025, 21:90-7. 10.1007/s12024-024-

00842-3

12. Dominic IR, Gopal BK, Viswakanth B, Shruthi P: Planned complex suicide: a conundrum to unravel . Indian Internet J Forensic Med Toxicol. 2014, 12:56-8. 10.5958/0974-4487.2014.00875.x