Cureus
Part of SPRINGER NATURE

Open Access Case Report

Severe Trigeminal Neuralgia With Initially Unrecognized Neurovascular Compression: A Case Report

Review began 10/16/2026
Review ended 11/20/2026
Published 11/22/2026

© Copyright 2026
Karimi et al. This is an open access article distributed under the terms of the Creative Commons Attribution License CC-BY 4.0., which permits unrestricted use, distribution, and reproduction in any medium, provided the original author and source are credited.

DOI: 10.7759/cureus.120099

Amir Karimi [1], Matthew Beucherie [2], Peter Huynh [1]

1. Anesthesiology and Critical Care, Harbor-UCLA Medical Center, Torrance, USA 2. Anesthesiology and Pain Medicine, Ventana Anesthesia Associates, Inc., Monterey, USA

Corresponding author: Amir Karimi, ahk88@case.edu

Abstract

Trigeminal neuralgia (TN) causes paroxysmal, electric shock-like facial pain that, when severe, can make even minimal facial movement intolerable. We report a 68-year-old woman with long-standing right-sided TN whose pain escalated over one week from the V2 distribution to all three trigeminal divisions. Light touch, air, speaking, and the slightest jaw movement triggered the pain. It became so severe that she could not speak, eat, or take oral medications, and she required total parenteral nutrition. Her pain did not respond to intravenous opioids, ketorolac, sumatriptan, valproic acid, lacosamide, or corticosteroids. Initial magnetic resonance imaging (MRI) showed no neurovascular compression. An ultrasound-guided trigeminal nerve block gave immediate relief, but the pain returned within hours. On repeat review, the imaging showed the right superior cerebellar artery indenting the trigeminal nerve, and microvascular decompression confirmed arterial compression. Her facial pain resolved completely within two days, and she remained pain-free at one month. When refractory TN pain does not match initial imaging, reassessing the imaging and pursuing definitive treatment can be decisive.

Categories: Neurosurgery, Anesthesiology
Keywords: microvascular decompression surgery, neurovascular compression, refractory pain, trigeminal nerve block, trigeminal neuralgia

Introduction

Trigeminal neuralgia (TN) is a debilitating neuropathic pain disorder characterized by recurrent episodes of unilateral, electric shock-like facial pain within one or more divisions of the trigeminal nerve [1]. The International Classification of Headache Disorders, 3rd edition (ICHD 3), defines the characteristic attacks as severe, electric shock-like, shooting, stabbing, or sharp pain lasting from a fraction of a second to two minutes and divides it into classical, secondary, and idiopathic forms [2]. Classical TN requires neurovascular compression accompanied by morphological changes in the trigeminal nerve root, demonstrated on magnetic resonance imaging (MRI) or during surgery; vascular contact alone is insufficient [2,3]. Secondary TN is attributable to another neurological disorder, such as multiple sclerosis or a space-occupying lesion, whereas idiopathic TN lacks an identified cause after appropriate investigation [3]. A complementary grading system distinguishes possible, clinically established, and etiologically established TN and requires demonstration of neurovascular compression with morphologic changes of the trigeminal root for a diagnosis of classical TN [3].

In a population-based study, the lifetime prevalence of TN was approximately 0.3%, with a female predominance and rising incidence with age [4]. Although attacks are typically brief, they can be triggered by innocuous stimuli such as speaking, chewing, brushing the teeth, or light tactile stimulation [1]. These triggers produce substantial impairment in quality of life. In a cohort of 225 patients, up to 45% were absent from usual daily activities for 15 days or more over six months, and more than half reported anxiety [5]. The majority of cases are initially managed with anticonvulsants, most commonly carbamazepine or oxcarbazepine [6]. Patients with medically refractory disease may require procedural interventions, including percutaneous rhizotomy, stereotactic radiosurgery, or microvascular decompression (MVD) [6], and ultrasound-guided trigeminal nerve blocks have also been used for refractory pain [7].

Classical TN is most commonly attributed to vascular compression of the trigeminal nerve at the root entry zone, which is thought to cause focal demyelination and ectopic, hyperexcitable discharges within the nerve root [1]. Neurovascular contact with morphologic change of the nerve is strongly associated with the symptomatic side [8]. The superior cerebellar artery is the most frequent offending vessel [9]. MVD directly addresses neurovascular compression and offers durable pain relief in appropriately selected patients; in a series of 1,185 patients, 70% had excellent outcomes at 10 years [9,10]. Determining whether vascular contact is clinically meaningful can nevertheless be difficult, particularly when initial imaging does not clearly demonstrate nerve deformation.

How to cite this article
Karimi A, Beucherie M, Huynh P (November 22, 2026) Severe Trigeminal Neuralgia With Initially Unrecognized Neurovascular Compression: A Case Report. Cureus 18(11): e120099. DOI 10.7759/cureus.120099

We report a patient with an unusually severe exacerbation of medically refractory TN resulting in complete inability to speak, eat, or tolerate oral medications, ultimately requiring total parenteral nutrition during a prolonged hospitalization. Her evaluation progressed from an initially unremarkable MRI/magnetic resonance angiography (MRA) to specialist review documenting vascular contact, subsequent dedicated imaging demonstrating right trigeminal nerve indentation, and operative confirmation of compression. This case highlights both the profound morbidity of refractory TN and the importance of distinguishing incidental vascular contact from clinically relevant compression through continued clinical assessment and dedicated imaging.

Case Presentation

A 68-year-old woman with a seven-year history of medically managed right-sided TN presented with a one-week history of rapidly progressive facial pain that culminated in complete inability to speak, open her mouth, eat, drink, or tolerate oral medications. Her symptoms had previously been well controlled with carbamazepine 200 mg three times daily and intermittent procedural interventions at outside institutions, including radiofrequency or cryoablation and peripheral nerve blocks that provided temporary relief. Approximately six months before presentation, she underwent a trigeminal nerve block that significantly improved her symptoms.

Her current exacerbation began with electric shock-like pain localized primarily to the right maxillary (V2) distribution before progressing to involve all three divisions of the trigeminal nerve. The pain was triggered by even minimal stimulation, including speaking, chewing, facial movement, light touch, exposure to air, and vibrations while riding in a car. As her symptoms intensified, even slight mandibular movement precipitated excruciating pain. Within days, she became unable to speak, eat, drink, or take her prescribed carbamazepine, prompting presentation after multiple evaluations at outside hospitals failed to provide meaningful relief. Initial MRI reportedly demonstrated no intracranial pathology aside from bilateral maxillary sinus polyps.

Physical examination was limited by severe pain and allodynia over the right side of the face. The patient refused to open her mouth or speak because facial movement consistently provoked paroxysms of pain, communicating primarily through head gestures while her daughter provided the clinical history. Aside from the limited cranial nerve examination imposed by pain, no focal neurologic deficits were identified.

Despite escalating multimodal therapy, including intravenous opioids, ketorolac, subcutaneous sumatriptan, intravenous valproic acid, lacosamide, corticosteroids, and repeated intravenous hydromorphone, her pain remained debilitating. The initial MRI and MRA obtained on January 2, 2025, were interpreted as unremarkable. On January 3, neurosurgery recommended continued nonsurgical management at that stage of the acute exacerbation.

By this point, the patient had gone nearly one week without meaningful oral intake because even minimal jaw movement provoked excruciating pain. Nutritional support became a priority, and because placement of a nasogastric tube was considered intolerable, a peripherally inserted central catheter (PICC) was placed, and total parenteral nutrition was initiated.

Given her previous response to peripheral nerve blockade and failure of extensive medical therapy, an ultrasound-guided trigeminal nerve block was performed under deep sedation on January 8. After placement of a high-frequency linear transducer inferior to the zygomatic arch, the maxillary nerve was identified superior to the maxillary artery within the infratemporal fossa using color Doppler guidance. Following local infiltration with 1% lidocaine, a 22-gauge, 50 mm echogenic needle was advanced using an out-of-plane approach through the lateral pterygoid muscle. After repeated negative aspiration, 5 mL of 0.25% bupivacaine combined with 10 mg preservative-free dexamethasone was injected without complication.

The block produced immediate but transient clinical improvement. Sensory loss throughout the right V1 to V3 distributions confirmed successful blockade, and for the first time during her hospitalization, the patient was able to speak comfortably and participate in her examination. However, the improvement proved short-lived. Later that evening, her pain recurred, and over the following several days, she again became unable to tolerate oral intake despite continued multimodal analgesic therapy.

On January 9, the neurology team discussed the January 2 imaging directly with neuroradiology. An addendum to the original report described bilateral superior cerebellar artery contact with the trigeminal nerves without displacement and characterized this as a common incidental finding. The neurology note from the same date described a vascular loop causing deformation of the right trigeminal nerve. These accounts differed in the degree of nerve involvement described. Neurosurgery was reconsulted on January 12 because the block had not provided lasting relief. Subsequent neurosurgical documentation described an extended discussion about the initial decision to defer surgery in the setting of an acute pain exacerbation. By January 15, neurosurgery had documented plans for operative treatment and repeat MRI/MRA. The subsequent dedicated study, obtained after the operative plan had been documented, demonstrated the right superior cerebellar artery contacting and indenting the proximal cisternal right trigeminal nerve just

distal to the root entry zone (Figures *1*, *2*). On January 18, the patient underwent a right retrosigmoid craniectomy for MVD. Intraoperatively, an arterial loop compressing the trigeminal nerve root entry zone was identified and mobilized away from the nerve using Teflon felt.

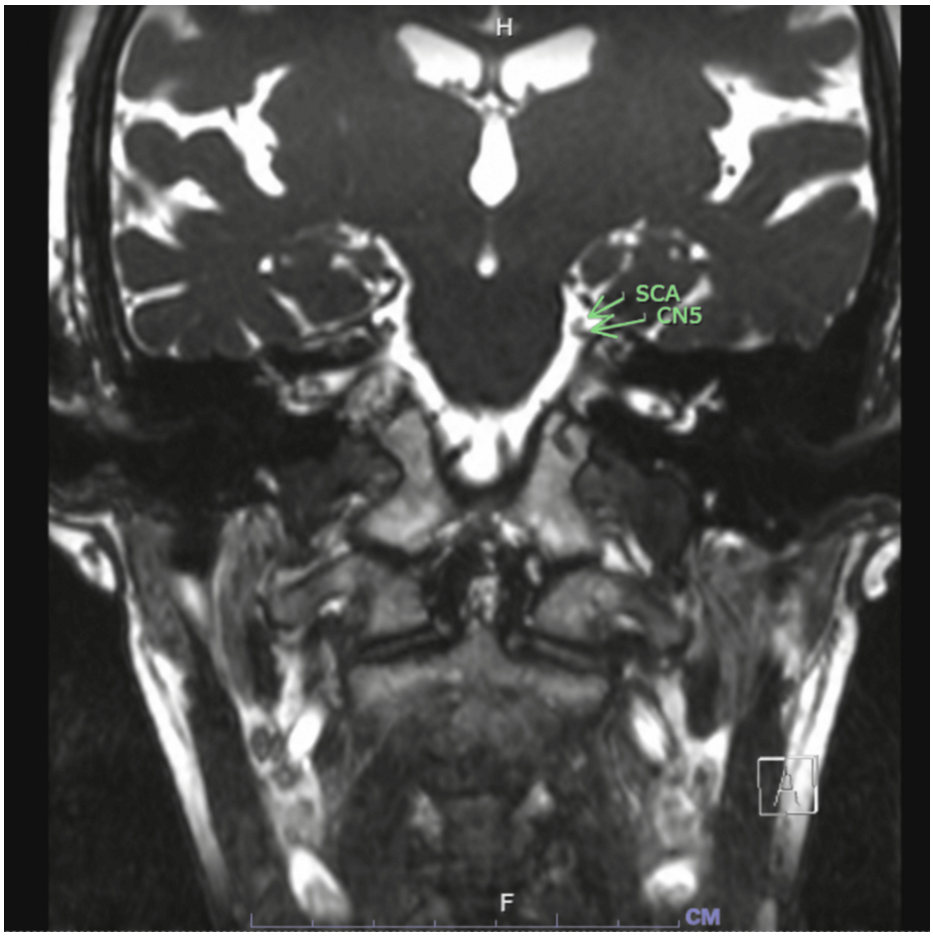

FIGURE 1: MRI Brain

The left SCA minimally contacts the superior margin of the cisternal portion of the left trigeminal nerve.

SCA: superior cerebellar artery; CN5: cranial nerve V

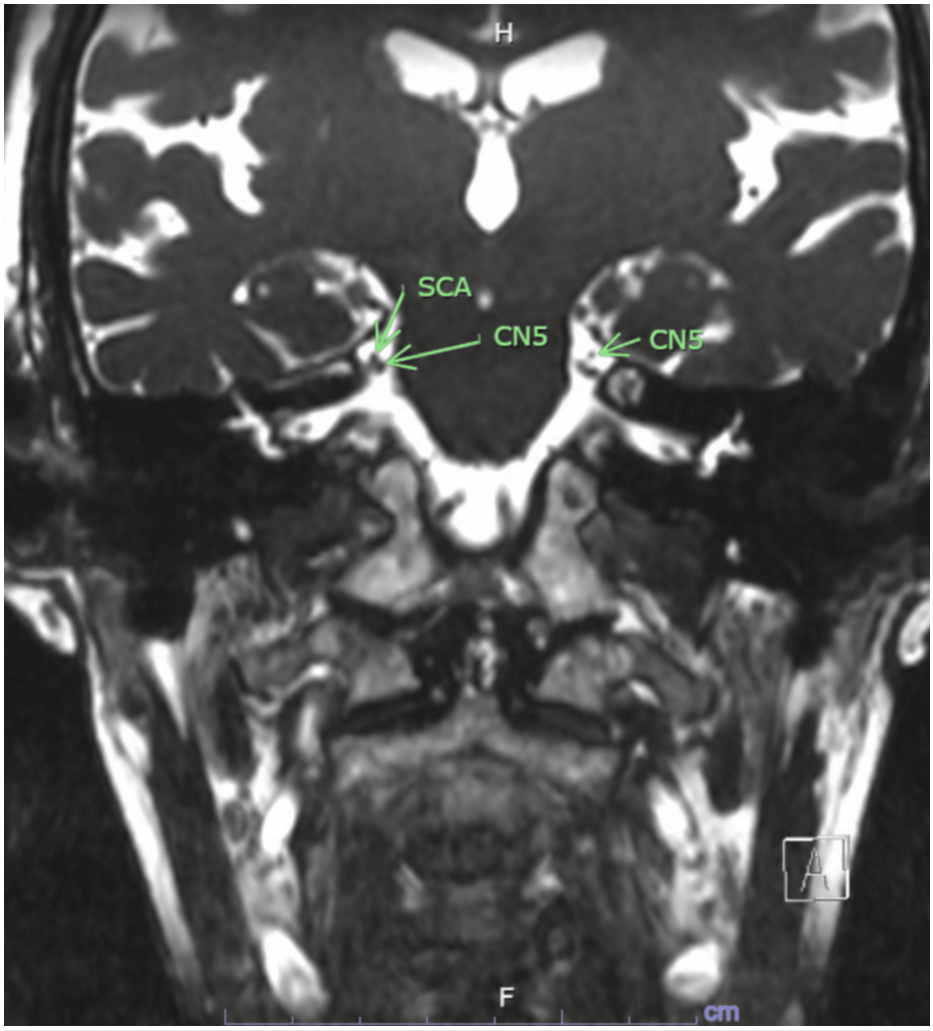

FIGURE 2: MRI Brain

The right SCA contacts and indents the superior margin of the proximal cisternal portion of the right trigeminal nerve just distal to the root entry zone.

SCA: superior cerebellar artery; CN5: cranial nerve V

During the early postoperative period, facial pain became progressively distinguishable from expected incisional discomfort. She subsequently received adjunctive ketamine, lidocaine, and magnesium infusions as part of her multimodal postoperative analgesic regimen. By postoperative day two, she reported complete resolution of her facial pain and burning sensations; was able to smile, speak, chew, and tolerate a soft diet without discomfort; and required substantially fewer opioid analgesics. She was discharged home with complete resolution of her TN, reporting only expected postoperative incisional pain and mild residual facial numbness. Her discharge medications included oxcarbazepine 600 mg twice daily, gabapentin 900 mg three times daily, baclofen 10 mg three times daily, acetaminophen as needed, and short courses of oxycodone and methocarbamol for postoperative pain management. At one-month follow-up, she remained pain-free with persistent mild numbness in the right V2 distribution.

Discussion

The distinguishing feature of this case was not simply refractory TN, but the extent to which pain disrupted functions necessary to sustain and treat the patient. Her exacerbation progressed from stimulus-evoked facial pain to an inability to speak, open her mouth, eat, drink, or take oral medications. Ultimately, nutritional support required a PICC line and total parenteral nutrition. This degree of functional deterioration represents an extreme manifestation of TN and illustrates a clinically important point: pain severity in TN may be underestimated when measured solely by pain intensity or attack frequency. Commonly used instruments, such as the Barrow Neurological Institute (BNI) pain intensity scale and the numerical rating scale (NRS), grade pain intensity and medication dependence but do not capture loss of essential functions [11,12]. Disability in TN is well documented, but in the most severe presentations, the consequences of pain, including loss of oral intake, inability to communicate, and inability to receive

established therapy, may be more informative measures of disease burden than a numerical pain score [5].

The inability to tolerate oral medications was particularly consequential because it removed the patient's principal means of disease control at the moment it was most needed. Carbamazepine and oxcarbazepine remain the preferred first-line pharmacologic treatments for TN, yet management becomes substantially more difficult when severe facial pain prevents swallowing or oral intake [6]. Evidence guiding treatment of acute TN crises in this setting remains limited; a systematic review identified only 17 studies reporting analgesic outcomes within 24 hours of treatment [13]. Intravenous lidocaine reduced pain intensity more than placebo in a small randomized crossover trial, and intravenous fosphenytoin has produced rapid relief in case series [14,15]. However, this literature consists largely of small studies and observational experience [13]. The failure of numerous parenteral and multimodal therapies in this patient highlights a therapeutic vulnerability of severe TN: progressive pain can simultaneously increase the need for treatment while eliminating access to the medications most likely to control it.

The need for total parenteral nutrition marks an important threshold in this patient's course. Avoidance of chewing and other facial movements is an understandable response to pain induced by triggers, but in this case, avoidance progressed to nutritional failure [1]. At that point, the clinical problem was no longer confined to pain control. Prolonged inability to eat placed the patient at risk of metabolic and nutritional complications, including refeeding syndrome when nutrition is reintroduced after a period of minimal intake, while inability to swallow prevented restoration of her usual anticonvulsant regimen [16]. This created a cycle in which pain prevented oral intake, inability to take medication limited pain control, and uncontrolled pain further prevented oral intake. This case therefore suggests that loss of essential function, particularly oral intake, should be regarded as an important marker of urgency in severe TN rather than simply another measure of symptom burden.

The ultrasound-guided trigeminal nerve block provided a useful interruption of this cycle, although not a durable one. Blockade of the trigeminal nerve via the pterygopalatine fossa has been reported to provide effective relief in refractory TN [7]. After the block, our patient had immediate numbness across the right trigeminal distribution and was able to speak again. The return of communication was clinically meaningful even though relief was transient. When sustained benefit did not emerge, neurosurgery was reconsulted four days after the block. Consistent with recommendations that acute management proceed in parallel with a definitive long-term plan, the block served as a temporizing intervention while the need for further treatment was reassessed [13]. The subsequent recurrence of symptoms also clarified the limitations of peripheral symptom control in a patient with an unresolved structural etiology.

An equally important aspect of this case was the discordance between the severity of the clinical presentation and the initial interpretation of neuroimaging. MRI is central to the evaluation of TN, but the identification of vascular contact and the determination of its clinical relevance are separate tasks. A meta-analysis of 13 studies found considerable variation in diagnostic performance depending on the imaging criterion used, with reported sensitivity for neurovascular compression ranging from approximately 75% to 97% and specificity ranging from 26% to 86% [17]. Neurovascular contact is common in asymptomatic nerves, whereas compression at the root entry zone and morphologic changes such as indentation, distortion, or atrophy are more strongly associated with symptomatic TN [8,17]. Earlier comparisons of MRI with operative findings also documented false-negative studies [18]. These findings support specialist reassessment and dedicated high-resolution imaging when clinical suspicion persists; an initially unrevealing radiologic interpretation cannot completely exclude a surgically relevant neurovascular conflict.

In this patient, the January 9 radiology addendum described bilateral contact without displacement, while the neurology note described deformation on the symptomatic right side. Preserving this distinction is essential: contact alone does not meet the imaging requirement for classical TN, which requires neurovascular compression with morphologic change demonstrated on MRI or at surgery [2,3]. The later dedicated MRI provided clearer evidence of right trigeminal nerve indentation, and surgery confirmed compression at the root entry zone. The operative plan had already been documented before the repeat study, so the chronology does not support attributing the decision to operate solely to that MRI. Similarly, the record does not establish that a missed finding caused additional suffering or that a formal conference was needed to reach the diagnosis. The patient experienced substantial morbidity during evaluation and treatment, but the interval after the block included observation for a possible delayed response and renewed neurosurgical assessment. This distinction avoids assigning preventable harm to imaging interpretation without supporting evidence. The broader concern of premature diagnostic closure remains relevant to continued reassessment [19], but it should not be presented as a demonstrated error in this case. The lesson is not that severe pain itself proves the presence of neurovascular compression. Rather, when a characteristic clinical syndrome continues to deteriorate despite treatment, discordance between the patient's phenotype and an initially negative imaging interpretation should prompt reconsideration of the diagnosis and imaging. This case illustrates the limitations of standard brain MRI protocols in detecting neurovascular compression, the difficulty of distinguishing pathologic compression from incidental vascular contact, and the value of dedicated high-resolution sequences and multidisciplinary review when clinical suspicion remains high despite unrevealing initial imaging.

The operative findings and subsequent response support the clinical significance of the vascular

compression. MVD directly addresses neurovascular conflict while avoiding intentional injury to the trigeminal nerve. In a systematic review and meta-analysis of 3,897 patients undergoing MVD for drug-resistant TN, approximately 76% achieved complete pain freedom at a mean follow-up of 1.7 years. Arterial compression and involvement of the superior cerebellar artery were associated with greater odds of postoperative pain freedom [10]. A separate meta-analysis of 2,102 patients similarly reported immediate complete pain relief in approximately 83% and found arterial, rather than isolated venous, conflict to be associated with more favorable long-term outcomes [20]. These findings are relevant to this patient, whose later dedicated MRI demonstrated right superior cerebellar artery contact with nerve indentation and whose operation confirmed arterial compression at the root entry zone. The operative findings support the final diagnosis but do not resolve the differing descriptions of the earlier study.

Perhaps the most striking feature of the postoperative course was the speed with which function returned once the neurovascular conflict was addressed. Within two days of decompression, a patient who had required parenteral nutrition because speaking and chewing were intolerable was again smiling, conversing, chewing, and eating. Immediate postoperative relief is typical after MVD, and the contrast between her prolonged preoperative deterioration and rapid postoperative recovery suggests that these functional deficits were not nonspecific consequences of hospitalization or generalized illness [9,20]. Instead, they were tightly linked to the uncontrolled trigeminal pain. Her continued pain freedom at one month, with only mild residual V2 numbness, further supports this relationship.

This case therefore expands the way severity can be conceptualized in TN. A pain score of 10 out of 10 on the NRS conveys intensity, and a BNI grade of V conveys treatment failure, but neither captures whether a patient can speak, swallow medication, maintain hydration, or obtain nutrition [11,12]. In this patient, those losses of function ultimately defined the seriousness of the episode and drove the need for multidisciplinary intervention. Severe TN can cross a threshold at which it should no longer be approached simply as an exacerbation of chronic neuropathic pain, but as a condition capable of producing acute medical consequences through the avoidance of essential activities. Recognition of that threshold should prompt aggressive efforts to restore function, provide temporary analgesia when necessary, and reconsider definitive treatment when the clinical trajectory remains inconsistent with initial diagnostic findings.

Conclusions

This case demonstrates the profound functional and physiologic consequences that can accompany an extreme exacerbation of TN. Pain severe enough to prevent speaking, eating, drinking, and oral medication administration can transform a chronic pain disorder into an acute medical problem requiring nutritional support and multidisciplinary intervention. When severe, refractory symptoms remain discordant with initial diagnostic findings, continued reassessment and consideration of definitive treatment may be critical to restoring function and preventing further clinical deterioration. Vascular contact alone should not be treated as diagnostic compression. Decisions about definitive treatment should integrate nerve morphology, the clinical course, response to temporizing measures, and loss of essential function.

Additional Information

Author Contributions

All authors have reviewed the final version to be published and agreed to be accountable for all aspects of the work.

Concept and design: Amir Karimi, Peter Huynh

Acquisition, analysis, or interpretation of data: Amir Karimi, Peter Huynh, Matthew Beucherie

Drafting of the manuscript: Amir Karimi, Peter Huynh, Matthew Beucherie

Critical review of the manuscript for important intellectual content: Amir Karimi, Peter Huynh

Supervision: Peter Huynh

Disclosures

Human subjects: Informed consent for treatment and open access publication was obtained or waived by all participants in this study. **Conflicts of interest:** In compliance with the ICMJE uniform disclosure form, all authors declare the following: **Payment/services info:** All authors have declared that no financial support was received from any organization for the submitted work. **Financial relationships:** All authors have declared that they have no financial relationships at present or within the previous three years with any organizations that might have an interest in the submitted work. **Other relationships:** All authors have declared that there are no other relationships or activities that could appear to have influenced the submitted work.

References

1. Cruccu G, Di Stefano G, Truini A: Trigeminal neuralgia. N Engl J Med. 2020, 383:754-62. 10.1056/NEJMra1914484
2. Headache Classification Committee of the International Headache Society (IHS) The International Classification of Headache Disorders, 3rd edition. Cephalalgia. 2018, 38:1-211. 10.1177/0333102417738202
3. Cruccu G, Finnerup NB, Jensen TS, et al.: Trigeminal neuralgia: new classification and diagnostic grading for practice and research. Neurology. 2016, 87:220-8. 10.1212/WNL.0000000000002840
4. Mueller D, Obermann M, Yoon MS, et al.: Prevalence of trigeminal neuralgia and persistent idiopathic facial pain: a population-based study. Cephalalgia. 2011, 31:1542-8. 10.1177/0333102411424619
5. Zakrzewska JM, Wu J, Mon-Williams M, Phillips N, Pavitt SH: Evaluating the impact of trigeminal neuralgia. Pain. 2017, 158:1166-74. 10.1097/j.pain.0000000000000853
6. Bendtsen L, Zakrzewska JM, Abbott J, et al.: European Academy of Neurology guideline on trigeminal neuralgia. Eur J Neurol. 2019, 26:831-49. 10.1111/ene.13950
7. Nader A, Kendall MC, De Oliveira GS Jr, Chen JQ, Vanderby B, Rosenow JM, Bendok BR: Ultrasound-guided trigeminal nerve block via the pterygopalatine fossa: an effective treatment for trigeminal neuralgia and atypical facial pain. Pain Physician. 2013, 16:537-45.
8. Maarbjerg S, Wolfram F, Gozalov A, Olesen J, Bendtsen L: Significance of neurovascular contact in classical trigeminal neuralgia. Brain. 2015, 138:311-9. 10.1093/brain/awu349
9. Barker FG 2nd, Jannetta PJ, Bissonette DJ, Larkins MV, Jho HD: The long-term outcome of microvascular decompression for trigeminal neuralgia. N Engl J Med. 1996, 334:1077-83. 10.1056/NEJM199604253341701
10. Holste K, Chan AY, Rolston JD, Englot DJ: Pain outcomes following microvascular decompression for drug-resistant trigeminal neuralgia: a systematic review and meta-analysis. Neurosurgery. 2020, 86:182-90. 10.1093/neuros/nyz075
11. Han PP, Shetter AG, Smith KA, Fiedler JA, Rogers CL, Speiser B, Feiz-Erfan I: Gamma knife radiosurgery for trigeminal neuralgia: experience at the Barrow Neurological Institute. Stereotact Funct Neurosurg. 1999, 73:131-3. 10.1159/000029771
12. Hawker GA, Mian S, Kendzerska T, French M: Measures of adult pain: Visual Analog Scale for Pain (VAS Pain), Numeric Rating Scale for Pain (NRS Pain), McGill Pain Questionnaire (MPQ), Short-Form McGill Pain Questionnaire (SF-MPQ), Chronic Pain Grade Scale (CPGS), Short Form-36 Bodily Pain Scale (SF-36 BPS), and Measure of Intermittent and Constant Osteoarthritis Pain (ICOAP). Arthritis Care Res (Hoboken). 2011, 63 Suppl 11:S240-52. 10.1002/acr.20543
13. Moore D, Chong MS, Shetty A, Zakrzewska JM: A systematic review of rescue analgesic strategies in acute exacerbations of primary trigeminal neuralgia. Br J Anaesth. 2019, 123:e385-96. 10.1016/j.bja.2019.05.026
14. Stavropoulou E, Argyra E, Zis P, Vadalouca A, Siafaka I: The effect of intravenous lidocaine on trigeminal neuralgia: a randomized double blind placebo controlled trial. ISRN Pain. 2014, 2014:853826. 10.1155/2014/853826
15. Cheshire WP Jr: Fosphenytoin: an intravenous option for the management of acute trigeminal neuralgia crisis. J Pain Symptom Manage. 2001, 21:506-10. 10.1016/s0885-3924(01)00269-x
16. da Silva JS, Seres DS, Sabino K, et al.: ASPEN consensus recommendations for refeeding syndrome. Nutr Clin Pract. 2020, 35:178-95. 10.1002/ncp.10474
17. Zhao W, Yin C, Ma L, Ding M, Kong W, Wang Y: Predictive value of MRI for identifying symptomatic neurovascular compressions in classical trigeminal neuralgia: a PRISMA-compliant meta-analysis. BMC Neurol. 2024, 24:466. 10.1186/s12883-024-03977-6
18. Meaney JF, Miles JB, Nixon TE, Whitehouse GH, Ballantyne ES, Eldridge PR: Vascular contact with the fifth cranial nerve at the pons in patients with trigeminal neuralgia: detection with 3D FISP imaging. AJR Am J Roentgenol. 1994, 163:1447-52. 10.2214/ajr.163.6.7992745
19. Graber ML, Franklin N, Gordon R: Diagnostic error in internal medicine. Arch Intern Med. 2005, 165:1493-9. 10.1001/archinte.165.13.1493
20. Di Carlo DT, Benedetto N, Perrini P: Clinical outcome after microvascular decompression for trigeminal neuralgia: a systematic review and meta-analysis. Neurosurg Rev. 2022, 46:8. 10.1007/s10143-022-01922-0