Cureus
Part of SPRINGER NATURE

Open Access Case Report

Surgical Pitfalls and Functional Outcomes in Cystic Vestibular Schwannoma

Carolina Fernandes Junger [1], Eduardo de Arnaldo Silva Vellutini [2, 3], Vinicius Trindade Gomes da Silva [2, 4]

1. Neurological Surgery, Hospital das Clínicas da Faculdade de Medicina da Universidade de São Paulo, São Paulo, BRA 2. Neurological Surgery, Hospital Universitário da Universidade de São Paulo, São Paulo, BRA 3. Neurological Surgery, Hospital Alemão Oswaldo Cruz, São Paulo, BRA 4. Neurological Surgery, A.C. Camargo Cancer Center, São Paulo, BRA

Corresponding author: Carolina Fernandes Junger, cfjunger@gmail.com

Review began 11/09/2026
Review ended 11/15/2026
Published 11/24/2026

© **Copyright** 2026
Fernandes Junger et al. This is an open access article distributed under the terms of the Creative Commons Attribution License CC-BY 4.0., which permits unrestricted use, distribution, and reproduction in any medium, provided the original author and source are credited.

DOI: 10.7759/cureus.120179

Abstract

Cystic vestibular schwannomas (CVS) are a challenging subtype of vestibular schwannoma whose clinical behavior, surgical difficulty, and outcomes remain debated. They often lack a clear dissection plane and adhere to neurovascular structures, jeopardizing facial and cochlear nerve function.

We present a single-surgeon case series (n=3) treated via a retrosigmoid approach in the semisitting position and describe the clinical-radiological features, operative strategy, and functional outcomes of three surgically treated CVS, highlighting technical nuances relevant to nerve preservation. Our patients underwent gross-total and near-total resection. Facial outcomes showed two patients achieved House-Brackmann (HB) grade I, while one remained HB grade V. Regarding hearing, one patient worsened from Gardner-Robertson grade I to III, and two had non-serviceable hearing preoperatively that remained unchanged. No lower cranial nerve deficits occurred, and no cases developed hydrocephalus. Findings reinforced that cysts are strongly adherent to the arachnoid plane, making dissection difficult. Surgical videos illustrating technique and dissection strategy are provided.

In experienced hands, gross-total and near-total resection of CVS are feasible with acceptable facial outcomes, but reliable cochlear nerve function remains uncommon. Long-term facial recovery depends more on anatomical integrity and rehabilitation than on immediate postoperative grade.

Categories: Neurology, Neurosurgery
Keywords: cystic vestibular schwannoma, facial nerve preservation, gross-total resection, hearing outcomes, retrosigmoid approach

Introduction

Vestibular schwannomas (VS) are benign, slow-growing tumors (1-2 mm per year) that account for 85% of cerebellopontine angle (CPA) tumors and 6% of all intracranial tumors [1]. Over the past decade, the incidence has increased, ranging from 3.0 to 5.2 per 100,000 person-years [2,3], which correlates with better diagnostic tools available globally. VS is divided into three subgroups according to lesion consistency: solid (homogeneous), cystic, and heterogeneous. The cystic variant represents 5.7-48% of all VS [4]. This wide range described in the literature is due to the lack of consensus on the definition of cystic patterns. In this series, a cystic component exceeding 50% of the tumor was used as the operational definition of CVS.

Histologically, VS can be classified into two tissue types: Antoni A and Antoni B. Antoni A is a densely cellular zone formed by elongated nuclei and long bipolar spindle cells arranged in palisade, the so-called "Verocay bodies." The Antoni B area is composed of loosely arranged, thin, and wispy cells separated by microcystic spaces filled with basophilic mucin, which may coalesce into macrocysts. Vascularization of the Antoni B region is often aberrant, and it is common to identify locally associated hemorrhage and/or thrombosis [5,6]. Cystic tumors appear to be an enlargement of the Antoni B area surrounded by an Antoni A membrane-like sheet [6].

Cystic VS (CVS) may exhibit rapid growth, a shorter duration of symptoms before presentation, and greater postoperative morbidity, although these findings vary across studies. Surgery is a standard treatment option, particularly for large symptomatic tumors with brainstem compression. However, attempts to achieve complete removal may be limited by adherence of the facial nerve to the tumor capsule, potentially compromising facial nerve preservation compared with solid tumors [7]. Although the response of CVS to radiotherapy remains debated, studies have evaluated Gamma Knife stereotactic radiosurgery as a treatment option in selected patients, with outcomes requiring interpretation in the context of tumor characteristics and patient selection [8,9].

This descriptive three-patient case series presents clinical and radiological features, operative observations, and documented functional outcomes after microsurgery for CVS. Surgical videos illustrate selected dissection steps. Although the small number of cases and the absence of a comparator group do not allow

definitive conclusions regarding prognostic factors or comparative treatment outcomes, these cases provide illustrative evidence that successful microsurgical treatment is possible despite the challenges associated with cystic morphology.

Facial nerve function was graded using the House-Brackmann (HB) scale [10], hearing was classified using the Gardner-Robertson system [11], and tumor extension was graded according to the Hannover classification [12]. Cyst morphology was described using the classifications of Piccirillo et al. [4] and Metwali et al. [7], which characterize cyst location, size, distribution, and wall thickness, providing features relevant to operative planning. Piccirillo et al.'s classification describes cyst location and wall characteristics, while the morphological patterns reported by Metwali et al. emphasize cyst size, distribution, and wall thickness [4,7]. These features help describe the anticipated capsule-neurovascular interface for operative planning.

Case Presentation

Case 1

A 52-year-old male patient presented to our hospital with left hypoacusia. Physical examination revealed no motor deficits or facial palsy and no remarkable alterations. The requested brain MRI showed multiple cystic lesions in the CPA-internal acoustic canal (CPA-IAC), suggestive of a VS. Audiometry tests proved the classical pattern found in VS patients with hearing loss due to high-frequency sounds. He was referred for surgery via the left retrosigmoid approach. Postoperative MRI performed one year after surgery showed no residual tumor. The patient has remained free of radiological recurrence over five years of follow-up. The patient had no preoperative facial weakness and maintained normal facial nerve function postoperatively (HB grade I). The worsening of hearing function was in accordance with the last six-month post-op audiogram chart (Gardner-Robertson grade from I to III) (Figures *1*-*3*).



FIGURE 1: Preoperative MRI

FIESTA-weighted MRI revealing T4A (Hannover)/type A1 (Piccirillo)/multiple small thick-walled cysts (Metwali). Cystic vestibular schwannoma (white arrow) reaching and slightly deforming the brainstem, formed by multiple small cysts with a thick cyst wall (outlined and shaded in red).

FIESTA: fast imaging employing steady-state acquisition

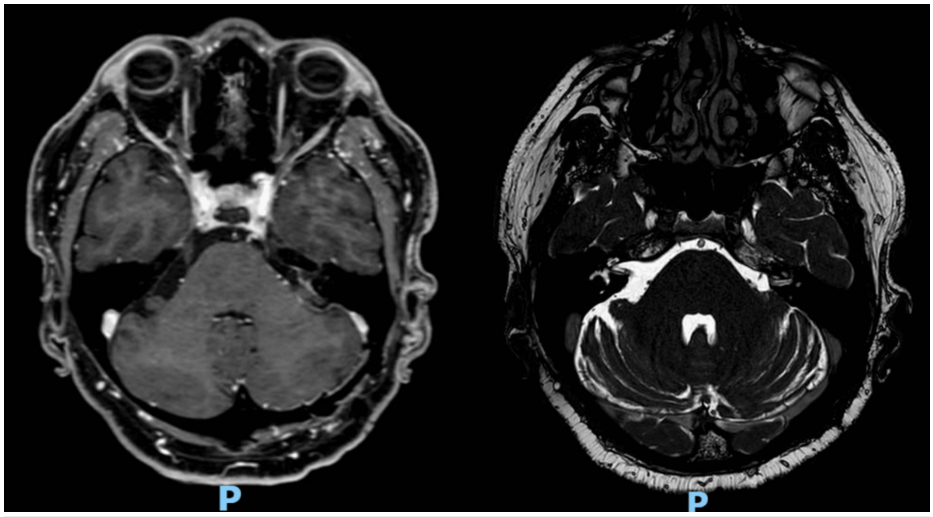

FIGURE 2: Postoperative MRI

T1-GD and FIESTA sequences showing gross-total tumor resection and release of brainstem compression.

GD: gadolinium; FIESTA: fast imaging employing steady-state acquisition

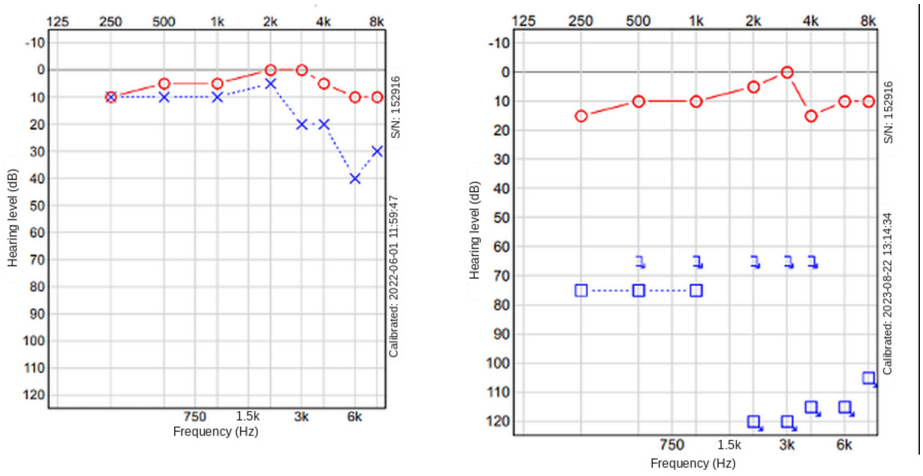

FIGURE 3: Pre- and postoperative comparative audiograms

Preoperative audiogram (right) shows high-frequency (4-8 k) hearing loss with a notch to 40 dB HL at 6 k. This pattern of steeper high-frequency loss is typical of vestibular schwannomas. PTA analysis of the right ear = 0 dB and PTA of the left ear = 25 dB. Postoperative audiogram (left) shows a profound hearing loss of the left ear, with thresholds of ~70-110 dB HL across the whole test. PTA analysis of the right ear = ~13 dB and PTA analysis of the left ear = 70 dB.

PTA: pure-tone audiogram; HL: hearing level

Case 2

An 85-year-old woman with a history of Parkinson disease presented with progressive facial palsy and gait impairment over two years, prompting further investigation. Physical examination revealed grade 3/5 left hemiparesis, HB grade V facial palsy, and anacusis. Brain MRI revealed a giant (as we considered tumors with >4.5 cm in their largest diameter) right CVS with significant brainstem compression. The patient underwent surgery through a right retrosigmoid approach. Follow-up imaging obtained six months postoperatively showed no findings suggestive of residual or recurrent tumor (Figures *4*-*5*). The patient has remained recurrence-free over five years of follow-up; however, facial nerve function has remained at HB grade V.

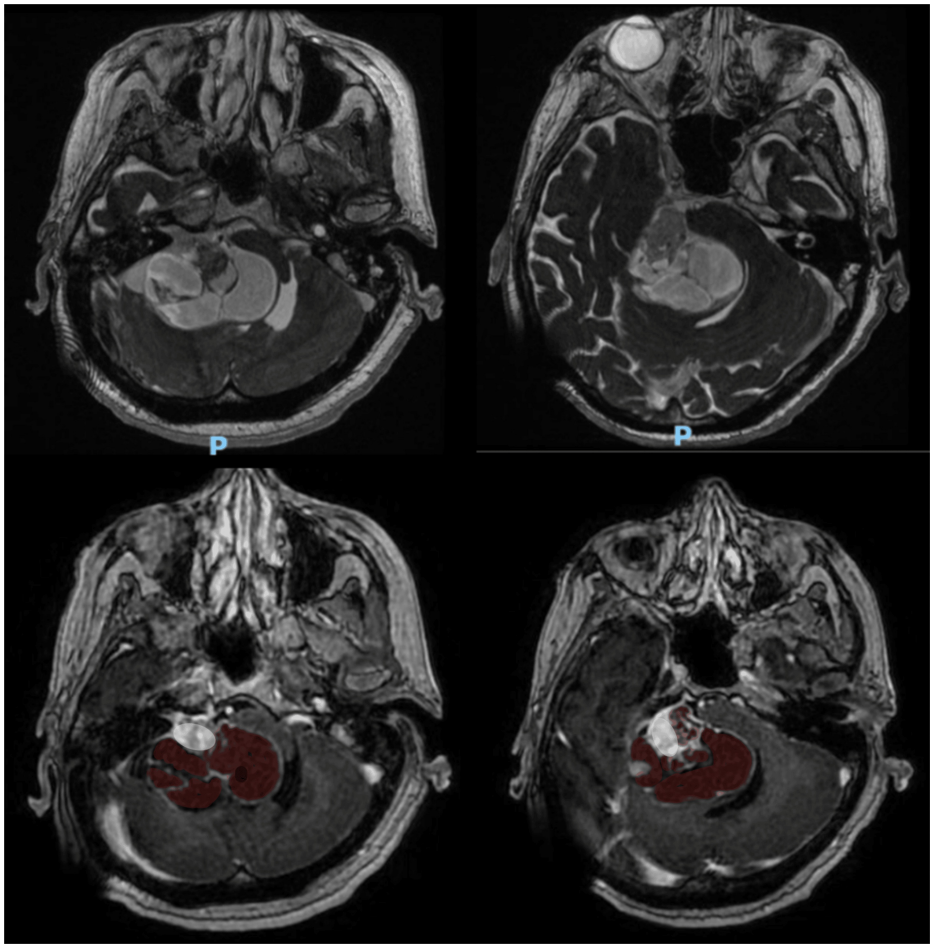

FIGURE 4: Preoperative MRI

Axial T2-weighted (top) and T1-GD (bottom) MRI revealing T4B (Hannover)/type B4 (Piccirillo)/multiple large thin-walled cysts (Metwali). Vestibular schwannoma compressing the brainstem while deforming the fourth ventricle, formed by peripheral and thin-walled large cysts around a small anterior solid portion. The solid portion is outlined in white, and cystic components are shaded in red in the bottom T1-GD sequence.

GD: gadolinium

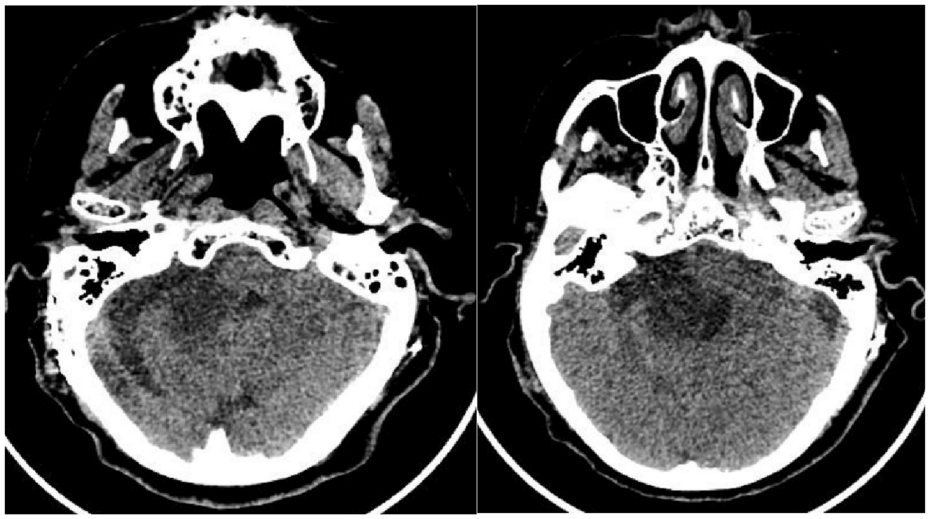

FIGURE 5: Postoperative CT

Axial CT images in the brain window showing complete tumor removal.

Case 3

A 50-year-old woman presented with progressive right-sided hearing loss. Physical examination revealed right-sided sensorineural hearing loss without motor deficits. Her medical history was unremarkable. Preoperative audiometry documented right-sided sensorineural hearing loss, although the original examination is no longer available. Brain MRI revealed a large (as we considered tumors with 3-4.5 cm in major diameter) cystic tumor lesion in the right CPA, suggestive of a VA. The patient underwent a right retrosigmoid craniotomy. Postoperative audiometry, which is available, showed persistent right-sided sensorineural hearing loss. Follow-up imaging obtained six months after surgery showed only a small residual capsule and no evidence of recurrence, and the patient has remained recurrence-free over seven years of follow-up (Figures *6*-*8*; Table *1*). Facial nerve function was normal before surgery and remained unchanged postoperatively (HB grade I).

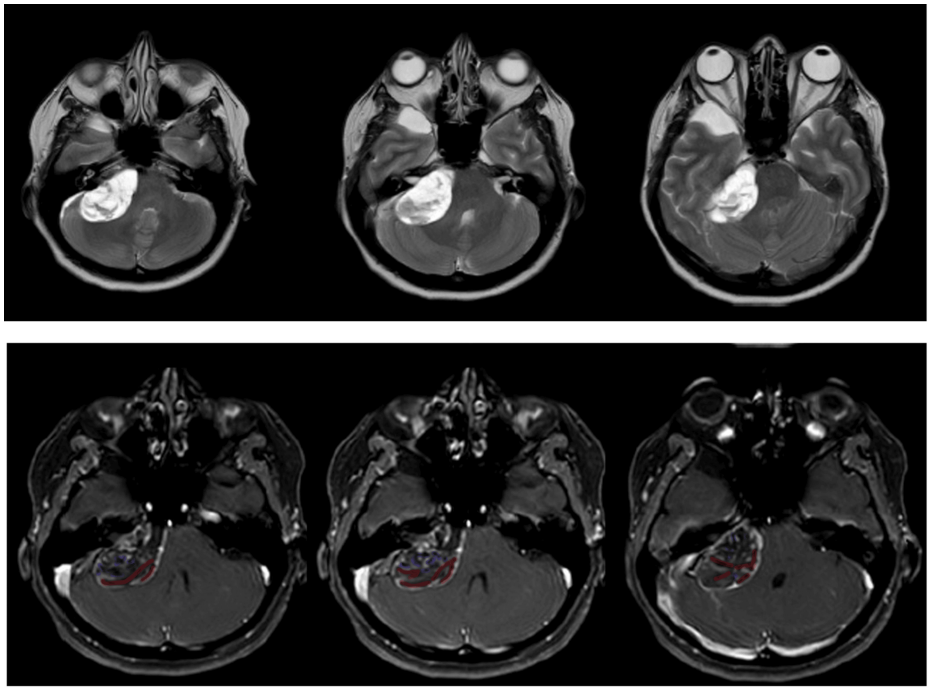

FIGURE 6: Preoperative MRI

Axial T2-weighted (top) and T1-GD (bottom) MRI revealing T4B (Hannover)/type B4 (Piccirillo)/mixed pattern of small and large cysts (Metwali). CVS formed by peripherally arranged large and thin-walled cysts and central small ones, shaded in red and blue, respectively, in the bottom sequence.

CVS: cystic vestibular schwannoma; GD: gadolinium

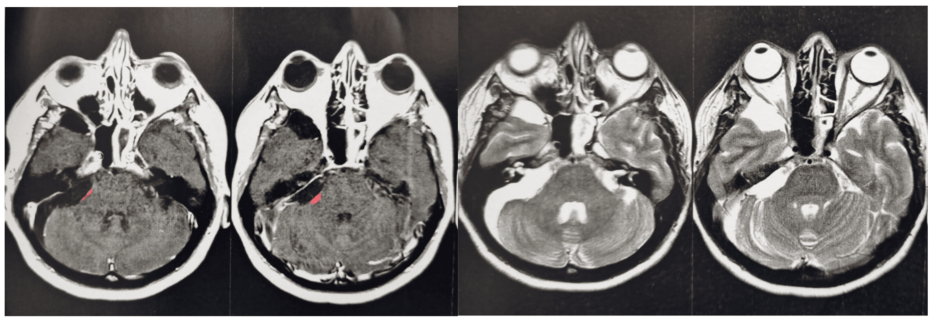

FIGURE 7: Postoperative MRI

Axial T1-GD (right) and T2-weighted (left) MRI demonstrating near-total tumor resection, with only a thin residual capsule adherent to the brainstem (shaded in red).

GD: gadolinium

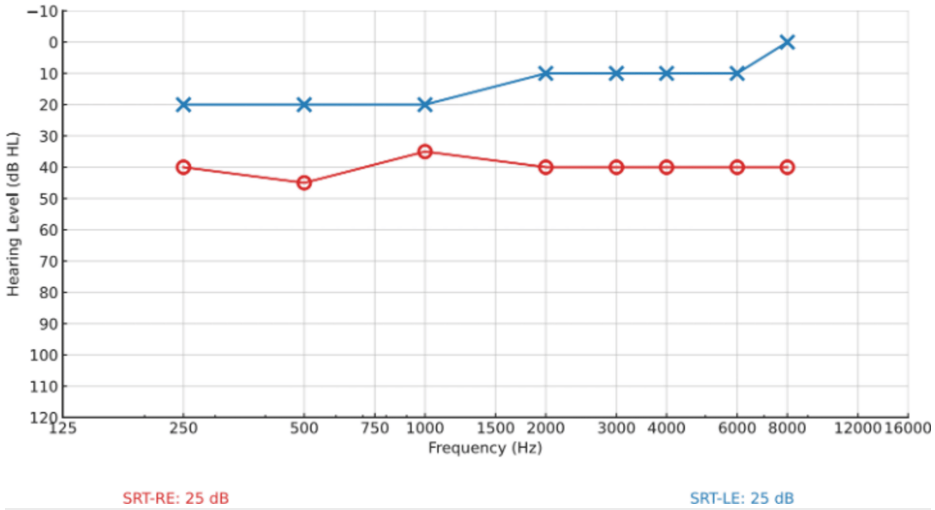

FIGURE 8: Postoperative audiogram

Postoperative audiogram shows ~30-45 dB HL across most test frequencies, with a notch to 50 dB HL at 500 Hz, consistent with a mild-to-moderate loss and an atypically steeper low-frequency component. PTA analysis of the right ear = 37 dB and PTA of the left ear = 18 dB. The Speech Recognition (Word Recognition) Score remains preserved at high presentation levels. Gardner-Robertson: class II.

PTA: pure-tone audiogram; HL: hearing level; SRT-RE: speech reception threshold-right ear; SRT-LE: speech reception threshold-left ear

Tested ear	Intensity	Monosyllable (%)	Disyllable (%)
RE	75 dB	100%	-
LE	60 dB	100%	-

TABLE 1: Speech recognition scores

RE: right ear; LE: left ear

Surgical videos

The videos from Cases 1 and 2 demonstrate the peculiar aspects of each and how to deal with the major issues of CVS surgery, focusing on preserving anatomical structures and postoperative functionality (Videos *1*-*2*).

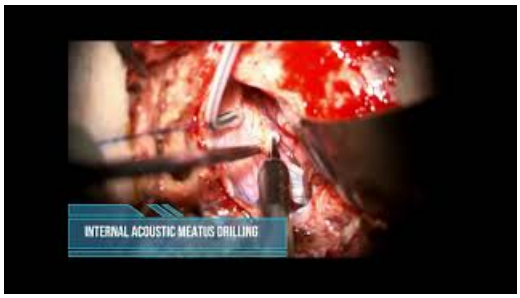

VIDEO 1: Case 1: cystic vestibular schwannoma

View video here: https://youtu.be/cr229j1glZQ



VIDEO 2: Case 2: giant cystic vestibular schwannoma

View video here: https://youtu.be/slKSu_lr3kQ

Discussion

CVS are associated with aggressive behavior and poorer post-surgical neurological status compared to their solid counterparts [4,7,13]. Subtotal resection may be justified when the cyst wall is densely adherent to the facial nerve [14]. In our series, a single surgeon performed all operations, ensuring technical uniformity; a retrosigmoid approach in the semisitting position was used throughout per the surgeon's preference. Continuous intraoperative electrophysiological monitoring informed dissection and safely allowed gross-total resection (GTR) and near-total resection (NTR) in our cases.

Pathophysiology of cyst formation

Cyst formation is not yet fully clarified. Direct osmotic effects or leakage of serum proteins resulting from a disrupted blood-tumor barrier could constitute a reasonable mechanism. Charabi et al. reported that myxomatous degeneration of small cysts in the Antoni B area leads to coalescence into larger ones, compressing the surrounding Antoni A fibers [15]. Some theories regard the role of matrix metalloproteinase II in cystic formation and enlargement, besides their primitive role in tissue remodeling, promoting the degradation of collagen, fibronectin, and laminin present in the cyst interstitial, and also could justify more peritumoral adhesions [16]. It is believed that intratumoral hemorrhages represent one of the leading mechanisms responsible for cyst development. Repeated intratumoral hemorrhages, demonstrated by radiologic features or quantified elevated hemosiderin deposition, are important factors associated with more frequent acute symptoms [17].

Tumor morphology

The definition of CVS varies across studies. In this series, tumors with a cystic component exceeding 50% were considered cystic. Piccirillo et al. classified these lesions according to cyst location and morphology, distinguishing predominantly central, thick-walled cysts (type A) from peripheral, thin-walled cysts (type B) [4]. Metwali et al. also evaluated cyst size, distribution, and wall thickness, identifying medially located thin-walled cysts as particularly challenging for facial nerve preservation [7].

In our series, one tumor was classified as Piccirillo type A1, and two were classified as type B4. According to the morphological patterns described by Metwali et al., one tumor contained multiple small thick-walled cysts, one contained multiple large thin-walled cysts, and one exhibited a mixed pattern of small and large cysts [7]. These characteristics helped contextualize the operative findings, particularly the difficulty of dissecting thin cyst walls adherent to adjacent neurovascular structures (Table *2*).

Case	Cyst morphology in the present series	Piccirillo et al.'s classification [4]	Morphological pattern described by Metwali et al. [7]
1	Multiple small cysts with thick walls	A1	Multiple small thick-walled cysts
2	Multiple large peripheral cysts with thin walls	B4	Multiple large thin-walled cysts
3	Small central cysts associated with large peripheral cysts	B4	Mixed pattern of small and large cysts

TABLE 2: Cyst morphology in the present series according to the classifications of Piccirillo et al. and Metwali et al.

This is an original table presenting the patients included in this series.

Based on the lead surgeon's technical judgment and operative considerations, the peripheral thin-walled cysts lack sufficient consistency to allow proper dissection while also being prone to rupture, and when combined with the strong adherence of the cystic capsule to the arachnoid of the CPA, they make plane separation extremely difficult and risky for cranial nerve functional preservation, notably VII and VIII. Lower cranial nerves were not affected in this series and did not pose a major issue, irrespective of tumor size.

Facial nerve

Historically, CVS is a synonym for worse facial nerve outcomes [13,18]. Although the literature supports the use of the HB scale [10], the definition of a satisfactory degree of facial nerve preservation remains a matter of debate. We considered HB grades I-III as good and HB grades IV-VI as poor results. In our series, all patients achieved anatomical preservation of the facial nerve. Two patients maintained HB grade I without any rehabilitation, and one remained at grade V despite one-year rehab and elected not to undergo nerve transfer surgery, representing an overall favorable outcome considering the challenging nature of CVS. Samii and Matthies reported decreased anatomical preservation of the facial nerve, from 93% to 88% in solid and cystic tumors, respectively [12]. The reason seems to be the worse cleavage plane and higher growth rate inherited by these tumors. As an alternative perspective, recent studies advocate that after one year of rehabilitation and when comparing patients with equivalent tumor sizes, the facial outcome is actually similar between the solid and cystic groups [7,19].

Hearing preservation

The cochlear nerve can remain anatomically intact despite postoperative hearing loss [20,21]. Hearing function was assessed using the Gardner-Robertson classification, which incorporates pure-tone average and speech discrimination. Grades I-II were considered serviceable hearing, corresponding to a pure-tone average of 50 dB hearing level (HL) or better and a speech discrimination score of at least 50% [11]. One patient had a worse hearing outcome according to pre- and postoperative audiometry records, and their referred PTA changed from a Gardner-Robertson class I to class III. The other two patients already had non-functional hearing that continued to be the same.

Hydrocephalus

VS patients develop hydrocephalus in 1.8-15% of cases, and 1-1.1% become shunt-dependent [20]. Tumor size and location influence the incidence of this complication, and each case should be assessed individually. Rapid tumor growth, brainstem or fourth ventricle compression, and hyperproteinorrachia account for the higher incidence of hydrocephalus in VS and are commonly associated with cystic lesions [22]. Otherwise, some advocate that cysts deform the shape of neural structures instead of compressing them, which makes a counterpoint to the first theory and would lead to less obstructive hydrocephalus [14]. This complication was not observed in our series, and all patients remained shunt-free.

Surgical considerations

The semisitting position was selected according to the senior surgeon's preference, as gravity-assisted drainage of cerebrospinal fluid and blood and optimized venous drainage help maintain a clear operative field and facilitate visualization of the tumor-neurovascular interfaces. Continuous transesophageal echocardiography was used to monitor for venous air embolism. The senior surgeon employed a two-forceps microsurgical technique to gently separate the arachnoid membrane from the tumor capsule, as demonstrated in the surgical videos, progressively developing the dissection plane while minimizing traction on adjacent neural structures. Intraoperative neurophysiological monitoring guided tumor dissection throughout the procedure. Brief pauses were incorporated during periods of substantial facial nerve manipulation to allow reassessment of the responses and minimize the risk of persistent deterioration in

facial motor evoked potentials. Intraoperative assessment of auditory function was more limited.

There is ongoing debate regarding the optimal surgical approach, particularly when comparing the middle fossa and retrosigmoid routes. Tumor size, location, and surgeon experience significantly influence this decision, and previous studies have shown biased results when these factors, especially tumor size, were not properly controlled. In general, the middle fossa approach is preferred for small intracanalicular lesions, whereas the retrosigmoid approach is favored for larger tumors with brainstem compression, as it provides sufficient surgical exposure to facilitate tumor resection while minimizing the risk of injury to adjacent neurovascular structures. With appropriate case selection and individualized planning, hearing preservation rates tend to be comparable between the two approaches [23].

In our series, the retrosigmoid approach was exclusively employed, based on criteria such as large tumor volume, major CPA location, and brainstem involvement. The IAC is routinely opened first as a mandatory step; only in bulky tumors is preliminary debulking performed to widen the operative corridor before addressing the canal.

Recurrent disease

The primary surgical objective was GTR, defined as complete tumor removal. When a small portion of the tumor capsule was intentionally retained, resection was classified as NTR. Two patients were considered GTR, and one was considered NTR considering the residual capsule. CVS can exhibit strong adhesions to neurovascular structures and an ill-defined dissection plane, limiting the feasibility of complete removal [4,7,14]. Larger postoperative residual tumor volumes are associated with an increased risk of subsequent growth. Vakilian et al. reported a significantly higher rate of recurrence in patients with residual tumor volumes greater than 2.5 cm^3 [24]. In the single case of NTR, the decision to leave a small portion of the capsule was guided by intraoperative neurophysiological monitoring. As monitoring alerts associated with surgical manipulation became more frequent, further dissection was discontinued to minimize the risk of permanent neurological injury. No tumor recurrence or progression was documented in our series during a minimum follow-up of five years.

Conclusions

CVS remain surgically challenging. In this three-patient series, GTR or NTR was achieved, with two patients maintaining normal facial nerve function and one remaining at HB grade V. No tumor recurrence or progression was documented during a minimum follow-up of five years. These cases illustrate that successful microsurgical treatment is possible despite the challenges associated with cystic morphology. For large tumors, particularly those causing symptomatic brainstem compression, surgery should be considered the treatment of choice when the patient's clinical condition permits. However, the small sample size limits definitive conclusions regarding functional outcomes and prognostic factors. Larger comparative studies with standardized long-term assessments are needed.

Additional Information

Author Contributions

All authors have reviewed the final version to be published and agreed to be accountable for all aspects of the work.

Concept and design: Carolina Fernandes Junger, Eduardo de Arnaldo Silva Vellutini, Vinicius Trindade Gomes da Silva

Acquisition, analysis, or interpretation of data: Carolina Fernandes Junger, Vinicius Trindade Gomes da Silva

Drafting of the manuscript: Carolina Fernandes Junger, Vinicius Trindade Gomes da Silva

Critical review of the manuscript for important intellectual content: Carolina Fernandes Junger, Eduardo de Arnaldo Silva Vellutini, Vinicius Trindade Gomes da Silva

Disclosures

Human subjects: Informed consent for treatment and open access publication was obtained or waived by all participants in this study. **Conflicts of interest:** In compliance with the ICMJE uniform disclosure form, all authors declare the following: **Payment/services info:** All authors have declared that no financial support was received from any organization for the submitted work. **Financial relationships:** All authors have declared that they have no financial relationships at present or within the previous three years with any organizations that might have an interest in the submitted work. **Other relationships:** All authors have declared that there are no other relationships or activities that could appear to have influenced the submitted work.

References

1. Gal TJ, Shinn J, Huang B: Current epidemiology and management trends in acoustic neuroma . Otolaryngol Head Neck Surg. 2010, 142:677-81. 10.1016/j.otohns.2010.01.037
2. Fernández-Méndez R, Wan Y, Axon P, Joannides A: Incidence and presentation of vestibular schwannoma: a 3-year cohort registry study. Acta Neurochir (Wien). 2023, 165:2903-11. 10.1007/s00701-023-05665-9
3. Marinelli JP, Lohse CM, Carlson ML: Incidence of vestibular schwannoma over the past half-century: a population-based study of Olmsted County, Minnesota. Otolaryngol Head Neck Surg. 2018, 159:717-23. 10.1177/0194599818770629
4. Piccirillo E, Wiet MR, Flanagan S, Dispenza F, Giannuzzi A, Mancini F, Sanna M: Cystic vestibular schwannoma: classification, management, and facial nerve outcomes. Otol Neurotol. 2009, 30:826-34. 10.1097/MAO.0b013e3181b04e18
5. Wippold FJ 2nd, Lubner M, Perrin RJ, Lämmle M, Perry A: Neuropathology for the neuroradiologist: Antoni A and Antoni B tissue patterns. AJNR Am J Neuroradiol. 2007, 28:1633-8. 10.3174/ajnr.A0682
6. Tang IP, Freeman SR, Rutherford SA, King AT, Ramsden RT, Lloyd SK: Surgical outcomes in cystic vestibular schwannoma versus solid vestibular schwannoma. Otol Neurotol. 2014, 35:1266-70. 10.1097/MAO.0000000000000435
7. Metwali H, Samii M, Samii A, Gerganov V: The peculiar cystic vestibular schwannoma: a single-center experience. World Neurosurg. 2014, 82:1271-5. 10.1016/j.wneu.2014.07.011
8. Huang CY, Peng SJ, Wu HM, et al.: Quantification of tumor response of cystic vestibular schwannoma to Gamma Knife radiosurgery by using artificial intelligence. J Neurosurg. 2022, 136:1298-306. 10.3171/2021.4.JNS203700
9. Wang SS, Rizk A, Ebner FH, van Eck A, Naros G, Horstmann G, Tatagiba M: Cystic vestibular schwannoma - a subgroup analysis from a comparative study between radiosurgery and microsurgery. Neurosurg Rev. 2024, 47:291. 10.1007/s10143-024-02495-w
10. House JW, Brackmann DE: Facial nerve grading system. Otolaryngol Head Neck Surg. 1985, 93:146-7. 10.1177/019459988509300202
11. Gardner G, Robertson JH: Hearing preservation in unilateral acoustic neuroma surgery . Ann Otol Rhinol Laryngol. 1988, 97:55-66. 10.1177/000348948809700110
12. Samii M, Matthies C: Management of 1000 vestibular schwannomas (acoustic neuromas): surgical management and results with an emphasis on complications and how to avoid them. Neurosurgery. 1997, 40:11-21. 10.1097/00006123-199701000-00002
13. Thakur JD, Khan IS, Shorter CD, Sonig A, Gardner GL, Guthikonda B, Nanda A: Do cystic vestibular schwannomas have worse surgical outcomes? Systematic analysis of the literature. Neurosurg Focus. 2012, 33:E12. 10.3171/2012.6.FOCUS12200
14. Nair S, Baldawa SS, Gopalakrishnan CV, Menon G, Vikas V, Sudhir JB: Surgical outcome in cystic vestibular schwannomas. Asian J Neurosurg. 2016, 11:219-25. 10.4103/1793-5482.145359
15. Charabi S, Klinken L, Tos M, Thomsen J: Histopathology and growth pattern of cystic acoustic neuromas . Laryngoscope. 1994, 104:1348-52. 10.1288/00005537-199411000-00006
16. Xu J, Ma J, Shi Y, et al.: Differential protein expression between cystic and solid vestibular schwannoma using tandem mass tag-based quantitative proteomic analysis. Proteomics Clin Appl. 2020, 14:e1900112. 10.1002/prca.201900112
17. de Vries M, Hogendoorn PC, Briaire-de Bruyn I, Malessy MJ, van der Mey AG: Intratumoral hemorrhage, vessel density, and the inflammatory reaction contribute to volume increase of sporadic vestibular schwannomas. Virchows Arch. 2012, 460:629-36. 10.1007/s00428-012-1236-9
18. Sinha S, Sharma BS: Cystic acoustic neuromas: surgical outcome in a series of 58 patients . J Clin Neurosci. 2008, 15:511-5. 10.1016/j.jocn.2007.01.007
19. Jones SE, Baguley DM, Moffat DA: Are facial nerve outcomes worse following surgery for cystic vestibular schwannoma?. Skull Base. 2007, 17:281-4. 10.1055/s-2007-986436
20. Samii M, Gerganov V, Samii A: Improved preservation of hearing and facial nerve function in vestibular schwannoma surgery via the retrosigmoid approach in a series of 200 patients. J Neurosurg. 2006, 105:527-35. 10.3171/jns.2006.105.4.527
21. Preet K, Ong V, Sheppard JP, et al.: Postoperative hearing preservation in patients undergoing retrosigmoid craniotomy for resection of vestibular schwannomas: a systematic review of 2034 patients. Neurosurgery. 2020, 86:332-42. 10.1093/neuros/nyz147
22. Mehrotra N, Behari S, Pal L, Banerji D, Sahu RN, Jain VK: Giant vestibular schwannomas: focusing on the differences between the solid and the cystic variants. Br J Neurosurg. 2008, 22:550-6. 10.1080/02688690802159031
23. Starnoni D, Giammattei L, Cossu G, et al.: Surgical management for large vestibular schwannomas: a systematic review, meta-analysis, and consensus statement on behalf of the EANS skull base section. Acta Neurochir (Wien). 2020, 162:2595-617. 10.1007/s00701-020-04491-7
24. Vakilian S, Souhami L, Melançon D, Zeitouni A: Volumetric measurement of vestibular schwannoma tumour growth following partial resection: predictors for recurrence. J Neurol Surg B Skull Base. 2012, 73:117-20. 10.1055/s-0032-1301395