Cureus
Part of SPRINGER NATURE

Open Access Case Report

Asymmetric Outcomes in Bilateral Myelin Oligodendrocyte Glycoprotein Antibody-Associated Optic Neuritis: A Case Report

Yutaro Morita [1], Ryusuke Hashimoto [2], Takayuki Baba [2]

1. Ophthalmology, Chiba Children's Hospital, Chiba, JPN 2. Department of Ophthalmology and Visual Science, Chiba University Graduate School of Medicine, Chiba, JPN

Corresponding author: Ryusuke Hashimoto, ryuhash0421@gmail.com

Review began 10/12/2026
Review ended 10/18/2026
Published 10/21/2026

© Copyright 2026
Morita et al. This is an open access article distributed under the terms of the Creative Commons Attribution License CC-BY 4.0., which permits unrestricted use, distribution, and reproduction in any medium, provided the original author and source are credited.

DOI: 10.7759/cureus.118322

Abstract

Myelin oligodendrocyte glycoprotein (MOG) antibody-associated optic neuritis (MOG-ON) usually responds well to corticosteroid treatment, even when acute visual loss is severe. We describe the case of a 60-year-old man with rapid-onset bilateral MOG-ON who was referred to our department for evaluation and treatment. At the first visit, best-corrected visual acuity (BCVA) was counting fingers in the right eye and light perception in the left eye, and a relative afferent pupillary defect was present in the left eye. Magnetic resonance imaging showed longitudinally extensive lesions of both optic nerves extending almost to the optic chiasm, with perineural enhancement of the left optic nerve. Serum anti-MOG immunoglobulin G (MOG-IgG) was positive at a titer of 1:64 on a cell-based assay. The left eye lost light perception and did not respond to intravenous methylprednisolone pulse therapy; therefore, a second course of pulse therapy and five sessions of plasma exchange were added. Although the interval from onset to treatment was shorter in the left eye, approximately five months after onset in the right eye, BCVA in logarithm of the minimum angle of resolution (logMAR) units was −0.08 in the right eye but only 0.82 in the left eye. The left eye also showed poor recovery of critical flicker fusion frequency, and a central scotoma and left-predominant macular inner retinal thinning persisted. In bilateral MOG-ON, outcomes may differ markedly between the eyes despite identical treatment. We report this case because we were able to document the longitudinal structural and functional changes in each eye.

Categories: Neurology, Ophthalmology, Internal Medicine
Keywords: asymmetric visual recovery, bilateral optic neuritis, critical flicker fusion frequency, mogad, no light perception, optical coherence tomography, optic neuritis, plasma exchange

Introduction

Myelin oligodendrocyte glycoprotein (MOG) antibody-associated disease (MOGAD) is an inflammatory demyelinating disease of the central nervous system that is distinct from multiple sclerosis and aquaporin-4 (AQP4) antibody-positive neuromyelitis optica spectrum disorder, and optic neuritis is one of its typical presentations [1]. MOG is located on the outermost surface of the myelin sheath in the central nervous system, including the optic nerves, which makes it a potential target of autoantibodies and cell-mediated immune responses, although the pathogenic role of MOG antibodies has not been fully clarified [2,3]. Detection of serum MOG immunoglobulin G (MOG-IgG) with a cell-based assay is a core diagnostic criterion, and MOG-IgG detected with a live cell-based assay is highly specific for the diagnosis in patients with a compatible clinical phenotype [1,4].

MOG antibody-associated optic neuritis (MOG-ON) is characterized by pain on eye movement, optic disc swelling, bilateral involvement, longitudinally extensive optic nerve lesions, and perineural enhancement [1,5]. Acute attacks are treated mainly with high-dose corticosteroids, and plasma exchange (PLEX) is also used; maintenance immunotherapy may be considered to prevent relapses, although evidence from randomized trials is limited [2-4]. Even when acute visual loss is severe, most patients recover well [5-8], although a small number of patients with severe residual visual dysfunction have been reported [8,9].

Most predictors of poor visual outcome, such as delayed corticosteroid treatment [7,10], older age, worse visual acuity at the time of PLEX, and a longer delay to PLEX [11], have been identified in cohort studies that compared different patients. In bilateral MOG-ON, the two eyes share patient-level factors, such as age, antibody status, and systemic treatment; therefore, a marked interocular difference in outcome may help identify eye-specific factors associated with poor recovery. In addition, because the peripapillary retinal nerve fiber layer (pRNFL) is thickened by disc swelling in the acute phase [12], serial measurement of macular inner retinal thickness with optical coherence tomography (OCT), together with visual field testing and critical flicker fusion frequency (CFF), may help clarify how structural and functional damage evolves in each eye [4,10,13,14].

Here, we report a case of rapid-onset bilateral MOG-ON in which the outcomes differed markedly between

the eyes despite identical treatment and in which we were able to document the longitudinal structural and functional changes.

Case Presentation

A 60-year-old man had no notable medical history other than hypertension. He noticed blurred vision in the right eye on waking (designated as day zero). On day four, pain on eye movement developed in both eyes, and he lost central vision in the right eye, whereas the left eye had no visual symptoms. The next day, he could see almost nothing with the right eye and developed blurred vision in the left eye, which prompted him to consult a local ophthalmologist, who referred him to our department with suspected bilateral optic neuritis. At the first visit to our department (day nine), visual acuity was counting fingers in the right eye and light perception in the left eye, and intraocular pressure was 19 mmHg in the right eye and 15 mmHg in the left eye. A relative afferent pupillary defect (RAPD) was present in the left eye, and the direct light reflex was absent in that eye. Fundus examination showed marked swelling of both optic discs without any other fundus abnormalities, and there were no neurological abnormalities other than those of the optic nerves. Contrast-enhanced orbital magnetic resonance imaging (MRI) performed on the same day showed hyperintensity of both optic nerves on coronal short tau inversion recovery images (Figure *1A*). Contrast-enhanced fat-suppressed T1-weighted images showed perineural enhancement of the left intraorbital optic nerve (Figure *1B*) and enhancement of both optic nerves extending from the optic disc almost to the optic chiasm (Figures *1C*, *1D*). Brain MRI showed only chronic ischemic changes in the cerebral white matter.

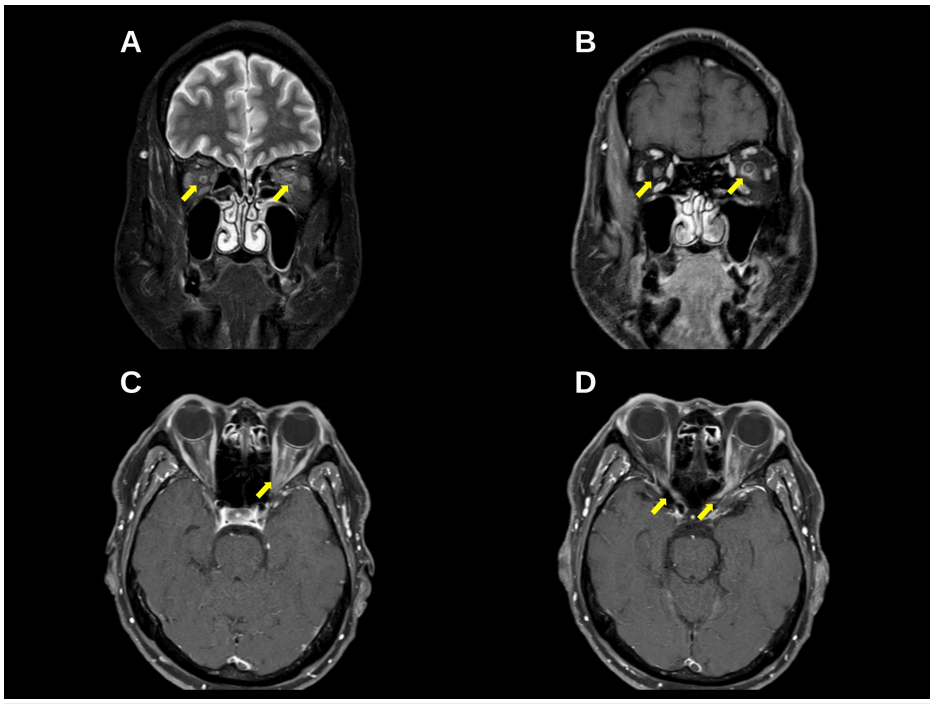

FIGURE 1: Pretreatment contrast-enhanced orbital magnetic resonance imaging.

(A) Coronal short tau inversion recovery (STIR) image showing hyperintensity of both optic nerves (arrows), more marked on the left. (B) Coronal contrast-enhanced fat-suppressed T1-weighted image showing perineural enhancement of the left optic nerve, which is minimal on the right (arrows). (C, D) Axial contrast-enhanced fat-suppressed T1-weighted images showing enhancement of both optic nerves extending from the optic disc almost to the optic chiasm. The arrow in C indicates enhancement of the left optic nerve, and the arrows in D indicate enhancement of both optic nerves near the optic chiasm. The left side of each image corresponds to the patient's right side.

Serum MOG-IgG was positive at a titer of 1:64 on a cell-based assay (CBA), and AQP4-IgG was negative on CBA. Cerebrospinal fluid analysis showed a cell count of 1/μL, a protein level of 0.52 g/L, and an IgG index of 0.64; oligoclonal bands were negative. Serological tests for syphilis, human immunodeficiency virus, hepatitis B and C, and herpes simplex and varicella-zoster virus immunoglobulin M were negative, and the soluble interleukin-2 receptor level was within the reference range (235 U/mL). Based on these findings, we diagnosed bilateral MOG-ON fulfilling the International MOGAD Panel diagnostic criteria [1]. Hereafter, best-corrected visual acuity (BCVA) is expressed as the logarithm of the minimum angle of resolution (logMAR), converted from decimal visual acuity; counting fingers, light perception, and no light perception (NLP) were not converted. Pulse corticosteroid therapy was planned, and he was admitted on day 12 according to the hospital admission schedule; at admission, BCVA was logMAR 2.00 in the right eye, and the

left eye had NLP. Intravenous methylprednisolone pulse therapy (IVMP; 1,000 mg/day) was given on days 13-15, followed by oral prednisolone (PSL) 40 mg/day on days 16-18. BCVA in the right eye improved to logMAR 0.15, but the left eye remained NLP; therefore, a second course of IVMP was given on days 19-21, and five sessions of PLEX were performed on days 20-34. Oral PSL was restarted at 80 mg/day on day 22 and then tapered (Table 1).

Day	Findings	BCVA OD (logMAR)	BCVA OS (logMAR)	CFF OD/OS (Hz)	Treatment
9	First visit; RAPD in the left eye; bilateral disc swelling; MRI	CF	LP	NM/NM	N/A
12	Admission	2.00	NLP	NM/NM	N/A
13–15	N/A	N/A	N/A	N/A	IVMP 1,000 mg/day (course 1)
16	N/A	0.40	NLP	11.5/NM	Oral PSL 40 mg/day (days 16–18)
18	N/A	0.15	NLP	11.3/NM	N/A
19–21	N/A	N/A	N/A	N/A	IVMP 1,000 mg/day (course 2)
20–34	N/A	N/A	N/A	N/A	PLEX, five sessions (days 20, 24, 27, 31, and 34); oral PSL 80 mg/day from day 22, then tapered
33	Visual acuity in the left eye became measurable	0.05	2.00	26.2/11.5	N/A
68	Disc swelling almost resolved	0.00	1.52	30.5/15.3	N/A
88	N/A	−0.08	1.30	N/A	N/A
116	Left-predominant macular inner retinal thinning on GCA	−0.08	0.82	N/A	N/A
151	No relapse; residual central scotoma in the left eye	−0.08	0.82	33.3/15.2	Oral PSL 20 mg on alternate days

TABLE 1: Clinical course, visual function, and treatment.

Days are counted from the onset of visual symptoms in the right eye (day zero). Best-corrected visual acuity is expressed as logMAR converted from decimal visual acuity; CF, LP, and NLP were not converted. N/A, not applicable or not measured.

BCVA = best-corrected visual acuity; CF = counting fingers; CFF = critical flicker fusion frequency; GCA = ganglion cell analysis; IVMP = intravenous methylprednisolone pulse therapy; logMAR = logarithm of the minimum angle of resolution; LP = light perception; MRI = magnetic resonance imaging; NLP = no light perception; NM = not measurable; OD = right eye; OS = left eye; PLEX = plasma exchange; PSL = prednisolone; RAPD = relative afferent pupillary defect

BCVA in the right eye recovered to logMAR −0.08 by day 88, whereas that in the left eye improved only to logMAR 0.82 by day 116, with no further improvement through day 151. CFF (Handy Flicker, Neitz Instruments Co., Ltd., Tokyo, Japan) recovered from 11.5 Hz on day 16 to 33.3 Hz on day 151 in the right eye, whereas in the left eye it plateaued at approximately 15 Hz from day 68 onward. No relapse occurred during follow-up, and on day 151, he was taking only PSL 20 mg on alternate days. Optic disc B-scans obtained with SPECTRALIS (Heidelberg Engineering, Heidelberg, Germany) showed marked bilateral disc swelling without peripapillary hyperreflective ovoid mass-like structures on day nine (Figures 2A, 2B). Macular ganglion cell analysis (GCA; from the internal limiting membrane to the inner plexiform layer/inner nuclear layer boundary) with the RS-3000 (NIDEK Co., Ltd., Gamagori, Japan) on the same day showed mean superior/inferior thicknesses of 95/95 µm in the right eye and 90/90 µm in the left eye (Figures 2C, 2D). Because these scans were decentered from the fovea, particularly in the left eye, and were obtained during marked disc swelling, the day nine values were interpreted with caution. The scans on days 33 and 116 were centered on the fovea. On day 33, the GCA values were 81/88 µm and 77/82 µm, respectively, and a wide perifoveal area had already thinned in the left eye (Figures 2E, 2F). Disc swelling had almost resolved by day 68 (Figures 2G, 2H). On day 116, the values were 77/84 µm and 55/58 µm, respectively, and macular inner retinal thinning had progressed over almost the entire analysis area in the left eye (Figures 2I, 2J).

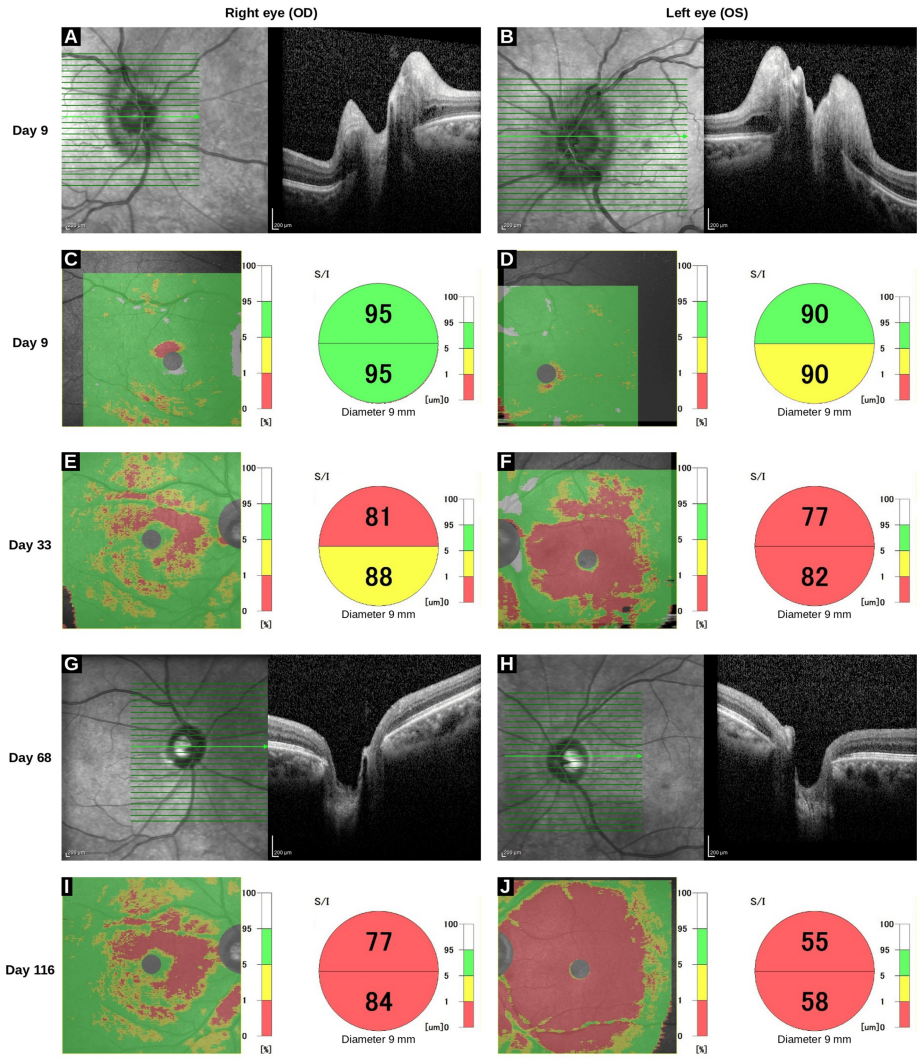

FIGURE 2: Longitudinal optical coherence tomography findings.

Left column, right eye (OD); right column, left eye (OS). (A, B) Optic disc B-scans obtained with SPECTRALIS on day nine, showing marked disc swelling in both eyes without peripapillary hyperreflective ovoid mass-like structures. (C, D) Macular ganglion cell analysis (GCA; internal limiting membrane to inner plexiform layer/inner nuclear layer boundary) with the RS-3000 on day nine. The scans are decentered from the fovea in both eyes, particularly in the left eye, and the image margins include unanalyzed areas; these values should therefore be interpreted with caution. (E, F) GCA on day 33, with the scans centered on the fovea. In the left eye, a wide perifoveal area is already below the 1% level of the normative database. (G, H) Optic disc B-scans on day 68, showing almost complete resolution of disc swelling. (I, J) GCA on day 116, with the scans centered on the fovea. Thinning has progressed in the left eye, with almost the entire analysis area below the 1% level, whereas thinning in the right eye is milder. In each GCA panel, the left image is a deviation map compared with the normative database (red, below 1%; yellow, 1%-5%; green, 5%-95%; white, above 95%), and the right image shows the mean superior/inferior (S/I) thickness (μm) within a 9-mm-diameter circle. The arrow on each infrared fundus image indicates the position of the displayed B-scan; scale bars, 200 μm.

Goldmann perimetry (L-1560 Goldmann-type perimeter; Inami & Co., Ltd., Tokyo, Japan) on day nine showed a severe visual field defect in the right eye, whereas the left eye was not measurable (Figures *3A*, *3B*). On day 151, the right visual field had almost recovered, whereas a visual field defect including a central I/4e scotoma persisted in the left eye (Figures *3C*, *3D*). The course of visual acuity, CFF, and treatment is shown in Figure *4*, and the findings in the two eyes are compared in Table *2*.

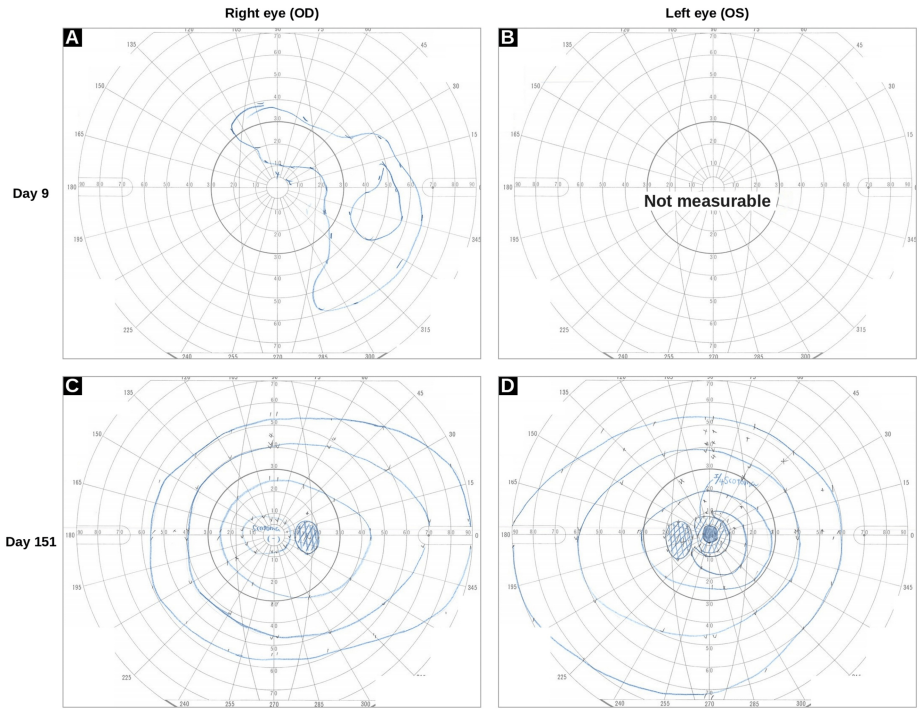

FIGURE 3: Goldmann visual fields (L-1560).

(A) Right eye (OD) on day nine, showing a severe visual field defect (outer isopter, V/4e; inner isopter, III/4e). (B) Left eye (OS) on day nine: not measurable. (C) Right eye on day 151, showing almost complete recovery without a central scotoma (isopters: V/4e, I/4e, I/2e, and I/1e). (D) Left eye on day 151, showing a persistent central I/4e scotoma (isopters: V/4e, I/4e, I/3e, and I/2e). Hatched areas indicate scotomas, including the blind spot.

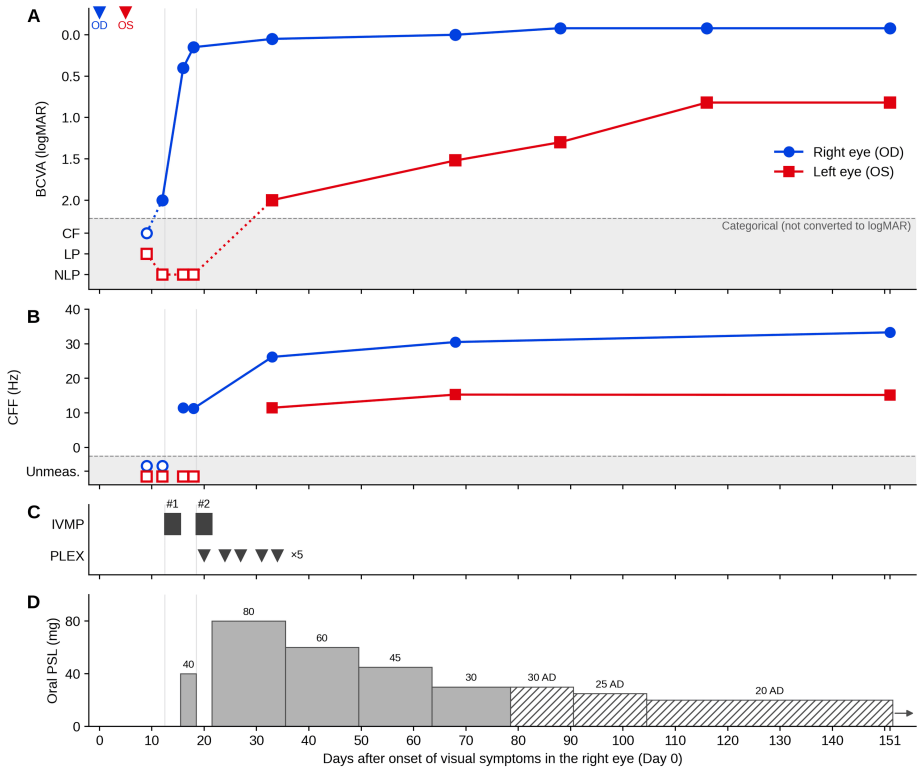

FIGURE 4: Course of best-corrected visual acuity, critical flicker fusion frequency, and treatment.

The horizontal axis shows days after the onset of visual symptoms in the right eye (day zero). (A) Best-corrected visual acuity (BCVA; logMAR, converted from decimal acuity). Blue circles, right eye (OD); orange squares, left eye (OS). Counting fingers (CF), light perception (LP), and no light perception (NLP) are not converted to logMAR and are plotted as categories with open symbols. (B) Critical flicker fusion frequency (CFF, Hz). Unmeasurable values (NM) are plotted with open symbols. The numbers at the right end of the lines indicate the values on day 151 (logMAR in A; Hz in B). (C) Onset in each eye (▼), intravenous (IV) methylprednisolone pulse therapy (IVMP; courses #1 and #2), and plasma exchange (PLEX; ▼, five sessions). (D) Oral prednisolone (PSL) dose (mg). Hatched bars indicate alternate-day dosing (AD). Gray vertical bands indicate the IVMP courses. BCVA in the right eye improved rapidly after the first IVMP course, before PLEX was started. In contrast, the left eye remained NLP after the first course, became measurable by day 33 during the PLEX period, and then improved only to logMAR 0.82. CFF in the right eye recovered to 33.3 Hz, whereas that in the left eye plateaued at approximately 15 Hz from day 68 onward. logMAR, logarithm of the minimum angle of resolution.

	Right eye	Left eye
Onset of visual symptoms	Day 0	Day 5
Interval from onset to first IVMP/first PLEX	~13/~20 days	~8/~15 days
BCVA at first visit/nadir	CF/CF	LP/NLP
RAPD	Absent	Present (absent direct light reflex)
Pretreatment MRI (day 9)	Optic nerve hyperintensity and enhancement, milder than on the left (~9 days after onset)	More marked hyperintensity and enhancement with intraorbital perineural enhancement (~4 days after onset)
BCVA after first IVMP course/on day 151 (logMAR)	0.15/−0.08	NLP/0.82
CFF on day 151	33.3 Hz	15.2 Hz
Goldmann visual field on day 151	Almost recovered	Residual central scotoma
GCA S/I thickness (μm), days 9*/33/116	95/95/81/88/77/84	90/90 / 77/82 / 55/58

TABLE 2: Comparison of findings between the two eyes.

Onset was defined for each eye as the day on which visual symptoms appeared. Best-corrected visual acuity is expressed as logMAR converted from decimal visual acuity; CF, LP, and NLP were not converted.

*: On day nine, the GCA scans were decentered from the fovea in both eyes, particularly in the left eye; the scans on days 33 and 116 were centered on the fovea.

BCVA = best-corrected visual acuity; CF = counting fingers; CFF = critical flicker fusion frequency; GCA = ganglion cell analysis (within a 9-mm-diameter circle); IVMP = intravenous methylprednisolone pulse therapy; logMAR = logarithm of the minimum angle of resolution; LP = light perception; MRI = magnetic resonance imaging; NLP = no light perception; PLEX = plasma exchange; RAPD = relative afferent pupillary defect; S/I = superior/inferior

Discussion

Our patient showed several features that are characteristic of MOG-ON and help distinguish it from other causes of optic neuritis: bilateral involvement with a short interval between the eyes, pain on eye movement, marked optic disc swelling, and longitudinally extensive optic nerve enhancement with perineural enhancement [1,4,5]. AQP4-IgG negativity on CBA, the absence of oligoclonal bands, and brain MRI showing only chronic ischemic white matter changes argued against neuromyelitis optica spectrum disorder and multiple sclerosis. Anterior ischemic optic neuropathy was considered unlikely because of pain on eye movement, optic nerve enhancement on MRI, and involvement of both eyes within days, and infectious causes were not supported by serological testing.

The visual prognosis of MOG-ON is generally considered favorable. In a study of 87 patients, the mean nadir visual acuity in the most severe attack was counting fingers, but the mean final visual acuity was logMAR 0.2 (Snellen 20/30), and only 6% had a final visual acuity of logMAR 1.0 (20/200) or worse in either eye [5]. Among 82 patients with a first attack, 91% recovered to logMAR 0.0 (20/20) at three months [7]. The final BCVA of logMAR 0.82 in the left eye of our patient represents a poor outcome for MOG-ON.

Attacks treated with IVMP within two days of visual loss recover faster, but final visual acuity does not differ significantly after adjustment for visual acuity at the time of treatment [6]. In contrast, a delay of 10 days or more to the first dose of methylprednisolone has been reported to be associated with failure to recover to logMAR 0.0 at three months [7]. In our patient, the interval from onset to IVMP was approximately 13 days in the right eye and 8 days in the left eye; thus, treatment was started earlier in the left eye, which had the poorer outcome. Eye pain reportedly precedes visual loss by a median of three days [6], but even if the eye pain on day four is taken as the onset in the left eye, the interval to corticosteroid treatment would still be approximately nine days. Therefore, it is difficult to explain the interocular difference by the timing of treatment alone. From the first visit, the left eye had worse visual acuity, an RAPD, and more prominent MRI findings, suggesting that the initial damage may have been more severe in this eye.

Moreover, severe visual impairment has been reported to persist in some patients with extensive lesions involving the optic chiasm [8]. In our patient, the lesions also extended almost to the chiasm and were more

prominent on the left side. However, MRI was performed at different disease stages in the two eyes (approximately nine days after onset in the right eye and four days after onset in the left eye); although the MRI asymmetry corresponded to the asymmetry in outcome, it cannot be concluded that the MRI findings directly predicted the outcome.

In an international multicenter study of 395 attacks, outcomes after PLEX were better in MOG-ON than in optic neuritis of other etiologies, whereas older age, worse visual acuity at the time of PLEX, and a longer delay to PLEX were associated with poor outcomes [11]. In our patient, the interval from onset to PLEX was shorter in the left eye (approximately 15 days in the left eye vs. 20 days in the right eye); therefore, the only factor that differed unfavorably in the left eye was visual acuity before PLEX (logMAR 0.15 in the right eye vs. NLP in the left eye on day 18; the last assessment before PLEX was started on day 20). The left eye improved to logMAR 0.82 after PLEX; however, this improvement may also reflect the second IVMP course, oral PSL, or the natural course, and the temporal association does not establish the contribution of any individual treatment.

In acute MOG-ON, the pRNFL is markedly thickened by disc swelling [12]; therefore, acute-phase values are not suitable for assessing axonal damage. In addition, pRNFL analysis in our patient was affected by segmentation errors, so retinal structure was assessed with macular GCA. GCA values were obtained with automated segmentation, which can be affected by scan decentration, signal strength, and retinal swelling in the acute phase; therefore, the day nine values were interpreted with caution, and the interocular comparison was based on the scans on days 33 and 116, which were centered on the fovea and showed no obvious segmentation errors on visual inspection. The small interocular difference on day nine was probably due to the early stage of disease in the left eye, as well as to disc swelling and scan decentration. After day 33, further thinning in the right eye was mild, whereas thinning in the left eye progressed until day 116. In MOG-ON, inner retinal thinning has been reported to correlate with reduced visual field mean deviation [13], and worse nadir visual acuity and longer lesion length on MRI have been associated with reduced final macular ganglion cell-inner plexiform layer volume [10]; the findings in the left eye of our patient are consistent with these reports. Although BCVA in the right eye recovered to logMAR −0.08, macular inner retinal thinning was also observed in that eye, albeit less marked than in the left eye.

CFF reflects the temporal resolution of the visual system and is known to correlate with BCVA, visual field mean deviation, and flash visual evoked potential latency in demyelinating optic neuritis [14]. In our patient, CFF in the left eye remained at approximately 15 Hz from day 68 onward, consistent with the poor final visual acuity in this eye.

Taken together, treatment timing cannot explain the asymmetric outcome, because both IVMP and PLEX were started earlier after onset in the left eye. In contrast, the left eye had worse findings at presentation (worse visual acuity, RAPD, and more prominent MRI findings) and during follow-up (progressive macular inner retinal thinning until day 116 and persistently low CFF). The asymmetry therefore appears more consistent with a difference in the initial severity of optic nerve damage than with a difference in treatment timing. However, because MRI was obtained at different disease stages in the two eyes and only one patient was studied, the prognostic value of these findings cannot be established.

This report has limitations. In particular, IVMP was started four days after the first visit, during which the visual acuity of the left eye deteriorated from light perception to NLP; therefore, the possibility that earlier treatment would have changed the outcome cannot be excluded. In addition, MRI was obtained at different disease stages in the two eyes; retinal thickness was measured with automated segmentation; the day nine scans were decentered; CFF is a subjective test; and the follow-up period was approximately five months.

Conclusions

In this patient with rapid-onset bilateral MOG-ON, structural and functional outcomes differed markedly between the eyes despite identical systemic treatment, and the left eye had the poorer outcome even though its treatment was started earlier after onset. Greater initial severity in the left eye may have contributed to this asymmetry, whereas the influence of the four-day interval before corticosteroid initiation and of the second IVMP course and PLEX on visual recovery could not be determined. This case highlights the importance of assessing each eye individually and monitoring visual acuity, visual field, OCT, and CFF longitudinally in bilateral MOG-ON. Because these observations are derived from a single case, they should not be generalized to prognosis or treatment decisions.

Additional Information

Author Contributions

All authors have reviewed the final version to be published and agreed to be accountable for all aspects of the work.

Concept and design: Ryusuke Hashimoto, Yutaro Morita

Acquisition, analysis, or interpretation of data: Ryusuke Hashimoto, Yutaro Morita, Takayuki Baba

Drafting of the manuscript: Ryusuke Hashimoto, Yutaro Morita

Critical review of the manuscript for important intellectual content: Ryusuke Hashimoto, Yutaro Morita, Takayuki Baba

Supervision: Takayuki Baba

Disclosures

Human subjects: Informed consent for treatment and open access publication was obtained or waived by all participants in this study. **Conflicts of interest:** In compliance with the ICMJE uniform disclosure form, all authors declare the following: **Payment/services info:** All authors have declared that no financial support was received from any organization for the submitted work. **Financial relationships:** All authors have declared that they have no financial relationships at present or within the previous three years with any organizations that might have an interest in the submitted work. **Other relationships:** All authors have declared that there are no other relationships or activities that could appear to have influenced the submitted work.

References

1. Banwell B, Bennett JL, Marignier R, et al.: Diagnosis of myelin oligodendrocyte glycoprotein antibody-associated disease: International MOGAD Panel proposed criteria. Lancet Neurol. 2023, 22:268-82. 10.1016/S1474-4422(22)00431-8
2. Ambrosius W, Michalak S, Kozubski W, Kalinowska A: Myelin oligodendrocyte glycoprotein antibody-associated disease: current insights into the disease pathophysiology, diagnosis and management. Int J Mol Sci. 2020, 22:100. 10.3390/ijms22010100
3. Marignier R, Hacohen Y, Cobo-Calvo A, et al.: Myelin-oligodendrocyte glycoprotein antibody-associated disease. Lancet Neurol. 2021, 20:762-72. 10.1016/S1474-4422(21)00218-0
4. Jeyakumar N, Lerch M, Dale RC, Ramanathan S: MOG antibody-associated optic neuritis. Eye (Lond). 2024, 38:2289-301. 10.1038/s41433-024-03108-y
5. Chen JJ, Flanagan EP, Jitprapaikulsan J, et al.: Myelin oligodendrocyte glycoprotein antibody-positive optic neuritis: clinical characteristics, radiologic clues, and outcome. Am J Ophthalmol. 2018, 195:8-15. 10.1016/j.ajo.2018.07.020
6. Chen JJ, Flanagan EP, Bhatti MT, et al.: Details and outcomes of a large cohort of MOG-IgG associated optic neuritis. Mult Scler Relat Disord. 2022, 68:104237. 10.1016/j.msard.2022.104237
7. Rode J, Pique J, Maarouf A, et al.: Time to steroids impacts visual outcome of optic neuritis in MOGAD . J Neurol Neurosurg Psychiatry. 2023, 94:309-13. 10.1136/jnnp-2022-330360
8. Akaishi T, Himori N, Takeshita T, et al.: Five-year visual outcomes after optic neuritis in anti-MOG antibody-associated disease. Mult Scler Relat Disord. 2021, 56:103222. 10.1016/j.msard.2021.103222
9. Handzic A, Naidu S, Brossard-Barbosa N, Margolin E: Poor visual outcome after first attack in a cohort of patients with myelin oligodendrocyte glycoprotein-related optic neuritis. J Neuroophthalmol. 2024, 44:178-83. 10.1097/WNO.0000000000002002
10. Princet C, Shor N, Boudot de la Motte M, et al.: Early corticosteroids predict visual whereas MRI lesion extent predicts retinal atrophy outcomes in MOG antibody-associated optic neuritis. Mult Scler. 2026, 32:487-96. 10.1177/13524585261428950
11. Chen JJ, Flanagan EP, Pittock SJ, et al.: Visual outcomes following plasma exchange for optic neuritis: an international multicenter retrospective analysis of 395 optic neuritis attacks. Am J Ophthalmol. 2023, 252:213-24. 10.1016/j.ajo.2023.02.013
12. Chen JJ, Sotirchos ES, Henderson AD, et al.: OCT retinal nerve fiber layer thickness differentiates acute optic neuritis from MOG antibody-associated disease and Multiple Sclerosis: RNFL thickening in acute optic neuritis from MOGAD vs MS. Mult Scler Relat Disord. 2022, 58:103525. 10.1016/j.msard.2022.103525
13. Deschamps R, Philibert M, Lamirel C, et al.: Visual field loss and structure-function relationships in optic neuritis associated with myelin oligodendrocyte glycoprotein antibody. Mult Scler. 2021, 27:855-63. 10.1177/1352458520937281
14. Fu J, Wang Y, Tan S, Xu G, Zhou H, Xu Q, Wei S: The clinical application of critical flicker fusion frequency in demyelinating optic neuritis. Adv Ophthalmol Pract Res. 2021, 1:100011. 10.1016/j.aopr.2021.100011