Cureus
Part of SPRINGER NATURE

Open Access Case Report

Multidisciplinary Airway Management of an Impacted Pharyngeal Spring in a Resource-Constrained Setting: A Case Report

Review began 10/15/2026
Review ended 11/22/2026
Published 11/24/2026

© Copyright 2026
Masoodi et al. This is an open access article distributed under the terms of the Creative Commons Attribution License CC-BY 4.0., which permits unrestricted use, distribution, and reproduction in any medium, provided the original author and source are credited.

DOI: 10.7759/cureus.120207

Tahir Masoodi [1], Sana Y. Hussain [2], Pratibha Panjiar [1, 3], Tariq Rasool [4]

1. Anesthesiology, Hamdard Institute of Medical Sciences and Research, Delhi, IND 2. Anesthesiology, Pain Medicine, and Critical Care, All India Institute of Medical Sciences, Delhi, IND 3. Anesthesiology, All India Institute of Medical Sciences, Bhopal, IND 4. Computer Science and Engineering, Model Institute of Engineering and Technology, Jammu, IND

Corresponding author: Tariq Rasool, tariqcukashmir@gmail.com

Abstract

Impacted penetrating foreign bodies in the aerodigestive tract of infants can lead to complete airway obstruction, vascular injury, and hypoxemic arrest. Conventional extraction techniques may be unsuccessful when a sharp or coiled metal object has anchored itself in pharyngeal soft tissue.

A 10-month-old boy presented with acute inspiratory stridor, pooling of blood-tinged oral secretions, and an industrial steel spring extending from the hypopharynx and protruding from his mouth. A lateral radiograph showed a coiled metallic body pushing the laryngeal framework forward. To eliminate the leverage exerted by the protruding spring and allow an airtight face-mask seal, we steadied it with gauze and cut it short externally. Supplemental oxygen was administered via nasal prongs at 6 L/min during airway preparation while spontaneous breathing was maintained. Anesthesia was induced with titrated sevoflurane and propofol while maintaining spontaneous ventilation. Once direct laryngoscopy revealed a Cormack-Lehane Grade II view, we gave succinylcholine and secured the airway on the first pass with a 3.5 mm uncuffed endotracheal tube. Rigid endoscopic extraction failed because mucosa was trapped between the coils, so the remaining spring was removed intact by manually unhooking it under direct laryngoscopy. The tube was accidentally dislodged during extraction. Nasal oxygen was immediately resumed at 6 L/min, and peripheral oxygen saturation remained above 95% until reintubation. Intravenous dexamethasone was given, and the infant was extubated on postoperative day 1 and discharged without sequelae.

This case highlights the importance of individualized airway planning, multidisciplinary coordination, careful modification of a protruding foreign body when appropriate, and preparation for airway rescue in infants with impacted penetrating aerodigestive foreign bodies.

Categories: Otolaryngology, Emergency Medicine, Anesthesiology
Keywords: accidental extubation, apneic oxygenation, case report, pediatric difficult airway, penetrating foreign body, resource-constrained setting

Introduction

Foreign bodies of the ear, nose, and throat are a common problem in both children and adults [1], and airway foreign bodies in particular can cause serious morbidity and death, with the incidence peaking between six months and three years of age [2,3]. Airway management in infants is especially hazardous. The airway is narrow, and the cartilaginous framework is soft and collapsible. Infants also have a high oxygen consumption and a relatively small functional residual capacity, so they tolerate apnea poorly and desaturate quickly [4,5]. An impacted, sharp, or interlocking foreign body presents an additional clinical challenge. Positive-pressure ventilation carries a theoretical risk of pushing a proximal object further down the airway, although evidence is limited [2,6], while blind instrumentation risks further mucosal laceration, perforation, and uncontrollable hemorrhage. Penetrating injuries of the lateral pharynx can also threaten adjacent vascular structures, and carotid injury has been described in children with oropharyngeal impalement [7,8].

These problems are magnified where specialized equipment is unavailable, as reported at other resource-constrained centers [7,9]. In our hospital, pediatric video laryngoscopes, advanced grasping instruments, and transnasal humidified rapid insufflation ventilatory exchange (THRIVE) systems were not available. Penetrating oropharyngeal foreign bodies in children are described mainly in single cases and small series involving objects such as pencils, toothbrushes, and metal rods [7-11].

In such resource-limited environments, structured multidisciplinary planning between anesthesiology and surgical teams is essential to manage shared airway hazards, maintain readiness for accidental extubation, and implement accessible supportive measures such as supplemental nasal oxygenation.

How to cite this article
Masoodi T, Hussain S Y, Panjiar P, et al. (November 24, 2026) Multidisciplinary Airway Management of an Impacted Pharyngeal Spring in a Resource-Constrained Setting: A Case Report. Cureus 18(11): e120207. DOI 10.7759/cureus.120207

A search of PubMed/MEDLINE and Google Scholar was conducted on September 17, 2026, using terms including “spring”, “foreign body”, “infant”, and “oropharyngeal”, and identified no previous report of an impacted industrial steel spring in an infant. A spring presents unique mechanical challenges: a projecting external lever arm, helical coils that trap swollen mucosa, and a curved anchoring hook. This report describes the decision-making, mechanical mitigation, and emergency airway rescue involved in managing an impacted oropharyngeal spring in an infant.

Case Presentation

Patient information

The case occurred in 2025 at the Hamdard Institute of Medical Sciences and Research, Delhi. A 10-month-old boy weighing 9.5 kg was brought to the emergency department in acute respiratory distress after swallowing an industrial steel spring that had become lodged in his throat. He had no relevant medical, surgical, or genetic history, and his developmental milestones were appropriate for his age. About one hour before presentation, family members had tried blind finger sweeps at home, and an on-call otolaryngologist then attempted forceps removal in the emergency room. Neither attempt dislodged the spring, and both worsened the local tissue injury. The infant had eaten solid food four hours before presentation and was therefore considered unfasted. The parents provided informed consent for surgery after being informed of the associated risks.

Clinical findings

On examination, the infant was agitated and tachypneic, with marked inspiratory stridor, suprasternal and intercostal retractions, and continuous pooling of blood-tinged secretions in the mouth. A heavy-gauge coiled metal spring protruded approximately 4 cm beyond his lips and prevented him from closing his mouth. His baseline vital signs were a heart rate of 158 beats/min, a respiratory rate of 42 breaths/min, a blood pressure of 88/54 mmHg, and a peripheral oxygen saturation (SpO_2) of 94% on room air.

Diagnostic assessment

Preoperative evaluation consisted of blood tests and urgent imaging. The complete blood count was within normal limits, showing a total leukocyte count of 12.4 × 10^3 cells/μL and a hemoglobin level of 11.2 g/dL. Baseline preoperative laboratory investigations, reference ranges, and units are detailed in Table *1*.

Laboratory parameter	Patient value	Reference range (6-12 months)	Unit	Interpretation
Hb	11.2	10.5-13.5	g/dL	Within age-appropriate range
TLC	12.4	6.0-17.0	×10^3/μL	Within age-appropriate range
Platelet count	310	150-450	×10^3/μL	Within reference range
Serum sodium	138	135-145	mmol/L	Within reference range
Serum potassium	4.3	3.5-5.1	mmol/L	Within reference range
BUN	11.0	5.0-18.0	mg/dL	Within reference range
Serum creatinine	0.3	0.2-0.4	mg/dL	Within age-appropriate range
PT	12.8	11.0-14.5	s	Within reference range
INR	1.05	0.85-1.15	-	Within reference range

TABLE 1: Laboratory investigations at presentation

Hb: hemoglobin, BUN: blood urea nitrogen, INR: international normalized ratio, PT: prothrombin time, TLC: total leukocyte count

Anteroposterior and lateral cervical and thoracic radiographs showed a dense coiled metallic foreign body running along the posterior pharyngeal wall into the hypopharynx and pushing the laryngeal air column forward (Figure *1A*). There was no subcutaneous emphysema, retropharyngeal free air, or pneumomediastinum.

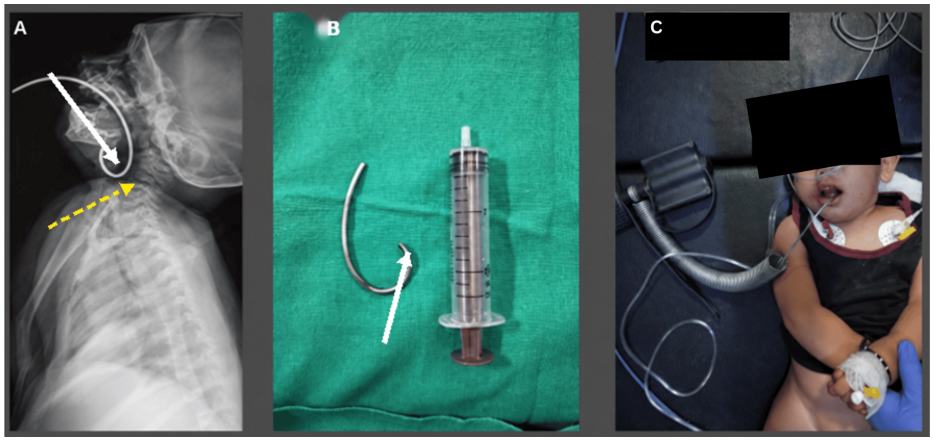

FIGURE 1: Imaging, extraction, and airway management of the retained foreign body

(A) Lateral neck radiograph showing the curved radiopaque foreign body in the hypopharyngeal region (white arrow) and associated anterior tracheal displacement (yellow dashed arrow). (B) Extracted metallic foreign body with the sharp terminal anchoring hook indicated by the white arrow. (C) De-identified clinical photograph during airway management.

The main diagnostic challenge was determining the depth of tissue penetration because injuries near the carotid artery can be life-threatening [7,8]. Dynamic contrast-enhanced CT angiography was not available in the emergency setting and was not feasible in an infant in respiratory distress. Our working diagnosis was an impacted penetrating metallic foreign body involving the oropharynx and hypopharynx with secondary mucosal injury and acute airway compromise. We considered deep fascial dissection and retropharyngeal hematoma as possible complications. The prognosis for full recovery was favorable, provided that the airway was secured and the object retrieved without mucosal tearing or hypoxic arrest.

Therapeutic intervention

Airway Preparation and Dual Strategy

In the emergency room, the stomach was decompressed using a nasogastric tube. The operating room was set up for an anticipated difficult pediatric airway, following the Difficult Airway Society pediatric guidance [12,13]. Although the guidance addresses unanticipated difficult airways in children aged one to eight years, it served as the framework for managing the anticipated difficult airway in this 10-month-old infant. We had straight Miller blades (sizes 0 and 1), curved Macintosh blades (sizes 1 and 2), and uncuffed endotracheal tubes (ETTs) (3.0, 3.5, and 4.0 mm ID), supraglottic airway devices (sizes 1.0 and 1.5), rigid ventilating bronchoscopes, and an emergency surgical tracheotomy tray with a 3.5 mm tracheostomy tube. Weight-based emergency drugs were drawn up beforehand. A formal multidisciplinary briefing was held between the anesthesiology and otolaryngology teams before induction to establish clear roles, nonverbal cues for surgical traction pauses, and readiness for immediate surgical front-of-neck access. We agreed on a two-part airway management strategy: Plan A involved induction with preserved spontaneous breathing, followed by direct laryngoscopy and oral tracheal intubation, whereas Plan B involved immediate surgical front-of-neck access (tracheotomy) by the otolaryngology team if a cannot-intubate, cannot-oxygenate situation developed.

Biomechanical Modification and Induction

We cut the protruding spring flush with the lips using sterile wire cutters. The aim was to remove the torque that could drive the distal hook deeper into the pharyngeal wall and to enable an effective face-mask seal. The intraoral segment was held with saline-soaked gauze and Magill forceps so that it could not recoil or shed a fragment into the posterior pharynx. Supplemental oxygen was administered via nasal prongs at 6 L/min while spontaneous ventilation was maintained. Nasal oxygen was discontinued after the airway was secured.

Atropine was administered at induction (0.02 mg/kg IV). We induced anesthesia by face mask with 100% oxygen and titrated sevoflurane (1% to 3%), adding an intravenous bolus of propofol (0.5 mg/kg). Spontaneous ventilation was maintained, and positive-pressure bag-mask ventilation was avoided to minimize the risk of distal displacement of the spring. Direct laryngoscopy with a Miller 1 blade gave a Cormack-Lehane Grade II view, with the glottis pushed to the left by the proximal turn of the spring.

Once we were satisfied that intubation was anatomically feasible, we gave succinylcholine (20 mg IV, ~2.1 mg/kg) to abolish airway reflexes and vocal cord movement. The trachea was intubated on the first pass with an uncuffed ETT with a 3.5-mm internal diameter, taped at the right corner of the mouth. We confirmed placement by symmetric bilateral auscultation and a sustained capnography waveform over consecutive breaths.

Surgical Retrieval and Complication Management

A rigid ventilating bronchoscope was passed into the hypopharynx alongside the ETT, but the optical grasping forceps could not free the spring because mucosa had caught between the coils. We returned to direct laryngoscopy to expose the posterior pharynx. Under direct visualization, the surgeon inserted a gloved index finger, turned the coil counterclockwise to release the terminal hook, and drew the remaining spring out intact through the mouth (Figure *1B*). The spring was anchored in the posterior hypopharyngeal region, with mucosa trapped between its coils. The exact depth of impalement could not be established intraoperatively. Following removal, the exposed hypopharyngeal mucosa was inspected directly for visible injury and bleeding. The depth of penetration could not be definitively determined intraoperatively, and vascular injury could not be definitively excluded in the absence of CT angiography.

During extraction, the ETT was inadvertently dislodged by the spring in the confined operative space, resulting in accidental extubation. At this point, the spring had not been completely removed. Supplemental oxygen was immediately restarted at 6 L/min via nasal prongs. SpO_2 remained above 95% during the reported interval. The precise duration between accidental extubation and successful reintubation, the apnea duration, and the presence or absence of spontaneous respiratory effort could not be reliably established from the available documentation. Repeat direct laryngoscopy revealed moderate reactive supraglottic edema. The trachea was successfully reintubated on the first attempt with a second uncuffed ETT with a 3.5-mm internal diameter, without documented hypoxemia or hemodynamic instability. Intravenous dexamethasone (0.2 mg/kg; 2.0 mg) was given to limit secondary airway edema.

Follow-up and outcomes

Following successful foreign body retrieval and airway stabilization, the infant was transferred under sedation to the pediatric intensive care unit (PICU) for continued mechanical ventilation and monitoring (Figure *1C*). He remained hemodynamically stable without inotropic support. On postoperative day 1, an audible air leak at 18 cm H_2O indicated that the laryngeal edema had subsided, and he was successfully extubated. He maintained spontaneous ventilation on room air and progressed to enteral feeds without dysphagia or stridor. He was discharged home in stable condition on postoperative day 3. At the two-week follow-up, clinical examination showed complete mucosal healing, with no hoarseness, stridor, or feeding difficulty.

Discussion

Strengths and limitations

The main strength of our approach was multidisciplinary crisis resource management: the surgical airway (Plan B) was prepared in parallel, and the spring was modified early. A pre-procedure multidisciplinary briefing ensured clear criteria for initiating rescue interventions and readiness for immediate front-of-neck access, while mitigating the inherent hazards of a shared aerodigestive operating space. Careful anticipation and quick intervention have also been stressed in other reports of penetrating airway injury in children from resource-constrained settings [9]. Cutting off the external portion removed the torque that could have driven the impalement deeper and, at the same time, allowed an airtight face-mask seal.

Although emergency surgical front-of-neck access was prepared as a rescue option, its feasibility in a 10-month-old infant requires particular caution. The small size of the laryngeotracheal structures, difficulty identifying anatomical landmarks, and the potential for injury to adjacent structures make emergency surgical airway access technically challenging. The availability of a tracheotomy tray therefore did not imply that surgical airway access would be straightforward or guaranteed to succeed. In a cannot-intubate, cannot-oxygenate scenario, rescue decisions would need to be individualized according to the infant's anatomy, the expertise of the available surgical team, equipment, and the feasibility of alternative oxygenation and airway rescue techniques.

Apneic oxygenation may reduce hypoxemia during pediatric intubation [4,14]. Infants are especially prone to precipitous desaturation due to their elevated oxygen consumption and reduced functional residual capacity. Supplemental nasal oxygen during airway instrumentation may provide an additional margin of safety against hypoxemia in settings lacking high-flow devices; however, conventional nasal oxygen delivery should not be equated with high-flow nasal oxygen or with a standardized apneic oxygenation technique. In our patient, SpO_2 remained above 95% during the reported accidental extubation interval. However, the contribution of nasal oxygen cannot be separated from prior preoxygenation with 100% oxygen, the duration of airway disruption, and the patient's residual oxygen reserve. The exact apnea duration and spontaneous respiratory effort during the event were not reliably documented. Much of the published

evidence concerns planned tracheal intubation rather than accidental extubation and includes high-flow nasal oxygen, so the findings may not be directly transferable [14]. This observation should therefore be interpreted cautiously and does not establish that nasal oxygen prevented desaturation.

A major limitation was the resource-constrained setting, which lacked pediatric video laryngoscopes, THRIVE, and advanced grasping instruments. As a result, manual extraction of the spring was required. This technique carries an inherent risk of mucosal laceration or secondary aspiration into the lower airway, and it contributed to tube displacement in a crowded pediatric airway. This highlights the persistent challenge of shared airway scenarios in infants, where surgical extraction tools and ETTs compete for space, requiring rehearsed reintubation protocols and readiness to provide supplemental nasal oxygen. The infant was also unfasted and had blood in the pharynx, so he was at risk of aspiration during and after induction, creating competing concerns regarding aspiration and the avoidance of positive-pressure ventilation. The stomach was decompressed in the emergency room with a nasogastric tube, and the infant was transferred to the PICU postoperatively, where chest radiography was performed before he was extubated. The dexamethasone dose we used (0.2 mg/kg) was lower than the 0.4-1 mg/kg range described for preventing airway edema after bronchoscopic foreign body removal [2], and the evidence that corticosteroids prevent post-extubation stridor in children is limited [15]. Finally, the depth of impalement could not be defined without CT, and, as a single case, our experience cannot show that this sequence is better than alternative approaches. Additionally, precise timing and detailed physiological parameters during the accidental extubation episode could not be independently verified from the available anesthesia documentation.

Comparison with relevant literature

Penetrating oropharyngeal injuries in children are reported mostly as single cases and small series [7-11]. Several involved children aged two to five years and objects such as toothbrushes, pencils, and metal rods [7,9]. These reports stress careful pre-anesthetic assessment, close coordination between the surgeon and anesthesiologist, the use of non-standard equipment when specialized equipment is unavailable, and the risk of injury to nearby vessels [7,8,10]. Managing complex pediatric aerodigestive emergencies in resource-constrained environments often requires practical adaptations to standard difficult airway algorithms that assume immediate access to video laryngoscopes, specialized grasping forceps, or advanced imaging. As reported by other resource-constrained centers [7,9], our experience shows that meticulous physical stabilization, preservation of spontaneous ventilation, and tactile manual unhooking under direct vision can safely overcome technical and infrastructural deficits. Our case differs in the patient's age, the mechanical behavior of the object (an external lever arm, coils that trapped mucosa, and an anchoring hook), and the need for rescue after accidental extubation.

The optimal ventilation strategy for children with airway foreign bodies remains uncertain. In tracheobronchial foreign body removal, published reports describe both spontaneous and controlled ventilation, and neither technique is superior [2,3,6]. These data cannot be applied directly to a penetrating hypopharyngeal spring. We chose to preserve spontaneous breathing during induction because, with a sharp spring lodged proximally, we were concerned that positive-pressure ventilation or vigorous instrumentation could displace it distally or worsen the tissue injury.

The use of neuromuscular blockade in a threatened airway is also debated [2,3,6]. Traditional teaching advises against the use of neuromuscular blocking agents when the airway is compromised, but we gave succinylcholine only after a Cormack-Lehane Grade II view had been obtained. With sharp metal edges in the pharynx, coughing, bucking, or vocal cord closure could avulse a vocal fold or drive the object down to the carina. A short-acting relaxant given once the glottis had been seen removed that risk of movement, without exposing the infant to unmonitored paralysis during the initial assessment. Current French pediatric airway guidelines recommend a rapid-onset relaxant during classic rapid-sequence induction in children, with succinylcholine the probable first choice [16], although our induction did not follow a conventional rapid-sequence induction protocol. Succinylcholine was preferred over rocuronium because sugammadex, the reversal agent for rocuronium, was not available at our center. Atropine was given at induction (0.02 mg/kg).

Rigid bronchoscopy is the conventional approach to tracheobronchial foreign body retrieval [2,6]. In our patient, however, the spring was lodged in the hypopharynx, and the optical grasping forceps could not free it because edematous mucosa was trapped between the coils. Direct axial traction posed a risk of mucosal tearing due to shear forces. Switching to direct laryngoscopy with manual digital unhooking gave three-dimensional tactile feedback and allowed the terminal hook to be released safely.

Conclusions

This case illustrates the challenges of managing sharp, impacted oropharyngeal foreign bodies in infants. In this patient, shortening the protruding portion of the foreign body facilitated an effective face-mask seal and helped prevent additional trauma to the levered tissue. Preserving spontaneous breathing during induction may have helped limit distal migration, while supplemental nasal oxygen during airway disruption may have provided an additional margin of safety against desaturation, including during accidental extubation. The case also highlights the importance of anticipating airway disruption and preparing individualized rescue strategies, including surgical airway options where appropriate, while recognizing the

technical limitations of front-of-neck access in infants. These observations represent practical lessons from a single case and should not be interpreted as universal management recommendations.

Appendices

Patient perspective as reported by the parents

> Seeing our baby unable to swallow, crying in pain, and bleeding with a heavy metal spring stuck in his mouth was terrifying. We tried everything to pull it out at home, but we quickly realized it was wedged tightly and made him bleed more. When we reached the hospital, the medical team explained the seriousness of his compromised breathing, the high risks involved, and their structured rescue plans. We are grateful for their quick actions in cutting the spring, securing his breathing, and safely removing the object. Watching him breathe comfortably and eat normally after the surgery brought immense relief to our entire family.

This statement was originally given in Hindi to the attending emergency physician on duty, who translated it into English. Before the infant was taken to the operating room, Dr. Tahir Masoodi took a further history from the parents in consultation with the emergency physician, and the two finalized the translation together.

Additional Information

Author Contributions

All authors have reviewed the final version to be published and agreed to be accountable for all aspects of the work.

Concept and design: Tariq Rasool, Tahir Masoodi

Critical review of the manuscript for important intellectual content: Tariq Rasool, Sana Y. Hussain

Acquisition, analysis, or interpretation of data: Sana Y. Hussain, Pratibha Panjiar

Supervision: Sana Y. Hussain, Tahir Masoodi

Drafting of the manuscript: Tahir Masoodi, Pratibha Panjiar

Disclosures

Human subjects: Informed consent for treatment and open access publication was obtained or waived by all participants in this study. **Conflicts of interest:** In compliance with the ICMJE uniform disclosure form, all authors declare the following: **Payment/services info:** All authors have declared that no financial support was received from any organization for the submitted work. **Financial relationships:** All authors have declared that they have no financial relationships at present or within the previous three years with any organizations that might have an interest in the submitted work. **Other relationships:** All authors have declared that there are no other relationships or activities that could appear to have influenced the submitted work.

References

1. Parajuli R: Foreign bodies in the ear, nose and throat: an experience in a tertiary care hospital in central Nepal. Int Arch Otorhinolaryngol. 2015, 19:121-3. 10.1055/s-0034-1397336
2. Kendigelen P: The anaesthetic consideration of tracheobronchial foreign body aspiration in children . J Thorac Dis. 2016, 8:3803-7. 10.21037/jtd.2016.12.69
3. Fidkowski CW, Zheng H, Firth PG: The anesthetic considerations of tracheobronchial foreign bodies in children: a literature review of 12,979 cases. Anesth Analg. 2010, 111:1016-25. 10.1213/ANE.0b013e3181ef3e9c
4. George S, Wilson M, Humphreys S, Gibbons K, Long E, Schibler A: Apnoeic oxygenation during paediatric intubation: a systematic review. Front Pediatr. 2022, 10:918148. 10.3389/fped.2022.918148
5. Trachsel D, Erb TO, Hammer J, von Ungern-Sternberg BS: Developmental respiratory physiology. Paediatr Anaesth. 2022, 32:108-17. 10.1111/pan.14362
6. Bould MD: Essential notes: the anaesthetic management of an inhaled foreign body in a child . BJA Educ. 2019, 19:66-7. 10.1016/j.bjae.2019.01.005
7. Bhandari P, Kapoor R, Chaudhary S, Lakshmi R: Anesthesia for penetrating injury of the oropharynx in a child: a case report. Ain-Shams J Anesthesiol. 2023, 15:25. 10.1186/s42077-023-00325-7
8. Snyder AJ, McKay S, Mammen L, Reichert LK: Carotid-threatening penetrating oropharyngeal trauma in a pediatric patient: a case report and literature review. Cureus. 2024, 16:70170. 10.7759/cureus.70170
9. Edem BE, Adekwu A, Efu ME, Kuni J, Onuchukwu G, Ugwuadu J: Anesthetic and surgical management of

airway penetrating injuries in children in resource-poor setting: case reports. Int J Surg Case Rep. 2017, 39:119-22. 10.1016/j.ijscr.2017.07.047

10. Incollingo F, Shevchenko Y: Airway management in a child with penetrating pharyngeal wall foreign body injury: a case report. AANA J. 2007, 75:329-32.
11. Yang X, Xu Z, Du J, Li K, Yu J, Wu JB, Sun BZ: Penetrating injuries to the oropharyngeal cavity in children-a challenge to the anesthetist. Int J Clin Exp Med. 2018, 11:4290-4.
12. Black AE, Flynn PE, Smith HL, Thomas ML, Wilkinson KA: Development of a guideline for the management of the unanticipated difficult airway in pediatric practice. Paediatr Anaesth. 2015, 25:346-62. 10.1111/pan.12615
13. Paediatric difficult airway guidelines. (2026). Accessed: September 20, 2026: https://das.uk.com/guidelines/paediatric-difficult-airway-guidelines.
14. Fuchs A, Koepp G, Huber M, et al.: Apnoeic oxygenation during paediatric tracheal intubation: a systematic review and meta-analysis. Br J Anaesth. 2024, 132:392-406. 10.1016/j.bja.2023.10.039
15. Khemani RG, Randolph A, Markovitz B: Corticosteroids for the prevention and treatment of post-extubation stridor in neonates, children and adults. Cochrane Database Syst Rev. 2009, 2009:001000. 10.1002/14651858.CD001000.pub3
16. Dadure C, Sabourdin N, Veyckemans F, et al.: Management of the child's airway under anaesthesia: the French guidelines. Anaesth Crit Care Pain Med. 2019, 38:681-93. 10.1016/j.accpm.2019.02.004