Cureus
Part of SPRINGER NATURE

Open Access Case Report

Simultaneous Bilateral Hand-Assisted Laparoscopic Radical Nephrectomy for Synchronous Native-Kidney Renal Cell Carcinoma in a Renal Transplant Recipient: A Case Report

Review began 10/21/2026
Review ended 11/22/2026
Published 11/25/2026

© **Copyright** 2026
Kassim et al. This is an open access article distributed under the terms of the Creative Commons Attribution License CC-BY 4.0., which permits unrestricted use, distribution, and reproduction in any medium, provided the original author and source are credited.

DOI: 10.7759/cureus.120235

Abdirashid Hassan Kassim [1], Romina Vega Hermosillo [1], Amy Hodder [1], Precious Quaye [1], Anthony Blacker [1]

1. Urology, University Hospitals Coventry and Warwickshire NHS Trust, Coventry, GBR

Corresponding author: Abdirashid Hassan Kassim, abdi.kassim@uhcw.nhs.uk

Abstract

Renal transplant recipients have an increased risk of renal cell carcinoma (RCC), which most often arises in the native (non-transplanted) kidneys. Synchronous bilateral native-kidney tumours are uncommon, and tumours of different morphology and grade in each kidney have rarely been reported. A 56-year-old man with a functioning renal allograft presented with haematuria 16 years after transplantation. Computed tomography (CT) and magnetic resonance imaging (MRI) identified a 10.6 cm left lower-pole mass and two small upper-pole lesions in the right native kidney. Simultaneous bilateral hand-assisted laparoscopic (HAL) radical nephrectomies were performed in a single session through one midline hand-port incision. Histology showed a necrotic high-grade (International Society of Urological Pathology (ISUP) grade 3) carcinoma suspicious for papillary RCC in the left kidney and multifocal papillary RCC (ISUP grade 2) with multiple papillary adenomas in the right kidney. Blood loss was minimal, there was no acute kidney injury, and he was discharged on postoperative day two; CT at six months showed no recurrence or metastasis. Simultaneous bilateral HAL radical nephrectomy was feasible in this transplant recipient, although a single case with short follow-up cannot establish its safety. The different morphology and grade of the two tumours highlight the need for classification according to the 2022 World Health Organization (WHO) criteria and consideration of hereditary and end-stage kidney disease-related tumours. The late symptomatic presentation raises the question of whether selected long-term transplant recipients may benefit from imaging surveillance.

Categories: Urology, Transplantation, Nephrology
Keywords: bilateral nephrectomy, hand-assisted laparoscopy, kidney neoplasms, kidney transplant recipient, papillary renal cell carcinoma

Introduction

Renal cell carcinoma (RCC) is the most common type of kidney cancer and accounts for approximately 2%-3% of all adult cancers. Established risk factors include male sex, age 60-70 years, smoking, hypertension and obesity [1].

Kidney transplant recipients have an increased risk of RCC compared with the general population, and chronic immunosuppression is the principal proposed mechanism [2]. Most of these tumours arise in the native kidneys, the patient's own diseased kidneys, which are usually left in place at transplantation, rather than in the transplanted kidney (allograft) [2]. Synchronous bilateral tumours, meaning tumours present in both native kidneys at the same time, have been reported in only a small number of transplant recipients, occasionally with a different histological type in each kidney [3].

Papillary RCC (pRCC) is a subtype of RCC characterised by tumour cells arranged around fibrovascular cores. The 2022 WHO classification of urinary and male genital tumours, the current international standard for naming and classifying kidney tumours, no longer subdivides pRCC into type 1 and type 2 and recognises several molecularly defined entities that were previously grouped with it [4].

We describe a renal transplant recipient with synchronous bilateral native-kidney tumours who underwent simultaneous bilateral hand-assisted laparoscopic (HAL) radical nephrectomy, a minimally invasive technique in which the surgeon places one hand inside the abdomen through a sealed port to assist laparoscopic dissection. Both kidneys were removed in a single session through one midline hand-port incision. We report the operative technique in detail and discuss the pathological findings in the context of the 2022 WHO classification [4].

Case Presentation

A 56-year-old man with end-stage kidney disease of unknown aetiology and well-controlled hypertension underwent living-related renal transplantation 16 years before presentation, with the allograft placed in the

right iliac fossa. Maintenance immunosuppression consisted of tacrolimus (trough level 5.5 ng/mL at diagnosis), prednisolone 5 mg once daily and mycophenolate 750 mg twice daily. At presentation, serum creatinine was 122 µmol/L (estimated glomerular filtration rate (eGFR) 65 mL/min/1.73 m^2).

He was reviewed in the renal clinic after a single episode of visible haematuria one month earlier. Contrast-enhanced CT performed one month after presentation demonstrated a heterogeneous 10.6 cm left lower-pole renal mass without convincing internal enhancement. Two right upper-pole lesions measuring 1.5 and 1.2 cm showed borderline enhancement. There was no evidence of metastases, and the transplant kidney appeared normal. At this time, mycophenolate was discontinued after discussion of the risks of reducing immunosuppression, including graft rejection, and he continued on tacrolimus and prednisolone 5 mg once daily. Tacrolimus trough levels ranged from 3.1 to 5.4 ng/mL over the following months. The case was discussed at the multidisciplinary team (MDT) meeting two months after presentation.

MRI performed four months after presentation showed peripheral enhancement and haemorrhage in the left kidney lesion and enhancement in the right kidney lesions, measuring up to 1.4 cm, suspicious for neoplasm. The case was reviewed again at the Urology MDT meeting six months after presentation, which recommended bilateral native nephrectomy. Clinical staging (TNM 8th edition) was cT2b cN0 cM0 for the left kidney and cT1a cN0 cM0 for the right kidney (Figure *1*).

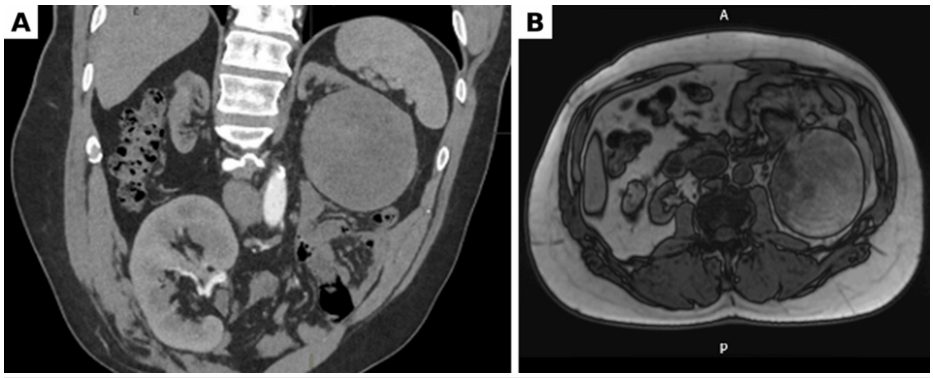

FIGURE 1: Preoperative imaging of the native kidneys.

(A, left) Coronal contrast-enhanced CT of the abdomen and pelvis demonstrating the 10.6 cm left lower-pole mass and the two small right upper-pole lesions with borderline enhancement. (B, right) Axial MRI of the abdomen at the level of the kidneys demonstrating the 1.4 cm enhancing right lesion and the 10.6 cm heterogeneous haemorrhagic left lesion with peripheral enhancement.

CT, computed tomography; MRI, magnetic resonance imaging

The patient requested that surgery be deferred because he would be away for an extended period. Restaging CT, including the thorax, eight months after presentation showed no interval change in the bilateral native renal lesions and no metastases, and surgery was performed 11 months after presentation.

Bilateral hand-assisted laparoscopic (HAL) radical nephrectomies were performed via a transperitoneal approach in a single session. With the patient in the full lateral position, left side up, a hand port (GelPort, Applied Medical, Rancho Santa Margarita, CA) was inserted through a 7 cm subumbilical midline incision, avoiding muscle division. A long 12 mm port was passed through the GelPort alongside the surgeon's arm, and a 12 mm camera port was placed in the midline above the umbilicus.

The left side was approached first. The colon was mobilised, the ureter was identified, and the lower pole of the kidney was mobilised. The renal pedicle was identified, and the renal artery and then the renal vein were each double-clipped with Hem-o-Lok clips (Teleflex, Wayne, PA) and divided. The kidney was then fully mobilised, the ureter was divided with a harmonic scalpel, and the adrenal gland was preserved. The specimen was placed in a retrieval bag and removed through the extended hand-port incision. The patient was then turned to the lateral position, right side up, and redraped, and the same ports were used. On the right side, the colon and ileum were mobilised, the ureter was identified, and the lower pole of the kidney was mobilised. The renal pedicle was identified, and the renal artery and vein were double-clipped and divided as on the left. The kidney was mobilised, the ureter was divided with a harmonic scalpel, the adrenal gland was left in situ, and the kidney was removed through the GelPort. Total operative time was three hours, estimated blood loss was 50 mL, intraoperative urine output was 700 mL, and there were no intraoperative complications. Routine closure was performed, and the skin was sealed with tissue adhesive (Figure *2*).

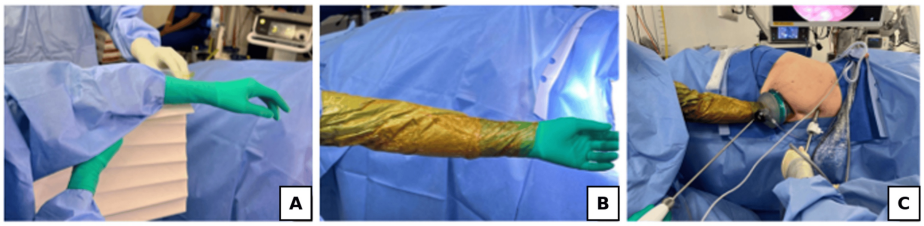

FIGURE 2: Port positioning and surgeon's arm preparation.

(A) Application of sterile adhesive film to the surgeon's arm, with a green glove, to reduce glare from the laparoscope light. (B) Final arm preparation before insertion through the GelPort (Applied Medical, Rancho Santa Margarita, CA). (C) Intraoperative view of the GelPort and laparoscopic ports.

Perioperative allograft function and haemoglobin are summarised in Table *1*. There was no acute kidney injury, and the patient was discharged on postoperative day 2.

Time point	Serum creatinine (µmol/L)	eGFR (mL/min/1.73 m²)	Haemoglobin (g/L)
At presentation	122	65	-
Preoperative	118	67	127
Postoperative day 1	116	63	131
Six months after surgery	131	51	-

TABLE 1: Allograft function and haemoglobin before and after surgery.

eGFR, estimated glomerular filtration rate; -, not available

Histopathological examination of the left kidney showed an extensively necrotic, high-grade carcinoma, International Society of Urological Pathology (ISUP) grade 3 [5], strongly suspicious for pRCC, staged pT2b, with multiple background tumours. In line with the 2022 WHO classification, which no longer subdivides pRCC into type 1 and type 2, the tumour was not further subtyped [4].

The right kidney showed multifocal pRCC, ISUP grade 2, with papillary and solid architecture. Tumour foci measured 1.7-2.2 cm and were staged pT1a. There was no tumour necrosis or invasion, and all margins were negative. Background changes included extreme diffuse thyroidisation with patchy inflammation and multiple papillary adenomas (Figure *3*).

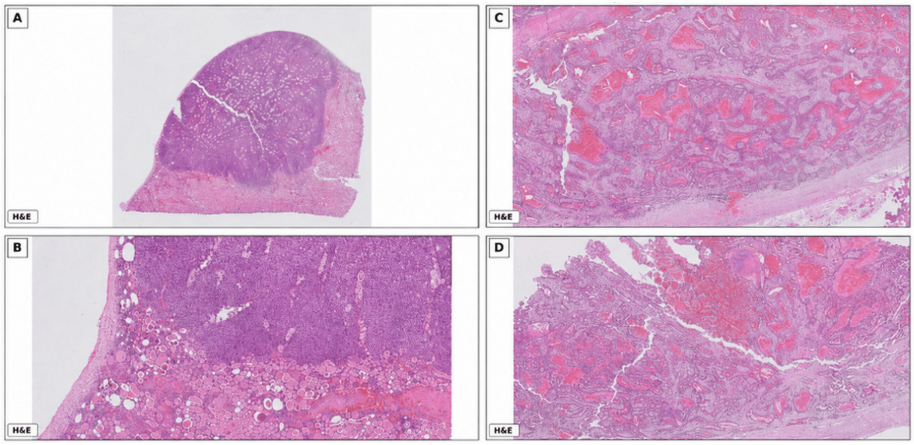

FIGURE 3: Histology micrographs of bilateral native kidney tumours.

(A) Right kidney pRCC, ISUP grade 2, showing the largest tumour focus. (B) Right kidney demonstrating tumour adjacent to the renal capsule and preserved non-neoplastic renal parenchyma. (C) Left kidney necrotic high-grade carcinoma suspicious for pRCC, ISUP grade 3, demonstrating tumour with extensive haemorrhagic and necrotic areas. (D) Additional left kidney section demonstrating tumour adjacent to the capsule with extensive necrosis and haemorrhage. All panels: haematoxylin and eosin (H&E) stain; digital whole-slide scans, approximate optical-equivalent magnification: (A) whole-slide overview (<×1), (B) ×4, (C) ×2, (D) ×2.

pRCC, papillary renal cell carcinoma; ISUP, International Society of Urological Pathology; H&E, haematoxylin and eosin

After surgery, mycophenolate was not reintroduced, and no other agents were added; he remains on tacrolimus 8 mg twice daily (trough level 5.7 ng/mL one month after surgery) and prednisolone 5 mg once daily. There have been no episodes of rejection. Genetic counselling and germline testing were not offered.

CT of the thorax, abdomen and pelvis six months after surgery showed no local recurrence or regional or distant metastases, and serum creatinine was 131 µmol/L (eGFR 51 mL/min/1.73 m²). As recommended by the MDT, he remains under routine surveillance in a nurse-led follow-up clinic, with imaging every 12 months. Written informed consent was obtained from the patient for publication of this case report and the accompanying clinical, operative, and histopathological images.

Discussion

Kidney cancer is the 14th most common type of cancer. Globally, in 2022, an estimated 434,840 new kidney cancer cases were diagnosed, with an age-standardised incidence rate of 4.4 per 100,000 population. In the UK, there are approximately 14,500 new kidney cancer cases each year [6,7].

The most common type of renal malignancy is RCC, representing over 90% of cases. RCC is sporadic (96%) or familial (4%) and is the most lethal urogenital cancer, with a mortality rate of 30-40%. Patients are typically aged 60-70 years, and RCC is more prevalent in men. The most common subtype is clear cell carcinoma, accounting for 70-80% of cases, followed by papillary RCC with 10-15% [8].

Half of patients are asymptomatic and are diagnosed incidentally through imaging. The triad of haematuria, flank pain and flank mass may indicate advanced disease and is not a typical presentation. The gold-standard imaging modality for the investigation and diagnosis of kidney tumours is renal characterisation [9]. It provides information on tumour extent, spread and identification of blood vessels, which are essential for clinical diagnosis and surgical planning [9].

Kidney transplant recipients have an increased risk of RCC, with approximately 90% of tumours found in native kidneys rather than the allograft. The histological distribution varies between cohorts, and pRCC has been reported more frequently than in the non-transplant population, representing 28-56% of RCC in some series [2].

Hereditary pRCC is rare (1:500,000), is most often associated with germline MET proto-oncogene mutations and typically presents with multiple, bilateral low-grade pRCC. In contrast, sporadic pRCC appears to be genetically heterogeneous. Recent molecular analyses have identified recurrent BRD4 alterations in subsets of non-hereditary pRCC, highlighting potential differences in tumour pathogenesis [10,11]. Multifocal pRCC with multiple papillary adenomas, as seen in the right kidney, is also a recognised finding in end-stage kidneys, and the 2022 WHO classification recognises several entities that were previously grouped as type 2 pRCC, including fumarate hydratase (FH)-deficient RCC, TFE3-rearranged RCC and acquired cystic disease-

associated RCC [4]. These entities are distinguished by immunohistochemical and molecular testing. In this patient, immunohistochemistry results were not available and genetic testing was not undertaken, so the left tumour could not be assigned definitively to a WHO 2022 subtype. The different morphology and grade of the two tumours may reflect independent tumour development, but a common hereditary or end-stage kidney disease-related process cannot be excluded.

In an analysis of Organ Procurement and Transplantation Network (OPTN) data on 215,928 kidney transplant recipients between 2004 and 2022, 839 (0.39%) developed de novo RCC [12]. In a single-centre cohort, Schmidt et al. reported an incidence of 0.64 per 1,000 person-years, with a standardised incidence ratio of 4.4 compared with the general population and 92% of tumours arising in native kidneys [13].

A 2010 study of the cancer registries in England, Wales and Scotland, including 37,617 transplant recipients from NHS Blood and Transplant data, found that renal malignancy was 7.9 times more common in kidney transplant recipients than in the general population, using a standardised incidence ratio. The registries did not distinguish between native and transplanted kidney malignancies [14].

The HAL approach allows tactile feedback of anatomical landmarks, immediate haemostatic control by digital pressure, better exposure and dissection of structures, maintenance of orientation and rapid kidney removal compared with other laparoscopic techniques [15].

Additionally, it has been favoured for the ease of managing adhesions, mobilisation of the renal hilum and reduced operative time compared with the purely laparoscopic approach for inflammatory renal disease [16]. Compared with the open approach, the HAL technique allows better visualisation for both the surgeon and assistant, and the higher intra-abdominal pressure reduces venous bleeding. It has been associated with reduced hospital stay, faster recovery and less postoperative pain, and, compared with the robotic approach, it has a shorter total operative time [17]. Yi et al. described single-session bilateral retroperitoneal laparoscopic nephrectomy for bilateral native-kidney RCC in a transplant recipient [3]. In the present case, a transperitoneal HAL approach allowed both kidneys to be mobilised and extracted through the same midline hand-port incision, with the patient repositioned between sides.

Management of immunosuppression is a central consideration in transplant recipients with malignancy. Reduction of overall immunosuppression and conversion to a mammalian target of rapamycin (mTOR) inhibitor, which has antiproliferative properties, are commonly considered, but must be balanced against the risk of allograft rejection [2]. In this patient, immunosuppression was reduced by withdrawing mycophenolate while continuing tacrolimus and prednisolone, and no rejection occurred; conversion to an mTOR inhibitor was not undertaken.

Risk factors for RCC after kidney transplantation include acquired cystic kidney disease and longer dialysis time before transplantation. At diagnosis, approximately 20-30% of patients have metastases, and 30-50% of patients with clinically localised disease progress to metastasis [1]. Transplant recipients may therefore benefit from screening with abdominal ultrasound or CT, aiming for earlier diagnosis and improved outcomes [18]. Singh-Singh et al. reported 23 years of ultrasound screening in 1,673 kidney transplant recipients, identifying RCC in 18 (1.08%), at a median of 89 months after transplantation [19].

Current British Transplantation Society and Renal Association guidance does not recommend routine RCC screening after renal transplantation [20]. This patient developed bilateral native-kidney RCC 16 years after transplantation and presented symptomatically with one lesion already exceeding 10 cm, which raises the question of whether selected high-risk transplant recipients may benefit from long-term imaging surveillance.

After nephrectomy for tumours at intermediate or high risk of recurrence, the EAU guideline recommends follow-up including cross-sectional imaging of the chest and abdomen, as the lungs are a common site of distant recurrence [9]. In this patient, surveillance included CT of the thorax, abdomen and pelvis at six months, and imaging is planned every 12 months. Whether more frequent imaging is warranted in immunosuppressed patients with high-grade tumours remains uncertain.

The 11-month interval between presentation and surgery, which resulted from the patient's request to defer surgery, carried a potential risk of tumour progression given the size and grade of the left tumour. Restaging CT before surgery showed no interval change or metastasis, and the tumours remained organ-confined at pathological staging.

This report has several limitations. It describes a single patient with short follow-up, so the safety and oncological outcomes of this approach cannot be generalised. Immunohistochemistry results, lymphovascular invasion and margin status for the left tumour, and the duration of dialysis before transplantation were not available. Genetic counselling and germline testing were not offered, so hereditary and molecularly defined RCC subtypes could not be excluded, and the original magnifications of the histology images could not be retrieved.

Conclusions

Simultaneous bilateral HAL radical nephrectomy through a single midline hand-port incision was feasible in this immunosuppressed patient with synchronous bilateral native-kidney tumours, with an estimated blood loss of 50 mL, no perioperative acute kidney injury and discharge on postoperative day two. As this is a single case with short follow-up, the safety and outcomes of this approach require confirmation in larger series. The different morphology and grade of the two tumours highlight the importance of classification according to the 2022 WHO criteria, and of considering hereditary and end-stage kidney disease-related tumours in transplant recipients with multifocal papillary lesions. The late symptomatic presentation after 16 years raises the question of whether selected long-term transplant recipients may benefit from imaging surveillance, which would need to be evaluated in larger studies.

Additional Information

Author Contributions

All authors have reviewed the final version to be published and agreed to be accountable for all aspects of the work.

Concept and design: Abdirashid Hassan Kassim, Romina Vega Hermosillo, Amy Hodder, Precious Quaye, Anthony Blacker

Acquisition, analysis, or interpretation of data: Abdirashid Hassan Kassim, Romina Vega Hermosillo, Amy Hodder, Precious Quaye, Anthony Blacker

Drafting of the manuscript: Abdirashid Hassan Kassim, Romina Vega Hermosillo, Amy Hodder, Precious Quaye, Anthony Blacker

Critical review of the manuscript for important intellectual content: Abdirashid Hassan Kassim, Romina Vega Hermosillo, Amy Hodder, Precious Quaye, Anthony Blacker

Supervision: Anthony Blacker

Disclosures

Human subjects: Informed consent for treatment and open access publication was obtained or waived by all participants in this study. **Conflicts of interest:** In compliance with the ICMJE uniform disclosure form, all authors declare the following: **Payment/services info:** All authors have declared that no financial support was received from any organization for the submitted work. **Financial relationships:** All authors have declared that they have no financial relationships at present or within the previous three years with any organizations that might have an interest in the submitted work. **Other relationships:** All authors have declared that there are no other relationships or activities that could appear to have influenced the submitted work.

References

1. Bahadoram S, Davoodi M, Hassanzadeh S, Bahadoram M, Barahman M, Mafakher L: Renal cell carcinoma: an overview of the epidemiology, diagnosis, and treatment. G Ital Nefrol. 2022, 39:2022-vol3.
2. Dahle DO, Skauby M, Langberg CW, Brabrand K, Wessel N, Midtvedt K: Renal cell carcinoma and kidney transplantation: a narrative review. Transplantation. 2022, 106:e52-63. 10.1097/TP.0000000000003762
3. Yi C, You X, Sha A, Zhang Z, Yu J, Guo X, Hu H: Renal cell carcinoma of different pathological types in bilateral native kidneys of a kidney transplant recipient: a case report and literature review. Front Oncol. 2022, 12:1112343. 10.3389/fonc.2022.1112343
4. Moch H, Amin MB, Berney DM, et al.: The 2022 World Health Organization classification of tumours of the urinary system and male genital organs-part A: renal, penile, and testicular tumours. Eur Urol. 2022, 82:458-68. 10.1016/j.eururo.2022.06.016
5. Delahunt B, Cheville JC, Martignoni G, et al.: The International Society of Urological Pathology (ISUP) grading system for renal cell carcinoma and other prognostic parameters. Am J Surg Pathol. 2013, 37:1490-504. 10.1097/PAS.0b013e318299f0fb
6. Kidney cancer statistics. (2026). Accessed: September 28, 2026: https://www.cancerresearchuk.org/health-professional/cancer-statistics/statistics-by-cancer-type/kidney-cancer.
7. Bray F, Laversanne M, Sung H, Ferlay J, Siegel RL, Soerjomataram I, Jemal A: Global cancer statistics 2022: GLOBOCAN estimates of incidence and mortality worldwide for 36 cancers in 185 countries. CA Cancer J Clin. 2024, 74:229-63. 10.3322/caac.21834
8. Pandey J, Syed W: Renal Cancer. StatPearls Publishing, Treasure Island, FL; 2024.
9. EAU guidelines on renal cell carcinoma. (2026). Accessed: October 21, 2026: https://d56bochluxqnz.cloudfront.net/documents/full-guideline/EAU-Guidelines-on-Renal-Cell-Carcinoma-2026.pdf.
10. Maher ER: Hereditary renal cell carcinoma syndromes: diagnosis, surveillance and management . World J Urol. 2018, 36:1891-8. 10.1007/s00345-018-2288-5
11. Eule CJ, Hu J, Davies KD, Jani A, Pshak T, Lam ET: Clinical features and mutational frequency of renal cell

carcinoma from patients undergoing kidney transplant evaluation. Front Oncol. 2025, 15:1526545. 10.3389/fonc.2025.1526545

12. Casey ME, Yanacek E, Kaul H, et al.: Association of acute rejection and de novo renal cell carcinoma in kidney transplant patients: an OPTN data analysis. Transplantology. 2024, 5:280-7. 10.3390/transplantology5040028
13. Schmidt J, Lehnert M, Lichy I, et al.: De novo renal cell carcinoma in kidney transplant recipients: incidence, outcomes, and therapeutic challenges. Cancers (Basel). 2025, 17:10.3390/cancers17132200
14. Collett D, Mumford L, Banner NR, Neuberger J, Watson C: Comparison of the incidence of malignancy in recipients of different types of organ: a UK Registry audit. Am J Transplant. 2010, 10:1889-96. 10.1111/j.1600-6143.2010.03181.x
15. Dols LF, Kok NF, Ijzermans JN: Live donor nephrectomy: a review of evidence for surgical techniques . Transpl Int. 2010, 23:121-30. 10.1111/j.1432-2277.2009.01027.x
16. Guo X, Wang H, Xiang Y, Jin X, Jiang S: Comparison of laparoscopic and hand-assisted laparoscopic nephrectomy for inflammatory renal disease: which is the preferred approach?. Ther Adv Urol. 2021, 13:1756287220984046. 10.1177/1756287220984046
17. Windisch OL, Matter M, Pascual M, Sun P, Benamran D, Bühler L, Iselin CE: Robotic versus hand-assisted laparoscopic living donor nephrectomy: comparison of two minimally invasive techniques in kidney transplantation. J Robot Surg. 2022, 16:1471-81. 10.1007/s11701-022-01393-x
18. Abbas M, Pätzel M, Thurn A, Brinkmann OA, Bettendorf O: Incidental occurrence of papillary renal cell carcinoma in the native kidney with autosomal dominant polycystic kidney disease after renal transplantation: a case report. Mol Clin Oncol. 2021, 15:223. 10.3892/mco.2021.2386
19. Singh-Singh A, Vigara LA, Aguilera A, et al.: Benefits of routine screening for renal cell carcinoma of native kidney in renal transplant recipients. Transplant Proc. 2023, 55:2262-5. 10.1016/j.transproceed.2023.09.010
20. Baker RJ, Mark PB, Patel RK, Stevens KK, Palmer N: Renal association clinical practice guideline in post-operative care in the kidney transplant recipient. BMC Nephrol. 2017, 18:174. 10.1186/s12882-017-0553-2