Cureus
Part of SPRINGER NATURE

Open Access Case Report

Traumatic Esophageal Rupture Following High-Velocity Blunt Thoracic Trauma in a Patient With Polytrauma: A Case Report of Diagnostic Challenges and Management

Bhathiya Nakandala [1], Anjana De Silva [1], Chathura Karunatileke [1]

1. Surgery, National Hospital of Sri Lanka, Colombo, LKA

Corresponding author: Bhathiya Nakandala, bhathiyaupendra1@gmail.com

Review began 11/08/2026
Review ended 11/25/2026
Published 11/26/2026

© **Copyright** 2026
Nakandala et al. This is an open access article distributed under the terms of the Creative Commons Attribution License CC-BY 4.0., which permits unrestricted use, distribution, and reproduction in any medium, provided the original author and source are credited.

DOI: 10.7759/cureus.120287

Abstract

Traumatic esophageal rupture following high-velocity blunt thoracic trauma is an uncommon and life-threatening condition. We report the case of a previously healthy 37-year-old man who sustained a distal esophageal rupture following a high-velocity motorcycle accident. The patient presented with multiple bilateral rib fractures and a C6-C7 unilateral facet fracture-dislocation resulting in complete paralysis below the C6 level. Due to profound neurological impairment, bradycardia, and hypotension, initial management focused on spinal stabilization and treatment of neurogenic shock. A focused assessment with sonography in trauma was negative, and an initial contrast-enhanced CT (CECT) scan on post-trauma day 2 failed to identify a visceral injury. However, on post-trauma day 3, drainage from a right-sided chest tube became bile-stained, prompting urgent upper gastrointestinal endoscopy that confirmed a longitudinal distal esophageal tear with established esophageal wall necrosis. Following initial stabilization through video-assisted thoracoscopic surgery and feeding jejunostomy, subsequent management with an esophageal stent resulted in an iatrogenic bronchoesophageal fistula involving the left main bronchus. Despite emergency surgical intervention, the patient died of refractory septic shock. This case underscores the diagnostic challenges of blunt esophageal trauma and the potential for catastrophic complications associated with esophageal stenting in necrotic tissue.

Categories: Trauma, Cardiac/Thoracic/Vascular Surgery, Gastroenterology
Keywords: blunt thoracic trauma, bronchoesophageal fistula, esophageal rupture, esophageal stenting, polytrauma management

Introduction

Esophageal rupture is a surgical emergency with a high mortality rate that increases significantly if the diagnosis is delayed beyond he first 24 hours after injury [1]. The reported mortality rate associated with esophageal perforation exceeds 20% [1]. While iatrogenic injury during endoscopic procedures is the most common cause of esophageal perforation, blunt traumatic rupture remains rare, reflecting a substantial transfer of kinetic energy [2]. The esophagus is shielded by the sternum, heart, and vertebral column, so a full-thickness tear usually requires a high-energy mechanism, such as a high-velocity motor vehicle collision or direct compression by large objects [2]. In patients with polytrauma, the diagnosis is particularly challenging. Patients often present with life-threatening distracting injuries, such as spinal cord injuries and severe chest injuries, which take precedence during the primary survey [3]. Because of the high-velocity nature of the trauma, esophageal rupture is often associated with aortic, tracheal, or cardiac injuries along with multiple rib fractures. An isolated esophageal rupture in this context is exceedingly rare. Furthermore, early contrast-enhanced CT (CECT) imaging, with or without oral contrast, has low sensitivity for detecting mucosal or full-thickness tears in the early post-trauma period, often leading to clinically significant diagnostic delays [4]. The subsequent development of chemical and bacterial mediastinitis results in rapid enzymatic digestion of the esophageal wall, making primary repair increasingly difficult after the first 24 to 48 hours. Successful management of traumatic esophageal rupture depends on maintaining a high index of clinical suspicion from the outset and promptly proceeding to definitive diagnostic modalities such as endoscopy or a Gastrografin swallow, followed by adequate surgical source control and repair [5]. Esophageal stenting has a limited role in traumatic esophageal injuries because of the risk of serious complications [6].

Case Presentation

A previously healthy 37-year-old man was admitted to the National Hospital of Sri Lanka following a high-velocity motorcycle accident. While riding as a motorcycle passenger, he was struck across the chest and abdomen by a fallen tree branch and subsequently thrown from the vehicle. On arrival, the patient was hypotensive, with a blood pressure of 83/44 mmHg and a pulse rate of 68 bpm. A focused assessment with sonography in trauma (FAST) scan performed during the primary survey was negative. Initial resuscitation achieved hemodynamic stability, but evaluation revealed multiple bilateral rib fractures and a left-sided

hemopneumothorax, managed with a chest tube. Neurological assessment revealed a Glasgow Coma Scale score of 15/15 and complete spinal cord injury at the C6 level, classified as American Spinal Injury Association Impairment Scale grade A. Sagittal CT imaging of the spine confirmed a C6-C7 unilateral facet fracture-dislocation (Figure *1*).



FIGURE 1: Sagittal CT of the cervical spine

Sagittal reconstruction showing a C6-C7 unilateral facet fracture-dislocation, which resulted in neurogenic shock and complete paralysis below the C6 level.

CT: computed tomography

Because of bradycardia and hypotension, the patient was diagnosed with neurogenic shock and started on norepinephrine before transfer to the intensive care unit. Although the spinal trauma team planned anterior cervical discectomy and fusion (ACDF) on post-trauma day 2, the patient developed acute respiratory distress and paralytic ileus, requiring intubation, and the ACDF procedure was postponed. Following intubation, a right-sided tension pneumothorax was identified on a chest radiograph (Figure *2*). It was managed with emergency needle decompression followed by chest tube insertion (Figure *3*).

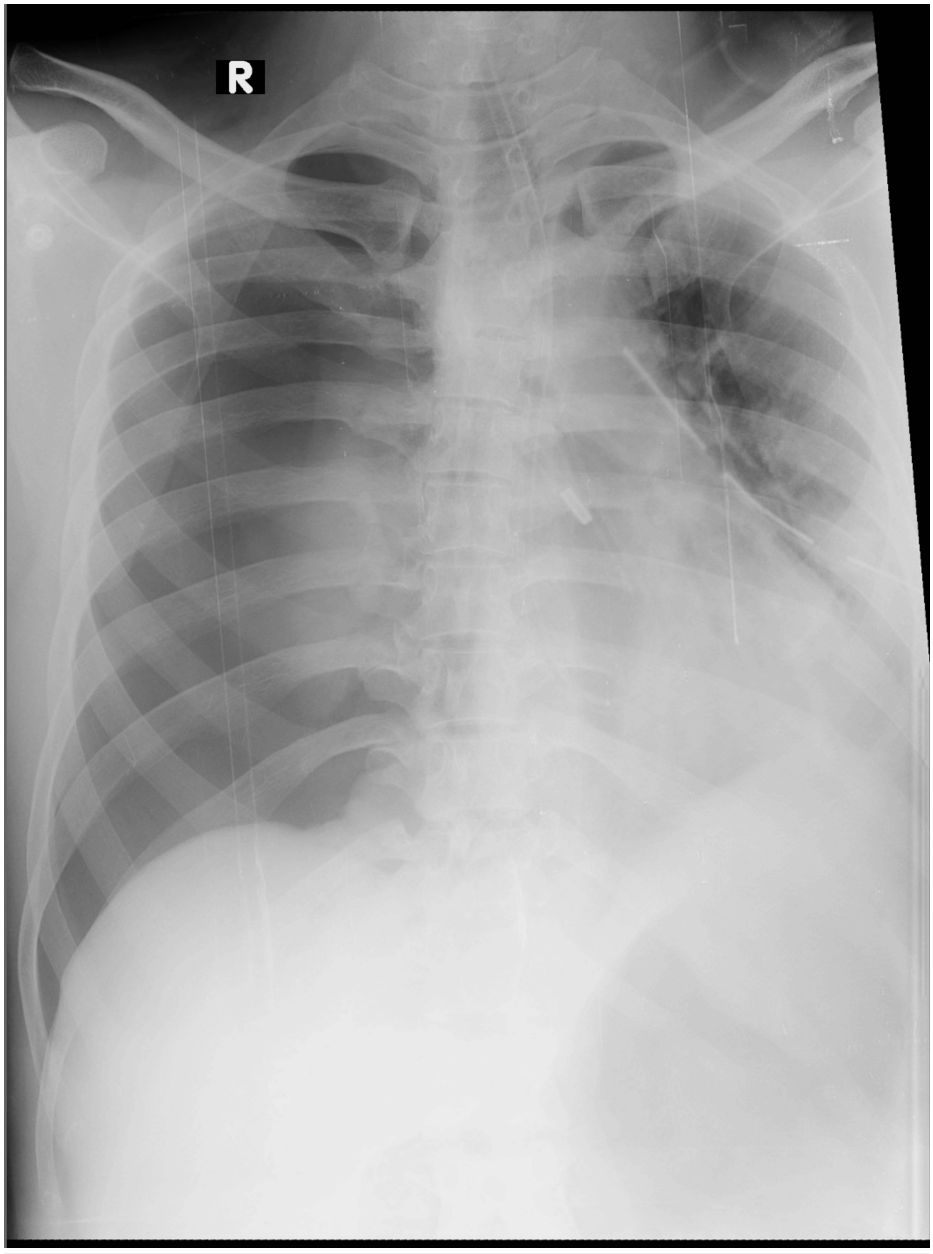

FIGURE 2: Initial chest radiograph showing right-sided tension pneumothorax

AP supine chest radiograph revealing a significant right-sided pneumothorax and bilateral rib fractures. A left-sided chest tube is visible from the resuscitation room.

AP: anteroposterior

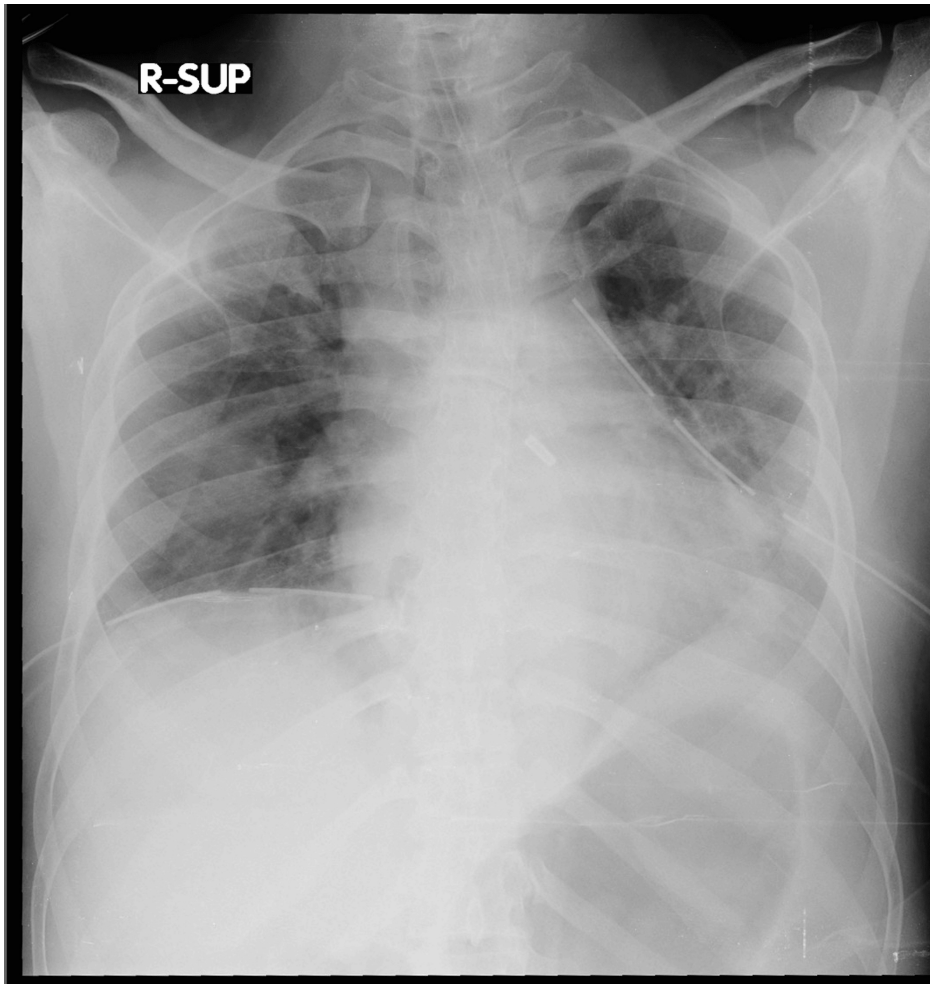

FIGURE 3: Post-intervention chest radiograph

AP chest radiograph after right-sided chest tube insertion for tension pneumothorax.

AP: anteroposterior

A CECT scan of the chest and abdomen without oral contrast performed on post-trauma day 2 did not indicate an esophageal injury or any other visceral injury. The scan also did not reveal pneumomediastinum or mediastinal inflammation. By post-trauma day 3, the drainage from the right chest tube became bile-stained, with an output of 1.5 L over 24 hours. This finding raised suspicion of an esophageal injury, prompting urgent upper gastrointestinal endoscopy, which revealed a 2-cm longitudinal tear with esophageal wall necrosis and inflammation in the distal esophagus approximately 35 cm from the incisors (Figure *4*).

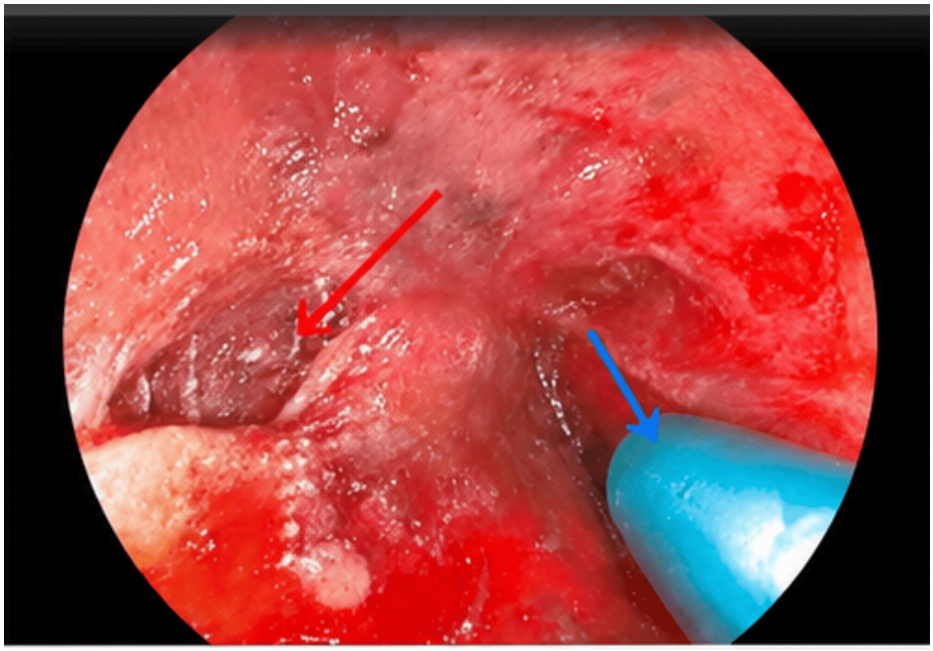

FIGURE 4: Diagnostic upper gastrointestinal endoscopy showing distal esophageal perforation

The red arrow shows part of the distal esophageal longitudinal tear. The blue arrow indicates that the nasogastric tube tip is lodged in a false tract in the posterior mediastinum.

The injury was characterized by established esophageal wall necrosis and severe inflammation, and the endoscope could not be advanced beyond the distal esophageal rupture site, as it entered a false tract within the mediastinum. Since the patient had severe mediastinitis, the thoracic surgical team was informed. Initial surgical stabilization was achieved via right-sided video-assisted thoracoscopic surgery (VATS) for mediastinal washout and lung decortication, with two chest tubes placed to ensure adequate drainage (Figure *5*).

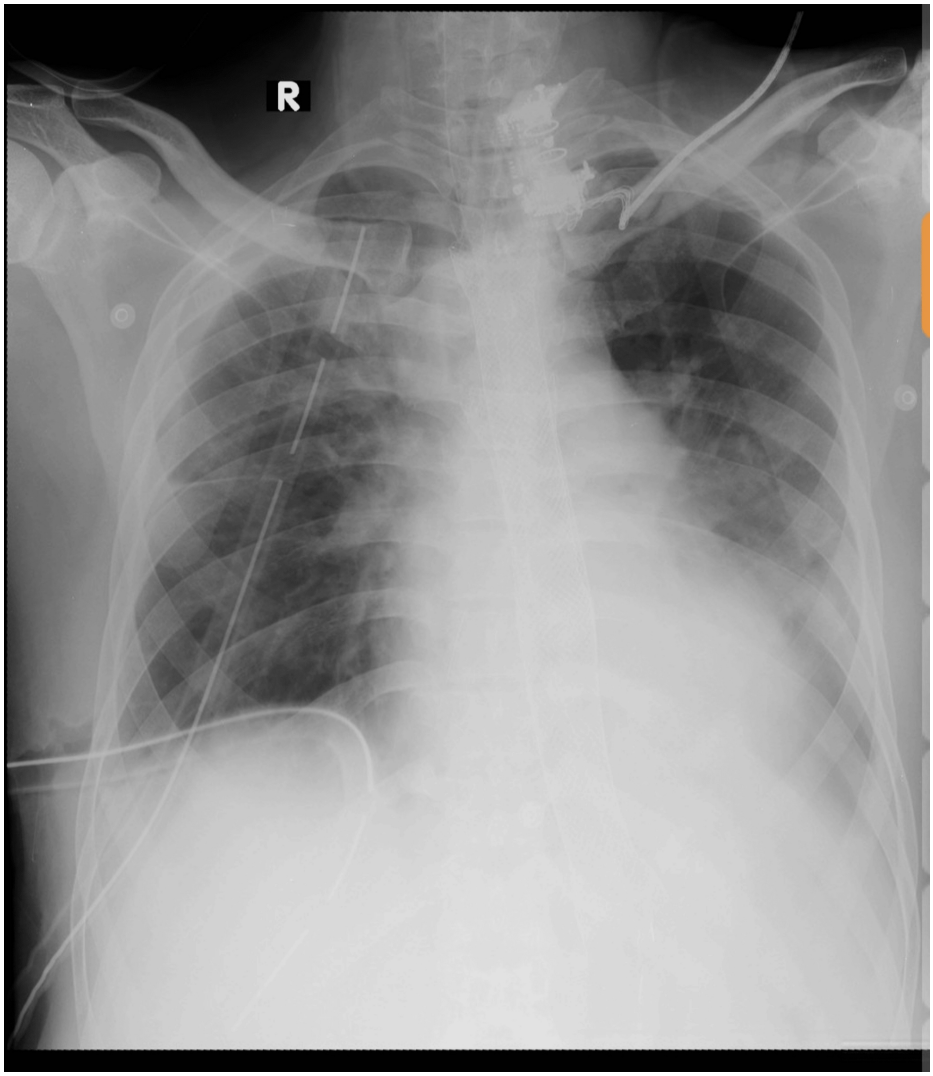

FIGURE 5: Post-VATS chest radiograph

AP chest radiograph taken after the initial VATS procedure, showing two chest tubes in situ on the right side for mediastinal and pleural drainage.

AP: anteroposterior, VATS: video-assisted thoracoscopic surgery

A feeding jejunostomy was also performed for nutritional support. The patient improved significantly after surgery, and the requirement for vasopressor support decreased. A multidisciplinary team meeting was convened because the patient required definitive treatment. Despite concerns about tissue viability and active mediastinitis, the multidisciplinary team ultimately decided to proceed with placement of a covered self-expanding metal esophageal stent with an antireflux mechanism on post-trauma day 9, as recommended by the gastrointestinal surgery team as the least invasive option. Following esophageal stenting, the patient's general condition did not improve as expected. Five days after stent insertion, the patient's condition rapidly deteriorated with fulminant sepsis. A repeat CECT scan was performed of the chest and abdomen with both intravenous and oral contrast on post-trauma day 16. The final CECT scan demonstrated erosion of the stent directly into the left main bronchus, confirming a bronchoesophageal fistula with severe mediastinitis (Figure *6*).

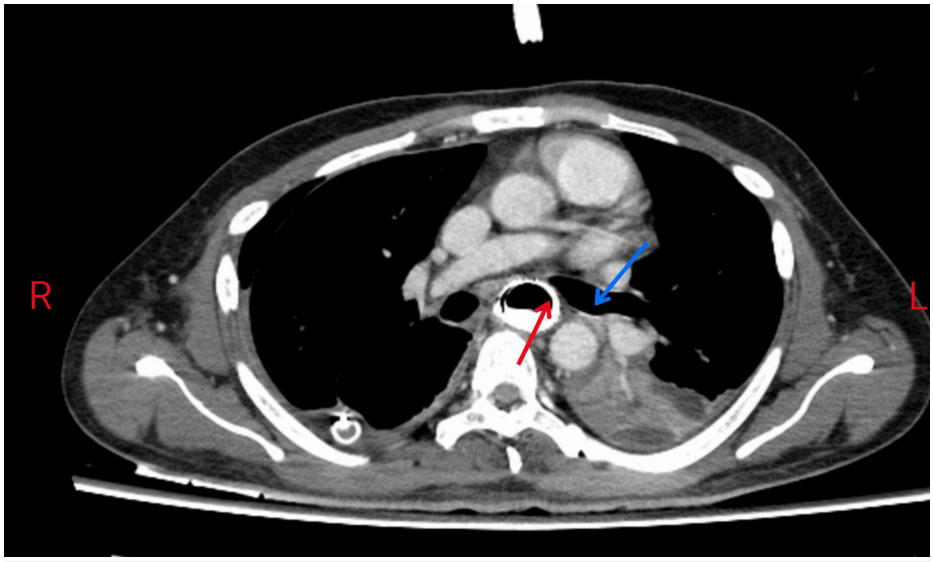

FIGURE 6: Final axial CECT Image taken on post-trauma day 16 (stent erosion indicating a bronchoesophageal fistula)

Final axial chest CECT image showing the esophageal stent (red arrow) eroding directly into the left main bronchus, with the left bronchial lumen indicated by the blue arrow.

CECT: contrast-enhanced computed tomography

An emergency right anterolateral thoracotomy was performed to remove the stent and repair the left main bronchus, but the patient died of refractory septic shock on post-trauma day 17.

Discussion

The management of esophageal rupture following blunt thoracic trauma represents one of the most significant challenges in thoracic surgery because of its high mortality rate, particularly when multisystem injuries are present [5]. This case illustrates three major clinical challenges in such scenarios: the masking effect of distracting injuries, the diagnostic limitations of current radiological imaging, and the risks associated with minimally invasive stenting in necrotic tissue. A major diagnostic challenge in this case was the presence of distracting injuries. The patient's C6-C7 unilateral facet fracture-dislocation and resultant neurogenic shock appropriately took priority during initial management. In polytrauma, visceral thoracic injuries are often "occult" during the primary survey, and even the CECT scan performed on post-trauma day 2 failed to identify a visceral injury [7]. Clinicians must remain vigilant for visceral injuries when the mechanism of injury involves a high-velocity impact. A retrospective review of the initial chest radiograph revealed that the nasogastric tube tip was positioned in the mid-esophagus. This case did not receive sufficient attention until subsequent endoscopy demonstrated its passage into a false tract within the mediastinum through the rupture site. This case highlights the importance of careful radiological assessment of nasogastric tube positioning and further investigation of unexplained tube malposition in patients with high-velocity blunt thoracic trauma. In this patient, the transition to bile-stained drainage in the chest tube on post-trauma day 3 was a clinical finding strongly suggestive of an upper gastrointestinal perforation that demanded immediate endoscopic verification [8].

High-velocity blunt trauma can result in significant transmural contusions and esophageal wall rupture. Esophageal rupture leads to extravasation of intraluminal contents, which in this case consisted of gastric fluid. The leaked contents then trigger a cascade of enzymatic and chemical digestion by gastric acid and bile, leading to rapid, full-thickness esophageal wall necrosis and inflammation of the surrounding mediastinal tissues [9]. By the time the diagnosis was confirmed on post-trauma day 3, the first 24 hours after injury for primary repair, typically considered the first 24 hours, had already passed. In this late phase, the esophageal wall becomes friable and loses the tensile strength required to hold surgical sutures or withstand the radial expansion of a stent. A major concern in this case was the placement of an endoscopic stent in the presence of necrotic and inflamed tissue. While covered self-expanding metal stents have improved the management of acute iatrogenic leaks, they require viable tissue for the safe application of radial pressure [10]. When a stent is deployed against necrotic and inflamed tissue, its constant radial force does not create a seal; instead, it causes pressure-induced ischemia and erosion, leading to further damage [11]. In this patient, the anatomical proximity of the left main bronchus may have contributed to stent erosion into the bronchus, resulting in a fatal iatrogenic bronchoesophageal fistula [12].

The surgical priority after delayed identification of esophageal rupture should be source control and esophageal diversion when the patient's clinical condition permits [5]. When the esophageal wall is compromised by frank necrosis, attempting a definitive minimally invasive intervention such as stenting may be inconsistent with fundamental surgical principles. The standard approach in a septic, unstable patient with established esophageal wall necrosis and mediastinitis involves wide surgical drainage to address chemical and bacterial contamination as a "bail-out" procedure, followed by cervical esophagostomy and distal stump closure, with gastrostomy or jejunostomy for feeding once the patient is stable enough [13]. This case highlights that, in the presence of esophageal wall necrosis and surrounding inflammation, radical surgical source control remains a priority until physiological stabilization is achieved [13].

Conclusions

Although esophageal rupture following blunt thoracic trauma is rare, it should be considered in patients who sustain high-velocity blunt thoracic trauma, particularly when unexplained pleural effusions or bile-stained drainage are present. A high index of clinical suspicion should be maintained despite initially negative imaging findings, including those from FAST. Early diagnosis significantly improves the likelihood of survival, as esophageal rupture carries a high mortality rate. In cases of delayed diagnosis, priority should be given to surgical source control and diversion. Most importantly, esophageal stenting should generally be avoided in the presence of established esophageal wall necrosis and gross mediastinal sepsis, because of the risk of potentially fatal complications, including fistula formation and injury to the airway or aorta.

Additional Information

Author Contributions

All authors have reviewed the final version to be published and agreed to be accountable for all aspects of the work.

Concept and design: Bhathiya Nakandala, Chathura Karunatileke, Anjana De Silva

Acquisition, analysis, or interpretation of data: Bhathiya Nakandala, Chathura Karunatileke, Anjana De Silva

Drafting of the manuscript: Bhathiya Nakandala, Chathura Karunatileke, Anjana De Silva

Critical review of the manuscript for important intellectual content: Bhathiya Nakandala, Chathura Karunatileke, Anjana De Silva

Supervision: Chathura Karunatileke

Disclosures

Human subjects: Informed consent for treatment and open access publication was obtained or waived by all participants in this study. **Conflicts of interest:** In compliance with the ICMJE uniform disclosure form, all authors declare the following: **Payment/services info:** All authors have declared that no financial support was received from any organization for the submitted work. **Financial relationships:** All authors have declared that they have no financial relationships at present or within the previous three years with any organizations that might have an interest in the submitted work. **Other relationships:** All authors have declared that there are no other relationships or activities that could appear to have influenced the submitted work.

References

1. Søreide JA, Viste A: Esophageal perforation: diagnostic work-up and clinical decision-making in the first 24 hours. Scand J Trauma Resusc Emerg Med. 2011, 19:66. 10.1186/1757-7241-19-66
2. Bryant AS, Cerfolio RJ: Esophageal trauma. Thorac Surg Clin. 2007, 17:63-72. 10.1016/j.thorsurg.2007.02.003
3. Oray NC, Sivrikaya S, Bayram B, Egeli T, Dicle O: Blunt trauma patient with esophageal perforation . West J Emerg Med. 2014, 15:659-62. 10.5811/westjem.2013.12.20792
4. Currie S, Menias CO, Mellnick V: Imaging of esophageal emergencies. Appl Radiol. 2016, 45:16-22. 10.37549/AR2313
5. Kaman L, Iqbal J, Kundil B, Kochhar R: Management of esophageal perforation in adults . Gastroenterology Res. 2010, 3:235-44. 10.4021/gr263w
6. Sudarshan M, Cassivi SD: Management of traumatic esophageal injuries . J Thorac Dis. 2019, 11:172-6. 10.21037/jtd.2018.10.86
7. Kumar S, Kaur M, Saurabh A, Srivastava NK, Kushwaha P: Delayed life-threatening hemothorax following blunt thoracic trauma: a rare and catastrophic evolution in a polytrauma patient. Trauma Case Rep. 2025, 60:101290. 10.1016/j.tcr.2025.101290
8. Demetriou GA, Nair MS: Biliary contents in the chest drain tube: a finding not to ignore . BMJ Case Rep. 2013, 2013:2013009849. 10.1136/bcr-2013-009849
9. Kakar N, Smith HC, Shadid AM: Prolonged emesis causing esophageal perforation: a case report . Cureus.

2022, 14:24720. 10.7759/cureus.24720

10. Maselli DB, Storm AC, Matar R, Abu Dayyeh BK: Improving stent efficiency by understanding stent-related adverse events. Tech Innov Gastrointest Endosc. 2020, 22:232-8. 10.1016/j.tige.2020.03.002
11. Wilson JL, Louie BE, Farivar AS, Vallières E, Aye RW: Fully covered self-expanding metal stents are effective for benign esophagogastric disruptions and strictures. J Gastrointest Surg. 2013, 17:2045-50. 10.1007/s11605-013-2357-4
12. Hirdes MM, Vleggaar FP, Van der Linde K, Willems M, Totté ER, Siersema PD: Esophageal perforation due to removal of partially covered self-expanding metal stents placed for a benign perforation or leak. Endoscopy. 2011, 43:156-9. 10.1055/s-0030-1255849
13. Chen FH, Han B, Wei YC, et al.: Case report: two-stage surgical management of spontaneous oesophageal rupture with extensive necrosis. Front Med (Lausanne). 2026, 13:1902558. 10.3389/fmed.2026.1902558