Cureus
Part of SPRINGER NATURE

Open Access Case Report

An Unusual Bilateral Presentation of Morphea En Coup De Sabre

Ghita Gmira [1], Hanane Baybay [1], Aimane Zaim [1], Fatima Zahra Mernissi [1]

1. Department of Dermatology, Hassan II University Hospital, Fez, MAR

Corresponding author: Ghita Gmira, ghita.gmira@gmail.com

Review began 11/12/2026
Review ended 11/19/2026
Published 11/23/2026

© **Copyright** 2026
Gmira et al. This is an open access article distributed under the terms of the Creative Commons Attribution License CC-BY 4.0., which permits unrestricted use, distribution, and reproduction in any medium, provided the original author and source are credited.

DOI: 10.7759/cureus.120134

Abstract

Morphea en coup de sabre is a rare subtype of linear morphea that typically affects the frontoparietal region and is almost always unilateral, with bilateral involvement being exceptionally rare. We report the case of a 14-year-old girl who presented with an eight-year history of bilateral indurated temporal plaques associated with localized alopecia of the scalp, eyebrows, and eyelashes. Clinical, neurological, and ophthalmological examinations were normal, as were laboratory and imaging investigations. The patient was treated with monthly intravenous corticosteroid pulses combined with weekly methotrexate, resulting in significant clinical improvement with softening of the lesions. This case highlights the exceptional bilateral presentation of morphea en coup de sabre and underscores the importance of early recognition, appropriate systemic therapy, and long-term follow-up to prevent disease progression and potential sequelae.

Categories: Radiology, Pathology, Dermatology
Keywords: bilateral involvement, corticosteroids, en coup de sabre, localized scleroderma, methotrexate, morphea

Introduction

Linear morphea is a form of localized scleroderma that accounts for approximately 15-20% of adult cases and 42-67% of childhood cases of morphea [1]. Morphea en coup de sabre is an uncommon subtype of localized linear scleroderma. It refers to a linear morphea lesion typically located on the frontoparietal scalp and/or paramedian forehead, often resembling a strike with a sword. It generally begins during the first decade of life, mainly in women, and follows a slow but progressive course. It is almost always unilateral, with very few cases of bilateral morphea en coup de sabre reported in the literature. Here, we report a case of bilateral morphea en coup de sabre given its exceptional presentation.

This article was previously presented as an abstract at the 2026 European Academy of Dermatology and Venereology (EADV) Congress in Vienna, Austria, from September 30 to October 3, 2026.

Case Presentation

A 14-year-old adolescent girl, followed for thyroiditis since a young age and currently receiving no treatment, presented with indurated plaques in the bilateral temporal regions that had been present for eight years. There was no family history of a similar condition.

Clinical examination revealed two well-defined, flesh-colored sclerotic plaques with irregular contours and overlying telangiectasias, extending from the external edges of both eyes at the temporal level bilaterally to the frontal margin. The lesions were associated with alopecia of the scalp, the tail of the right eyebrow, and the external portions of the eyelashes of both eyes (Figure *1*). The perilesional skin was normal. The underlying cortical bones appeared normal, with no associated facial asymmetry.

How to cite this article
Gmira G, Baybay H, Zaim A, et al. (November 23, 2026) An Unusual Bilateral Presentation of Morphea En Coup De Sabre. Cureus 18(11): e120134. DOI 10.7759/cureus.120134

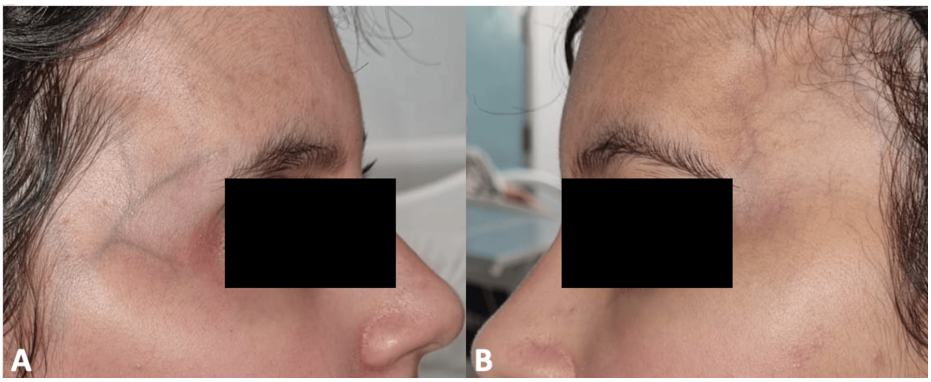

FIGURE 1: Clinical image

(A-B) Profile photographs showing bilateral frontoparietal morphea with associated depression and eyebrow alopecia.

Brain magnetic resonance imaging (MRI), including post-contrast T1-weighted and coronal T2-weighted sequences, showed bilateral frontal atrophy of the cutaneous and subcutaneous soft tissues of the scalp, without pathological contrast enhancement or underlying osseous involvement (Figure *2*).

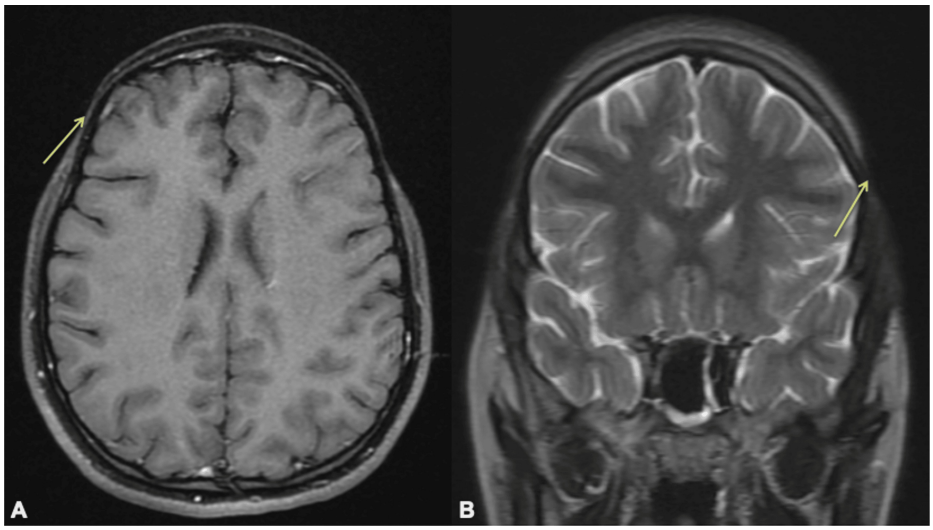

FIGURE 2: Brain magnetic resonance imaging

Post-contrast T1-weighted (A) and coronal T2-weighted (B) sequences showing bilateral frontal atrophy of the cutaneous and subcutaneous soft tissues of the scalp, without pathological contrast enhancement or underlying osseous involvement.

The remainder of the dermatological examination was unremarkable. Neurological and ophthalmological examinations were also normal. The pretherapeutic assessment was normal.

The patient was treated with intravenous methylprednisolone pulses at a dose of 1 g administered on three consecutive days each month for six months, in combination with methotrexate at a dose of 0.3 mg/kg/week. The patient showed moderate clinical improvement after nine months of treatment, with slight softening of the affected skin. The bilateral eyebrow alopecia persisted, and the patient used cosmetic camouflage methods to conceal the eyebrow hair loss (Figure *3*).

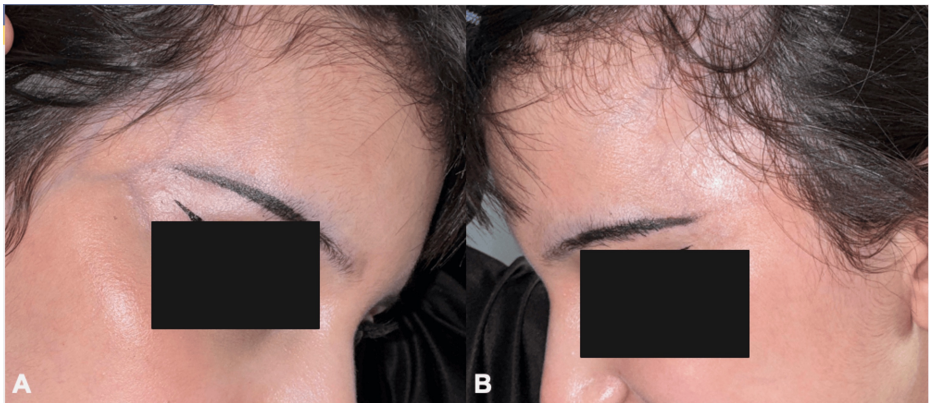

FIGURE 3: Clinical image

(A-B) Profile photographs after nine months of treatment showing slight improvement in skin softness, with persistent bilateral eyebrow alopecia partially concealed by cosmetic camouflage.

Discussion

Morphea en coup de sabre usually begins in childhood and typically involves the paramedian frontoparietal region in a Blaschkoid distribution. Although its exact etiology remains unclear, several triggering factors have been identified in susceptible individuals, including trauma, injections, and mechanical compression [2].

Morphea en coup de sabre is a rare entity, with only a few cases reported in the literature. Bilateral involvement is even rarer. In a retrospective study involving 54 patients, only four cases showed bilateral involvement [3]. When combined with eight additional isolated cases reported in the literature [4,5], a total of 12 cases of bilateral morphea en coup de sabre have been documented.

Some children with typical morphea en coup de sabre may progress to Parry-Romberg syndrome after several years. Therefore, prolonged follow-up is essential, as it may be difficult to distinguish involuted morphea en coup de sabre from Parry-Romberg syndrome. This observation suggests that both conditions may represent different manifestations within the same disease spectrum.

Children and adolescents with morphea and scleroderma, in their various forms, generally have a better prognosis compared with adult patients.

Various therapeutic modalities have been proposed for the management of bilateral morphea en coup de sabre, including topical tacrolimus, phototherapy, calcipotriol combined with betamethasone dipropionate, imiquimod, methotrexate combined with systemic corticosteroids, photopheresis, and D-penicillamine [6]. Among these treatments, methotrexate combined with oral or pulse corticosteroids has shown the best clinical outcomes, although this regimen is associated with a higher incidence of adverse effects. Antimalarial drugs, such as chloroquine, have also been used with favorable results and a more acceptable side-effect profile.

Conclusions

Bilateral morphea en coup de sabre is an exceptionally rare presentation of localized scleroderma. Our case highlights the unusual bilateral distribution, the absence of neurological and ophthalmological involvement despite long-standing disease, and the favorable response to combined methotrexate and corticosteroid pulse therapy. Early recognition and appropriate systemic treatment are important to limit disease progression and potential sequelae. Long-term follow-up remains essential given the possible evolution of morphea en coup de sabre and its relationship with Parry-Romberg syndrome.

Additional Information

Author Contributions

All authors have reviewed the final version to be published and agreed to be accountable for all aspects of the work.

Concept and design: Ghita Gmira, Aimane Zaim

Acquisition, analysis, or interpretation of data: Ghita Gmira, Hanane Baybay, Fatima Zahra Mernissi,

Aimane Zaim

Drafting of the manuscript: Ghita Gmira, Hanane Baybay, Fatima Zahra Mernissi, Aimane Zaim

Critical review of the manuscript for important intellectual content: Ghita Gmira, Hanane Baybay, Fatima Zahra Mernissi, Aimane Zaim

Supervision: Hanane Baybay, Fatima Zahra Mernissi

Disclosures

Human subjects: Informed consent for treatment and open access publication was obtained or waived by all participants in this study. **Conflicts of interest:** In compliance with the ICMJE uniform disclosure form, all authors declare the following: **Payment/services info:** All authors have declared that no financial support was received from any organization for the submitted work. **Financial relationships:** All authors have declared that they have no financial relationships at present or within the previous three years with any organizations that might have an interest in the submitted work. **Other relationships:** All authors have declared that there are no other relationships or activities that could appear to have influenced the submitted work.

References

1. Zulian F, Athreya BH, Laxer R, et al.: Juvenile localized scleroderma: clinical and epidemiological features in 750 children. An international study. Rheumatology (Oxford). 2006, 45:614-20. 10.1093/rheumatology/kei251
2. Amaral TN, Peres FA, Lapa AT, Marques-Neto JF, Appenzeller S: Neurologic involvement in scleroderma: a systematic review. Semin Arthritis Rheum. 2013, 43:335-47. 10.1016/j.semarthrit.2013.05.002
3. Tollefson MM, Witman PM: En coup de sabre morphea and Parry-Romberg syndrome: a retrospective review of 54 patients. J Am Acad Dermatol. 2007, 56:257-63. 10.1016/j.jaad.2006.10.959
4. Rai R, Handa S, Gupta S, Kumar B: Bilateral en coup de sabre-a rare entity . Pediatr Dermatol. 2000, 17:222-4. 10.1046/j.1525-1470.2000.01757.x
5. Gambichler T, Kreuter A, Hoffmann K, Bechara FG, Altmeyer P, Jansen T: Bilateral linear scleroderma "en coup de sabre" associated with facial atrophy and neurological complications. BMC Dermatol. 2001, 1:9. 10.1186/1471-5945-1-9
6. Fett N, Werth VP: Update on morphea: part II. Outcome measures and treatment . J Am Acad Dermatol. 2011, 64:231-42; quiz 243-4. 10.1016/j.jaad.2010.05.046