Cureus
Part of SPRINGER NATURE

Open Access Case Report

Coexistence of Appendiceal Diverticulitis and Appendiceal Neuroma Incidentally Diagnosed After Laparoscopic Appendectomy for Presumed Uncomplicated Acute Appendicitis: A Case Report

Review began 10/08/2026
Review ended 11/15/2026
Published 11/25/2026

© Copyright 2026
Escandón Villalobos et al. This is an open access article distributed under the terms of the Creative Commons Attribution License CC-BY 4.0., which permits unrestricted use, distribution, and reproduction in any medium, provided the original author and source are credited.

DOI: 10.7759/cureus.120266

Edson A. Escandón Villalobos [1], María F. Ramos Griera [1], Viana Guerrero-Elías [2], Jorge Leal Hidalgo [3], Diego M. García Vivanco [1]

1. General Surgery, Hospital Médica Sur, Mexico City, MEX 2. Pathology, Hospital Médica Sur, Mexico City, MEX 3. Surgery, Hospital Médica Sur, Mexico City, MEX

Corresponding author: Diego M. García Vivanco, diegogviva@gmail.com

Abstract

Appendiceal diverticular disease is uncommon, frequently mimics acute appendicitis, and is often diagnosed only after histopathological examination. Its recognition is clinically relevant because it has been associated with a higher risk of perforation and appendiceal neoplasia. Appendiceal neuroma is another rare benign histopathological finding that is usually identified incidentally. A 60-year-old man presented with acute epigastric pain, dyspepsia, and nausea without vomiting. Laboratory studies showed leukocytosis with neutrophilia. Abdominal computed tomography was performed, and acute appendicitis was demonstrated. Laparoscopic appendectomy was performed, and the postoperative course was uneventful. Gross and histopathological examination showed appendiceal diverticula associated with appendiceal neuroma. These lesions were unsuspected before surgery and could not be distinguished from uncomplicated appendicitis by the nonspecific clinical and imaging findings. This case supports routine histopathological examination of appendectomy specimens while recognizing that a single observation cannot establish causality or a universal surveillance strategy.

Categories: General Surgery, Pathology, Gastroenterology
Keywords: acute appendicitis, appendiceal diverticulitis, appendiceal diverticulosis, appendiceal neuroma, case report, histopathology

Introduction

Acute appendicitis is a common indication for emergency abdominal surgery, but uncommon appendiceal lesions may produce the same clinical and radiological picture. Appendiceal diverticular disease has been reported in approximately 1.7%-2.3% of appendectomy specimens [1,2]. Most lesions are acquired pseudodiverticula, in which the mucosa and submucosa protrude through defects in the muscularis propria, the smooth-muscle layer of the appendiceal wall [2,3]. Before surgery, appendiceal diverticulitis is often indistinguishable from conventional acute appendicitis [1,2].

Appendiceal diverticulitis is clinically relevant because acquired pseudodiverticula lack a complete muscular wall and have been associated with higher perforation rates [1,2]. Appendiceal diverticulosis has also been associated with appendiceal neoplasia, supporting careful histopathological examination of the specimen [3].

Appendiceal neuroma is a benign proliferation of nerve fibers and Schwann cells, the supporting cells of peripheral nerves [4,5]. It may cause or mimic symptoms of acute appendicitis and is usually diagnosed microscopically. It should be distinguished from an appendiceal neuroendocrine tumor, a true neoplasm whose management may depend on tumor size, margin status, mesoappendiceal invasion, lymphovascular invasion, and other risk features [6,7]. Low-grade appendiceal mucinous neoplasm (LAMN) is a mucin-producing epithelial tumor of the appendix that may also distort the appendiceal wall and enter the pathological differential diagnosis [8].

The coexistence of appendiceal diverticular disease and neuromatous proliferation has been described mainly in histopathological studies. Lowes et al. reported an association between mucosal neuromatous changes and complicated appendiceal diverticular disease [8]. However, lesions described as appendiceal neuroma may involve different anatomic compartments, and histopathological equivalence should be based on the documented location and morphology rather than terminology alone. The clinical presentation and practical significance of this coexistence remain incompletely characterized.

This case report was prepared in accordance with the Surgical CAse REport (SCARE) 2025 checklist [9]. The objective of this report is to describe the incidental coexistence of appendiceal diverticulitis and appendiceal

neuroma after laparoscopic appendectomy for presumed uncomplicated acute appendicitis and to correlate the nonspecific clinical and imaging findings with the final histopathological diagnosis.

Case Presentation

Patient information and clinical findings

A 60-year-old man presented to the emergency department with acute epigastric pain, dyspepsia, and nausea without vomiting. His history included conservatively managed Hinchey I diverticulitis and prior symptoms suggestive of acid-peptic disease. He reported an iodine allergy and denied recent antibiotic use, hospitalizations, transfusions, or other relevant surgical history.

The patient's main concern was acute abdominal pain that had not improved despite the use of a proton-pump inhibitor. Because the pain was epigastric and associated with dyspeptic symptoms, an upper gastrointestinal cause was initially considered. The leukocytosis with neutrophilia prompted further imaging evaluation.

On admission, the patient was alert, oriented, cooperative, and adequately hydrated. His blood pressure was 175/88 mmHg, heart rate was 88 beats/min, respiratory rate was 16 breaths/min, oxygen saturation was 95% on room air, and temperature was 36.3°C. Abdominal examination showed a soft, depressible abdomen without clear peritoneal irritation. Initial laboratory findings showed mild leukocytosis with neutrophilia and lymphopenia, with creatinine and electrolyte levels within the reference ranges shown in Table *1*.

Parameter	Patient result	Adult reference range
Hemoglobin (g/dL)	14.4	13-18
Hematocrit (%)	43.2	40-55
Platelets (×10⁹/L)	214	150-400
Leukocytes (×10⁹/L)	11.68	4.5-11.0
Absolute neutrophil count (×10⁹/L)	10.0	1.5-7.5
Absolute lymphocyte count (×10⁹/L)	0.9	1.0-4.8
Creatinine (mg/dL)	0.95	0.7-1.3
Sodium (mmol/L)	136	135-145
Potassium (mmol/L)	4.0	3.7-5.2

TABLE 1: Relevant laboratory findings on admission.

Adult reference ranges may vary by laboratory.

Diagnostic assessment

Because the patient reported an iodine allergy, computed tomography was performed without intravenous contrast. Non-contrast abdominal computed tomography demonstrated an infraileal vermiform appendix arising from the cecum, approximately 9 cm in length, with intraluminal fluid, wall thickening up to 0.45 cm, a total diameter of 1.5 cm, and periappendiceal fat stranding. There was no appendicolith, inflammatory phlegmon, free intraperitoneal fluid, or pneumoperitoneum. The radiological impression was uncomplicated acute appendicitis (Figure *1*).



FIGURE 1: Non-contrast axial abdominal computed tomography.

Abdominal CT scan showing an enlarged infraileal appendix with wall thickening and periappendiceal fat stranding, consistent with uncomplicated acute appendicitis. No appendicolith, inflammatory phlegmon, free intraperitoneal fluid, or pneumoperitoneum was identified.

Intervention

The patient was admitted for surgical management. Management included intravenous fluids, analgesia, antiemetic therapy, proton-pump inhibitor therapy, and antibiotic coverage with ceftriaxone 1 g intravenously as a single dose and metronidazole 500 mg intravenously as a single dose. Given the clinical and radiological findings of acute appendicitis, laparoscopic appendectomy was performed under general anesthesia on day 2.

Intraoperatively, the appendix showed findings consistent with phase II acute appendicitis, with fibrinopurulent exudate and inflammatory fluid in the abdominal cavity. The mesoappendix and appendiceal base were managed laparoscopically, and the appendix was resected using an endoscopic stapler. The inflammatory fluid was aspirated. No abdominal drains were placed. No intraoperative complications or deviations from the planned laparoscopic approach were reported. Estimated blood loss was 15 mL, anesthetic time was 1 hour 15 minutes, and operative time was 50 minutes.

Postoperative instructions included progressive oral intake according to tolerance, pain control, wound care, early ambulation, and outpatient follow-up. The patient received postoperative analgesia and progressed without clinical evidence of an immediate postoperative complication.

Histopathological findings

The surgical specimen measured 9.5 × 1.2 cm. The serosal surface was gray, dull, and irregular, with adherent fibrinopurulent plaques and prominent vascularity. Gross examination revealed five sac-like outpouchings of the appendiceal wall, consistent with diverticula, distributed along the distal half of the appendix, from the middle third to the appendiceal tip. There was no gross evidence of perforation (Figure *2A*). Histological examination confirmed five appendiceal diverticula without perforation (Figure *2B*).

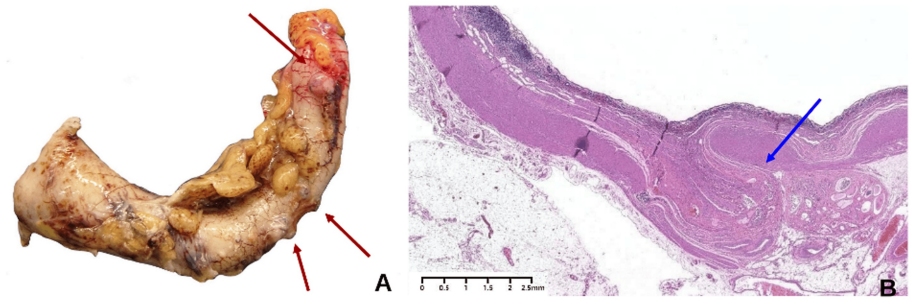

FIGURE 2: Gross and histopathological features of appendiceal diverticula.

(A) Gross photograph of the appendectomy specimen showing five sac-like outpouchings of the appendiceal wall extending toward the serosal surface (red arrows), distributed from the middle third to the appendiceal tip. (B) H&E photomicrograph showing an appendiceal diverticulum (blue arrow), with no histological evidence of perforation (×10 objective).

Gross examination showed a cross-section from the middle third corresponding to the site of the appendiceal neuroma (Figure *3A*). Hematoxylin and eosin (H&E)-stained sections revealed a benign neural proliferation in the middle third of the appendix, confined to the submucosa and associated with partial obliteration of the appendiceal lumen, without mucosal involvement. The lesion was composed of spindle-shaped cells with elongated, cytologically bland nuclei arranged within a fibrous stroma and admixed with variable amounts of adipose tissue and chronic inflammatory infiltrates. No cytological atypia, increased mitotic activity, or destructive infiltrative growth pattern was identified. These morphological findings were consistent with appendiceal neuroma (Figure *3B*, *3C*). The diagnosis was established on the characteristic H&E morphology, and immunohistochemical studies were not required. No morphological features of a neuroendocrine neoplasm or an epithelial mucinous neoplasm, including LAMN, were identified. The proximal resection margin and mesoappendix were free of neuromatous proliferation. The integrated final diagnosis remained ulcerated acute appendicitis, appendiceal diverticulosis with diverticulitis, and appendiceal neuroma.

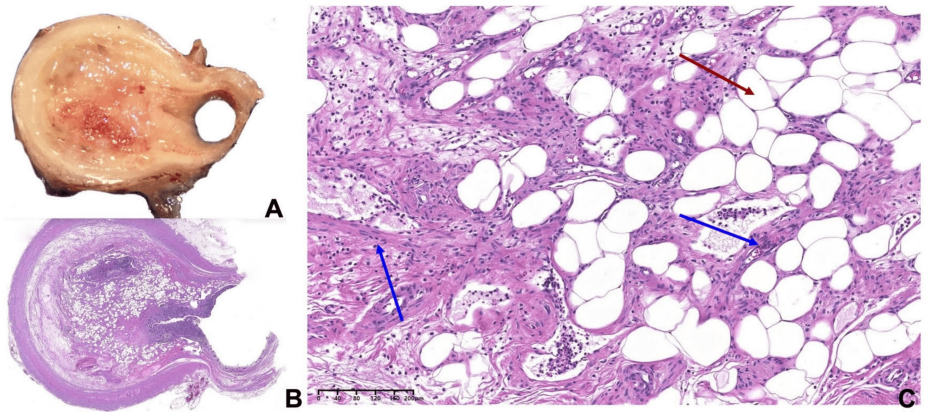

FIGURE 3: Gross and histopathological features of appendiceal neuroma.

(A) Gross photograph of a cross-section from the site of the appendiceal neuroma in the middle third of the appendix; histologically, the lesion involved the submucosa. (B) H&E photomicrograph showing replacement of the submucosa by a proliferation of neural elements associated with adipose tissue and chronic inflammatory cells, with partial obliteration of the appendiceal lumen. (C) Higher-magnification H&E photomicrograph showing spindle-shaped cells with elongated, cytologically bland nuclei (blue arrows) arranged within a fibrous stroma and admixed with adipose tissue (red arrow) and chronic inflammatory infiltrates (×40 objective).

Follow-up and outcomes

The postoperative course was uneventful, with stable vital signs, adequate pain control, progressive oral tolerance, and no evidence of wound complications. The patient was discharged on day 4 with wound-care instructions and outpatient follow-up.

At 30-day postoperative follow-up, the patient remained asymptomatic, with no reported surgical-site infection, abdominal pain, fever, intolerance to oral intake, or other postoperative complications. No readmission, reintervention, or additional procedure was required. According to the Clavien-Dindo classification, no postoperative complication occurred during the reported 30-day follow-up period.

Patient perspective

At the 30-day follow-up, the patient reported clinical improvement and adequate recovery after surgery. He expressed understanding of the final pathological findings and the plan for routine postoperative follow-up according to the treating surgeon's recommendations.

Timeline

The sequence of presentation, investigation, intervention, recovery, and diagnosis is summarized in Table *2*.

Day or interval	Clinical event
Day 1	Acute epigastric pain, dyspepsia, and nausea; emergency assessment showed leukocytosis with neutrophilia.
Day 2	Non-contrast computed tomography, selected because of the patient-reported iodine allergy, suggested uncomplicated appendicitis; ceftriaxone 1 g IV and metronidazole 500 mg IV were each administered as a single dose; laparoscopic appendectomy was performed.
Day 2 to Day 4	Uneventful recovery with pain control and oral tolerance, without fever or wound complications.
Day 4	Discharged with wound-care instructions and outpatient follow-up.
30 days postoperatively	Asymptomatic recovery without reported wound infection, abdominal pain, fever, oral intolerance, readmission, reintervention, or additional procedure.
Final histopathology	Final pathology showed ulcerated acute appendicitis, five nonperforated diverticula, and an appendiceal neuroma in the middle third confined to the submucosa without mucosal involvement.

TABLE 2: Timeline of the patient's clinical course.

Discussion

This case demonstrates that appendiceal diverticulitis and appendiceal neuroma may coexist in a patient whose symptoms and computed tomography findings suggest uncomplicated acute appendicitis. In this patient, the coexistence was not suspected clinically, radiologically, or intraoperatively and was identified only through examination of the appendectomy specimen. The epigastric pain and dyspeptic symptoms were nonspecific; therefore, this report does not identify a clinical feature that can reliably distinguish this rare coexistence from ordinary acute appendicitis.

Appendiceal diverticular disease may be congenital or acquired, although most acquired lesions are pseudodiverticula formed by mucosal and submucosal herniation through defects in the muscularis propria [2,3]. Previous studies have associated appendiceal diverticulitis with perforation and appendiceal diverticulosis with neoplasia [1-3]. These are associations from published cohorts and do not mean that either complication was present in this patient: gross and histological examination showed five diverticula extending from the middle third to the tip without perforation, and no epithelial mucinous neoplasm was identified.

The second unexpected finding was appendiceal neuroma. In this patient, the lesion was located in the middle third of the appendix, confined to the submucosa, and associated with partial luminal obliteration without mucosal involvement. It consisted of cytologically bland spindle-shaped cells in a fibrous stroma with adipose tissue and chronic inflammatory infiltrates. The absence of atypia, increased mitotic activity, or destructive growth supported a benign neural proliferation. Pathology review determined that the characteristic H&E morphology was sufficient for the diagnosis and that immunohistochemistry was not required. Published studies describe appendiceal neuroma as a benign proliferation involving Schwann cells and nerve fibers [4,5]. Lowes et al. reported mucosal neuromatous changes associated with complicated appendiceal diverticular disease [8]. A prior case report also documented the simultaneous presentation of appendiceal diverticular disease and appendiceal neuroma [10]. Because the lesion in this case was submucosal and lacked mucosal involvement, it should not be regarded as histopathologically equivalent to the mucosal neuromatous changes described by Lowes et al. [8]. The present case documents coexistence but cannot establish a causal relationship between diverticular disease and neuromatous proliferation.

Low-grade appendiceal mucinous neoplasm is an important pathological differential diagnosis when diverticular disease causes mucin pooling, epithelial displacement, or distortion of the appendiceal wall [8]. Appendiceal neuroendocrine tumor is a separate neoplasm that must be distinguished from appendiceal neuroma [7]. In this case, no morphological features of a neuroendocrine neoplasm or epithelial mucinous neoplasm, including LAMN, were identified. The proximal resection margin and mesoappendix were free of neuromatous proliferation. These findings support complete excision in the appendectomy specimen, but management decisions should remain individualized according to the full pathological and clinical context.

Laparoscopic appendectomy was appropriate for the clinical and imaging diagnosis and was definitive treatment in this patient. Routine histopathological examination allowed the unexpected lesions to be recognized. Any further pathological sampling or postoperative surveillance should be individualized according to the complete pathology findings and clinical context. This single case does not support mandatory additional surgery, special surveillance, or a universal change in postoperative management.

Published observations suggest that appendiceal diverticulitis may be associated with a longer or intermittent clinical course than conventional appendicitis [1,2], but no validated clinical score or imaging criterion reliably identifies the coexistence described here. Prospective studies with standardized imaging and pathology reporting would be needed to determine whether reproducible preoperative or histological markers exist.

Strengths and limitations

The main strength of this report is the clinicoradiological and detailed histopathological correlation in a case that appeared uncomplicated before surgery. Its limitations include the single-patient design, non-contrast imaging, and follow-up limited to 30 days. The pathological diagnosis was based on characteristic H&E morphology, for which pathology review considered ancillary immunohistochemistry unnecessary. These limitations prevent conclusions about causality, diagnostic accuracy, long-term outcomes, or a standardized surveillance strategy.

Conclusions

Appendiceal diverticulitis and appendiceal neuroma were incidentally identified after laparoscopic appendectomy for presumed uncomplicated acute appendicitis. The nonspecific presentation and non-contrast computed tomography did not distinguish these lesions before surgery, and the diagnosis depended on histopathological examination. The neuroma was confined to the submucosa without mucosal involvement and therefore should not be considered histopathologically equivalent to the mucosal neuromatous changes described by Lowes et al. This observation supports routine examination of appendectomy specimens but does not establish a causal relationship between the lesions or justify additional surgery or surveillance beyond that indicated by the complete pathology findings and individual clinical context.

Additional Information

Author Contributions

All authors have reviewed the final version to be published and agreed to be accountable for all aspects of the work.

Concept and design: Edson A. Escandón Villalobos, María F. Ramos Griera, Diego M. García Vivanco

Acquisition, analysis, or interpretation of data: Edson A. Escandón Villalobos, María F. Ramos Griera, Diego M. García Vivanco, Viana Guerrero-Elías, Jorge Leal Hidalgo

Drafting of the manuscript: Edson A. Escandón Villalobos, María F. Ramos Griera, Diego M. García Vivanco, Viana Guerrero-Elías, Jorge Leal Hidalgo

Critical review of the manuscript for important intellectual content: Edson A. Escandón Villalobos, María F. Ramos Griera, Diego M. García Vivanco, Viana Guerrero-Elías, Jorge Leal Hidalgo

Supervision: Edson A. Escandón Villalobos, Diego M. García Vivanco

Disclosures

Human subjects: Informed consent for treatment and open access publication was obtained or waived by all participants in this study. **Conflicts of interest:** In compliance with the ICMJE uniform disclosure form, all authors declare the following: **Payment/services info:** All authors have declared that no financial support was received from any organization for the submitted work. **Financial relationships:** All authors have declared that they have no financial relationships at present or within the previous three years with any organizations that might have an interest in the submitted work. **Other relationships:** All authors have

declared that there are no other relationships or activities that could appear to have influenced the submitted work.

References

1. Ito D, Miki K, Seiichiro S, Hata S, Kobayashi K, Teruya M, Kaminishi M: Clinical and computed tomography findings of appendiceal diverticulitis vs acute appendicitis. World J Gastroenterol. 2015, 21:3921-7. 10.3748/wjg.v21.i13.3921
2. Sahin N, Donmez T, Degerli MS, et al.: Appendiceal diverticular disease: Evaluation of the clinical, radiologic, and pathologic findings in 153 patients. Surg Today. 2026, 56:1401-11. 10.1007/s00595-026-03323-y
3. Lim CSH, Cheah SYL, Kwok AMF, Ravindran P, Chan DL: Systematic review and meta-analysis of the association between diverticulosis of the appendix and neoplasia. ANZ J Surg. 2020, 90:1871-7. 10.1111/ans.15811
4. Peisl S, Burckhardt O, Egger B: Neurogenic appendicopathy: An underestimated disease—Systematic review of the literature. Int J Colorectal Dis. 2021, 36:1995-2005. 10.1007/s00384-021-03901-1
5. Stanley MW, Cherwitz D, Hagen K, Snover DC: Neuromas of the appendix: A light-microscopic, immunohistochemical and electron-microscopic study of 20 cases. Am J Surg Pathol. 1986, 10:801-15. 10.1097/00000478-198611000-00008
6. Altunpak B, Çebi F, Dölek MA, Yarıkkaya E, İdiz UO: Incidental appendiceal neoplasms in patients undergoing appendectomy for acute appendicitis: A 10-year retrospective analysis of 5001 cases. Surg Endosc. 2026, 40:4792-805. 10.1007/s00464-026-12897-0
7. Muñoz de Nova JL, Hernando J, Sampedro Núñez M, et al.: Management of incidentally discovered appendiceal neuroendocrine tumors after an appendicectomy. World J Gastroenterol. 2022, 28:1304-14. 10.3748/wjg.v28.i13.1304
8. Lowes H, Rowaiye B, Carr NJ, Shepherd NA: Complicated appendiceal diverticulosis versus low-grade appendiceal mucinous neoplasms: A major diagnostic dilemma. Histopathology. 2019, 75:478-85. 10.1111/his.13931
9. Kerwan A, Al-Jabir A, Mathew G, et al.: Revised surgical case report (SCARE) guideline: An update for the age of artificial intelligence. Premier J Sci. 2025, 10:100079. 10.70389/PJS.100079
10. Lara-Torres CO, Soria-Céspedes D, Piña-Oviedo S, Ortiz-Hidalgo C: Presentación simultánea de enfermedad diverticular del apéndice cecal y neuroma apendicular que protruye a través de defectos múltiples de la pared muscular (Article in Spanish). Patol Rev Latinoam. 2010, 48:243-5.