Cureus
Part of SPRINGER NATURE

Open Access Case Report

Paratubal Cyst With Isolated Torsion of the Fallopian Tube in an Adolescent Girl: A Case Report

Hidaya Zitan [1], Ismail Benomar [1], Chaima Riadi [1], Loubna Aqqaoui [1], Houda Oubejja [1], Fouad Ettayebi [1]

1. Pediatric Surgery, Children's Hospital of Rabat, Faculty of Medicine and Pharmacy, Mohammed V University, Rabat, MAR

Corresponding author: Hidaya Zitan, hidayazitan@gmail.com

Review began 11/05/2026
Review ended 11/16/2026
Published 11/19/2026

© **Copyright** 2026
Zitan et al. This is an open access article distributed under the terms of the Creative Commons Attribution License CC-BY 4.0., which permits unrestricted use, distribution, and reproduction in any medium, provided the original author and source are credited.

DOI: 10.7759/cureus.119958

Abstract

Isolated fallopian tube torsion (IFTT) is a rare cause of acute pelvic pain in adolescents. Diagnosis is often delayed due to nonspecific clinical and imaging findings, which may lead to tubal necrosis and loss of fertility.

We report the case of a 13-year-old adolescent girl who presented with right lower abdominal pain associated with vomiting. Initial ultrasound suggested hydrosalpinx, while pelvic MRI revealed hematosalpinx with torsion. Laparoscopic exploration showed a twisted and necrotic right fallopian tube associated with a paratubal cyst, with a normal ipsilateral ovary. Due to necrosis, conversion to open surgery was performed.

IFTT should be considered in adolescents presenting with acute pelvic pain, even in the absence of ovarian abnormalities. Early diagnosis and surgical intervention are essential to preserve fertility.

Categories: Obstetrics/Gynecology, Radiology, Pediatric Surgery
Keywords: acute pelvic pain, adolescent, hematosalpinx, isolated fallopian tube torsion, laparoscopy, paratubal cyst

Introduction

Acute pelvic pain in adolescent girls represents a frequent diagnostic challenge. The differential diagnosis includes appendicitis, ovarian torsion, pelvic inflammatory disease, and functional pain, and adnexal torsion should be considered in this population even when the ipsilateral ovary appears normal on imaging [1]. Isolated fallopian tube torsion (IFTT) is a rare but important entity, often overlooked due to its nonspecific presentation and the frequent presence of a normal ovary on imaging [2,3].

Paratubal cysts, often acting as a pivot point for rotation, are among the most frequently identified predisposing factors for IFTT [3]. Because IFTT and ovarian torsion share overlapping clinical and radiological features, the two entities can be difficult to distinguish preoperatively; the presence of a normal ipsilateral ovary is a key distinguishing feature, and magnetic resonance imaging may provide additional diagnostic value when ultrasound findings are inconclusive [3-5].

We report a case of isolated torsion of the fallopian tube with hematosalpinx in an adolescent girl, highlighting the diagnostic difficulties and surgical management.

Case Presentation

A 13-year-old girl presented with a 12-day history of right lower abdominal pain. The pain was intermittent during the first week before becoming constant, with a gradual decrease in intensity over the course of the illness. The pain was localized to the right iliac fossa and associated with episodes of alimentary vomiting. There were no associated bowel or urinary symptoms, and the clinical course evolved in the absence of fever. The patient reported a two-month history of foul-smelling leukorrhea, for which she had not sought care and which had therefore not been treated; no clinical or biological evidence of genital tract infection was found, as leukorrhea was not observed on admission examination and a repeat vaginal swab performed during admission was negative. Her gynecological history revealed menarche with regular 25-day cycles, with the last menstrual period on February 17, 2026, and no history of dysmenorrhea. A urine pregnancy test performed on admission was negative.

On admission, the patient was alert and clinically stable. Abdominal examination revealed a soft abdomen without palpable mass or tenderness. Genitourinary examination was unremarkable, with a non-bulging hymen, no leukorrhea, and no adnexal tenderness.

Ultrasound findings were suggestive of right hydrosalpinx, with no abnormalities of the ovaries or appendix;

given the operator-dependent nature of ultrasonography and persistent diagnostic uncertainty, pelvic MRI was performed the same day, without delaying surgical management. MRI demonstrated right hematosalpinx, with the fallopian tube distended to 18 mm in caliber, associated with a 2-cm right paratubal cyst and a whirlpool sign corresponding to the vascular pedicle, consistent with tubal torsion. The right ovary was enlarged (30 × 27 × 26 mm) but otherwise morphologically normal, with minimal pelvic free fluid, supporting a diagnosis of isolated tubal torsion rather than ovarian or adnexal torsion. Doppler ultrasound was not performed. Laboratory tests, including complete blood count and C-reactive protein, were within normal limits, and microbiological analysis of the vaginal swab was negative.

An initial exploratory laparoscopy was performed under general anesthesia using a 10-mm umbilical trocar and an additional trocar in the left flank. Intraoperative findings revealed a twisted right fallopian tube, violaceous, necrotic, and sphacelated, associated with a paratubal cyst (Figures *1*, *2*).

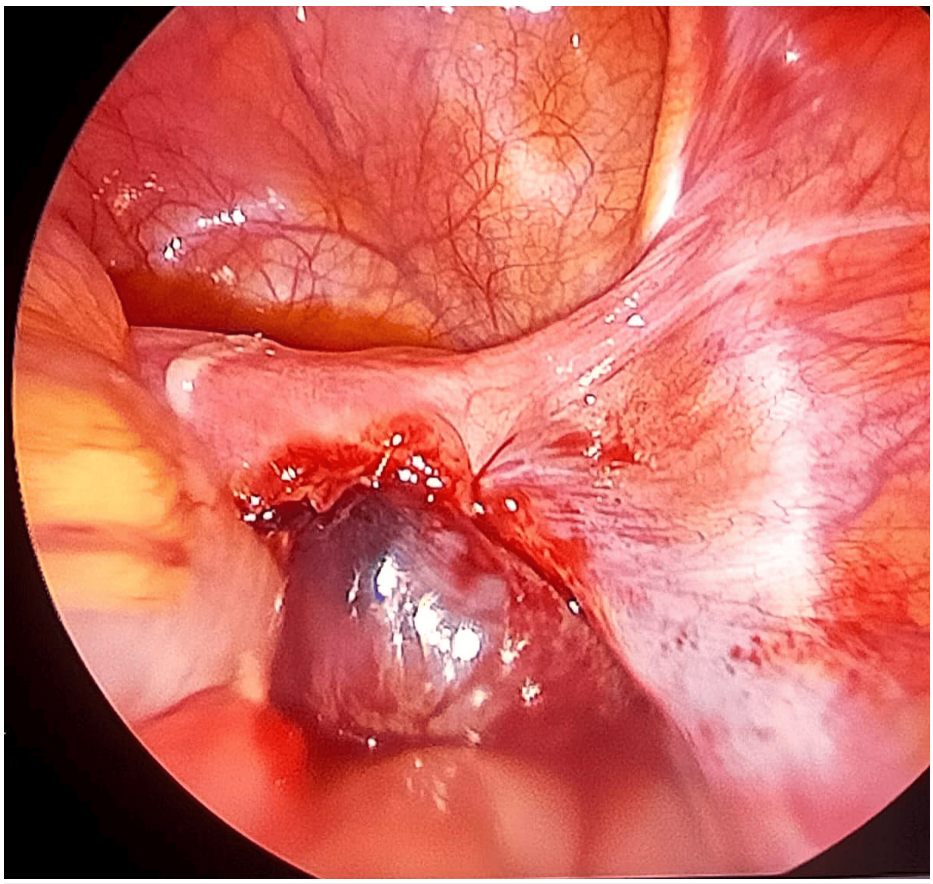

FIGURE 1: Initial diagnostic laparoscopy showing the twisted right adnexa

Laparoscopic view of the pelvis demonstrating a markedly congested, dusky right fallopian tube twisted around its axis, with an associated paratubal cyst and surrounding hemorrhagic exudate.

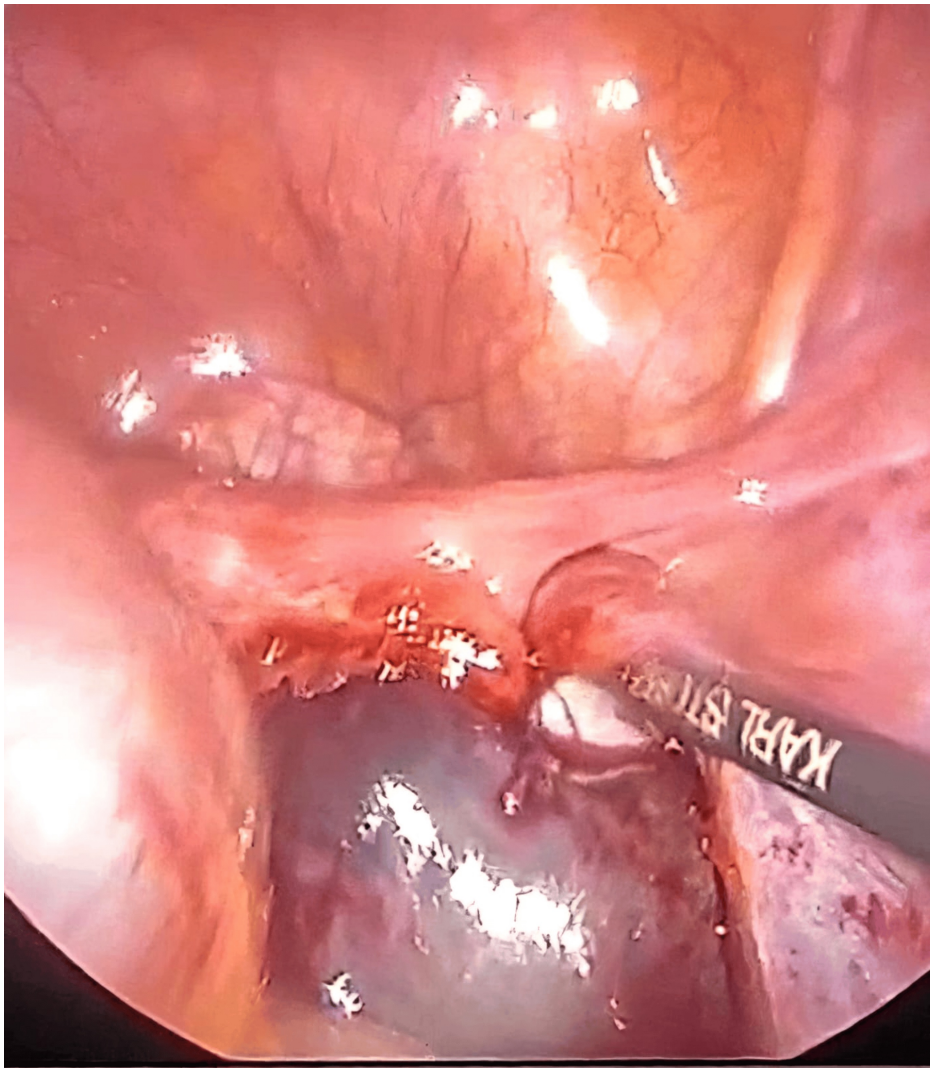

FIGURE 2: Laparoscopic close-up of the torsed tubal pedicle

Closer laparoscopic view showing the necrotic, hemorrhagic torsed segment of the right fallopian tube, obtained during exploration prior to conversion to open surgery.

Detorsion was attempted, but the tube showed no evidence of reperfusion after an observation period, confirming irreversible ischemic damage. The right ovary was normal in size and appearance, and the left adnexa were unremarkable. The appendix appeared macroscopically inflamed on direct visualization. Given the necrotic appearance of the fallopian tube and the risk of paratubal cyst rupture during laparoscopic specimen extraction, conversion to open surgery via a right-sided Pfannenstiel incision was undertaken for definitive management. Intraoperative exploration confirmed a twisted paratubal cyst associated with a necrotic right fallopian tube, while the right ovary was preserved and appeared normal. A right salpingectomy with paratubal cyst excision was performed after ligation of the vascular pedicle, with preservation of the right ovary. Given the macroscopically inflamed appearance of the appendix, a retrograde appendectomy was also carried out, including ligation and division of the mesoappendix. Hemostasis was secured, and the surgical specimens were sent for histopathological examination (Figures *3*, *4*).



FIGURE 3: Gross specimen of the resected right fallopian tube

Ex vivo photograph of the surgical specimen after right salpingectomy, showing a diffusely hemorrhagic, necrotic, sausage-shaped fallopian tube with an adherent paratubal cyst.



FIGURE 4: Gross specimen with a ruler for size reference

Ex vivo photograph of the resected necrotic right fallopian tube and paratubal cyst alongside a ruler, showing a specimen length of approximately 9 cm.

Postoperative evolution was uncomplicated. Analgesia with paracetamol was sufficient, oral intake was reintroduced at 24 hours, and discharge occurred at 48 hours.

Histopathological examination of the fallopian tube showed ischemic necrosis with hemorrhagic infarction; the paratubal cyst contained serosanguinous fluid, with no evidence of malignancy. Examination of the appendix confirmed inflammatory changes consistent with appendicitis, likewise without evidence of malignancy.

Discussion

IFTT is a rare entity, particularly in adolescents, and remains a diagnostic challenge due to its nonspecific clinical presentation and the frequent absence of pathognomonic imaging features [2,3].

In the present case, initial ultrasound findings were suggestive of hydrosalpinx, whereas MRI provided better lesion characterization by demonstrating hematosalpinx and raising suspicion of torsion through the

presence of a whirlpool sign [5]. Nevertheless, as in most reported cases, definitive diagnosis was established only at the time of surgical exploration [3].

Paratubal cysts are well-recognized predisposing factors for tubal torsion, serving as a pivot for tubal rotation; a recent single-center series found structural tubal or paratubal abnormalities, including paratubal cysts, hydrosalpinx, and Müllerian cysts, in all surgically confirmed pediatric cases of IFTT [3]. Despite advances in imaging techniques, preoperative diagnosis remains difficult, and laparoscopy continues to represent the gold standard for both diagnosis and management of suspected adnexal torsion in adolescents [1].

Early recognition allows for conservative treatment with detorsion, with or without excision of the associated cyst, and preservation of the fallopian tube [4,6]. This decision should be guided primarily by intraoperative assessment of tissue viability rather than by torsion duration or macroscopic appearance alone, given the documented potential for tissue recovery even after apparently severe ischemic changes. In the largest available pediatric series, comprising 10 adolescents followed over a 15-year period, the tube was preserved by detorsion in 50% of cases and removed by salpingectomy in the remaining 50%, with open conversion required in 80% of cases and an associated paraovarian or paratubal cyst present in 70% [7]. In our case, detorsion was attempted as a fertility-preserving first step; however, the absence of any reperfusion after an adequate observation period was considered indicative of irreversible necrosis, consistent with the subset of reported cases requiring salpingectomy, and conversion to laparotomy was undertaken given the risk of cyst rupture during laparoscopic extraction. The 12-day symptom duration in our patient falls within the range reported in this series (six hours to one month), underscoring that delayed presentation, as in our case, may lead to irreversible ischemic damage necessitating salpingectomy [4,7].

Conclusions

IFTT should be considered in adolescent girls presenting with acute or subacute pelvic pain, even in the presence of a normal ovary on imaging. Early surgical exploration is essential to establish the diagnosis and maximize the chances of fertility preservation. This case involved unilateral salpingectomy, and although menstrual cycles had returned to normal at nine months of follow-up, longer-term reproductive outcomes, including future fertility, were not assessed.

Additional Information

Author Contributions

All authors have reviewed the final version to be published and agreed to be accountable for all aspects of the work.

Concept and design: Hidaya Zitan, Ismail Benomar, Chaima Riadi, Loubna Aqqaoui, Houda Oubejja, Fouad Ettayebi

Acquisition, analysis, or interpretation of data: Hidaya Zitan, Ismail Benomar, Chaima Riadi, Loubna Aqqaoui, Houda Oubejja, Fouad Ettayebi

Drafting of the manuscript: Hidaya Zitan, Ismail Benomar, Chaima Riadi, Loubna Aqqaoui, Houda Oubejja, Fouad Ettayebi

Critical review of the manuscript for important intellectual content: Hidaya Zitan, Ismail Benomar, Chaima Riadi, Loubna Aqqaoui, Houda Oubejja, Fouad Ettayebi

Supervision: Hidaya Zitan, Ismail Benomar, Chaima Riadi, Loubna Aqqaoui, Houda Oubejja, Fouad Ettayebi

Disclosures

Human subjects: Informed consent for treatment and open access publication was obtained or waived by all participants in this study. **Conflicts of interest:** In compliance with the ICMJE uniform disclosure form, all authors declare the following: **Payment/services info:** All authors have declared that no financial support was received from any organization for the submitted work. **Financial relationships:** All authors have declared that they have no financial relationships at present or within the previous three years with any organizations that might have an interest in the submitted work. **Other relationships:** All authors have declared that there are no other relationships or activities that could appear to have influenced the submitted work.

References

1. American College of Obstetricians and Gynecologists: Adnexal torsion in adolescents: ACOG Committee Opinion No. 783 Summary. Obstet Gynecol. 2019, 134:435-6. 10.1097/AOG.0000000000003376

2. Magdoud K, Mkadmi H, Moussa F, Ghali Z, Menjli S, Karoui A: Isolated fallopian tube torsion: a rare cause of acute pelvic pain in adolescence. J Paediatr Child Health. 2024, 60:601-3. 10.1111/jpc.16629
3. Li S, Xie F, Wang J, et al.: Clinicopathological characteristics and etiological considerations of isolated fallopian tube torsion in pediatric patients: a single center study. Transl Pediatr. 2025, 14:3053-60. 10.21037/tp-2025-405
4. Vadukkut AS, Mangeshikar A, Jadhav S, Kumar S: Laparoscopic salpingectomy for an isolated case of left fallopian tube torsion in a premenarcheal 13 years old. Gynecol Minim Invasive Ther. 2020, 9:245-7. 10.4103/GMIT.GMIT_90_18
5. Arkoudis NA, Efthymiou E, Koutserimpas C, Spiliopoulos S: Classics in abdominal imaging: the "whirlpool" sign of ovarian torsion on MRI. Abdom Radiol (NY). 2024, 49:678-80. 10.1007/s00261-023-04144-0
6. Sancar S, Anayurt M, Dayı S: Surgical management of ovarian torsion in children: detorsion, cyst/mass excision, and ovarian fixation. Reprod Biol. 2025, 25:101054. 10.1016/j.repbio.2025.101054
7. Güney C, Coskun A: A fifteen-year analysis of rare isolated fallopian tube torsions in adolescent children: a case series. Diagnostics (Basel). 2019, 9:110. 10.3390/diagnostics9030110