Cureus
Part of SPRINGER NATURE

Open Access Case Report

Anterior Tibial Stress Fracture With an Underlying Osteoid Osteoma in a Collegiate Basketball Player

Review began 10/29/2026
Review ended 11/18/2026
Published 11/23/2026

© **Copyright** 2026
Marshall et al. This is an open access article distributed under the terms of the Creative Commons Attribution License CC-BY 4.0., which permits unrestricted use, distribution, and reproduction in any medium, provided the original author and source are credited.

DOI: 10.7759/cureus.120149

Dustin Marshall [1], Earl R. Stewart [1], Jonathan R. Guin [1]

1. Family Medicine, University of Alabama, Tuscaloosa, USA

Corresponding author: Dustin Marshall, dustin.cole.marshall@gmail.com

Abstract

Anterior tibial stress fractures and osteoid osteomas are included in the differential diagnosis of anterior leg pain. However, their respective pathologies and management differ significantly. Anterior tibial stress fractures most commonly occur in high-level jumping athletes and long-distance runners and may require surgical treatment due to their location, tensile forces, and limited blood supply. Conversely, osteoid osteomas are benign tumors that are typically self-limiting and can be treated with supportive care. Refractory cases may occasionally require radiofrequency ablation or surgical resection. This case highlights a collegiate basketball player who had an anterior tibial stress fracture with an underlying osteoid osteoma. A carbon fiber rod was used to repair the stress fracture instead of a standard titanium rod to minimize imaging artifacts during MRI and CT surveillance of both lesions.

Categories: Sports Medicine, Orthopedics
Keywords: anterior tibial stress fracture, basketball player, collegiate athlete, lower extremity injury, osteoid osteoma

Introduction

Anterior leg pain is a common complaint among athletes involved in jumping sports such as basketball, gymnastics, and track and field. Anterior tibial stress fractures account for 5-15% of all stress fractures and occur at a higher rate among these athletes. They are classified as high-risk fractures due to their limited blood supply and the continuous tensile forces imposed at the site of injury [1]. Most collegiate athletes also fall into the age category of teenagers or young adults, placing them at a higher risk of developing a benign skeletal neoplasm called an osteoid osteoma. Although pain from osteoid osteomas typically improves with nonsteroidal anti-inflammatory drugs (NSAIDs), the tumors may still necessitate radiofrequency ablation or surgical resection for persistent pain. Both lesions are included in the differential diagnosis of anterior leg pain in collegiate jumping athletes. They present similarly with deep, localized, persistent pain that worsens over time. One key difference in presentation is that pain from anterior tibial stress fractures usually worsens with activity, while pain from osteoid osteomas worsens at night and generally, though not always, improves with NSAIDs [1,2]. This case highlights a patient who had an anterior tibial stress fracture with an underlying osteoid osteoma, requiring co-management of these two distinct lesions. This report highlights the diagnostic pitfalls in distinguishing between these two entities and the steps taken to ensure appropriate treatment when managing them together. It is reported in accordance with the Case Reports and Literature Review (CaReL) guidelines [3].

Case Presentation

A 20-year-old women's college basketball player with no pertinent past medical history presented to a sports medicine clinic for evaluation of left shin pain of 2 weeks' duration. The pain initially felt "like shin splints" and would gradually worsen with activity. The pain was now occurring at rest and had recently become sharp and localized to a pinpoint area on the tibia. She rated the pain as 8/10 in severity on the numeric rating scale (NRS), and it was worse with walking and jumping. It had progressed to the point of inhibiting her play and was causing her to wake at night. There was no known trauma to the area prior to the onset of pain. She had tried diclofenac patches twice daily with minimal relief. Her in-office examination showed no notable swelling or ecchymosis. Both lower extremities had full active range of motion, strength, and sensation. She had pinpoint tenderness to palpation over the bony prominence of the anterior portion of her left tibia, approximately 20 cm distal to the tibial tubercle, and was unable to perform a single-leg hop without pain.

The differential diagnosis at the time of presentation included an anterior tibial stress fracture versus a stress reaction of the tibia. This was based on her age, the nature of her sport, and her history of progressively worsening pain, particularly given her inability to hop on the affected leg and the evolution of pain from exertional to resting. Medial tibial stress syndrome (MTSS) was considered given the complaint of "shin splints" but was felt to be less likely due to the highly localized, pinpoint anterior tenderness rather than the typical diffuse posteromedial tibial pain seen with MTSS. A traumatic bone contusion or periosteal hematoma was also considered, but the absence of a clear injury mechanism, swelling, or ecchymosis, along

with the gradual symptom onset, made these diagnoses unlikely. Malignancy and osteomyelitis were considered less likely due to the absence of systemic symptoms and aggressive imaging features.

Her initial X-ray raised concern for a "dreaded black line" (Figure *1*), which is a key pathognomonic finding in anterior tibial stress fractures [1]. Based on the X-ray findings, an MRI was ordered, which showed no evidence of a fracture but demonstrated bone marrow edema consistent with a mild stress reaction of the tibia (Figure *2*). A follow-up CT was ordered to assess the bone reaction observed on MRI and rule out any evidence of a fracture. This showed a more rounded appearance of the lucency seen on the X-ray, raising concern for an osteoid osteoma (Figure *3*). Based on the new imaging findings, the patient was treated for both a stress reaction and a suspected osteoid osteoma with a tall walking boot, meloxicam 15 mg nightly for two weeks, over-the-counter NSAIDs as needed thereafter, and rest from activities until her two-month follow-up appointment.



FIGURE 1: Plain lateral radiograph of the left leg at the initial visit showing a lucency in the anterior tibial cortex consistent with the "dreaded black line" appearance, raising concern for an anterior tibial stress fracture.

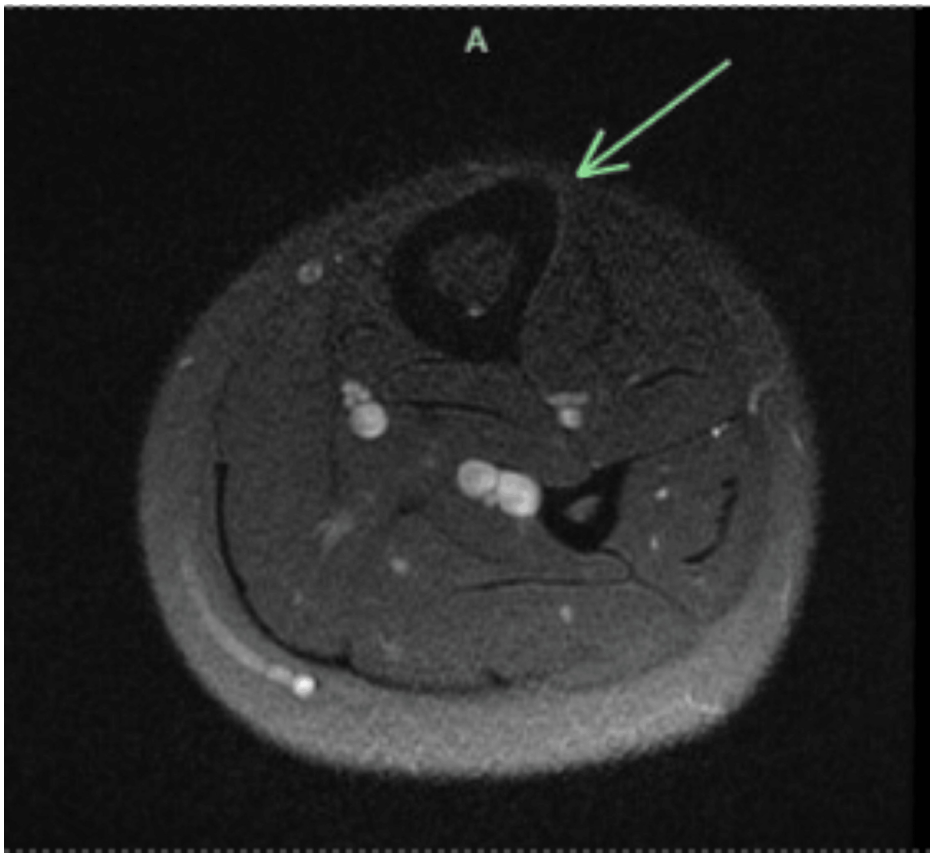

FIGURE 2: Axial proton density fat-saturated MRI of the left lower leg obtained after the initial X-ray, showing mild periosteal swelling and edema consistent with a stress reaction of the anterior tibia.

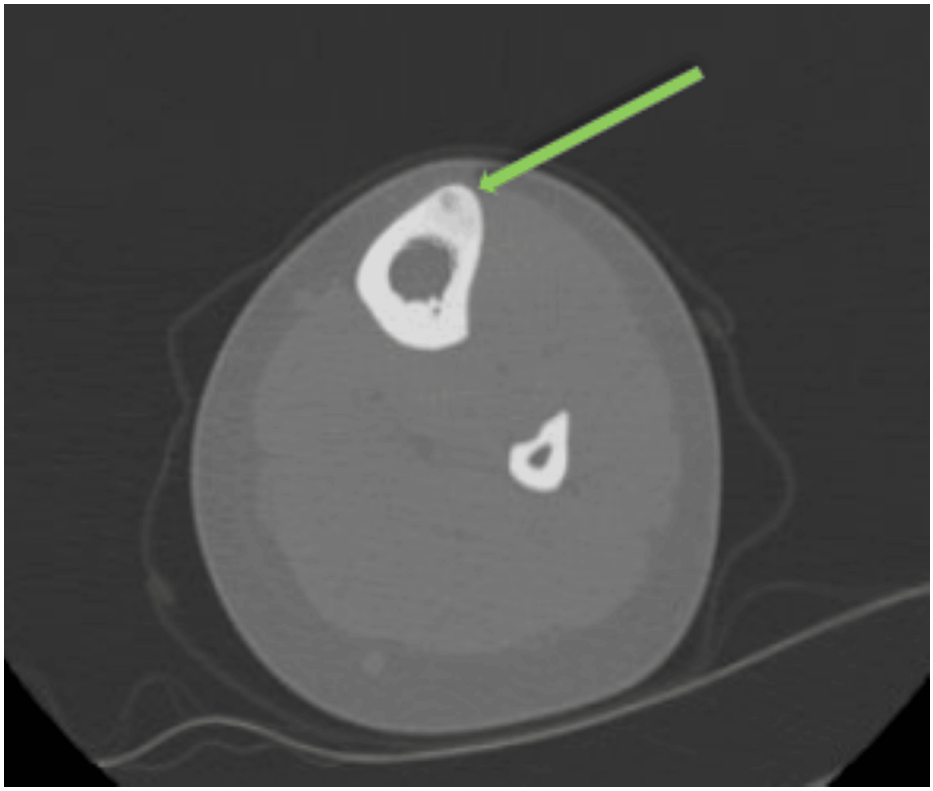

FIGURE 3: Follow-up CT scan obtained after MRI to rule out any evidence of a fracture. The axial image at the site of the lucency identified on X-ray shows a more rounded nidus than would be expected for a fracture, consistent with an osteoid osteoma. The nidus measured 4.35 in width.

At the two-month follow-up, 10 weeks after symptom onset, her pain had minimally improved, and repeat X-rays continued to show the lucency in the area. Due to the persistent symptoms and X-ray findings, a repeat CT was ordered. It raised concern for an enlarging osteoid osteoma with notable soft tissue edema (Figure *4*). She was then referred for ablation and continued partial weight-bearing in a walking boot with nightly NSAIDs as needed.

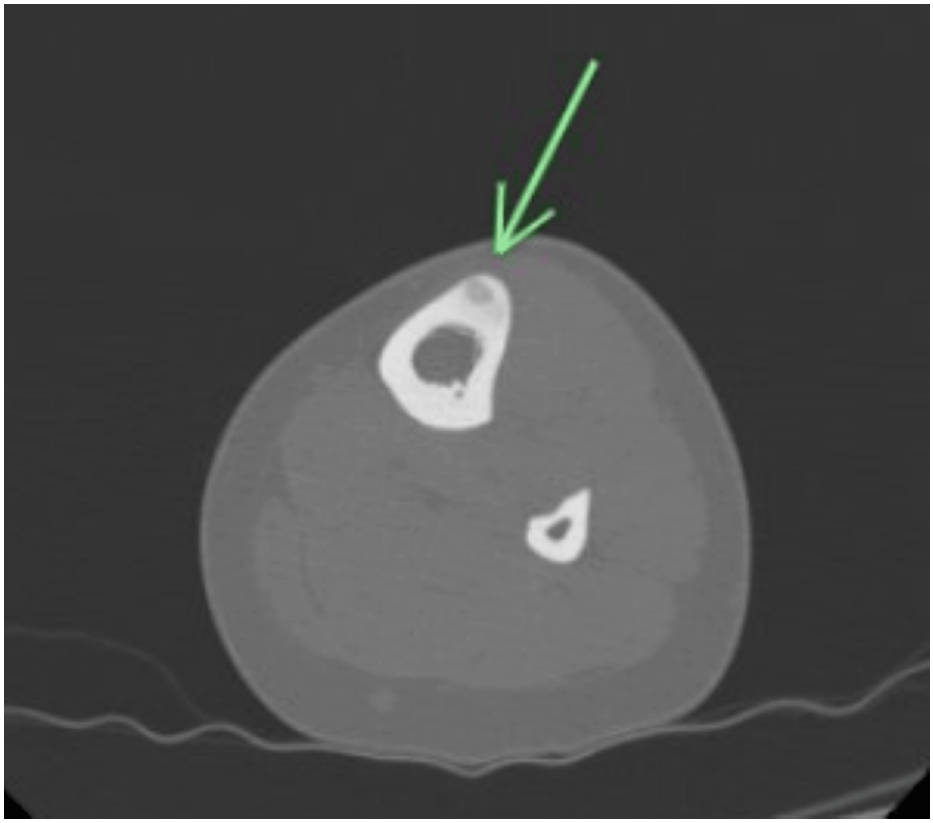

FIGURE 4: Two months later, a repeat CT scan showed an enlarging osteoid osteoma with associated soft tissue edema, now measuring 6.17 mm in width.

At the three-month mark, 14 weeks after symptom onset, her pain had worsened, and a repeat MRI demonstrated a now-evident anterior cortical stress fracture overlying the known nidus (Figure *5*). She had not yet been scheduled for ablation, and the osteoid osteoma was still present.

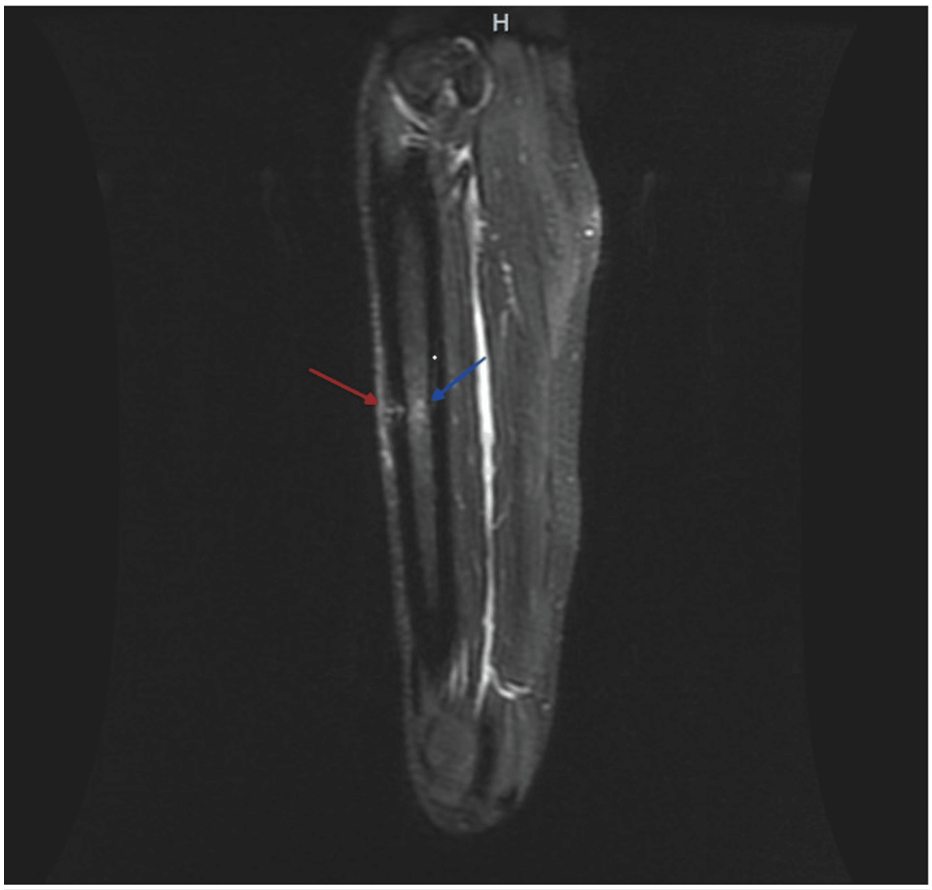

FIGURE 5: Follow-up MRI obtained after the CT scan showing an anterior tibial stress fracture overlying the previously identified osteoid osteoma. The red arrow indicates the osteoid osteoma lesion, while the blue arrow indicates linear edema extending through the cortex, consistent with a stress fracture.

The patient was treated for a total of 15 weeks with conservative management, including a tall walking boot, complete rest from activities, and meloxicam for two weeks, followed by over-the-counter NSAIDs nightly as needed until ablation of the suspected osteoid osteoma was performed. Following ablation, a carbon fiber intramedullary rod was placed in the tibia to treat the stress fracture. She then continued partial weight-bearing for another six weeks before progressing to full weight-bearing, undergoing physical therapy, and subsequently returning gradually to play. She remained out of competition for the remaining nine months of the season, completed her postoperative recovery, and fully returned to sport at the start of the next season, with only minimal pain, which she rated as 0-2 on the NRS. She is currently doing well and has experienced minimal to no pain up to one year postoperatively (Figure *6*).



FIGURE 6: Postoperative X-ray showing the radiolucent carbon fiber rod in place.

A summary timeline of events is presented in Figure 7.

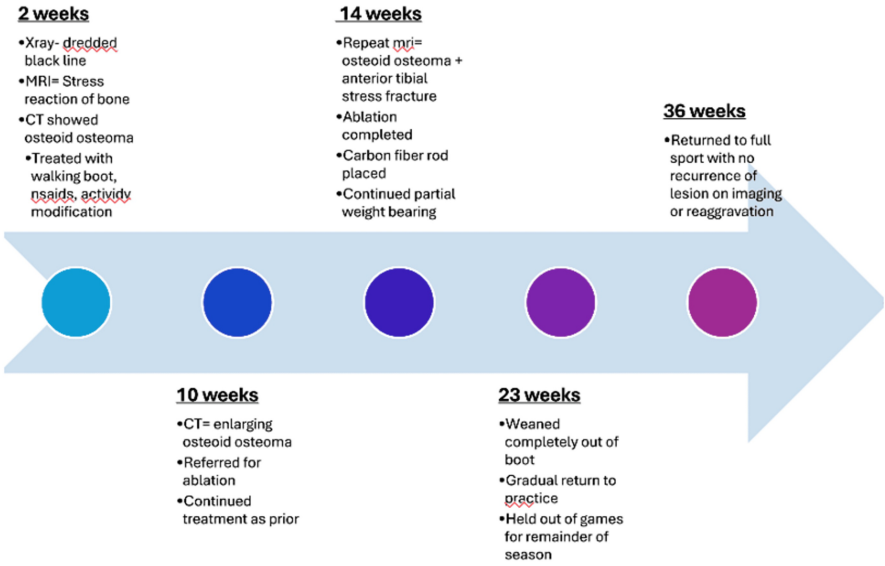

FIGURE 7: Timeline of imaging and treatment for the patient's current condition. Each section is labeled in weeks since symptom onset.

Discussion

Stress fractures are caused by chronic, repetitive submaximal loading of the bone. When a bone is subjected to repetitive stress, the resulting damage can outpace the healing process and eventually lead to a break in the cortex [2]. These injuries account for approximately 0.7-20% of all sports-related injuries and most commonly affect the tibia, metatarsals, and fibula. Risk factors include rapid increases in training volume, biomechanical abnormalities, poor muscle strength and flexibility, and inadequate nutrition. Patients typically present with an insidious onset of pain that worsens with activity and localized bony tenderness on examination. Plain radiographs are often negative early on but may show periosteal reaction, lucency, or fracture lines such as the “dreaded black line.” MRI has become the preferred imaging modality due to its high sensitivity and specificity and its ability to evaluate for alternative pathologies [4].

It is also important to differentiate between low-risk and high-risk stress fractures when determining management. High-risk locations include the femoral neck, patella, medial malleolus, talus, navicular, proximal fifth metatarsal, great toe sesamoid, and anterior tibia, as in this case [1,2]. Low-risk stress fractures are typically managed conservatively, while high-risk fractures often require immobilization or surgical intervention due to the risk of nonunion [5]. In anterior tibial stress fractures, nonoperative treatments such as bracing, shockwave therapy, low-intensity pulsed ultrasound (LIPUS), and bone stimulators have demonstrated relatively low rates of successful return to sport [6]. Surgical management has traditionally involved either intramedullary rod placement or tension band plating, both of which have shown improved return-to-sport timelines compared with conservative management [7].

Osteoid osteomas are the third most common benign bone tumor, accounting for 10-14% of benign bone tumors. They most commonly affect children, adolescents, and young adults and typically arise in the cortex of long bones, particularly in the lower extremities. Patients classically describe localized pain that worsens at night and is relieved by NSAIDs. CT is considered the diagnostic gold standard, typically demonstrating a small, round or oval radiolucent nidus with surrounding sclerosis. Initial management often consists of NSAIDs and observation, as spontaneous regression may occur; however, persistent or refractory cases are best treated with radiofrequency ablation [8]. Surgical resection is generally indicated only if other treatment methods fail or are contraindicated. Complications of osteoid osteomas are uncommon, although recurrence is possible, and pathological fractures have been reported, potentially due to focal weakening of the bone [9].

This case highlights the rarity of having both an osteoid osteoma and an anterior tibial stress fracture at the same anatomical location. Current literature has not demonstrated a clear causal relationship between these two conditions. Prior case reports have described osteoid osteomas diagnosed after treatment of stress fractures and stress fractures occurring after ablation of osteoid osteomas without a definitive mechanistic explanation; the authors identified no other studies demonstrating causation or correlation. Table *1* summarizes these findings [10-12]. Other reports have noted the diagnostic challenges in distinguishing these entities based on clinical history, as well as tibial stress or insufficiency fractures that were not visible

on initial radiographs and required serial bone scans and MRI for diagnosis [13,14]. Further research is needed to determine whether osteoid osteomas predispose patients to stress fractures through focal cortical weakening, whether repetitive mechanical stress contributes to tumor development, or whether their coexistence is coincidental. This case also highlights the innovative use of a carbon fiber intramedullary rod to reduce artifacts on future MRI and CT imaging, as carbon fiber implants have demonstrated significantly fewer imaging artifacts compared with titanium implants, with comparable complication rates [15,16].

Study	Patient	Site	Reported Relationship Between Osteoid Osteoma and Stress Injury
Schulze W et al., (2001)	14-year-old boy with a history of an open traumatic tibial fracture 3 years earlier, complicated by osteomyelitis	Distal tibia	The authors suggested that the fracture was unlikely to have caused the osteoid osteoma (OO).
Soon M et al., (1999)	24-year-old military trainee	Left tibia	A stress fracture was proposed as a possible trigger for OO, and it delayed the diagnosis.
Netzer PA (2007)	22-year-old female elite sprinting athlete with chronic tibial pain and a history of OO resection elsewhere in the body two years earlier	Mid-anterior tibia	No causal relationship was discussed, but successful surgery following an ablation procedure was reported.

TABLE 1: Summary of prior case reports examining the relationship between tibial stress fractures and osteoid osteomas. The table presents the study name, patient description, and a summary of the reported relationship.

Conclusions

This case reinforces the importance of continued follow-up and maintaining a high index of suspicion when patients are not improving as expected. The clinical picture in this athlete evolved over time, and the pursuit of more advanced imaging ultimately led to the correct diagnosis and appropriate management. It also highlights the importance of planning for adequate postoperative follow-up, if needed, through the use of a carbon fiber intramedullary rod. Further research is needed to evaluate whether a true association exists between osteoid osteomas and stress fractures and whether one condition may predispose patients to developing the other.

Additional Information

Author Contributions

All authors have reviewed the final version to be published and agreed to be accountable for all aspects of the work.

Concept and design: Dustin Marshall, Jonathan R. Guin, Earl R. Stewart

Acquisition, analysis, or interpretation of data: Dustin Marshall, Jonathan R. Guin, Earl R. Stewart

Drafting of the manuscript: Dustin Marshall, Jonathan R. Guin, Earl R. Stewart

Critical review of the manuscript for important intellectual content: Dustin Marshall, Jonathan R. Guin, Earl R. Stewart

Disclosures

Human subjects: Informed consent for treatment and open access publication was obtained or waived by all participants in this study. **Conflicts of interest:** In compliance with the ICMJE uniform disclosure form, all authors declare the following: **Payment/services info:** All authors have declared that no financial support was received from any organization for the submitted work. **Financial relationships:** All authors have declared that they have no financial relationships at present or within the previous three years with any organizations that might have an interest in the submitted work. **Other relationships:** All authors have declared that there are no other relationships or activities that could appear to have influenced the submitted work.

References

1. McInnis KC, Ramey LN: High-risk stress fractures: diagnosis and management. PM R. 2016, 8:S113-S124.

10.1016/j.pmrj.2015.09.019

2. Lohrer H: [High-risk stress fractures in competitive athletes] . Unfallchirurgie (Heidelb). 2023, 126:848-855. 10.1007/s00113-023-01339-4
3. Prasad S, Nassar M, Azam A: CaReL guidelines: a consensus-based guideline on case reports and literature review (CaReL). Barw Med J. 2024, 2: 10.58742/bmj.v2i2.89
4. Fredericson M, Jennings F, Beaulieu C, Matheson GO: Stress fractures in athletes. Top Magn Reson Imaging. 2006, 17:309-325. 10.1097/RMR.0b013e3180421c8c
5. Mallee WH, Weel H, van Dijk CN, van Tulder MW, Kerkhoffs GM, Lin CW: Surgical versus conservative treatment for high-risk stress fractures of the lower leg (anterior tibial cortex, navicular and fifth metatarsal base): a systematic review. Br J Sports Med. 2015, 49:370-376. 10.1136/bjsports-2013-093246
6. Feldman JJ, Bowman EN, Phillips BB, Weinlein JC: Tibial stress fractures in athletes. Orthop Clin North Am. 2016, 47:733-741. 10.1016/j.ocl.2016.05.015
7. Lara PH, Cabello GL, Domingues DC, Bezerra DC, de Albuquerque AB, Belangero PS: Surgical versus conservative treatment for high-risk stress fractures of the lower leg (anterior tibial cortex, navicular and fifth metatarsal base): a systematic review. Acta Ortop Bras. 2025, 33:e290433. 10.1590/1413-785220253305e290433
8. Tepelenis K, Skandalakis GP, Papathanakos G, et al.: Osteoid osteoma: an updated review of epidemiology, pathogenesis, clinical presentation, radiological features, and treatment option. In Vivo. 2021, 35:1929-1938. 10.21873/invivo.12459
9. Shu M, Ke J: The surgical management of osteoid osteoma: a systematic review . Front Oncol. 2022, 12:935640. 10.3389/fonc.2022.935640
10. Schulze W, Richter J, Kuhnen C, Henschel MG, Muhr G: Osteoid osteoma that occurred in a former fracture site. Clin Orthop Relat Res. 2001, 387:200-206. 10.1097/00003086-200106000-00027
11. Soon M, Low CK, Chew J: Osteoid osteoma after a stress fracture of the tibia: a case report . Ann Acad Med Singap. 1999, 28:877-878.
12. Netzer PA: Mid-anterior tibial stress fracture in a female elite athlete: a case report . Eur J Trauma Emerg Surg. 2007, 33:96-98. 10.1007/s00068-007-6068-y
13. Chun-Pu Chu, Bellin D: Insufficiency fracture of the tibial plateau: a disease of rare diagnosis . J Osteopor Phys Act. 2015, 3:1-3.
14. Connolly LP, Connolly SA, Treves ST: Differentiation of anterior tibial stress fracture from osteoid osteoma . Clin Nucl Med. 2001, 26:54-56. 10.1097/00003072-200101000-00013
15. Krätzig T, Mende KC, Mohme M, et al.: Carbon fiber-reinforced PEEK versus titanium implants: an in vitro comparison of susceptibility artifacts in CT and MR imaging. Neurosurg Rev. 2021, 44:2163-2170. 10.1007/s10143-020-01384-2
16. Bhashyam AR, Yeung C, Sodhi A, Xu RF, Groot OQ, Kelly S, Lozano-Calderon S: Titanium vs. carbon fiber-reinforced intramedullary nailing for humeral bone tumors. J Shoulder Elbow Surg. 2023, 32:2286-2295. 10.1016/j.jse.2023.04.023