Cureus
Part of SPRINGER NATURE

Open Access Case Report

Peutz-Jeghers Syndrome in Children: A Case Series

Hidaya Zitan [1], Ismail Benomar [1], Loubna Aqqaoui [1], Houda Oubejja [1], Fouad Ettayebi [2]

1. Department of Pediatric Surgical Emergencies, Children's Hospital of Rabat, Ibn Sina University Hospital Center, Faculty of Medicine and Pharmacy, Mohammed V University, Rabat, MAR 2. Department of Pediatric Surgical Emergencies, Children's Hospital of Rabat, Ibn Sina University Hospital Center,Faculty of Medicine and Pharmacy, Mohammed V University, Rabat, MAR

Corresponding author: Hidaya Zitan, hidayazitan@gmail.com

Review began 09/16/2026
Review ended 10/18/2026
Published 11/03/2026

© Copyright 2026
Zitan et al. This is an open access article distributed under the terms of the Creative Commons Attribution License CC-BY 4.0., which permits unrestricted use, distribution, and reproduction in any medium, provided the original author and source are credited.

DOI: 10.7759/cureus.119045

Abstract

Peutz-Jeghers syndrome (PJS) is an uncommon autosomal dominant disorder characterized by the occurrence of hamartomatous polyps throughout the gastrointestinal (GI) system and characteristic mucocutaneous pigmentation, including dark spots on the lips, oral mucosa, and fingertips. The syndrome is caused by mutations in the STK11 gene, which encodes a tumor suppressor that serves key roles in regulating cell proliferation and differentiation. Herein, we present four cases of PJS patients handled at the Pediatric Surgical Emergency Department during the period from 2010 to 2023.

The purpose of this study is to emphasize this rare condition in children and to describe the diagnostic and therapeutic maneuvers. The clinical features of patients with PJS in childhood are frequently characterized by GI manifestations, which are usually the first symptoms of the disease. The diagnosis is a histological one and according to clear-cut criteria. PJS carries a high risk of malignant transformation, either at or apart from the GI tract, proving the importance of careful surveillance according to the established guidelines. Treatment should be as conservative as possible to prevent repeated intestinal resections and maintain digestive tract continuity, particularly in children who are still growing.

Categories: Genetics, Pediatric Surgery, Gastroenterology
Keywords: child, intestinal invagination, lentiginosis, peutz-jeghers syndrome, polyposis

Introduction

Peutz-Jeghers syndrome (PJS) is a rare autosomal dominant hereditary disorder, first described by Peutz in 1921 and later by Jeghers in 1949 [1,2]. It is characterized by the presence of hamartomatous polyps throughout the gastrointestinal (GI) tract, particularly in the small intestine, and by distinctive mucocutaneous pigmentation, typically dark brown or blue-gray macules around the lips, oral mucosa, and digits. The underlying genetic defect is usually a germline mutation in the STK11 (LKB1) gene, a tumor suppressor involved in the regulation of cell growth and differentiation [3].

The estimated incidence of PJS ranges from one in 8,300 to one in 120,000 individuals [4], with approximately one-third of cases diagnosed before the age of 10. In children, the disease often presents with digestive complications, such as bleeding, anemia, or bowel obstruction due to intussusception, which may reveal the underlying condition [3].

Since the 1980s, PJS has been recognized as a cancer predisposition syndrome, associated with a significantly elevated lifetime risk of both GI and extra-GI malignancies, including cancers of the breast, pancreas, ovaries, and testes. These cancers often occur at younger ages compared to the general population. Therefore, early diagnosis, regular surveillance, and a multidisciplinary management approach are crucial to improving outcomes, preventing complications, and preserving the quality of life, especially in pediatric patients [5].

In this report, we present a case series of four pediatric patients with PJS managed at our institution, illustrating the diversity of clinical presentations and the diagnostic and surgical management challenges encountered in this age group.

Case Presentation

Case 1

Presentation

A four-year-old boy was admitted with a prolapsed anal mass. The clinical course was characterised by episodic abdominal pain, rectal bleeding and weight loss.

Examination

Physical examination showed a protruding mass embedded with small polyps (Figure 1) and mucocutaneous lentigines at the lips (Figure 2).



FIGURE 1: Clinical photograph of Case 1 obtained at presentation showing a large, protruding anal mass studded with small polyps, corresponding to the ileocolic intussusception subsequently confirmed on imaging.



FIGURE 2: Characteristic dark brown mucocutaneous lentigines on the upper lip of the patient; a hallmark clinical finding of Peutz-Jeghers syndrome.

Investigations

Imaging indicated an intussusception of the ileocolic variety due to a colonic polyp (Figure 3).

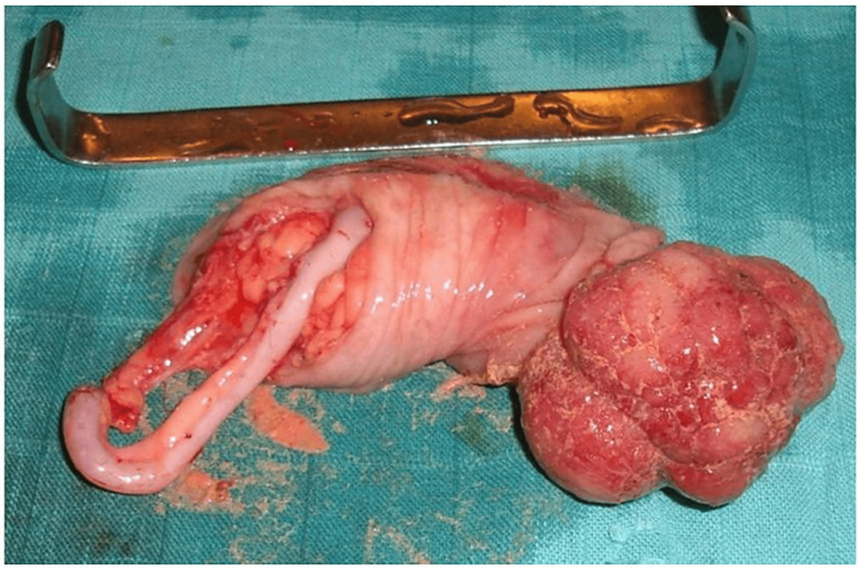

FIGURE 3: Gross specimen from the ileocolectomy performed on Case 1 showing a lobulated, cauliflower-like polypoid mass at the ileocecal junction, representing the lead point of the ileocolic intussusception.

Diagnosis

Biopsy revealed a Peutz-Jeghers-like hamartomatous polyp, without dysplasia. The patient was found to be carrying a heterozygous STK11 gene mutation determined by genetic testing, confirming the diagnosis of PJS.

Treatment

The patient received an initial hydrostatic reduction and a planned ileocolectomy for recurrence. Surgery was through a transumbilical incision and recovery was uneventful (Figure *4*).



FIGURE 4: Postoperative photograph showing the sutured transumbilical incision in Case 1, illustrating the cosmetically favorable single-site surgical approach.

Follow-Up

Nine months later, the patient experienced a resolving subocclusive episode. One year afterwards, the patient showed bilateral gynecomastia, and a calcifying large cell Sertoli cell tumor of the testicles, limited to the testicular parenchyma, was diagnosed. Hormonal therapy was advised but refused by the father, after which the patient was lost to follow-up.

Case 2

Presentation

A four-year-old girl (current age 13 years) with a family history (affected elder brother) presented with an anal prolapsed mass. Her past medical history was significant for rectal prolapse since the age of two, which was later complicated by abdominal pain and mucoid bloody diarrhea.

Examination

The lower lip lentiginosis and protruding polypoid anal mass were noted on examination (Figures *5*, *6*).



FIGURE 5: Clinical photograph of Case 2 showing lentiginosis of the lower lip and gingival mucosa, a characteristic mucocutaneous finding of Peutz-Jeghers syndrome.



FIGURE 6: Clinical photograph of Case 2 obtained at presentation showing a large, lobulated, hemorrhagic polypoid mass prolapsing through the anus.

Investigation

Radiologic and endoscopic evaluations identified a large sigmoid polyp located 20 cm from the anal verge. Another mid-sized polyp at 10 cm from the gastric polyps appeared on upper endoscopy. A rectal polypoid lesion was seen on a barium enema. Blood tests were normal.

Diagnosis

Genetic testing revealed a 46-bp deletion in exon 5 of the STK11 gene, which diagnosed PJS (Table *1*).

Investigation	Findings
Abdominal radiography	No air-fluid levels
Abdominal ultrasound	No sonographic evidence of intussusception
Colonoscopy	Large sigmoid polyp, 20 cm from the anal verge. Medium-sized polyp, 10 cm from the anal verge. Near-normal colonic mucosa
Upper gastrointestinal endoscopy	Two small sessile polyps on the gastric mucosa of the greater curvature. Markedly congestive gastric mucosa. Normal duodenum, duodenal bulb, cardia, and esophagus
Double-contrast barium enema	Good passage of contrast through a colon of normal caliber. Small anterior rectal lesion a few centimeters from the anal verge, suggestive of a polyp. No other identifiable abnormalities
Standard biological test	Unremarkable

TABLE 1: Case 2's paraclinical investigations

Treatment

The patient underwent a transanal polypectomy (Figure 7) and resection of 5 cm sigmoid via left pseudo-Pfannenstiel incision with termino-terminal anastomosis (Figure 8). The postoperative course was uneventful.

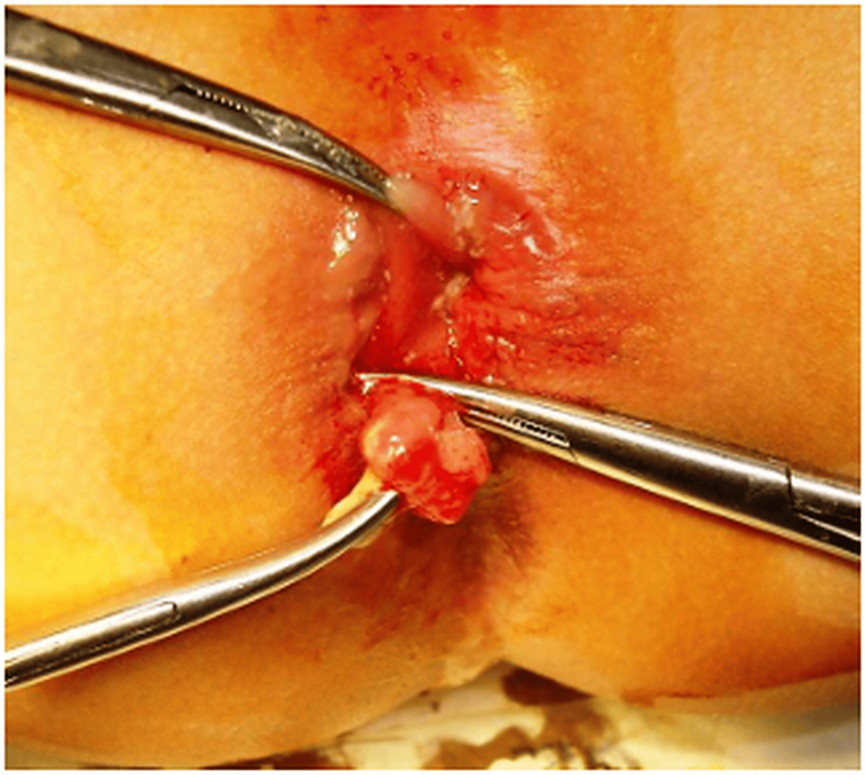

FIGURE 7: Intraoperative photograph of Case 2 showing the polypoid lesion grasped with forceps during transanal polypectomy.

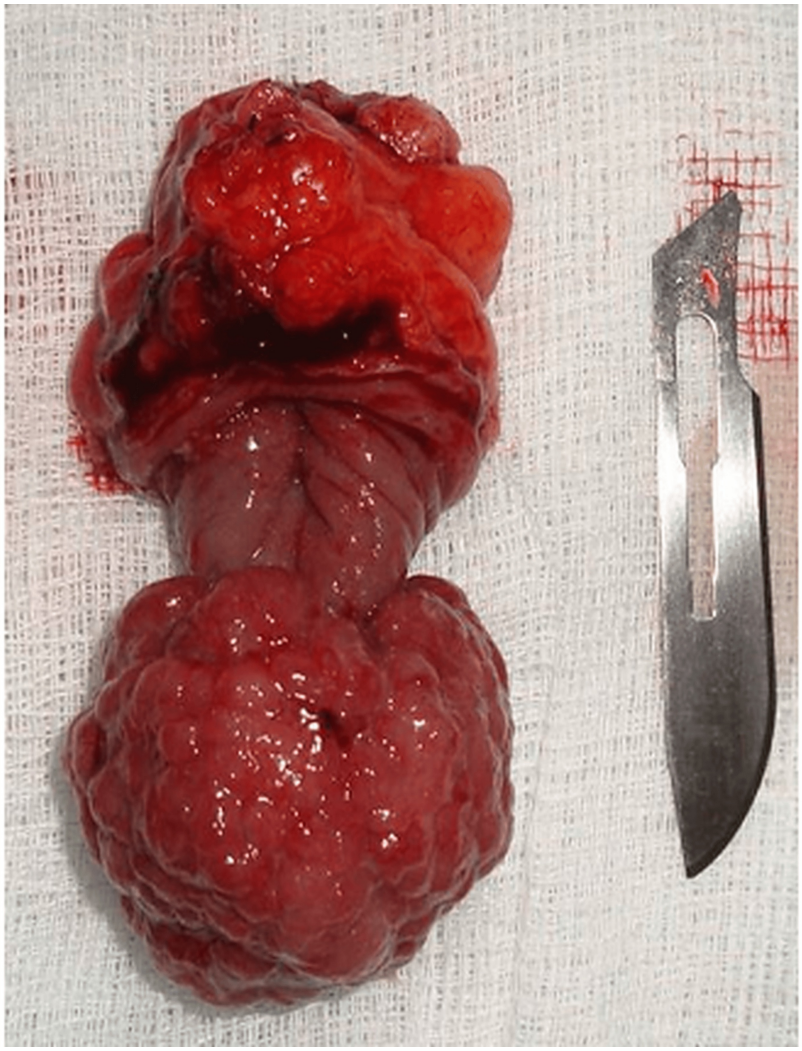

FIGURE 8: Gross specimen from the sigmoid resection performed in Case 2, showing a 3.5-cm lobulated hamartomatous polyp.

Histopathology

Histopathology demonstrated a 3.5-cm hamartomatous polyp with mucin-secreting villous epithelium, without atypia, along with dilated vessels and a lymphoplasmacytic infiltrate with lymphoid follicles.

Case 3

Presentation

A nine-year-old boy (now aged 16) with past medical history of carbon monoxide poisoning at age three and five months presented to our institution through the emergency department for one week of severe abdominal pain associated with several episodes of bilious vomiting and bloody diarrhea and with obvious signs of malnutrition and fever (38°C).

Examination

On clinical examination, he had diffuse abdominal guarding with lentiginosis of the lower lip (Figure 9) but no palpable mass.



FIGURE 9: Clinical photograph of Case 3 showing dark mucocutaneous lentigines on the lower lip.

Investigations

Imaging showed small bowel air-fluid levels and a crescent-shaped gas collection beneath the liver on an upright abdominal X-ray, consistent with pneumoperitoneum. Abdominal ultrasonography revealed a 6 cm-long ileocolic or colocolic intussusception, evidence of perforation and moderate (but impure) abdominal effusion (Table *2*).

Investigation	Findings
Abdominal radiography	Central air-fluid levels, consistent with small-bowel origin. Subphrenic (pre-hepatic) gas crescent, consistent with pneumoperitoneum
Abdominal ultrasound	Acute left para-umbilical ileocolic/colocolic intussusception, 55 mm in diameter, extending over 6 cm; probably perforated. Moderate, impure peritoneal effusion in the pouch of Douglas and interloop spaces
Preoperative blood test	Normal electrolyte panel

TABLE 2: Case 3's paraclinical investigations

Treatment

Emergency laparotomy revealed an ileo-ileal intussusception with a tiny perforation of the proximal jejunum, 15 cm distal to the Treitz's ligament, next to a bunch of polyps (Figure *10*).

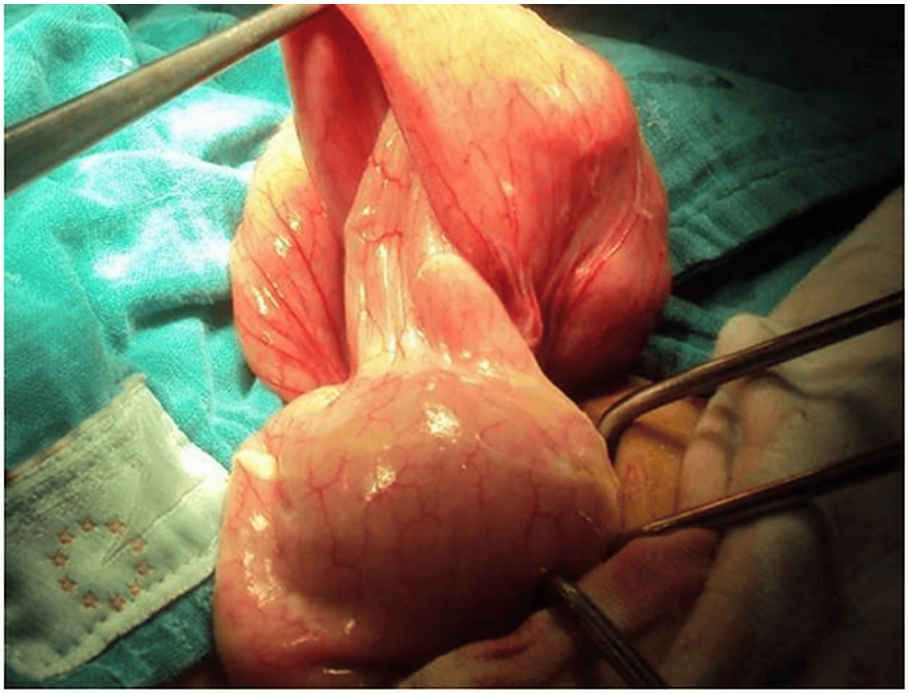

FIGURE 10: Intraoperative photograph of Case 3 obtained during emergency laparotomy showing the ileo-ileal intussusception with adjacent bowel loops exposed.

A segmental jejunal resection was done with peritoneal lavage and a left jejunostomy. Two weeks later, the digestive system was put back together.

Histopathology

Pathological examination revealed three large hamartomatous polyps, one with findings of infarction and perforation (Figure *11*).



FIGURE 11: Gross specimen from the segmental jejunal resection performed on Case 3 showing multiple hamartomatous polyps, one of which (right, dark/yellow area) shows evidence of infarction and perforation.

Ruler shown for scale (centimeters).

Follow-Up

The patient´s postoperative course was uneventful, and he visited us one month after the procedure in good clinical condition. Endoscopy of the upper and lower GI tracts was scheduled, and the patient underwent genetic counseling to evaluate possible familial cases. The control was adequate and in accordance with international PJS therapy guidelines [6].

Case 4

Presentation

A four-year-old girl with a history of refractory anemia on iron therapy presented with a three-year history of intermittent, diffuse abdominal pain, without melena or rectal bleeding. Her symptoms progressively worsened, with increasing pain followed by the onset of rectal bleeding.

Examination

Physical examination revealed cutaneous and mucosal pallor, generalized abdominal tenderness, and a palpable mass in the left iliac fossa. Mucocutaneous examination showed multiple lentigines on both lips and the oral mucosa (Figure *12*).



FIGURE 12: Clinical photograph of Case 4 showing multiple lentigines on both lips and the oral mucosa.

Investigations

Plain abdominal radiography showed gastric stasis (Figure *13*), and abdominal ultrasound demonstrated an ileo-ileal intussusception with a target sign formed by three superimposed, thickened intestinal layers (Figures *14*, *15*),

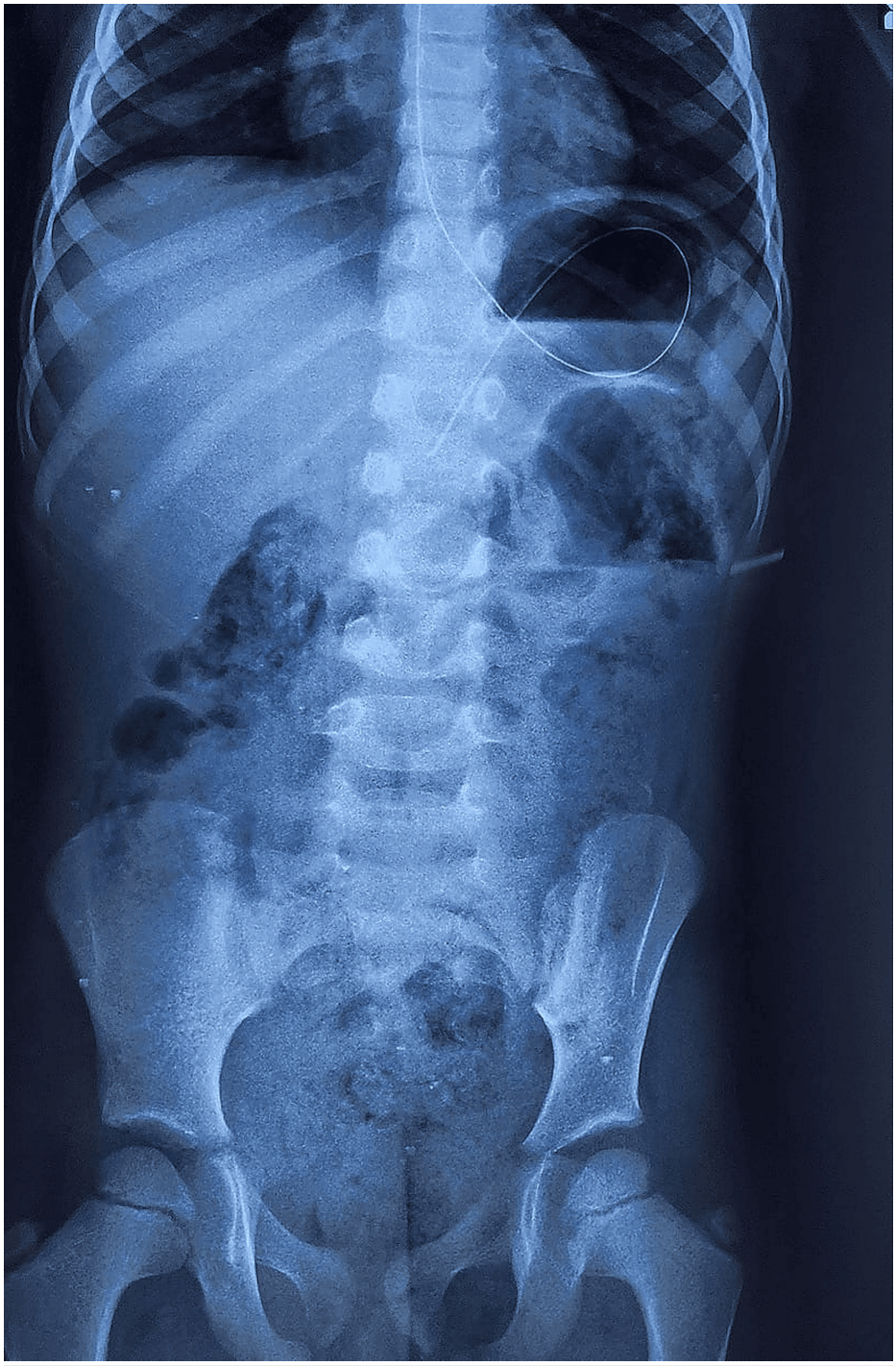

FIGURE 13: Plain, upright abdominal radiograph of Case 4 showing gastric stasis.

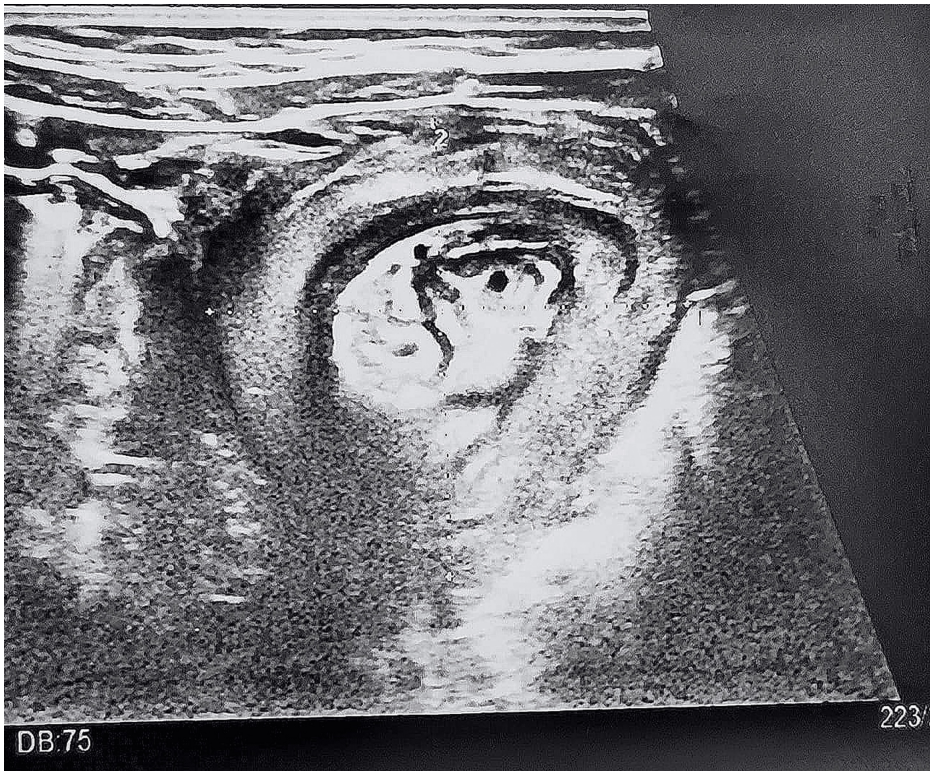

FIGURE 14: Transverse ultrasound section of the abdomen of Case 4 showing concentric alternating hyperechoic and hypoechoic rings, the "target" (doughnut) sign corresponding to the multiple concentric bowel wall layers of the intussuscipiens surrounding the intussusceptum, confirming the diagnosis of intussusception.

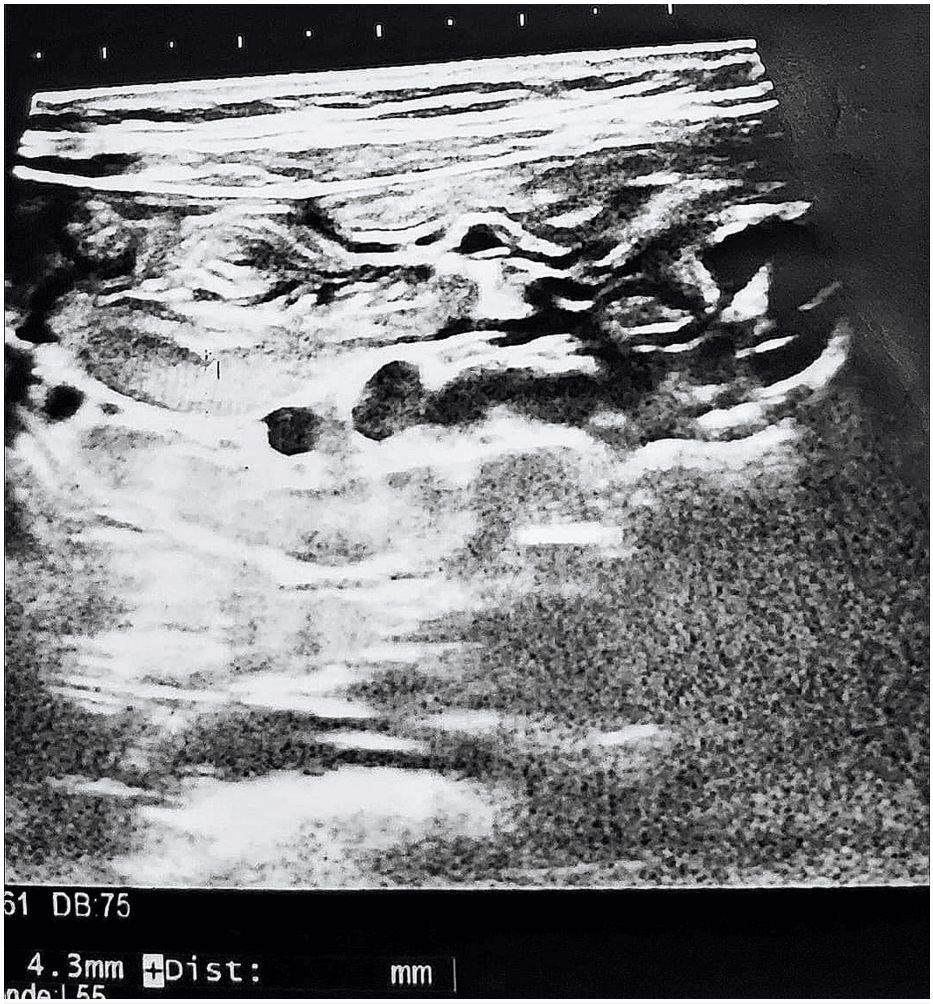

FIGURE 15: Longitudinal ultrasound section of the abdomen of Case 4 demonstrating alternating hyperechoic and hypoechoic parallel layers, the "sandwich" or pseudo-kidney sign, corresponding to the telescoped intussusceptum within the intussuscipiens, with a measured length of 36.9 mm, consistent with intussusception.

Further evaluation with magnetic resonance enterography revealed intussusception secondary to a suspicious, stenosing ileal wall thickening measuring 22 mm, with upstream bowel distension.

Treatment

Exploratory laparotomy revealed an ileo-ileal intussusception with a palpable polyp within the intussuscepted segment (Figures *16*, *17*).



FIGURE 16: Intraoperative photograph obtained during exploratory laparotomy performed on Case 4 showing the ileo-ileal intussusception with a palpable polyp within the intussuscepted segment.

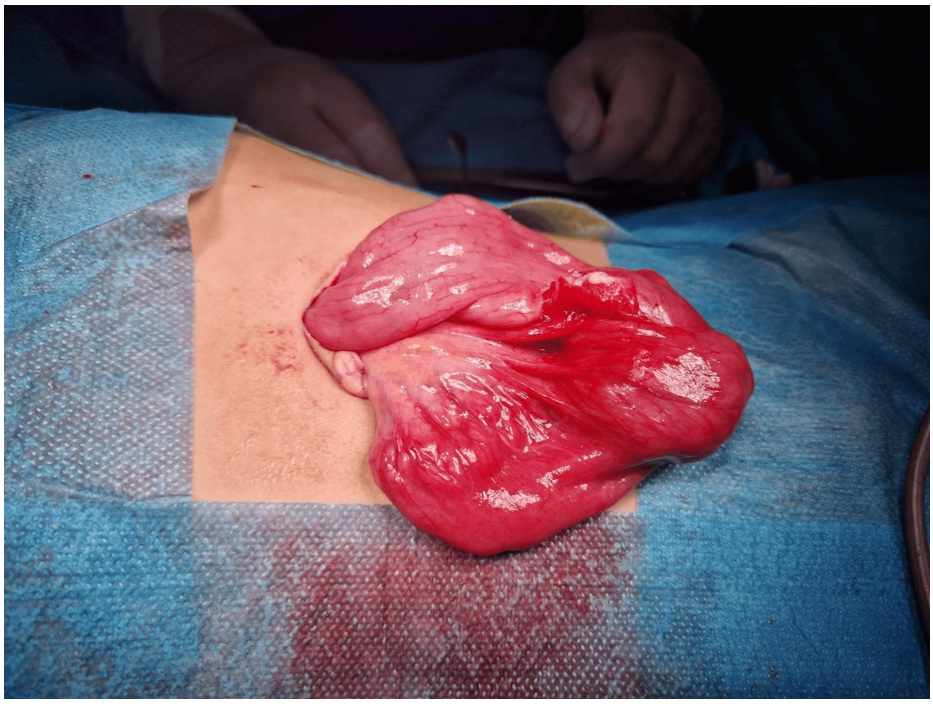

FIGURE 17: Intraoperative photograph of Case 4 showing the bowel loop after manual reduction of the intussusception.

Manual reduction was performed, followed by segmental resection of the involved loop and end-to-end anastomosis; palpation of the remaining bowel loops did not reveal any additional polyps.

Follow-Up

The postoperative course was uneventful (Figure *18*, *19*).



FIGURE 18: Postoperative photograph of the transumbilical incision at the end of Case 4's procedure.



FIGURE 19: Clinical appearance of the transumbilical incision at the 10-day postoperative follow-up in Case 4.

Histopathology

Histopathological examination confirmed the diagnosis of PJS, with hamartomatous polyps identified on the resected specimen (Figure *20*).



FIGURE 20: Resected ileal specimen showing a hamartomatous polyp following segmental resection in Case 4.

A ruler is shown for scale (centimeters).

A comparative summary of the four cases of PJS is presented in Table 3.

Variable	Case 1	Case 2	Case 3	Case 4
Age/Sex	Four-year-old boy	Four-year-old girl (now 13)	Nine-year-old boy (now 16)	Four-year-old girl
Family history	None reported	Affected elder brother	None reported	None reported
Presenting features	Prolapsed anal mass, episodic abdominal pain, rectal bleeding, weight loss	Prolapsed anal mass, chronic rectal prolapse, abdominal pain, mucoid bloody diarrhea	Severe abdominal pain, bilious vomiting, bloody diarrhea, malnutrition, fever	Refractory anemia, chronic intermittent abdominal pain, rectal bleeding, palpable left iliac fossa mass
Mucocutaneous pigmentation	Lips	Lower lip, gingival mucosa	Lower lip	Both lips, oral mucosa
Polyp location	Ileocecal junction	Sigmoid colon, rectum, stomach	Proximal jejunum	Ileum
Major complication	Ileocolic intussusception	Rectal/anal prolapse	Ileo-ileal intussusception with perforation	Ileo-ileal intussusception
Genetic/histopathological confirmation	STK11 heterozygous mutation; hamartomatous polyp	46-bp deletion in exon 5 of STK11; hamartomatous polyp	Hamartomatous polyps (histopathology only)	Hamartomatous polyps (histopathology only)
Surgical treatment	Hydrostatic reduction, then ileocolectomy (recurrence)	Transanal polypectomy + sigmoid resection	Segmental jejunal resection + jejunostomy, continuity restored at two weeks	Manual reduction + segmental resection with end-to-end anastomosis
Follow-up	Subocclusive episode (nine months); Sertoli cell tumor (one year); lost to follow-up	Uneventful	Uneventful	Uneventful, 10-day wound check

TABLE 3: Comparative summary of the four cases of Peutz-Jeghers syndrome

Discussion

PJS is characterized by hamartomatous polyps throughout the GI tract, sparing the esophagus, together with typical mucocutaneous pigmented lesions [3]. These lesions most commonly present as brown to black macules on the lips and oral mucosa, and may also involve the digits, palms, soles, and occasionally the nasal, conjunctival, or rectal mucosa. All four of our patients exhibited typical pigmentation of the lips, with additional involvement of the gingiva and oral mucosa noted in Cases 2 and 4.

GI polyps are the second major feature of the syndrome and may be the first manifestation of the disease when they present with complications such as digestive bleeding or bowel obstruction, as illustrated by our series. These polyps are hamartomas, most commonly involving the small intestine (predominantly the jejunum), but also the colon and stomach. No clear correlation has been established between polyp size and malignant potential, although it is estimated that malignant transformation occurs in approximately two of every 75 polyps [7]. Pediatric presentations show no significant clinical differences compared with those occurring in adults [8].

The diagnosis of PJS is established when any of the following criteria are met: (a) three or more histologically confirmed hamartomatous polyps, typically showing a characteristic arborizing pattern of smooth muscle fibers with goblet and Paneth cells; (b) any number of hamartomatous polyps in a patient with a family history of PJS; (c) typical mucocutaneous pigmentation in combination with a family history of PJS; or (d) the association of hamartomatous polyps and mucocutaneous pigmentation, even in the absence of a known family history [5,7,8]. In our series, the diagnosis was established in all four patients based on the combination of histologically confirmed hamartomatous polyps and characteristic mucocutaneous pigmentation (criterion d); in Case 2, a positive family history of an affected sibling further supported the diagnosis (criterion b).

Management of PJS is guided by polyp location, clinical presentation, and locally available expertise [6,8]. In our series, three of the four patients (Cases 1, 3, and 4) presented with intussusception requiring surgical

intervention [5]. In Case 1, hydrostatic reduction was performed initially, followed by elective ileocolectomy after recurrence. In Case 3, emergency laparotomy for a perforated intussusception required segmental jejunal resection with a temporary jejunostomy, bowel continuity being restored two weeks later. In Case 4, the intussuscepted segment was reduced intraoperatively, followed by segmental resection and primary end-to-end anastomosis. The remaining patient (Case 2) presented with rectal prolapse secondary to a large sigmoid polyp and was managed by transanal polypectomy and sigmoid resection.

There is currently no clear consensus on the optimal surveillance interval for patients with PJS; nevertheless, regular monitoring is generally recommended even in asymptomatic individuals. This typically includes annual clinical and laboratory assessment together with abdominal (particularly pancreatic) and pelvic or testicular ultrasound, along with a complete endoscopic evaluation, small bowel follow-through, and enterography every two to three years to detect complications or early signs of malignancy [6]. Long-term adherence to surveillance remains essential: in our series, Case 3 continued follow-up in accordance with international guidelines, whereas Case 1 was lost to follow-up after the family declined recommended hormonal therapy, underscoring the importance of sustained family counseling in this population.

Conclusions

PJS should be considered in any child presenting with recurrent intussusception, unexplained GI bleeding, or characteristic mucocutaneous pigmentation. This descriptive series of four cases illustrates the varied clinical presentations of the disease in childhood, ranging from anal prolapse to life-threatening bowel perforation, and underscores the role of surgery specifically in the management of acute or complicated presentations, rather than in the overall management of PJS. Early recognition of the syndrome's cutaneous markers, combined with histopathological confirmation, allows for timely diagnosis and initiation of long-term, multidisciplinary surveillance, with conservative management remaining appropriate in the absence of acute complications. Given the syndrome's hereditary nature and elevated cancer risk, a multidisciplinary approach involving pediatric surgeons, gastroenterologists, geneticists, and sustained family counseling is essential to optimize long-term outcomes and ensure adherence to surveillance protocols. Given the limited sample size and descriptive nature of this report, these findings should not be regarded as representative of the broader pediatric PJS population.

Additional Information

Author Contributions

All authors have reviewed the final version to be published and agreed to be accountable for all aspects of the work.

Concept and design: Hidaya Zitan, Ismail Benomar, Loubna Aqqaoui, Houda Oubejja, Fouad Ettayebi

Acquisition, analysis, or interpretation of data: Hidaya Zitan, Ismail Benomar, Loubna Aqqaoui, Houda Oubejja, Fouad Ettayebi

Drafting of the manuscript: Hidaya Zitan, Ismail Benomar, Loubna Aqqaoui, Houda Oubejja, Fouad Ettayebi

Critical review of the manuscript for important intellectual content: Hidaya Zitan, Ismail Benomar, Loubna Aqqaoui, Houda Oubejja, Fouad Ettayebi

Supervision: Hidaya Zitan, Ismail Benomar, Loubna Aqqaoui, Houda Oubejja, Fouad Ettayebi

Disclosures

Human subjects: Informed consent for treatment and open access publication was obtained or waived by all participants in this study. **Conflicts of interest:** In compliance with the ICMJE uniform disclosure form, all authors declare the following: **Payment/services info:** All authors have declared that no financial support was received from any organization for the submitted work. **Financial relationships:** All authors have declared that they have no financial relationships at present or within the previous three years with any organizations that might have an interest in the submitted work. **Other relationships:** All authors have declared that there are no other relationships or activities that could appear to have influenced the submitted work.

References

1. Peutz JL: Very remarkable case of: familial polyposis of mucous membrane of intestinal tract and nasopharynx accompanied by peculiar pigmentations of skin and mucous membrane. Nederl Maandschr Geneesk. 1921, 10:134-46.
2. Jeghers H, McKusick VA, Katz KH: Generalized intestinal polyposis and melanin spots of the oral mucosa, lips and digits; a syndrome of diagnostic significance. N Engl J Med. 1949, 241:993, illust; passim. 10.1056/NEJM194912222412501

3. McGarrity TJ, Amos CI, Baker MJ: Peutz-Jeghers syndrome. GeneReviews. Adam MP, Feldman J, Mirzaa GM, et al. (ed): University of Washington, Seattle, WA; 2001.
4. Tacheci I, Kopacova M, Bures J: Peutz-Jeghers syndrome. Curr Opin Gastroenterol. 2021, 37:245-54. 10.1097/MOG.0000000000000718
5. Sherman S, Menon G, Krishnamurthy K: Peutz-Jeghers Syndrome. StatPearls [Internet], StatPearls Publishing, Treasure Island, FL; 2025.
6. Wagner A, Aretz S, Auranen A, et al.: The management of Peutz-Jeghers syndrome: European Hereditary Tumour Group (EHTG) guideline. J Clin Med. 2021, 10:473. 10.3390/jcm10030473
7. Beggs AD, Latchford AR, Vasen HF, et al.: Peutz-Jeghers syndrome: a systematic review and recommendations for management. Gut. 2010, 59:975-86. 10.1136/gut.2009.198499
8. Yamamoto H, Sakamoto H, Kumagai H, et al.: Clinical guidelines for diagnosis and management of Peutz-Jeghers syndrome in children and adults. Digestion. 2023, 104:335-47. 10.1159/000529799