Cureus
Part of SPRINGER NATURE

Open Access Case Report

Published via Centro Médico Episcopal San Lucas - Research Channel

Embryonal Rhabdomyosarcoma of the Cervix in a 13-Year-Old Girl: A Rare Pediatric Gynecologic Malignancy

Received 10/26/2026
Review began 11/01/2026
Review ended 11/23/2026
Published 11/24/2026

© Copyright 2026
Escobales-Cabrera et al. This is an open access article distributed under the terms of the Creative Commons Attribution License CC-BY 4.0., which permits unrestricted use, distribution, and reproduction in any medium, provided the original author and source are credited.

DOI: 10.7759/cureus.120192

Paola L. Escobales-Cabrera [1], Hillary N. Mercado Figueroa [1], Luis E. Morales-Jimenez [1], Inevy I. Seguinot-Tarafa [2], Alexandra Ortiz Oramas [1]

1. Obstetrics and Gynecology, Centro Médico Episcopal San Lucas, Ponce, PRI 2. Obstetrics and Gynecology, University of Puerto Rico, Medical Sciences Campus, San Juan, PRI

Corresponding author: Luis E. Morales-Jimenez, luimorales24@stu.psm.edu

Abstract

Embryonal rhabdomyosarcoma (ERMS) is the most prevalent soft tissue sarcoma in the pediatric population. Although most genital tract rhabdomyosarcomas are of the embryonal subtype, frequently presenting as the botryoid variant, cervical involvement is exceptionally rare and is typically reported in women in their late teens and early 20s. A 13-year-old gravida 0 adolescent with no significant medical history or history of sexual activity presented with several months of persistent, profuse abnormal vaginal discharge. Pelvic examination revealed a large polypoid vaginal mass. Pelvic MRI and serum tumor markers were obtained, followed by biopsy. Initial pathology was nondiagnostic, prompting fertility-sparing surgical excision of the mass. Histopathologic evaluation confirmed ERMS of the uterine cervix. Molecular testing demonstrated a FOXO1 fusion-negative tumor harboring a pathogenic germline DICER1 variant and a somatic TP53 mutation. The patient was classified as intermediate-risk disease and treated with multimodal therapy consisting of fertility-preserving surgery followed by chemotherapy and radiotherapy according to the Children's Oncology Group ARST1431 protocol. She completed treatment without major complications and achieved a complete clinical and radiographic response. Cervical ERMS is a rare pediatric gynecologic malignancy that should be considered in adolescents presenting with persistent abnormal vaginal discharge or a cervical/vaginal mass. Early recognition, prompt histopathologic diagnosis, and multidisciplinary management, including fertility-preserving surgery when feasible, are essential to optimize oncologic and reproductive outcomes. This case also underscores the importance of molecular testing, particularly evaluation for DICER1 pathogenic variants, which has implications for genetic counseling, surveillance, and long-term management of affected patients and their families.

Categories: Obstetrics/Gynecology, Oncology, Pediatrics
Keywords: case report, cervical sarcoma, embryonal rhabdomyosarcoma, fertility-sparing treatment, pediatric gynecologic oncology

Introduction

Rhabdomyosarcoma (RMS) is the most common soft tissue sarcoma of childhood, arising from primitive mesenchymal cells. It represents approximately 50% of pediatric soft tissue sarcomas and 3% of childhood malignancies and has an annual incidence of 4.6 cases per million individuals younger than 20 years, translating to approximately 350 cases annually [1,2]. The head and neck are the most common primary sites, followed by the genitourinary tract, extremities, trunk, retroperitoneum, and other less frequent locations [3]. Within the female genital tract, RMS accounts for approximately 3.5% of cases, with this anatomical region considered a favorable primary site in RMS risk classification [4]. Cervical involvement is particularly uncommon, representing only about 0.5% of genitourinary embryonal RMS (ERMS) [5].

ERMS, including the botryoid variant, is the most common histologic subtype of RMS [6,7]. In the female genital tract, vaginal ERMS predominates in children, cervical ERMS occurs more frequently in adolescents and young adults, and uterine ERMS is most often diagnosed in postmenopausal women [7]. Patients typically present with abnormal vaginal bleeding, persistent vaginal discharge, or a polypoid cervical or vaginal mass with a characteristic grape-like appearance, also referred to as botryoid [8,9]. Histologically, ERMS is characterized by rhabdomyoblasts within a myxoid stroma and commonly demonstrates positive immunohistochemical staining for desmin, myogenin, and MyoD1 [1,10].

Several hereditary cancer predisposition syndromes have been associated with ERMS, including DICER1 syndrome, Li-Fraumeni syndrome, neurofibromatosis type 1, Costello syndrome, Beckwith-Wiedemann syndrome, and Noonan syndrome [2]. Among these, DICER1 alterations are particularly associated with cervical ERMS [2,4]. DICER1 encodes an endoribonuclease essential for microRNA processing, and pathogenic variants may occur in the context of germline or somatic mutations [11]. Recognition of germline DICER1 variants is particularly important given their association with additional neoplasms and their implications for genetic counseling and long-term surveillance [10]. Alongside DICER1, TP53 and FOXO1 have also been implicated in this type of tumor. TP53, a tumor suppressor gene involved in cell cycle

regulation, DNA damage responses, and apoptosis, has also been implicated in RMS development. Although concurrent DICER1 and TP53 alterations have been documented in gynecologic ERMS, their biological interactions and specific prognostic implications in cervical ERMS remain incompletely understood [12,13]. FOXO1 encodes a transcription factor involved in regulating metabolism, cell survival, stress resistance, and immune function. In RMS, FOXO1 fusion status is an important molecular prognostic marker because FOXO1 gene fusions are associated with more aggressive tumor behavior and poorer clinical outcomes. Accordingly, FOXO1 fusion status has been incorporated into the Children's Oncology Group (COG) risk stratification system to guide prognostic assessment and treatment decisions [14].

Management is guided by tumor stage, surgical-pathologic group, and FOXO1 fusion status, given association with poorer prognosis when present [2]. Treatment relies on multimodal therapy incorporating systemic chemotherapy with surgery, radiotherapy, or both, depending on disease extent and resectability [2]. Because cervical ERMS is a rare disease presentation, management strategies are largely derived from published case series and active treatment trials rather than disease-specific protocols.

We report the case of a 13-year-old girl with cervical ERMS harboring a pathogenic germline DICER1 variant and a somatic TP53 mutation who was successfully treated with fertility-preserving surgery followed by multimodal therapy. This case highlights the importance of early recognition, comprehensive molecular and genetic characterization, and multidisciplinary management in optimizing oncologic and reproductive outcomes.

Case Presentation

Clinical finding

A 13-year-old gravida 0 adolescent presented to the outpatient obstetrics and gynecology clinic, accompanied by her mother, with a several-month history of persistent, profuse yellowish vaginal discharge that was intermittently serosanguineous. She reported menarche at 12 years of age and denied any history of sexual activity. Her medical and surgical histories were unremarkable, and there was no known family history of gynecologic or hereditary malignancies.

Physical examination demonstrated normal external genitalia. Speculum examination revealed a large, friable, multilobulated polypoid mass occupying the upper vaginal canal and protruding from the cervix. The lesion measured greater than 5 cm and exhibited a characteristic grape-like (botryoid) appearance with copious serosanguineous discharge, raising strong clinical suspicion for ERMS.

Diagnostic assessment

Pelvic MRI demonstrated an 11.7 × 8.4 × 8.0 cm mass surrounding the cervix without invasion of the cervical stroma or vaginal wall, inguinal lymphadenopathy, or suspicious marrow signal (Figure *1*). Serum lactate dehydrogenase, alpha-fetoprotein, cancer antigen 125, carbohydrate antigen 19-9, and carcinoembryonic antigen were within normal limits.

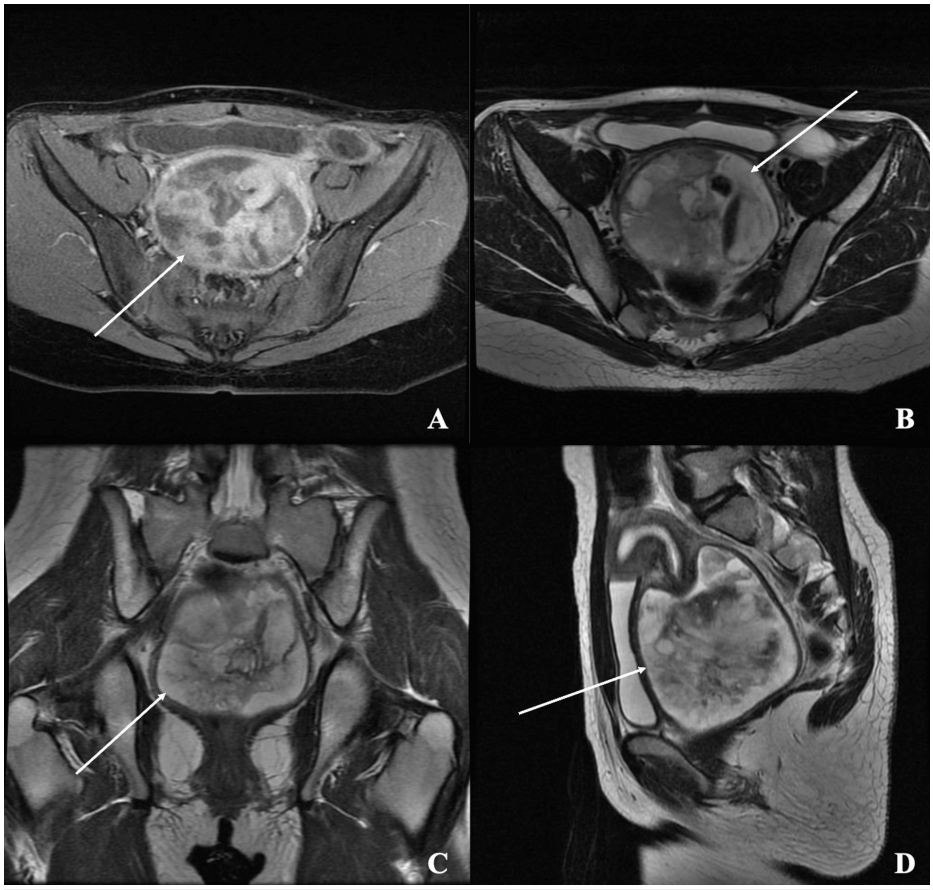

FIGURE 1: Multiplanar MRI of a large heterogeneous mass within the vaginal canal.

(A) Axial postcontrast T1-weighted image showing enhancement of the solid and septated components. (B) Axial T2-weighted image demonstrating heterogeneous solid and cystic components. (C) Coronal T2-weighted image showing the craniocaudal extent of the mass surrounding the cervix without stromal invasion. (D) Sagittal T2-weighted image demonstrating vaginal distention without invasion of adjacent structures. The mass measures approximately 11.7 cm × 8.4 cm × 8.0 cm. The white arrows in panels A-D indicate the large mass centered within the vaginal canal.

The initial office biopsy was nondiagnostic because the specimen consisted predominantly of nonviable tissue, warranting repeat tissue sampling under anesthesia. During surgery, a large pedunculated botryoid mass arising from the uterine cervix was identified without adherence to the vaginal walls (Figure *2A*). Diagnostic hysteroscopy demonstrated a normal endocervical canal and endometrial cavity without intracavitary extension or additional lesions, supporting a fertility-preserving surgical approach (Figure *3*).

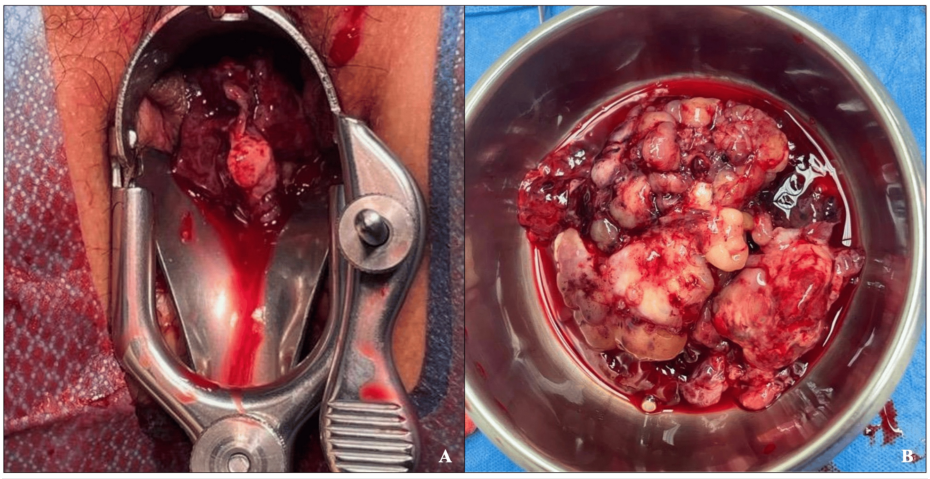

FIGURE 2: Gross appearance of the cervical mass.

(A) Examination under anesthesia with speculum visualization revealing a grape-like mass protruding from the vaginal canal. (B) Surgically excised cervical mass exhibiting a characteristic grape-like (botryoid) appearance.

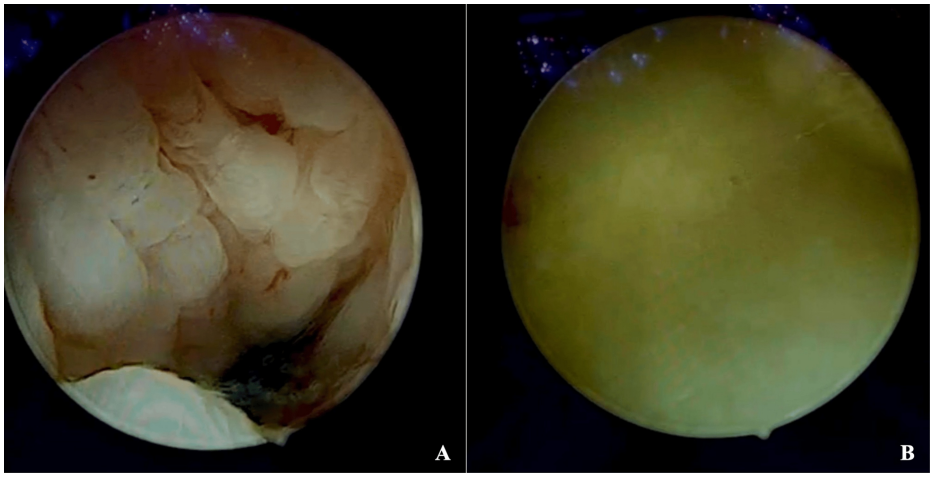

FIGURE 3: Hysteroscopic findings.

(A) Hysteroscopic view demonstrating polypoid mass arising from the cervix. (B) Hysteroscopic view of the uterine fundus without evidence of tumor involvement.

Histopathologic examination confirmed ERMS characterized by undifferentiated round to spindle cells, frequent mitotic figures, and a prominent subepithelial cambium layer. Immunohistochemistry demonstrated diffuse positivity for MyoD1 and myogenin (Figure *4*).

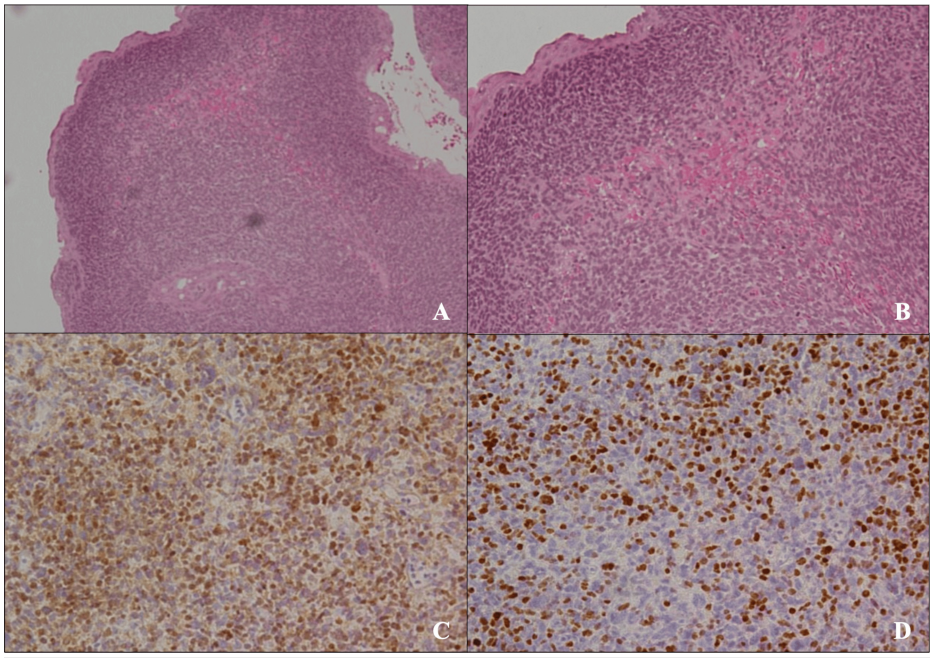

FIGURE 4: Histology and immunohistochemistry staining.

Histopathologic and immunohistochemical findings of ERMS of the cervix. (A) H&E-stained section at intermediate magnification demonstrating a densely cellular neoplasm. (B) Higher-magnification H&E section demonstrating the tumor cellular morphology. (C) Immunohistochemical staining demonstrating tumor cell positivity for MyoD1. (D) Immunohistochemical staining demonstrating tumor cell positivity for myogenin.

Therapeutic intervention

Following an examination under anesthesia (Figure *2A*) and multidisciplinary review involving pediatric oncology, gynecologic oncology, pathology, radiology, and radiation oncology, the patient underwent fertility-preserving local excision of the cervical mass while preserving the cervical architecture and surrounding reproductive organs (Figure *2B*). Molecular analysis demonstrated the absence of a FOXO1 fusion and identified pathogenic DICER1 and TP53 variants.

Postoperative CT of the chest, abdomen, and pelvis demonstrated no residual pelvic mass or metastatic disease. However, PET/CT identified a 2.4-cm hypermetabolic focus along the vaginal canal without evidence of distant metastases. Following multidisciplinary evaluation, this finding was interpreted as suggestive of residual malignancy rather than postoperative inflammatory changes and was considered for risk stratification and treatment planning.

RMS risk stratification integrates the pretreatment tumor-node-metastasis (TNM) staging system, the Intergroup Rhabdomyosarcoma Study (IRS) surgical-pathologic grouping system, and molecular characteristics status. TNM staging considers tumor location, size, lymph node involvement, and distant metastases, whereas IRS grouping assesses surgical resection and residual disease [14]. Using the abovementioned as a guide and with the previously described findings, the patient was assigned to Stage 1, surgical-pathologic Group III, intermediate-risk ERMS.

Given the rarity of pediatric cervical ERMS and the limited availability of site-specific treatment guidelines, the multidisciplinary team adopted a treatment approach informed by the COG ARST1431 protocol. Although the patient was not formally enrolled in the clinical trial, systemic chemotherapy was administered using vincristine, actinomycin-D, and cyclophosphamide alternating with vincristine and irinotecan (VI) over 42 weeks, followed by maintenance therapy.

Because residual disease remained following surgery, definitive radiotherapy to the primary tumor site was initiated during week 13 of chemotherapy. Following completion of protocol therapy, the patient received six cycles of maintenance treatment consisting of weekly vinorelbine (three doses per cycle) and continuous oral cyclophosphamide administered over 28 days during each cycle.

Follow-up and outcomes

Serial imaging demonstrated an excellent therapeutic response. Pelvic MRI obtained during week 32 of treatment showed complete radiographic resolution of the primary lesion without evidence of local

recurrence, and repeat staging studies remained negative for distant metastatic disease. The patient completed chemotherapy, radiotherapy, and maintenance therapy without major treatment-related complications. She achieved a complete clinical and radiographic response and remains under multidisciplinary surveillance with oncology and gynecologic oncology for ongoing oncologic, genetic, and fertility follow-up.

Discussion

ERMS of the uterine cervix is a rare pediatric gynecologic malignancy that occurs predominantly in adolescents and young adults and is increasingly recognized as being associated with pathogenic DICER1 variants [4,10,15]. In addition to sporadic tumors, cervical ERMS may arise in the setting of DICER1 syndrome, an autosomal dominant cancer predisposition disorder with reduced penetrance in which first-degree relatives of an affected carrier have a 50% chance of inheriting the pathogenic variant [16]. Identification of a pathogenic DICER1 variant may therefore warrant germline genetic evaluation, with potential implications for genetic counseling, cascade testing, and surveillance of affected patients and at-risk family members [10,16].

Cervical ERMS typically exhibits a botryoid growth pattern and has a more favorable prognosis than vaginal or uterine RMS when diagnosed with localized disease [5,6]. Because most patients are diagnosed during adolescence, fertility preservation has become a major consideration in treatment planning. Current recommendations from the IRS Group support fertility-sparing surgery combined with systemic chemotherapy for appropriately selected patients with localized disease, reserving more radical approaches for patients with extensive or metastatic disease [5]. Fertility-sparing approaches have been reported in selected patients with cervical ERMS, with encouraging oncologic outcomes [17]. A case report documented spontaneous conception and successful pregnancy 16 years after conservative management of cervical ERMS [18]. Nevertheless, although reproductive anatomy was preserved in our patient, future fertility cannot be guaranteed because chemotherapy and pelvic radiation may adversely affect ovarian function, uterine development, and reproductive capacity. Thus, the decision to preserve the reproductive organs reflects an effort to maintain the possibility of future fertility while prioritizing oncologic outcomes.

Given the limited evidence available to guide treatment specifically for pediatric cervical ERMS, management frequently relies on established treatment strategies for RMS at other anatomical sites. In the present case, the multidisciplinary team selected an ARST1431-based chemotherapy regimen as an individualized therapeutic approach rather than through formal trial enrollment. This distinction highlights the challenges of applying standardized risk-adapted treatment protocols to rare pediatric gynecologic malignancies.

The molecular findings in this case are particularly noteworthy. Like previously reported adolescent cases, the tumor was FOXO1 fusion-negative but harbored a pathogenic germline DICER1 variant and a somatic TP53 mutation [4,10,15]. DICER1 encodes an endoribonuclease essential for microRNA processing, and its disruption may contribute to tumorigenesis through altered gene regulation. In contrast, TP53 encodes the tumor suppressor p53, which plays a critical role in cell cycle regulation, DNA damage responses, and apoptosis. TP53 alterations have been associated with unfavorable clinical outcomes in broader RMS cohorts, although their specific prognostic significance in cervical ERMS remains uncertain [11,12].

The concurrent identification of pathogenic DICER1 and TP53 variants in our patient is of particular molecular interest, as these genes regulate distinct cellular pathways. These findings raise the possibility that disruption of the p53 pathway may represent an additional molecular event in a subset of DICER1-associated tumors. However, a direct cooperative relationship between these genes has not been established, and their combined biological and prognostic implications in cervical ERMS remain poorly understood [13]. Comprehensive molecular profiling may also identify variants that warrant evaluation for hereditary cancer predisposition syndromes, potentially informing genetic counseling, surveillance strategies, and long-term risk assessment for patients and their families.

The favorable outcome observed in this patient likely reflects several complementary factors, including localized disease at presentation, complete fertility-preserving surgical excision, risk-adapted multimodal therapy, and comprehensive molecular characterization that informed subsequent management and surveillance. This case further supports contemporary treatment strategies that prioritize organ preservation without compromising oncologic outcomes in carefully selected patients.

The principal strength of this report is the comprehensive clinicopathologic and molecular characterization of an exceptionally rare malignancy, including the identification of concurrent pathogenic DICER1 and TP53 variants in an adolescent treated successfully with fertility-preserving multimodal therapy. The detailed description of the diagnostic evaluation, multidisciplinary management, and favorable response contributes additional evidence to the limited literature on cervical ERMS. However, several limitations should be acknowledged. As a single case report, the findings cannot be generalized to all patients with cervical ERMS, particularly given the rarity and biological heterogeneity of the disease. In addition, longer follow-up will be necessary to assess long-term oncologic control, late treatment-related effects, fertility outcomes, and the clinical implications of the identified molecular variants.

Conclusions

ERMS of the uterine cervix should be considered in adolescents presenting with persistent abnormal vaginal discharge, abnormal vaginal bleeding, or a polypoid cervical mass. Early recognition and prompt histopathologic diagnosis are essential to ensuring timely and appropriate management. A multidisciplinary approach incorporating comprehensive molecular evaluation and individualized treatment planning is essential for optimizing patient outcomes, assessing recurrence risk, and guiding long-term surveillance. In carefully selected patients, fertility-preserving treatment can achieve excellent oncologic outcomes while maintaining future reproductive potential. This case highlights the importance of identifying potential hereditary cancer predisposition, as molecular findings may guide long-term surveillance, genetic counseling, and individualized patient care.

Additional Information

Author Contributions

All authors have reviewed the final version to be published and agreed to be accountable for all aspects of the work.

Acquisition, analysis, or interpretation of data: Luis E. Morales-Jimenez, Hillary N. Mercado Figueroa, Paola L. Escobales-Cabrera, Alexandra Ortiz Oramas

Drafting of the manuscript: Luis E. Morales-Jimenez, Hillary N. Mercado Figueroa, Paola L. Escobales-Cabrera, Inevy I. Seguinot-Tarafa, Alexandra Ortiz Oramas

Critical review of the manuscript for important intellectual content: Luis E. Morales-Jimenez, Hillary N. Mercado Figueroa, Paola L. Escobales-Cabrera, Alexandra Ortiz Oramas

Concept and design: Hillary N. Mercado Figueroa, Paola L. Escobales-Cabrera, Inevy I. Seguinot-Tarafa

Supervision: Alexandra Ortiz Oramas

Disclosures

Human subjects: Informed consent for treatment and open access publication was obtained or waived by all participants in this study. **Conflicts of interest:** In compliance with the ICMJE uniform disclosure form, all authors declare the following: **Payment/services info:** All authors have declared that no financial support was received from any organization for the submitted work. **Financial relationships:** All authors have declared that they have no financial relationships at present or within the previous three years with any organizations that might have an interest in the submitted work. **Other relationships:** All authors have declared that there are no other relationships or activities that could appear to have influenced the submitted work.

Acknowledgements

Paola L. Escobales-Cabrera and Hillary N. Mercado-Figueroa contributed equally to this work and should be considered co-first authors.

References

1. Menon G, Winters R, Babiker HM: Rhabdomyosarcoma. StatPearls [Internet]. StatPearls Publishing, Treasure Island (FL); 2023.
2. Childhood Rhabdomyosarcoma Treatment (PDQ®)-Health Professional Version . (2025). Accessed: July 8, 2026: https://www.cancer.gov/types/soft-tissue-sarcoma/hp/rhabdomyosarcoma-treatment-pdq.
3. Hosseini MS, Ashrafganjoei T, Sourati A, Tabatabeifar M, Mohamadianamiri M: Rhabdomyosarcoma of cervix: a case report. Iran J Cancer Prev. 2016, 9:e4383. 10.17795/ijcp-4383
4. Kebudi R, Dural O, Bay SB, et al.: Childhood rhabdomyosarcoma of the female genital tract: association with pathogenic DICER1 variation, clinicopathological features, and outcomes. J Pediatr Adolesc Gynecol. 2021, 34:449-53. 10.1016/j.jpag.2021.01.011
5. Buruiana FE, Gupta B, Singh K: Rhabdomyosarcoma of the cervix in teenagers - is fertility preservation a feasible option?. Gynecol Oncol Rep. 2020, 34:100677. 10.1016/j.gore.2020.100677
6. Imawan DK, Oesman WS, Yuseran H, Mustokoweni S, Kania N, Harsono AA, Alkaff FF: Recurrent cervical sarcoma botryoides in a 3-year-old female: approach in a limited resource setting. Am J Case Rep. 2019, 20:838-43. 10.12659/AJCR.915608
7. Hermoza AD, de Macêdo Matsushita G, Dos Santos MH, Schmidt RL, Dos Reis R, da Cunha Andrade CE: Botryoid embryonal rhabdomyosarcoma of the cervix: a case report . Int J Surg Case Rep. 2023, 102:107858. 10.1016/j.ijscr.2022.107858
8. van Sambeeck SJ, Mavinkurve-Groothuis AM, Flucke U, Dors N: Sarcoma botryoides in an infant . BMJ Case Rep. 2014, 2014:brc2013202080. 10.1136/bcr-2013-202080
9. Richardson DL: Vaginal cancer. Williams Gynecology, 4th Edition. Hoffman BL, Schorge JO, Halvorson LM, Hamid CA, Corton MM, Schaffer JI (ed): McGraw-Hill Education, New York, NY; 2020. 691-8.

10. Stambouli A, Cartault A, Petit IO, Evrard S, Mery E, Savagner F, Trudel S: DICER1 syndrome and embryonal rhabdomyosarcoma of the cervix: a case report and literature review. Front Pediatr. 2023, 11:1150418. 10.3389/fped.2023.1150418
11. Kommoss FK, Stichel D, Mora J, et al.: Clinicopathologic and molecular analysis of embryonal rhabdomyosarcoma of the genitourinary tract: evidence for a distinct DICER1-associated subgroup. Mod Pathol. 2021, 34:1558-69. 10.1038/s41379-021-00804-y
12. Shern JF, Selfe J, Izquierdo E, et al.: Genomic classification and clinical outcome in rhabdomyosarcoma: a report from an international consortium. J Clin Oncol. 2021, 39:2859-71. 10.1200/JCO.20.03060
13. Sharma AE, Dermawan JK, Chiang S, Wexler LH, Antonescu CR: Botryoid-type embryonal rhabdomyosarcoma: a comprehensive clinicopathologic and molecular appraisal with cross-comparison to its conventional-type counterpart. Am J Surg Pathol. 2024, 48:1557-67. 10.1097/PAS.0000000000002300
14. Haduong JH, Heske CM, Allen-Rhoades W, et al.: An update on rhabdomyosarcoma risk stratification and the rationale for current and future Children's Oncology Group clinical trials. Pediatr Blood Cancer. 2022, 69:e29511. 10.1002/pbc.29511
15. Bell SG, Konney TO, Appiah-Kubi A, et al.: Two rare presentations of embryonal rhabdomyosarcoma of the cervix in teenagers at a low-resource teaching hospital in Ghana: a case series. Gynecol Oncol Rep. 2021, 36:100750. 10.1016/j.gore.2021.100750
16. Schultz KA, Williams GM, Kamihara J, et al.: DICER1 and associated conditions: identification of at-risk individuals and recommended surveillance strategies. Clin Cancer Res. 2018, 24:2251-61. 10.1158/1078-0432.CCR-17-3089
17. Bouchard-Fortier G, Kim RH, Allen L, Gupta A, May T: Fertility-sparing surgery for the management of young women with embryonal rhabdomyosarcoma of the cervix: a case series. Gynecol Oncol Rep. 2016, 18:4-7. 10.1016/j.gore.2016.08.004
18. Yu X, Qie M, Huang L, Hou M: Successful pregnancy in a female with embryonal rhabdomyosarcoma of the cervix who received biopsy and chemotherapy alone without recurrence after 16 years: a case report and literature review. BMC Womens Health. 2023, 23:466. 10.1186/s12905-023-02623-6