Cureus
Part of SPRINGER NATURE

Open Access Case Report

A Sharp Encounter With Mahonia aquifolium: A Case of Multidisciplinary Management of Penetrating Orbital Trauma

Review began 09/17/2026
Review ended 11/18/2026
Published 11/23/2026

© **Copyright** 2026
Mawji et al. This is an open access article distributed under the terms of the Creative Commons Attribution License CC-BY 4.0., which permits unrestricted use, distribution, and reproduction in any medium, provided the original author and source are credited.

DOI: 10.7759/cureus.120150

Sadiq Mawji [1], Diya Baker [2, 3], Joshua Whittaker [4], Zikrullah Kalim [5], Nick Grew [1], Neil Molony [4], Richard Morse [5]

1. Oral and Maxillofacial Surgery, The Royal Wolverhampton NHS Trust, Wolverhampton, GBR 2. Ophthalmology, The Royal Wolverhampton NHS Trust, Wolverhampton, GBR 3. Ophthalmology, East Kent Hospitals University NHS Foundation Trust, Canterbury, GBR 4. Otolaryngology, The Royal Wolverhampton NHS Trust, Wolverhampton, GBR 5. Anaesthetics, The Royal Wolverhampton NHS Trust, Wolverhampton, GBR

Corresponding author: Sadiq Mawji, sadiq_mawji@hotmail.com

Abstract

Penetrating orbital and midfacial injuries from organic foreign bodies represent a rare but clinically complex subset of maxillofacial trauma. Wooden foreign bodies carry a disproportionate infective risk due to their porosity and propensity to fragment, demanding thorough operative retrieval. Such cases necessitate close multidisciplinary coordination across anaesthetics, oral and maxillofacial surgery, otorhinolaryngology and ophthalmology.

A 65-year-old woman with morbid obesity (BMI 64 kg/m²), type 2 diabetes mellitus and hypertension presented following a mechanical fall onto a Mahonia shrub. Computed tomography demonstrated a wooden splinter traversing the right maxilla, ethmoid complex and nasal cavity, with its distal tip abutting the left orbital apex in proximity to the optic nerve. Same-day operative intervention was undertaken. Anaesthetic management was complicated by distorted midface anatomy, bilateral nasal occlusion and severely reduced functional residual capacity; pre-oxygenation was achieved via an inverted paediatric facemask, followed by a staged i-Gel to GlideScope video-laryngoscope intubation strategy. Foreign body retrieval was accomplished via a combined open and endoscopic approach, with retrograde passage of the distal fragment through the nasal cavity avoiding direct orbital apex manipulation. Multiple additional organic fragments were retrieved on endoscopic wound tract exploration. The patient was electively maintained intubated in Level 3 intensive care overnight and extubated the following morning uneventfully.

Postoperative ophthalmic assessment confirmed intact visual acuity, full colour vision, normal intraocular pressures and no evidence of traumatic optic neuropathy or restrictive myopathy. The patient made an uncomplicated functional recovery following a short inpatient course of intravenous antimicrobial therapy.

Categories: Trauma, Otolaryngology, Anesthesiology
Keywords: anaesthetics, maxillofacial trauma, orbital foreign body, orbital injury, penetrating orbital injury

Introduction

Penetrating facial and orbital trauma is an uncommon but potentially devastating injury pattern, carrying risk of globe rupture, haemorrhage, infective orbital cellulitis, optic nerve injury and disfiguring facial deformity. The composition of the offending foreign body critically influences both the immediate surgical approach and subsequent infective risk [1].

Organic foreign bodies, particularly wood, are associated with substantially higher rates of postoperative infection compared to inorganic materials, owing to their intrinsic porosity, retained microbial flora and propensity to fragment. Moreover, wood is frequently radiolucent on plain radiography and may be poorly characterised on CT, rendering thorough intraoperative exploration essential to minimise the risk of retained fragments [1-4].

The multidisciplinary nature of such injuries, involving the orbits, nasal cavity, ethmoid sinuses and skull base, mandates a coordinated operative strategy with pre- and post-operative ophthalmic assessment, careful anaesthetic planning in the context of a potentially compromised airway, and endoscopic surgical adjuncts to supplement open approaches. As such, a multidisciplinary approach can help negotiate the challenges involved with penetrating facial and orbital injuries. We present a case that illustrates these principles in detail.

Case Presentation

A 65-year-old woman presented to the Emergency Department following an unwitnessed mechanical fall

from standing height onto a dry shrub in her garden. The plant was subsequently identified as Mahonia aquifolium (Oregon grape), a species characterised by rigid, spined, compound foliage. She reported no loss of consciousness and sustained no other injuries of note. On primary survey, she was haemodynamically stable with a Glasgow Coma Scale (GCS) score of 15/15. Examination of the face revealed an approximately 5 cm segment of woody stem protruding from the right cheek in the maxillary region, with no evidence of active haemorrhage either from the penetrating wound or epistaxis (Figures *1*, *2*). A second, superficially contaminated laceration of approximately 3 cm was identified in the right anterior scalp.

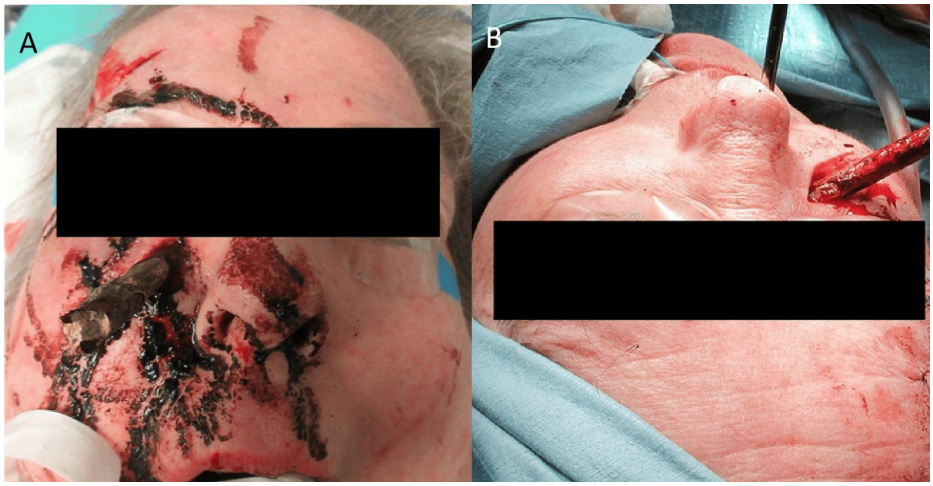

FIGURE 1: Clinical photographs taken after induction of general anaesthesia demonstrating the wooden foreign body penetrating the skin of the right cheek

A: Frontal view immediately after induction of anaesthesia; B: The trajectory of the foreign body can be appreciated in this 'bird's-eye' view after much of the dried blood has been removed.



FIGURE 2: Coronal plane CT: violation of the right lamina papyracea

RLP: Right Lamina Papyracea; FB: Foreign Body; RMA: Right Maxillary Antrum; LMA: Left Maxillary Antrum

Her medical background was notable for morbid obesity (body mass index (BMI) 64 kg/m^2, 154kg and 1.55m), type 2 diabetes mellitus with a HbA1C of 45, essential hypertension, and bilateral lower limb lymphoedema. She was ambulatory with a walking aid and lived independently. Medications included antihypertensive and oral hypoglycaemic agents. She had no known drug allergies.

Initial assessment of the eyes in the emergency department revealed there was no proptosis, periorbital ecchymosis, chemosis or enophthalmos. Pupillary responses were symmetrical and reactive. Visual acuity was measured at LogMAR 0.20 in the right eye and LogMAR 0.26 in the left eye. Intravenous co-amoxiclav was administered empirically in accordance with local antimicrobial guidelines for contaminated penetrating facial trauma, and tetanus prophylaxis was provided with a tetanus toxoid booster alongside tetanus immunoglobulin given incomplete immunisation status.

Investigations

An urgent CT of the head and facial skeleton with intravenous contrast was performed, which delineated the full trajectory of the foreign body. The wooden splinter was identified entering the right premaxillary soft tissues, traversing the anterior wall of the right maxillary antrum and into the superficial right medial orbit

(Figure 2). It then pieced the right lamina papyracea, passing through the ethmoid complex and nasal septum (Figure 3A), and extending into the left orbit with its distal tip in close juxtaposition to the left orbital apex and optic nerve (Figure 3B). The foreign body crossed the midline and showed no evidence of intracranial extension, although was in close proximity to the cribriform plate (Figure 4). There was no pneumocephalus, intracranial haemorrhage or evidence of acute sinonasal haemorrhage. Distinguishing the foreign body from air in the paranasal sinuses was facilitated by observing the scan through a lung window, rendering a subtle radiodensity within the foreign body.

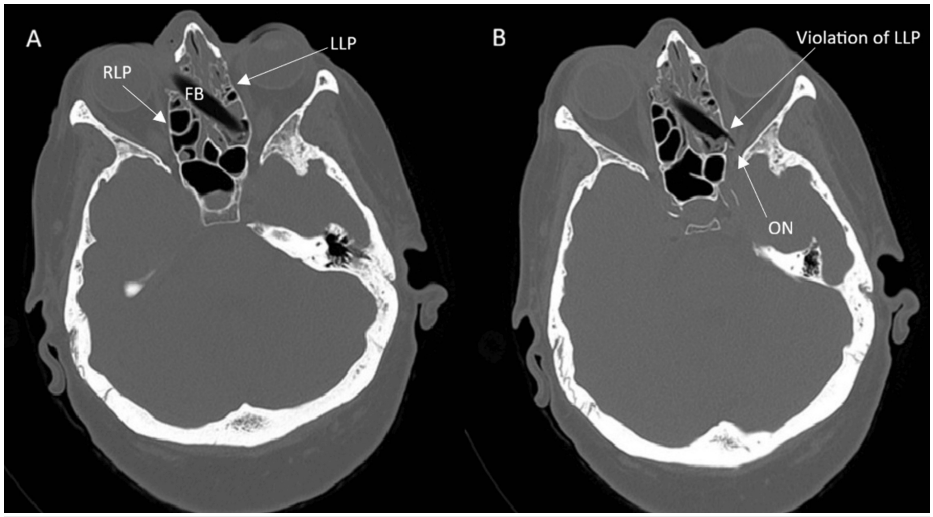

FIGURE 3: Axial plane CT demonstrating the trajectory of the wooden foreign body through the ethmoid air cells with extension into the left orbit

A: Entry of the foreign body into the right orbit, and traversing the Ethmoid air cells; B: Violation of the left medial orbital wall, with the foreign body abutting the left optic nerve.

RLP: Right Lamina Papyracea; LLP: Left Lamina Papyracea; FB: Foreign Body; ON: Optic Nerve

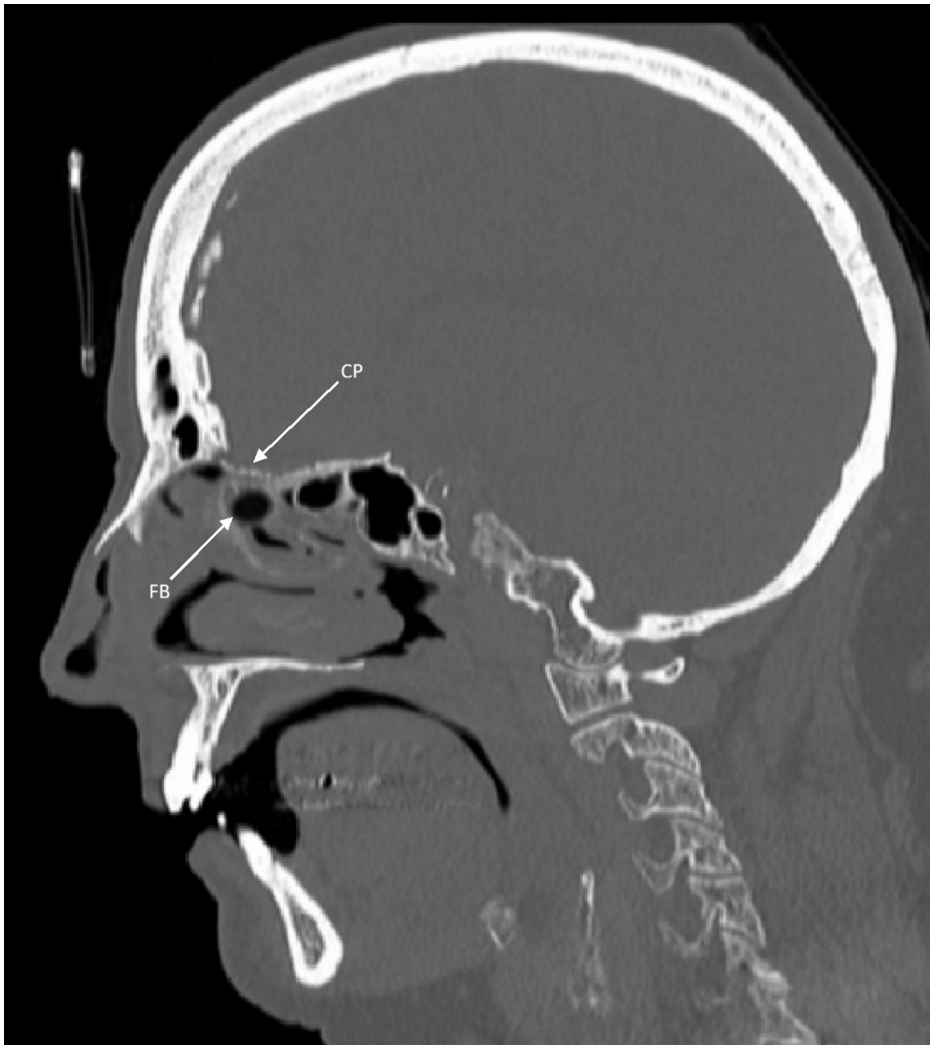

FIGURE 4: Sagittal-plane CT demonstrating the proximity of the foreign body and cribriform plate

CP: Cribriform Plate; FB: Foreign Body

Pre-operative ophthalmic assessment was undertaken using a portable slit-lamp after induction of general anaesthesia. Anterior segment examination demonstrated no corneal abrasion, laceration, hyphaema or evidence of open-globe injury. Intraocular pressure (IOP) was measured using a portable tonometer, yielding values of 20 mmHg in the right eye and 19 mmHg in the left eye, both within normal limits (range: 10-21mmHg) providing reassurance against occult globe rupture and scleral perforation whilst avoiding the risk of exacerbating any globe injury by the application of applanation tonometry.

Multidisciplinary preoperative decision-making

Following CT characterisation, an urgent multidisciplinary discussion was convened between OMFS, ENT, Ophthalmology and Anaesthetics. The operative decision was driven by several compounding factors: the proximity of the foreign body to the optic nerve and orbital apex, conferring risk of traumatic or pressure-induced optic neuropathy; the organic composition of the foreign body in a type 2 diabetic patient; and the risk of progressive orbital sepsis should surgical intervention be deferred. Also considered during discussion was risk of injury to the cribriform plate, and therefore potential for cerebrospinal fluid (CSF) leak, ethmoidal artery injury and injury to the nasolacrimal duct (right side). The consensus was to proceed with emergency operative foreign body removal under general anaesthesia on the same admission.

Anaesthetic management

Anaesthetic assessment identified multiple concurrent predictors of difficult airway management. These included distorted midface anatomy attributable to the in-situ foreign body, complete obstruction of both nasal passages by blood clot, and significantly reduced functional residual capacity (FRC) secondary to

morbid obesity. Additionally, there were concerns that positive pressure ventilation of the upper airways in a “sealed system” could result in retro-orbital surgical emphysema. The patient was classified as ASA physical status III.

Owing to an anticipated difficult airway, the front of the neck was examined by the surgical team. A difficult airway trolley containing all necessary equipment for an emergency front of neck airway access was immediately available, and the surgical team were primed and ready should an airway emergency arise.

Consideration was given to awake fibreoptic intubation. However given the location of the foreign body in the nasal cavity, and its proximity to the cribriform plate and optic nerve the decision was made to not proceed with awake intubation. Unpredictable coughing and patient movement are known complications during awake intubation, and so although technically feasible, the notion was rejected.

Conventional pre-oxygenation via a standard adult facemask was not feasible given the protruding foreign body, which precluded adequate mask seal without the risk of transmitting force to the impaled object. This was overcome by inverting a paediatric facemask to cover the oral aperture only, exploiting the coincidental complete bilateral nasal occlusion to maintain a closed circuit. This also reduced pressurisation of air in the nasal cavity. Pre-oxygenation was conducted with the patient in a 45-degree ramped, head-up position to maximise FRC and prolong safe apnoea time. End-tidal oxygen fraction was monitored to confirm denitrogenation prior to induction.

Anaesthesia was induced intravenously with meticulous attention to haemodynamic stability. As the patient had been fasted for 22 hours, rapid sequence induction was not deemed necessary and cricoid pressure was not applied. Anaesthesia and intubation continued in the ramped-up position to reduce chance of regurgitation and reduce the peak pressures required for ventilation. Ultimately, induction of anaesthesia was established using 150mcg of fentanyl (based on ideal body weight), 70mg of rocuronium (based on ideal body weight) and 100mg of propofol (based on lean body weight). Sugammadex was immediately available with pre-calculated reversal agents at hand.

Given the above challenges in maintaining an airway post-induction, an i-Gel supraglottic airway device (size 5) was inserted immediately after induction to establish a patent ventilatory circuit and optimise oxygen reserve prior to definitive intubation. This strategy intentionally avoided any external pressure on the foreign body, reduced positive pressure in the upper airways, whilst ensuring the patient did not desaturate during the transition from spontaneous to controlled ventilation.

Definitive tracheal intubation was subsequently achieved using a video laryngoscope with bougie assistance. Re-inserting the i-Gel and using a bronchoscope and airway exchange catheter remained a viable contingency plan should convetional intubation fail. Video laryngoscopy provided full visualisation of the glottic aperture (100% POGO score) and facilitated a shared situational awareness amongst the operative team during this critical step. A cuffed oral endotracheal tube (7.5 mm internal diameter) was passed without complication. The use of a video laryngoscope in this context served the dual purpose of optimising first-pass success in a predicted difficult airway and enabling all team members to identify and respond to any complications in real time. The presence of both ENT and oral and maxillofacial surgeons ensured a surgical airway could be inserted should a 'Can't intubate, Can't Ventilate' situation arise.

Anaesthesia was maintained with sevoflurane, with protective lung ventilation strategies targeting low-normal $PaCO_2$, normoxia, normotension and normothermia. Continuous invasive blood pressure monitoring was established after induction of anaesthesia via radial artery cannulation. Pre-operative blood loss was not significant and there was no suggestion of haemodynamic instability. As such the insertion of the arterial line was deferred to after anaesthetic induction. Perioperative fluid management was guided by the principle of euvolaemia. Multimodal analgesia was employed, tailored to the patient's metabolic and physiological profile. Adequate neuromuscular blockade ensured easy ventilation and peak airway pressure did not exceed 25cmH20 perioperatively, mininimising risk of surgical emphysema.

Operative management

Following induction of general anaesthesia and patient positioning, local anaesthetic with vasoconstrictive agent (2.2 mL lidocaine 2% with adrenaline 1:80,000) was infiltrated circumferentially around both the penetrating facial wound and the scalp laceration to facilitate operative haemostasis and postoperative analgesia.

A small relaxing incision was fashioned at the margin of the right premaxillary puncture wound to permit controlled exposure of the proximal foreign body segment. The externally visible fragment was carefully extracted under direct vision; in doing so, it became apparent that the branch had fractured intracorporeally at or beyond the point of facial entry, and that a further intracavitary segment required retrieval (Figure *5*).



FIGURE 5: External fragment

The image shows the externally retrieved fragment with a clear point of fracture.

An endonasal approach was taken to exposing the intranasal segment (Figure *6*). On initial endonasal examination, the fragment was largely obscured within the ethmoid complex bilaterally. 4.4ml of lidocaine hydrochloride 2% with adrenaline 1:80,000 was infiltrated across both lateral walls and the nasal septum (total 6.6mls of 2% lidocaine, 132mg). A modified Moffat solution was used for topical decongestion and haemostasis (200mg cocaine, 1mg adrenaline, 7ml sodium chloride). A single preparation was used throughout the procedure with no adverse effect on haemodynamics, confirmed by the presence of continuous invasive blood pressure monitoring. Middle turbinate medialisation, uncinectomy and medial maxillary antrostomy was initially performed to identify the posterior wall and roof of the maxillary sinus bilaterally. An ethmoidectomy was then performed to fully expose the foreign body in both sides of the nasal cavity. Regarding the septum, minimal bilateral mucoperichondrial flaps were raised around the penetration and the cartilaginous/bony septum surrounding the foreign body were debrided to mobilise it. Once fully exposed, a 30-degree endoscope was used to assess the position of the foreign body. Consideration was made to dividing the foreign body within the nasal cavity but it was felt this would cause too much movement in the process, risking the left optic nerve at the distal fragment tip. Therefore under combined endonasal and direct external visualisation, an endoscopic grasping forceps was used via the left nasal cavity to grip the distal fragment and manipulate it from its position at the orbital apex (Figure *7*). It was then passed retrogradely through the nasal cavity back towards the right maxilla, essentially following the entry route. The fragment was then grasped externally through the original premaxillary puncture wound and retrieved intact.

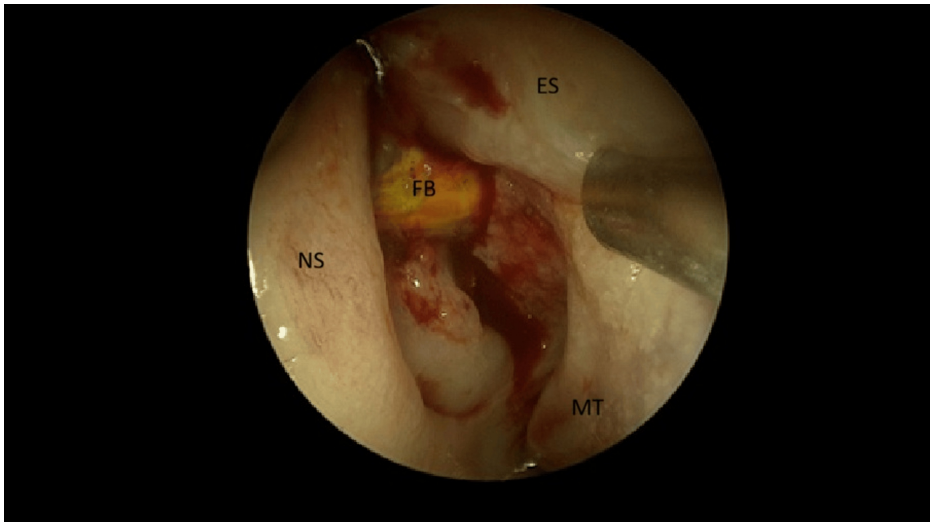

FIGURE 6: Left nasal cavity: endonasal endoscopic views showing the foreign body traversing the nasal septum

NS: Nasal Septum; FB: Foreign Body; ES: Ethmoid Sinus; MT: Middle Turbinate (lateralised)

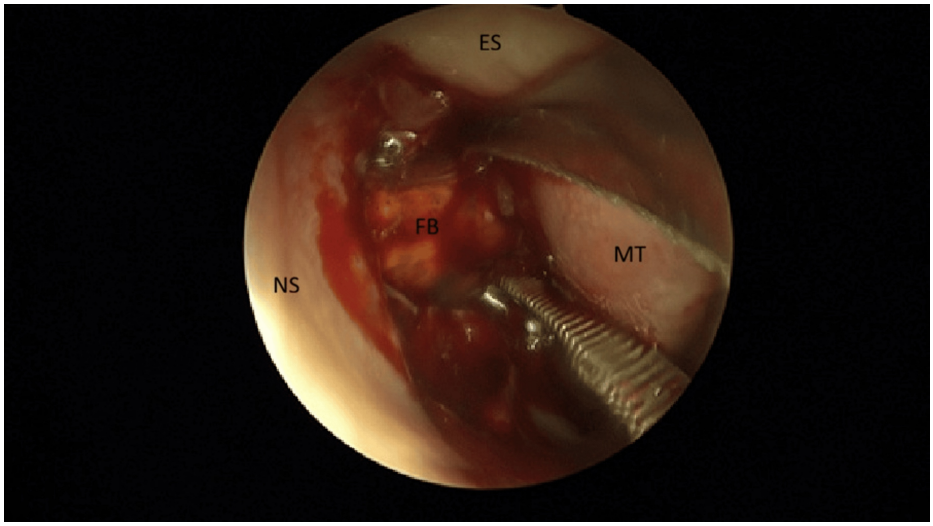

FIGURE 7: Left nasal cavity: endoscopic grasping forceps holding onto the foreign body

NS: Nasal Septum; FB: Foreign Body; ES: Ethmoid Sinus; MT: Middle Turbinate

Following removal of the principal foreign body, further endoscopic examination was used to meticulously explore of the entire wound tract, including the nasal cavity, ethmoid sinuses and in particular the left orbital apex. Multiple additional smaller organic fragments were identified and retrieved using endoscopic cup-biopsy forceps, confirming that in-situ fragmentation of the branch had occurred along its length (Figures *8*, *9*). Thorough wound irrigation with saline was performed. No attempt was made to repair the defect in either of the medial orbital walls or nasal septum. In the former, this was felt favourable to allow decompression of the apex in the event of post-operative intraconal swelling. No CSF leak or ethmoid artery injury was identified. The mucoperichondrial flaps were loosely laid back and nasal packing was avoided to allow for orbital decompression in the event of post-op swelling.

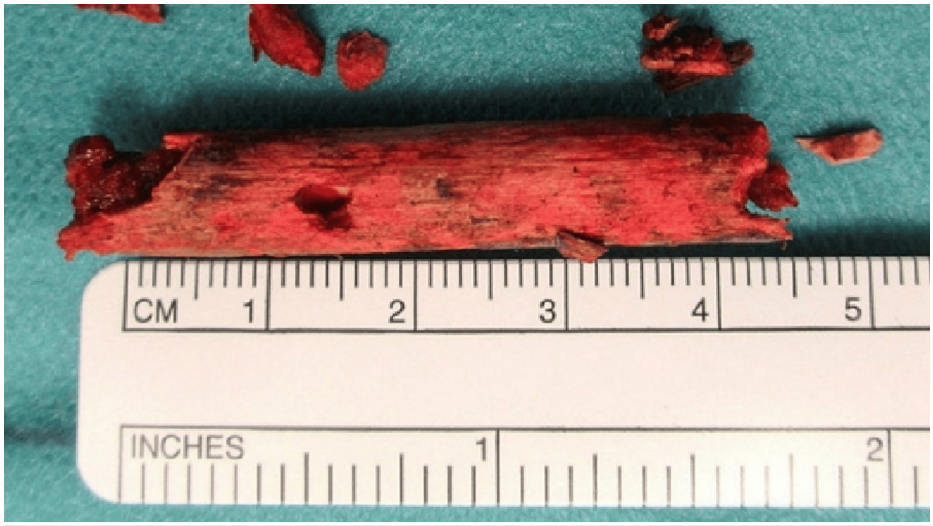

FIGURE 8: Internal fragment



FIGURE 9: All removed fragments including multiple smaller internal fragments

Both the premaxillary puncture wound and the anterior scalp laceration were closed primarily in layers. At wound closure, repeat IOP measurement was performed and confirmed to be within normal limits bilaterally, providing reassurance against acute intraoperative elevation in intraorbital pressure.

Outcome and follow-up

The total operative time was two hours, and the procedure was completed at 1.00am. Given the prolonged and complex endonasal instrumentation, and the significant physiological risk associated with unplanned reintubation in this patient - with a known difficult airway in the context of morbid obesity - the decision was taken to defer extubation and transfer the patient to the Level 3 Intensive Care Unit (ICU) electively intubated and sedated for continued postoperative monitoring. This decision was further supported by the early morning completion of the procedure, at which time senior airway-experienced personnel and optimal anaesthetic resources would be less available. This also allowed a period of observation for CSF leak and allowed time for oedema to reduce. The patient was successfully extubated in a controlled setting the following morning without complication and subsequently stepped down to the ward.

Postoperative ophthalmic re-evaluation was conducted once the patient had recovered from anaesthesia. Extraocular motility was intact in all cardinal positions of gaze, with no evidence of restrictive myopathy or cranial nerve palsy. Colour vision was assessed using Ishihara pseudoisochromatic plates and was full at 17/17 in both eyes. Visual acuity was measured at LogMAR 0.20 in the right eye and LogMAR 0.26 in the left eye which was unchanged from baseline assessment. Fundoscopy using a portable indirect ophthalmoscope

demonstrated no evidence of retinal tears, retinal detachment, commotio retinae, choroidal rupture, or early features of traumatic optic neuropathy in either eye. Repeat IOP was within normal limits bilaterally.

The patient received 1.2 grams intravenous co-amoxiclav post operatively which was subsequently transitioned to oral antibiotics on discharge to complete a seven-day course. She was discouraged from nose blowing initially and started nasal irrigation with saline from post-operative day 3. She was reviewed in combined ENT and Ophthalmology outpatient clinics following discharge, with no evidence of wound dehiscence, orbital cellulitis, sinonasal infection, optic nerve dysfunction or restriction of ocular motility at follow-up. She made an uneventful functional recovery.

Discussion

The botanical composition of the foreign body in this case was of particular clinical significance. Wooden foreign bodies are characteristically radiolucent on plain radiography and may demonstrate variable attenuation on CT. The soft tissue window in particular will often demonstrate density indistinguishable from air; however, using the lung window to examine penetrating foreign bodies will more reliably differentiate a wooden foreign body from free air (surgical emphysema) [4].

Their porous, friable structure predisposes to intraoperative fragmentation. Thorough endoscopic exploration of the wound tract where appropriate can be a useful adjunct to exclude retained fragments, a principle demonstrated directly in this case, in which multiple additional splinters not clearly identified on the pre-operative CT were retrieved following removal of the primary fragment [2,3,5].

Furthermore, organic material carries a markedly elevated risk of inflammatory and infective orbital complications, including fungal orbital cellulitis, compared to inorganic foreign bodies [1-3].

The trajectory of the foreign body in this case, traversing the ethmoid complex and nasal septum to abut the left orbital apex and optic nerve, posed a risk of direct optic nerve contusion or pressure-induced ischaemic neuropathy. Critically, the optic nerve was not approached directly; rather, the combined open and endoscopic technique allowed the distal fragment to be mobilised and passed retrogradely through the nasal cavity, avoiding any manipulation of the orbital apex. This approach exemplifies a cardinal principle in penetrating orbital foreign body removal: that the trajectory of extraction should, wherever possible, follow the trajectory of entry, or exploit an adjacent natural cavity, to minimise displacement force on adjacent neurovascular structures [1,6].

The anaesthetic management of this patient is worthy of detailed consideration. The combination of a distorted midface, bilateral nasal occlusion and morbid obesity created a genuinely hostile airway scenario in which standard management algorithms were not directly applicable. The inventive adaptation of an inverted paediatric facemask to facilitate pre-oxygenation, the staged airway strategy employing a supraglottic device prior to video-laryngoscope-assisted tracheal intubation, and the elective postoperative ICU admission for deferred extubation each represent pragmatic solutions to well-defined anaesthetic challenges in complex facial trauma. The importance of shared situational awareness through the use of video laryngoscopy in this high-stakes context merits specific emphasis.

The continuous involvement of ophthalmology throughout the perioperative pathway - from pre-induction anterior segment assessment and baseline IOP measurement, through intraoperative IOP monitoring, to structured postoperative evaluation of visual acuity, colour vision, extraocular motility and the posterior segment - ensured that any evolving visual complication would be detected and escalated without delay. This approach is consistent with published recommendations for the management of penetrating orbital trauma, which emphasise that functional ophthalmic outcomes are optimised by serial assessment rather than single-point evaluation alone [1,6].

Elective postoperative intubation and Level 3 ICU admission should be considered following prolonged complex endonasal instrumentation in obese patients with a predicted difficult airway, particularly when re-intubation would be high-risk and the risk of delayed haemorrhage is non-trivial.

Conclusions

This case illustrates the rare but clinically significant presentation of a penetrating transnasal orbital injury attributable to a fall onto a garden shrub and exemplifies the multidisciplinary coordination required to achieve a safe and favourable outcome.

Any penetrating orbital and midfacial injuries require prompt multidisciplinary assessment. Consideration should be given to same-day operative intervention especially when the foreign body is in close proximity to the optic nerve, globe, or skull base and is of organic composition and the patient carries immunocompromising comorbidities.

Additional Information

Author Contributions

All authors have reviewed the final version to be published and agreed to be accountable for all aspects of the work.

Concept and design: Sadiq Mawji, Diya Baker, Nick Grew, Neil Molony, Richard Morse, Joshua Whittaker, Zikrullah Kalim

Acquisition, analysis, or interpretation of data: Sadiq Mawji, Diya Baker, Nick Grew, Neil Molony, Richard Morse, Joshua Whittaker, Zikrullah Kalim

Drafting of the manuscript: Sadiq Mawji, Diya Baker, Nick Grew, Neil Molony, Richard Morse, Joshua Whittaker, Zikrullah Kalim

Critical review of the manuscript for important intellectual content: Sadiq Mawji, Diya Baker, Nick Grew, Neil Molony, Richard Morse, Joshua Whittaker, Zikrullah Kalim

Disclosures

Human subjects: Informed consent for treatment and open access publication was obtained or waived by all participants in this study. **Conflicts of interest:** In compliance with the ICMJE uniform disclosure form, all authors declare the following: **Payment/services info:** All authors have declared that no financial support was received from any organization for the submitted work. **Financial relationships:** All authors have declared that they have no financial relationships at present or within the previous three years with any organizations that might have an interest in the submitted work. **Other relationships:** All authors have declared that there are no other relationships or activities that could appear to have influenced the submitted work.

References

1. Fulcher TP, McNab AA, Sullivan TJ: Clinical features and management of intraorbital foreign bodies . Ophthalmology. 2002, 109:494-500. 10.1016/S0161-6420(01)00982-4
2. Nasr AM, Haik BG, Fleming JC, Al-Hussain HM, Karcioglu ZA: Penetrating orbital injury with organic foreign bodies. Ophthalmology. 1999, 106:523-32. 10.1016/S0161-6420(99)90111-2
3. Shelsta HN, Bilyk JR, Rubin PAD, Penne RB, Carrasco JR: Wooden intraorbital foreign body injuries: clinical characteristics and outcomes of 23 patients. Ophthalmic Plast Reconstr Surg. 2010, 26:238-44.
4. Roberts CF, Leehey PJ 3rd: Intraorbital wood foreign body mimicking air at CT . Radiology. 1992, 185:507-8. 10.1148/radiology.185.2.1410363
5. Yu CH, Su YJ: Detection of radiolucent wooden foreign bodies: diagnostic insights for computed tomography imaging. Quant Imaging Med Surg. 2025, 15:7585-8. 10.21037/qims-2025-85
6. Dehghanpour Barouj M, Tabrizi R, Behnia P, Alizadeh Tabrizi MA, Kheirkhahi M: Penetrating orbital injury: a case report and treatment algorithm. Arch Acad Emerg Med. 2020, 8:e33.