Cureus
Part of SPRINGER NATURE

Open Access Case Report

A Case of Anti-signal Recognition Particle Antibody-Positive Immune-Mediated Necrotizing Myopathy Complicated by Mild Pulmonary Abnormalities Successfully Managed With an Intensive Multidrug Regimen

Moko Zeniya [1], Takahiro Okai [1], Mari Seshima [2], Hirofumi Shoda [3]

1. Department of Nephrology and Rheumatology, Kawakita General Hospital, Tokyo, JPN 2. Department of Rehabilitation, Kawakita General Hospital, Tokyo, JPN 3. Department of Rheumatology, Tokyo Medical University Hospital, Tokyo, JPN

Corresponding author: Moko Zeniya, m.zeniya@kawakita.or.jp

Review began 10/18/2026
Review ended 11/13/2026
Published 11/24/2026

© **Copyright** 2026
Zeniya et al. This is an open access article distributed under the terms of the Creative Commons Attribution License CC-BY 4.0., which permits unrestricted use, distribution, and reproduction in any medium, provided the original author and source are credited.

DOI: 10.7759/cureus.120208

Abstract

Background: Anti-signal recognition particle (SRP) antibody-positive immune-mediated necrotizing myopathy (IMNM) is an aggressive subset of inflammatory myopathy characterized by rapid myofiber destruction, profound muscle weakness, severe dysphagia, and poor functional prognosis. Conventional immunosuppression is frequently insufficient, and the optimal timing and composition of multimodal therapeutic strategies, particularly regarding the incorporation of rituximab (RTX) alongside standard rescue therapies, remain challenging.

Case Presentation: A 68-year-old woman presented with subacute proximal weakness, severe dysphagia, mechanic's hands, Raynaud's phenomenon, and mild respiratory abnormalities. Marked hyperCKemia (9,388 IU/L) and high-titer anti-SRP autoantibodies were identified, while anti-aminoacyl-tRNA synthetase antibodies were negative. A CT scan of the chest revealed subtle subpleural opacities. Despite initial high-dose corticosteroids, tacrolimus, and a preliminary course of intravenous immunoglobulin (IVIg), her condition deteriorated to complete aphagia requiring enteral tube feeding and complete loss of trunk control. To overcome this refractory progression, an aggressive multimodal escalation protocol was executed: weekly RTX (375 mg/m^2) was introduced as a pivotal therapeutic pillar, coupled with a second methylprednisolone pulse, a consolidated full-course high-dose IVIg regimen (2.0 g/kg), and intensive multidisciplinary swallowing and physical rehabilitation. This integrated multidrug strategy halted disease progression and catalyzed rapid, robust recovery: the patient achieved complete weaning from tube feeding, restored independent ambulation, and demonstrated resolution of the pulmonary opacities.

Conclusions: In hyperacute, life-threatening anti-SRP IMNM refractory to conventional induction, early strategic escalation to an RTX-anchored multimodal regimen, synergized with high-dose IVIg, calcineurin inhibition, and aggressive multidisciplinary rehabilitation, serves as an extraordinarily effective therapeutic approach to rescue function and achieve favorable long-term outcomes.

Categories: Neurology, Rheumatology
Keywords: anti-signal recognition particle antibody, immune-mediated necrotizing myopathy, interstitial lung disease, intravenous immunoglobulin, multidrug regimen, rituximab

Introduction

Immune-mediated necrotizing myopathy (IMNM) is a clinically aggressive subtype within the idiopathic inflammatory myopathies (IIM), characterized histopathologically by massive myofiber necrosis and prominent regeneration with sparse lymphocytic infiltrate [1,2]. Among its serological subsets, anti-signal recognition particle (SRP) antibody-positive IMNM represents a notoriously severe clinical phenotype characterized by rapid progression, profound proximal muscle atrophy, and frequent bulbar involvement resulting in disabling dysphagia and respiratory vulnerability [3,4]. Furthermore, recent registry investigations have shown that extramuscular manifestations, specifically interstitial lung disease (ILD), even if clinically indolent or radiologically subtle, occur far more frequently than traditionally recognized, mandating thorough baseline staging and vigilant monitoring [5,6].

In elderly patients presenting with insidious or progressive weakness, establishing a diagnosis of inflammatory myopathy requires distinguishing it from other prevalent or serious etiologies, including cervical spondylotic myelopathy, neurodegenerative disorders, endocrine myopathies, and drug- or toxin-induced muscle injuries. Furthermore, paraneoplastic myopathic and neuromuscular syndromes must be rigorously investigated, particularly in older individuals with high-risk oncologic profiles. Among the IIMs, IMNM is characterized histopathologically by massive myofiber necrosis and prominent regeneration with

How to cite this article
Zeniya M, Okai T, Seshima M, et al. (November 24, 2026) A Case of Anti-signal Recognition Particle Antibody-Positive Immune-Mediated Necrotizing Myopathy Complicated by Mild Pulmonary Abnormalities Successfully Managed With an Intensive Multidrug Regimen. Cureus 18(11): e120208. DOI 10.7759/cureus.120208

sparse lymphocytic infiltrate [1,2].

Therapeutically, anti-SRP IMNM is recognized as extraordinarily recalcitrant [2,3,7]. Corticosteroid monotherapy invariably fails, with over 90% of patients requiring combinations of multiple immunosuppressive agents [2,3]. In cases demonstrating rapid deterioration or bulbar involvement, conventional therapies often fall short, necessitating aggressive second-line escalation. B-cell depletion therapy via rituximab (RTX) has demonstrated compelling clinical utility in multiple refractory IMNM series [8,9]. However, because RTX-mediated autoantibody clearance and clinical muscle reconstitution often require weeks to months [8], RTX cannot be deployed in isolation during hyperacute crises. Instead, it must be strategically incorporated into an intensive multimodal framework in which fast-acting modalities, such as high-dose intravenous immunoglobulin (IVIg), repeat corticosteroid pulses, and calcineurin inhibitors, bridge the patient to long-term stability, accompanied by coordinated multidisciplinary physical and swallowing therapy.

Here, we present a patient with refractory, rapidly deteriorating anti-SRP antibody-positive IMNM presenting with complete aphagia and motor collapse, alongside mild subpleural lung opacities, who achieved complete functional independence through an early, intensive multimodal treatment strategy centered on RTX, high-dose IVIg, tacrolimus (TAC), corticosteroids, and structured multidisciplinary care.

Case Presentation

A 68-year-old woman presented with a six-month history of worsening shoulder pain, progressive fatigue, exertional dyspnea, and swallowing difficulties. Over the two months prior to admission, she experienced an exacerbation of a productive cough and developed Raynaud's phenomenon. Lower-extremity weakness advanced to the point where she could negotiate stairs only by crawling, prompting urgent hospital admission.

Her medical background included an intracranial meningioma resected 12 years prior, an unruptured cerebral aneurysm under observation, hypertension, reflux esophagitis, and a prior left distal radius fracture. Crucially, she had no history of statin exposure, substance misuse, or familial neuromuscular disorders. Her maintenance medications were vonoprazan, eldecalcitol, amlodipine, mecobalamin, and denosumab every six months.

Physical examination revealed marked mechanic’s hands with fissures over the bilateral fingers and distinct Raynaud's phenomenon, in the absence of classic heliotrope or Gottron's rashes. Neurological examination demonstrated proximal muscle weakness dominating over distal segments without sensory dissociation, pathological reflexes, or upper motor neuron signs (including hyperreflexia, spasticity, or positive Babinski signs), clinically arguing against cervical spondylotic myelopathy. The initial Manual Muscle Testing-8 (MMT-8) score was 52/80 [10].

Initial laboratory testing demonstrated extreme hyperCKemia at 9,388 IU/L, aldolase of 123.5 U/L, AST of 416 IU/L, ALT of 363 IU/L, LDH of 1,485 IU/L, and an erythrocyte sedimentation rate of 48 mm/h. KL-6 was 182 U/mL. Thyroid function tests and serum electrolytes were unremarkable, ruling out endocrine or metabolic myopathies. A comprehensive laboratory summary is shown in Table *1*. Electrocardiography demonstrated T-wave inversions in leads V1-V2 and occasional premature ventricular contractions; echocardiography confirmed a preserved ejection fraction (71%) without regional wall motion abnormalities (Figure *1*). Continuous telemetry monitoring revealed no malignant ventricular arrhythmias or advanced atrioventricular block during hospitalization. Needle electromyography (EMG) displayed fibrillations, prominent positive sharp waves, and short-duration, low-amplitude polyphasic potentials with early recruitment, diagnostic of active necrotizing myopathy (Table *2*).

Parameters	Values	Reference range
Red blood cells	449 x 10^4/μL	(385-435)
Hemoglobin	13.4 g/dL	(12-16)
Hematocrit	40.7%	(34-43)
Platelet	24.3 × 10^4/μL	(15-35)
White blood cells	3,900/μL	(3,500-8,500)
Neutrophil	64.2%	(28.0-77.0)
Lymphocyte	25.5%	(17.0-57.0)
Monocyte	7.7%	(0.0-10.0)

Eosinophil	1.8%	(0.0-10.0)
Basophil	0.8%	(0.0-2.0)
Albumin	3.2 g/dL	(3.9-4.9)
Aspartate aminotransferase	416 IU/L	(7-38)
Alanine aminotransferase	363 IU/L	(4-36)
Lactate dehydrogenase	1485 IU/L	(124-222)
Alkaline phosphatase	55 U/L	(38-113)
Cholinesterase	280 U/ml	(168-470)
Amylase	70 U/L	(40-126)
Creatinine kinase	9,388 IU/L	(45-165)
Aldolase	123.5 U/L	(2.7-7.5)
Blood urea nitrogen	13.2 mg/dL	(8-20)
Creatinine	0.31 mg/dL	(0.4-0.8)
Na	139 mEq/L	(136-145)
Cl	103 mEq/L	(100-108)
K	4.1 mEq/L	(3.4-4.9)
Ca	8.5 mg/L	(8.6-10.1)
IP	4.2 mg/dL	(2.2-4.1)
Ferritin	250.5 ng/mL	(5-157)
HbA1c	5.2%	(4.6-6.2)
Total cholesterol	187 mg/dL	(130-219)
Triglycerides	110 mg/dL	(30-149)
LDL cholesterol	110.0 mg/dL	(70-139)
C-reactive protein	0.31 mg/dL	(0-0.29)
Erythrocyte sedimentation rate	48 mm/hr	(3-15)
KL-6	182 U/mL	(0-499)
CH50	50.4 U/mL	(30-45)
sIL-2R	752 U/mL	(<609)
IgG	1344 mg/dL	(870-1,700)
IgA	87 mg/dL	(110-410)
IgM	45 IU/mL	(33-190)
Ant-ARS Ab	<5.0 (index)	(0-25)
Ant-Jo-1 Ab	<0.3 (index)	(0-6.9)
Ant-TIF1-γ Ab	<5.0 (index)	(0-32)
Ant-MDA5 Ab	<4.0 (index)	(<7.0)
Ant-SRP54 Ab	636.9 (index)	(<10.0)
Ant-SRP19 Ab	81.1 (index)	(<10.0)
Ant-SRP68 Ab	39 (index)	(<10.0)
Ant-SRP72 Ab	86.3 (index)	(<10.0)
ANA	<40-fold	(<40-fold)

MPO-ANCA	0.3 IU/mL	(<3.5 IU/mL)
PR3-ANCA	<0.6 IU/mL	(<2.0 IU/mL)
TSH	2.3 μIU/ml	(0.61-4.23)
fT4	1.1 μg/dl	(0.75-1.45)
HBs Ag	(-)	(-)
Anti-HCV Ab	(-)	(-)
Urine Specific Gravity	1.018	(1.0005-1.030)
Urine pH	6.5	(5.0-8.0)
Urine protein	(1+)	(-)
Urine occult blood	(3+)	(-)
Urine white blood cells	(±)	(-)
Urine red blood cells	1-4/HPF	(<5/HPF)

TABLE 1: Laboratory findings on admission.

LDL: low-density lipoprotein; KL-6: sialylated carbohydrate antigen KL-6; CH50: 50% hemolytic complement activity; sIL-2R: soluble interleukin-2 receptor; ARS: aminoacyl tRNA synthetase; Jo-1: anti-histidyl-tRNA synthetase antibody; TIF1-γ: transcriptional intermediary factor 1-gamma; MDA5: melanoma differentiation-associated gene 5; SRP: signal recognition particle; HMGCR: 3-hydroxy-3-methylglutaryl-coenzyme A reductase; ANA: antinuclear antibody; MPO: myeloperoxidase; PR3: proteinase 3; ANCA: anti-neutrophil cytoplasmic antibody; TSH: thyroid stimulating hormone; fT4: free hyroxine; HBsAg: hepatitis B surface antigen; Anti-HCV: anti-hepatitic C virus antibody.

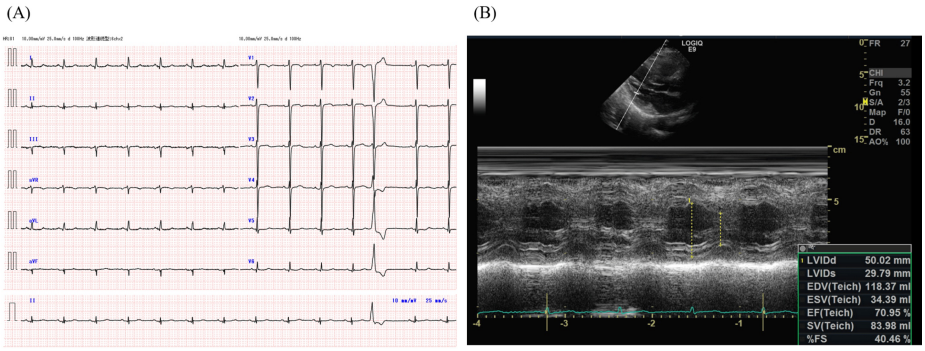

FIGURE 1: Electrocardiography and echocardiography.

(A) Electrocardiography demonstrated T-wave inversions in leads V1 and V2 and occasional premature ventricular contractions. (B) Echocardiography confirmed preserved ejection fraction (71%) without regional wall motion abnormalities.

Muscle	Side	Ins. Act.	Fibs.	Pos. wave	Fasc.	MYO. Disch.	Normal MUP	Poly	Low amp.	High amp.	Dur.	Recruit	Int. patt.
Quadriceps	R	Normal	2+	2+	-	-	↓↓	1+	1+	-	short	early	3+

TABLE 2: Needle electromyography findings of the right quadriceps muscle.

Resting examination demonstrated marked membrane instability, evidenced by 2+ fibrillation potentials and positive sharp waves. Voluntary effort revealed typical myopathic MUAP morphology, consisting of short duration, low amplitude, and polyphasia, accompanied by early recruitment with a full interference pattern.

0 = none; 1+ = persistent single train of potentials in at least two areas; 2+ = moderate activity in three or more areas; 3+ = abundant potentials in almost all needle insertions; 4+ = continuous discharges. ↓↓ = markedly reduced or decreased.

R: right; Ins. Act.: insertional activity; Fibs: fibrillation potentials; PSWs: positive sharp waves; Fasc: fasciculation potentials; CRD/Myo (MYO. Disch.): myotonic or complex repetitive discharges; MUAP (MUP): motor unit action potential; Poly: polyphasic potentials; Low Amp: low-amplitude potentials; High Amp: high-amplitude potentials; Dur: duration; Recruit: recruitment pattern; Int. Patt.: interference pattern.

Coronal and axial short-tau inversion recovery (STIR) MRI of the thighs revealed extensive, symmetric hyperintensities predominantly within the bilateral adductor magnus muscles, the right vastus lateralis muscle, and the vastus medialis muscle, confirming severe myofascial edema (Figure *2*). High-resolution computed tomography (HRCT) of the chest revealed faint peripheral ground-glass opacities (GGO) and delicate subpleural reticular changes at both lung bases (Figure *3A*). Multiplex line immunoassay revealed massive anti-SRP autoantibody positivity (SRP54: 636.9, SRP19: 81.1, SRP68: 39.0, SRP72: 86.3 index; normal < 10.0 index), while anti-ARS antibodies (Jo-1, PL-7, PL-12, EJ, KS) and anti-TIF1-γ antibodies were completely negative. A muscle biopsy was declined by the patient. To exclude paraneoplastic myopathy and occult malignancy, a paramount concern in this age demographic, systemic screening was completed. High-resolution chest-to-pelvic computed tomography (CT) and tumor marker assays revealed no occult malignancy. The clinical phenotype, combined with highly specific serology, fulfilled the 2017 EULAR/ACR classification (score 8.4) and the 224th European Neuromuscular Centre (ENMC) criteria for definite anti-SRP IMNM [2,7,11]. A collaborative multidisciplinary clinical team, comprising rheumatologists, neurologists, pulmonologists, and dedicated physical/speech therapists, was engaged early to optimize systemic monitoring and therapy.

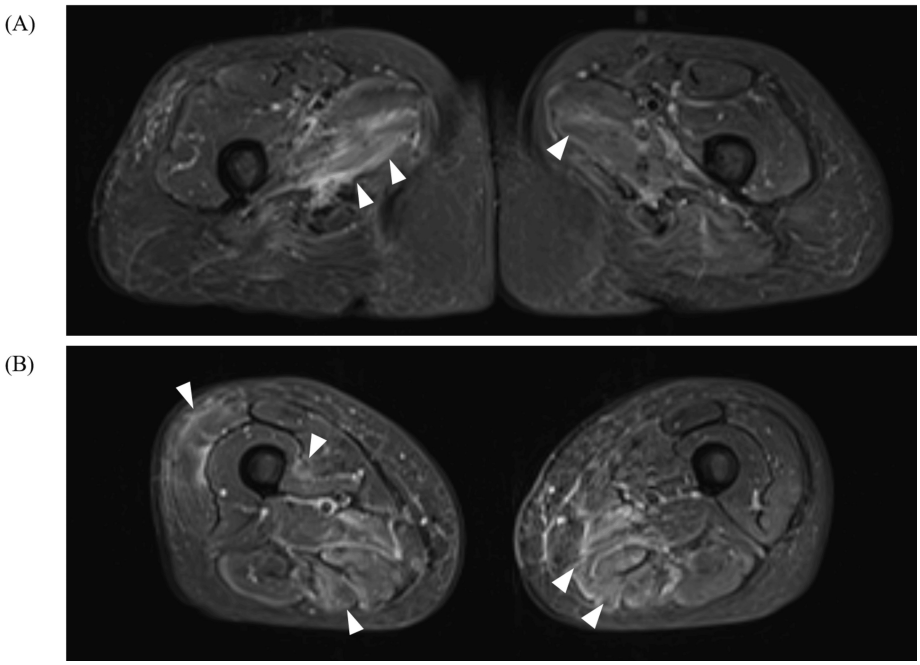

FIGURE 2: Axial short-tau inversion recovery (STIR) MRI of the bilateral thighs.

Axial STIR images (1.5-Tesla, Philips Healthcare, Amsterdam, the Netherlands) demonstrating diffuse, symmetric hyperintensities predominantly within the bilateral adductor magnus muscles, the right vastus lateralis muscle, and the vastus medialis muscle. (indicated by white arrows), reflecting active myofascial edema and acute necrotizing myopathy. Images were retrieved directly from the institutional Picture Archiving and Communication System (PACS) and prepared using Microsoft PowerPoint (Microsoft Corporation, Redmond, Washington).

STIR: short-tau inversion recovery.

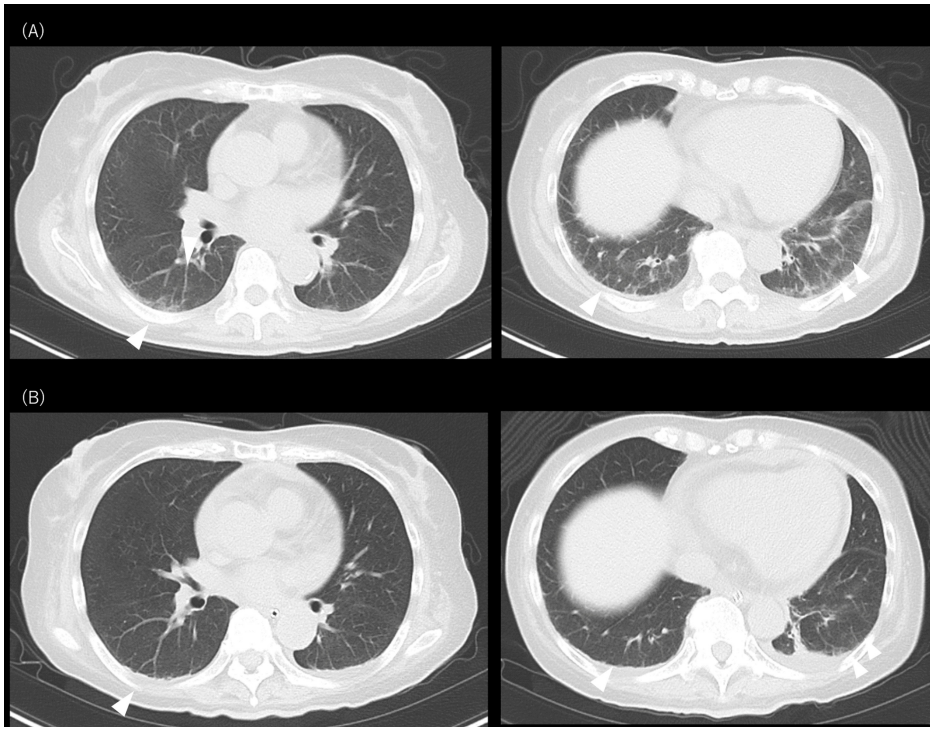

FIGURE 3: High-resolution computed tomography (HRCT) of the chest.

(A) Baseline chest HRCT obtained on admission showing faint peripheral ground-glass opacities (GGO) and subtle subpleural reticular opacities predominantly in the bilateral posterior lower lung bases (white arrowheads). (B) Follow-up HRCT on hospital day 48 demonstrating substantial attenuation and regression of peripheral GGO and reticular changes following intensive multidrug immunosuppressive therapy. Images were exported from the institutional PACS and annotated using Microsoft PowerPoint (Microsoft Corporation).

HRCT: high-resolution computed tomography; PACS: Picture Archiving and Communication System; GGO: ground-glass opacities.

While autoantibody confirmation was pending, induction began with intravenous methylprednisolone (mPSL) pulse therapy (500 mg/day for three days), followed by oral prednisolone (PSL) at 50 mg/day (1.2 mg/kg/day) and oral TAC (3 mg/day, adjusted to maintain a trough concentration of 5-8 ng/mL). Because dysphagia worsened, an initial IVIg course (15 g/day for four days) was initiated on day 6. On day 15, anti-SRP positivity was confirmed.

Despite substantial laboratory reductions in serum CK and CRP, the patient suffered devastating clinical deterioration. By hospital day 18, she developed total aphagia, was unable to clear thickened saliva, was mandating nasogastric enteral tube feeding, and was completely lost in independent sitting balance; her MMT-8 score plummeted to 28/80.

Recognizing that conventional immunosuppression had failed, an aggressive multimodal rescue strategy was promptly deployed. Weekly RTX infusions (375 mg/m^2) were instituted on day 20 as the cornerstone therapy, combined with a second mPSL pulse (500 mg/day for three days; days 22-24). Clinical stabilization emerged by day 34, allowing progressive PSL tapering. To solidify recovery and prevent further bulbar aspiration, a second full-dose IVIg regimen (15 g/day for five days; 400 mg/kg/day, totaling 2.0 g/kg) was administered on days 40-44. In parallel, a specialized multidisciplinary rehabilitation team, including speech therapists, physical therapists, occupational therapists, and clinical dietitians, conducted daily intensive swallowing maneuvers, trunk stability training, and progressive resistive exercise.

This coordinated regimen achieved a dramatic turnaround: her MMT-8 score rose to 46/80 by day 45. By day 49, the patient safely resumed a regular oral diet, allowing permanent feeding tube removal, and regained unassisted ambulation for >50 meters by day 51. Her cough resolved, and follow-up HRCT on day 48 revealed marked regression of pulmonary opacities (Figure *3B*). She was transitioned to inpatient rehabilitation on day 50. The therapeutic timeline and clinical trajectory are summarized in Figure *4*.

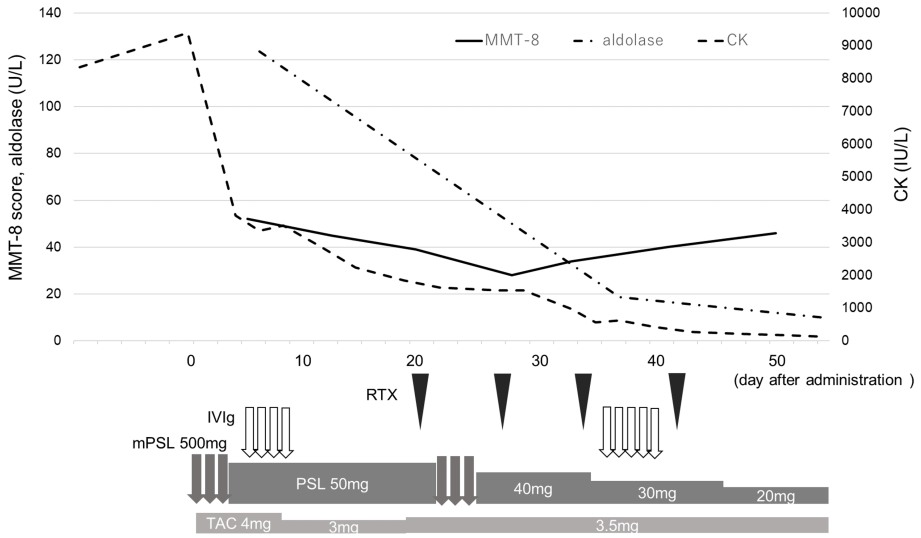

FIGURE 4: Chronological clinical course, laboratory trends, and therapeutic timeline.

Temporal trends of serum creatine kinase (CK; dotted-dashed line, IU/L), aldolase (dashed line, U/L), and Manual Muscle Testing-8 (MMT-8; solid line, /80) scores are plotted along the horizontal axis representing hospital days. Administration timing and dosages of intravenous methylprednisolone (mPSL), oral prednisolone (PSL), oral tacrolimus (TAC), intravenous immunoglobulin (IVIg), and weekly rituximab (RTX) infusions are delineated below. The graph was generated using Microsoft Excel (Microsoft Corporation, Redmond, Washington) and formatted using Microsoft PowerPoint (Microsoft Corporation).

Discussion

Anti-SRP antibody-positive IMNM is a distinctive, highly debilitating myopathy driven by complement-mediated myofiber necrosis [1,2,12]. The present case illustrates two pivotal clinical themes: the successful reversal of catastrophic functional collapse through an RTX-centered multimodal regimen and the underrecognized presence of concurrent mild pulmonary involvement in anti-SRP disease.

A central takeaway from this case is that monotherapy or sequential, low-intensity escalation is inadequate for severe anti-SRP IMNM [2,3,13,14]. When our patient developed complete aphagia and became bedridden despite high-dose corticosteroids, tacrolimus, and early IVIg, rapid escalation to RTX served as the decisive turning point.

The literature strongly supports the efficacy of RTX in refractory anti-SRP cohorts [8,9]. In the seminal series by Valiyil et al., 75% of refractory anti-SRP patients achieved significant strength gains and CK normalization within 2-4 months of RTX, enabling major steroid sparing [8]. Xiong et al.'s systematic review confirmed that anti-SRP IMNM showed a response substantially better to RTX than anti-HMGCR myopathy (76.5% vs. 42.9%) [9]. Although the randomized RIM trial did not achieve statistical significance in its anti-SRP subset due to limited numbers and chronic fibrotic damage prior to enrollment [15], wider observational evidence and meta-analyses reaffirm that early RTX intervention halts necrotizing myopathy before irreversible fatty replacement occurs [16,17].

From an immunological standpoint, anti-SRP IMNM is orchestrated through complex humoral and innate immune cascades: circulating pathogenic anti-SRP IgG antibodies bind to target surface antigen complexes, triggering activation of the classical complement pathway and resulting in membrane attack complex (MAC; C5b-9) deposition on non-necrotic sarcolemma [1,2,12]. This complement-driven necrosis occurs in a milieu with minimal lymphocytic infiltration, distinct from classical dermatomyositis or polymyositis. This pathophysiology explains why multimodal targeting is mechanistically necessary. Critically, our case highlights that the therapeutic success was achieved not by RTX in isolation but through its synergy within a multimodal regimen.

The biological kinetics of RTX require weeks for full B-cell depletion and clearance of pathogenic autoantibodies [8]. In our patient, functional improvement began within two weeks of RTX initiation. This rapid turnaround was made possible because high-dose IVIg (2.0 g/kg) and steroid pulse therapy acted as immediate pharmacodynamic bridges, neutralizing pathogenic anti-SRP autoantibodies, intercepting membrane attack complex (MAC) assembly on myofibers, and mitigating acute swelling, while tacrolimus dampened T-cell activation and calcineurin-dependent inflammatory pathways. RTX subsequently dismantled the underlying B-cell-driven autoimmune cascade, locking in sustained remission and allowing

successful steroid tapering. Thus, combining RTX with IVIg and calcineurin inhibitors created a potent bidirectional approach addressing both hyperacute sarcolemmal injury and chronic antibody production.

Equally vital to this patient's outcome was intensive multidisciplinary rehabilitation. Bulbar involvement in IMNM carries grave morbidity, frequently resulting in fatal aspiration pneumonia or prolonged feeding dependence. While aggressive immunosuppression halted muscle fiber necrosis, functional deglutition and ambulation were restored through early, coordinated swallowing therapies, respiratory muscle training, and graded motor rehabilitation delivered during the acute immunosuppressive nadir. Pharmacotherapy created the cellular environment for repair, but multidisciplinary rehabilitation directly drove the functional recovery.

This case also emphasizes the importance of evaluating pulmonary abnormalities in anti-SRP IMNM. While ILD is traditionally associated with anti-synthetase and anti-MDA5 syndromes, multicenter studies have shown that pulmonary involvement is present in up to 50% of anti-SRP patients when high-resolution imaging is systematically utilized [5,6]. Unlike the rapidly progressive or fibrosing patterns seen in other myopathies, anti-SRP ILD often presents with mild, subpleural ground-glass or reticular opacities and normal biomarker levels (such as KL-6), as seen in our patient. The prompt radiographic clearance on follow-up HRCT suggests that such subtle pulmonary opacities readily respond to intensive combination regimens containing RTX and calcineurin inhibitors, further supporting the comprehensive systemic efficacy of this multimodal approach.

Fortunately, this case did not involve myocardial damage. However, cardiac complications in anti-SRP IMNM range from subclinical conduction abnormalities to overt myocarditis and congestive heart failure. Active cardiac surveillance, including electrocardiography, troponins, and echocardiography, should be systematically incorporated into the baseline workup and therapeutic monitoring of all anti-SRP patients.

Limitations include the omission of a diagnostic muscle biopsy due to patient preference, although clinical, laboratory, and high-titer serological profiles definitively satisfied ENMC diagnostic standards [7]. Additionally, formal baseline pulmonary function tests (forced vital capacity (FVC) and diffusing capacity of the lungs for carbon monoxide (DLCO)) and objective swallowing videofluoroscopy could not be conducted during the acute decompensation phase due to extreme patient weakness. Finally, although emerging novel therapeutics such as neonatal Fc receptor (FcRn) antagonists (efgartigimod) and complement inhibitors represent promising future options for refractory IMNM [18,19], RTX remains the most accessible, proven biologic therapy capable of integration into intensive multimodal regimens worldwide.

Conclusions

Anti-SRP antibody-positive IMNM can evolve with devastating speed into life-threatening bulbar and functional collapse. In such refractory presentations, an aggressive multimodal regimen centered on RTX, synergistically reinforced by full-dose IVIg, calcineurin inhibition, repeat corticosteroid pulses, and coordinated multidisciplinary rehabilitation, provides an exceptionally effective therapeutic framework to reverse acute functional deterioration and achieve durable clinical and radiological recovery.

Additional Information

Author Contributions

All authors have reviewed the final version to be published and agreed to be accountable for all aspects of the work.

Concept and design: Moko Zeniya, Takahiro Okai, Mari Seshima, Hirofumi Shoda

Drafting of the manuscript: Moko Zeniya, Takahiro Okai, Mari Seshima, Hirofumi Shoda

Disclosures

Human subjects: Informed consent for treatment and open access publication was obtained or waived by all participants in this study. Institutional Ethics Committee of Kawakita General Hospital issued approval NA. Consent was obtained or waived by all participants in this study. The study was approved by the Institutional Ethics Committee of Kawakita General Hospital and adhered to the Declaration of Helsinki. **Conflicts of interest:** In compliance with the ICMJE uniform disclosure form, all authors declare the following: **Payment/services info:** All authors have declared that no financial support was received from any organization for the submitted work. **Financial relationships:** All authors have declared that they have no financial relationships at present or within the previous three years with any organizations that might have an interest in the submitted work. **Other relationships:** All authors have declared that there are no other relationships or activities that could appear to have influenced the submitted work.

References

1. Tanboon J, Uruha A, Stenzel W, Nishino I: Where are we moving in the classification of idiopathic inflammatory myopathies?. Curr Opin Neurol. 2020, 33:590-603. 10.1097/WCO.0000000000000855
2. Allenbach Y, Benveniste O, Stenzel W, Boyer O: Immune-mediated necrotizing myopathy: clinical features and pathogenesis. Nat Rev Rheumatol. 2020, 16:689-701. 10.1038/s41584-020-00515-9
3. Watanabe Y, Uruha A, Suzuki S, et al.: Clinical features and prognosis in anti-SRP and anti-HMGCR necrotising myopathy. J Neurol Neurosurg Psychiatry. 2016, 87:1038-44. 10.1136/jnnp-2016-313166
4. Suzuki S, Nishikawa A, Kuwana M, et al.: Inflammatory myopathy with anti-signal recognition particle antibodies: case series of 100 patients. Orphanet J Rare Dis. 2015, 10:61. 10.1186/s13023-015-0277-y
5. Ge Y, Yang H, Xiao X, Liang L, Lu X, Wang G: Interstitial lung disease is not rare in immune-mediated necrotizing myopathy with anti-signal recognition particle antibodies. BMC Pulm Med. 2022, 22:14. 10.1186/s12890-021-01802-1
6. Sehgal S, Patel A, Chatterjee S, et al.: Idiopathic inflammatory myopathies related lung disease in adults . Lancet Respir Med. 2025, 13:272-88. 10.1016/S2213-2600(24)00267-4
7. Allenbach Y, Mammen AL, Benveniste O, Stenzel W: 224th ENMC International Workshop:: Clinico-sero-pathological classification of immune-mediated necrotizing myopathies Zandvoort, The Netherlands, 14-16 October 2016. Neuromuscul Disord. 2018, 28:87-99. 10.1016/j.nmd.2017.09.016
8. Valiyil R, Casciola-Rosen L, Hong G, Mammen A, Christopher-Stine L: Rituximab therapy for myopathy associated with anti-signal recognition particle antibodies: a case series. Arthritis Care Res (Hoboken). 2010, 62:1328-34. 10.1002/acr.20219
9. Xiong A, Yang G, Song Z, et al.: Rituximab in the treatment of immune-mediated necrotizing myopathy: a review of case reports and case series. Ther Adv Neurol Disord. 2021, 14:1756286421998918. 10.1177/1756286421998918
10. Rider LG, Koziol D, Giannini EH, et al.: Validation of manual muscle testing and a subset of eight muscles for adult and juvenile idiopathic inflammatory myopathies. Arthritis Care Res (Hoboken). 2010, 62:465-72. 10.1002/acr.20035
11. Lundberg IE, Tjärnlund A, Bottai M, et al.: 2017 European League Against Rheumatism/American College of Rheumatology classification criteria for adult and juvenile idiopathic inflammatory myopathies and their major subgroups. Ann Rheum Dis. 2017, 76:1955-64. 10.1136/annrheumdis-2017-211468
12. Suh J, Amato AA: Management of immune-mediated necrotizing myopathy . Muscle Nerve. 2024, 70:166-72. 10.1002/mus.28114
13. Reeves WH, Nigam SK, Blobel G: Human autoantibodies reactive with the signal-recognition particle . Proc Natl Acad Sci U S A. 1986, 83:9507-11. 10.1073/pnas.83.24.9507
14. Pinal-Fernandez I, Parks C, Werner JL, et al.: Longitudinal course of disease in a large cohort of myositis patients with autoantibodies recognizing the signal recognition particle. Arthritis Care Res (Hoboken). 2017, 69:263-70. 10.1002/acr.22920
15. Oddis CV, Reed AM, Aggarwal R, et al.: Rituximab in the treatment of refractory adult and juvenile dermatomyositis and adult polymyositis: a randomized, placebo-phase trial. Arthritis Rheum. 2013, 65:314-24. 10.1002/art.37754
16. Fasano S, Gordon P, Hajji R, Loyo E, Isenberg DA: Rituximab in the treatment of inflammatory myopathies: a review. Rheumatology (Oxford). 2017, 56:26-36. 10.1093/rheumatology/kew146
17. Zhen C, Hou Y, Zhao B, Ma X, Dai T, Yan C: Efficacy and safety of rituximab treatment in patients with idiopathic inflammatory myopathies: a systematic review and meta-analysis. Front Immunol. 2022, 13:1051609. 10.3389/fimmu.2022.1051609
18. Peng Q, Yao X, Chen S, Li X, Lin F, Zou Z: Efgartigimod combined with steroids as a fast-acting therapy for anti-SRP immune-mediated necrotizing myopathy. Front Neurol. 2025, 16:1560483. 10.3389/fneur.2025.1560483
19. Raaphorst J, Kooi AJ, Mecoli CA, et al.: Advances in the classification and management of idiopathic inflammatory myopathies. Lancet Neurol. 2025, 24:776-88. 10.1016/S1474-4422(25)00233-9