Cureus
Part of SPRINGER NATURE

Open Access Case Report

Pathological Complete Response After Conversion Surgery for Initially Unresectable Hepatocellular Carcinoma Followed by Alpha-Fetoprotein-Producing Jejunal Adenocarcinoma With Hepatoid Differentiation: A Case Report

Keiji Nagata [1], Takahisa Fujikawa [1], Yasusato Matsuda [2], Yusuke Uemoto [1]

1. Surgery, Kokura Memorial Hospital, Kitakyushu, JPN 2. Gastroenterology, Kokura Memorial Hospital, Kitakyushu, JPN

Corresponding author: Takahisa Fujikawa, takamaminao@gmail.com

Review began 09/02/2026
Review ended 10/15/2026
Published 10/21/2026

© **Copyright** 2026
Nagata et al. This is an open access article distributed under the terms of the Creative Commons Attribution License CC-BY 4.0., which permits unrestricted use, distribution, and reproduction in any medium, provided the original author and source are credited.

DOI: 10.7759/cureus.118288

Abstract

Recent advances in systemic therapy have increased opportunities for conversion surgery in selected patients with initially unresectable hepatocellular carcinoma (uHCC). We report a rare case of initially unresectable advanced HCC with portal vein tumor invasion, multiple intrahepatic metastases, and extrahepatic metastases in which sequential immune-based systemic therapy enabled conversion surgery, with pathological examination confirming a complete response in the resected segment 2 lesion. Persistent alpha-fetoprotein (AFP) elevation after surgery initially raised concern for occult or recurrent HCC, but the subsequent detection of recurrent HCC and jejunal adenocarcinoma with hepatoid differentiation complicated this interpretation. After resection of both lesions, folinic acid (leucovorin), 5-fluorouracil, and oxaliplatin (FOLFOX) therapy for residual mesenteric lymph node lesions considered metastatic on imaging was followed by a marked decline in AFP and disappearance of the lymph node lesions. This case highlights the potential role of conversion surgery after systemic therapy in selected patients with initially unresectable HCC and the importance of interpreting persistent AFP elevation together with imaging, pathological findings, and the clinical course.

Categories: General Surgery, Oncology, Gastroenterology
Keywords: alpha-fetoprotein, conversion surgery, hepatocellular carcinoma, hepatoid adenocarcinoma with hepatoid differentiation, pathological complete response

Introduction

Systemic treatment for unresectable hepatocellular carcinoma (uHCC) has changed substantially with the introduction of molecularly targeted agents and immune checkpoint inhibitor (ICI)-based regimens. Atezolizumab plus bevacizumab and durvalumab plus tremelimumab have improved survival outcomes and are widely used as first-line systemic therapies for uHCC [1,2]. In selected patients, these regimens can achieve sufficient tumor regression or durable disease control to permit surgical resection. Conversion surgery refers to surgical resection performed after systemic therapy renders initially unresectable disease technically and oncologically resectable. However, its indications, optimal timing, and postoperative management remain uncertain, particularly in patients who initially present with macrovascular invasion or extrahepatic metastases [3,4].

Alpha-fetoprotein (AFP) is widely used as a tumor marker for HCC but is not specific to this disease. Hepatoid adenocarcinoma is a rare extrahepatic adenocarcinoma that resembles HCC morphologically and immunohistochemically and may also produce AFP [5,6]. We report a patient with initially uHCC who achieved long-term disease control after prolonged immune-based systemic therapy and underwent conversion surgery, with a pathological complete response confirmed in the resected segment 2 lesion. The patient was subsequently diagnosed with recurrent HCC and AFP-producing jejunal adenocarcinoma with hepatoid differentiation. This case illustrates both the potential role of conversion surgery in selected patients with initially advanced HCC and the difficulty of interpreting persistent AFP elevation when more than one AFP-producing malignancy may be present.

Case Presentation

A 59-year-old man with hepatitis C virus-related chronic liver disease who had not received antiviral therapy was referred to our hospital for treatment of advanced HCC. Contrast-enhanced computed tomography (CT) showed a 10-cm tumor in the left lateral hepatic section, tumor thrombus involving the left portal vein branch and extending into the main portal vein, multiple intrahepatic lesions, bulky periduodenal lymph node metastases compressing the duodenum, and multiple lung and rib metastases (Figures *1A*-*1D*).

How to cite this article
Nagata K, Fujikawa T, Matsuda Y, et al. (October 21, 2026) Pathological Complete Response After Conversion Surgery for Initially Unresectable Hepatocellular Carcinoma Followed by Alpha-Fetoprotein-Producing Jejunal Adenocarcinoma With Hepatoid Differentiation: A Case Report. Cureus 18(10): e118288. DOI 10.7759/cureus.118288

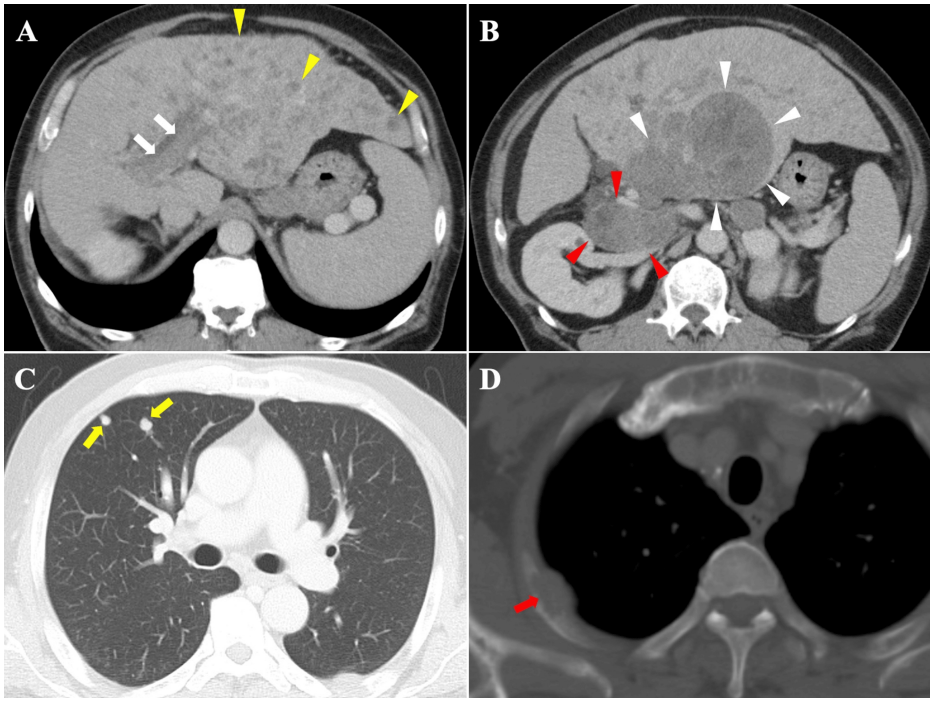

FIGURE 1: Contrast-enhanced CT findings at diagnosis

(A) Tumor thrombus occupied the left portal vein branch and extended into the main portal vein (white arrows), with multiple intrahepatic lesions in the left hepatic lobe (yellow arrowheads). (B) A 10-cm tumor was present in the left lateral hepatic section (white arrowheads), with enlarged metastatic periduodenal lymph nodes compressing the duodenum (red arrowheads). (C) Multiple lung metastases were present (yellow arrows). (D) A metastatic rib lesion was present (red arrow).

CT: computed tomography

Serum AFP was >200,000 ng/mL, and protein induced by vitamin K absence or antagonist-II (PIVKA-II) was 145,311 mAU/mL. The indocyanine green (ICG) retention rate at 15 minutes was 38.7%. The patient had an Eastern Cooperative Oncology Group (ECOG) Performance Status of 0 and Child-Pugh class A liver function. Based on the characteristic imaging findings and markedly elevated AFP and PIVKA-II levels, the disease was clinically diagnosed as advanced HCC without biopsy of the initial hepatic tumor. Laboratory findings at the initial presentation are summarized in Table *1*.

Parameter	Result	Reference range
WBC	4.9 × 10^3/uL	3.3-8.6 × 10^3/uL
Hb	7.6 g/dL	13.7-16.8 g/dL
Plt	17.3 × 10^4/uL	12.0-39.0 × 10^4/μL
AST	214 U/L	13-30 U/L
ALT	53 U/L	10-30 U/L
ALP	253 U/L	38-113 U/L
γ-GTP	609 IU/L	<50 IU/L
T-bil	1.8 mg/dL	0.4-1.5 mg/dL
Alb	2.8 g/dL	4.0-5.0 g/dL
PT	81%	70%-130%
BUN	11.1 mg/dL	8.0-20.0 × 10^3/uL
Cr	0.77 mg/dL	0.65-1.0 mg/dL
AFP	>200,000 ng/mL	<10 ng/mL
PIVKA-II	145,311 mAU/mL	<40 mAU/mL
CEA	2 ng/mL	<5 ng/mL
CA19-9	19 U/mL	<37 U/mL
Child-Pugh class	A	A-C

TABLE 1: Baseline laboratory and liver function findings at initial presentation

AFP: alpha-fetoprotein, Alb: albumin, ALP: alkaline phosphatase, ALT: alanine aminotransferase, AST: aspartate aminotransferase, BUN: blood urea nitrogen, CA19-9: carbohydrate antigen 19-9, CEA: carcinoembryonic antigen, Cr: creatinine, γ-GTP: gamma-glutamyl transferase, Hb: hemoglobin, PIVKA-II: protein induced by vitamin K absence or antagonist-II, Plt: platelet count, PT: prothrombin time, T-bil: total bilirubin, WBC: white blood cell count

Treatment with atezolizumab plus bevacizumab was initiated. Endoscopy showed tumor-related duodenal mucosal invasion with bleeding. Biopsy of the duodenal lesion showed AE1/AE3 positivity and focal hepatocyte marker expression, findings considered compatible with HCC involvement. Because of the bleeding risk, bevacizumab was administered at a reduced dose of 8 mg/kg. AFP and PIVKA-II declined rapidly after treatment initiation, and approximately three months after diagnosis, CT after six cycles showed marked regression of the primary hepatic tumor and the metastatic lesions (Figure *2A*). The lung and rib metastases subsequently disappeared on imaging, and disease control was maintained without the development of new lesions.

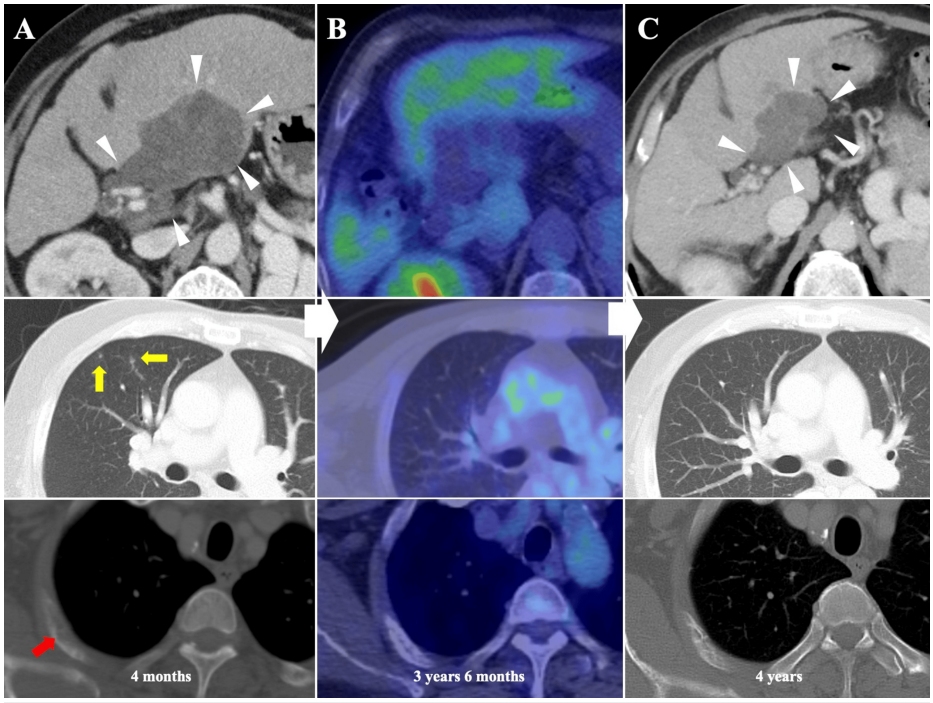

FIGURE 2: CT and PET-CT findings during treatment

(A) CT after six courses of atezolizumab plus bevacizumab showed marked regression of the primary hepatic tumor (white arrowheads), lung metastases (yellow arrows), and rib metastasis (red arrow). (B) PET-CT after 53 courses of atezolizumab-based therapy showed no abnormal uptake suggestive of active disease. (C) CT before the first hepatic resection showed the residual hepatic lesion, which was the only remaining radiographically detectable lesion (white arrowheads).

CT: computed tomography, PET-CT: positron emission tomography-computed tomography

Approximately two years after diagnosis, during the 34th cycle, the patient developed gastrointestinal perforation requiring emergency surgery. The perforation occurred in the jejunum, anatomically separate from the subsequently detected jejunal tumor. Histopathological examination of the resected specimen showed no malignancy. Bevacizumab was permanently discontinued, whereas atezolizumab monotherapy was continued because radiographic disease control had been maintained. Approximately three years and seven months after diagnosis, the patient ultimately received 53 cycles of atezolizumab-based therapy. CT showed marked tumor regression, with only one residual lesion remaining in the left lateral hepatic section, and positron emission tomography-computed tomography (PET-CT) showed no abnormal uptake suggestive of active disease (Figure *2B*).

Despite the absence of new radiographic lesions, serum tumor marker levels gradually increased. Approximately three years and eight months after diagnosis, because occult viable HCC or emerging resistance to prolonged atezolizumab-based therapy was suspected, treatment was changed to durvalumab plus tremelimumab, followed by durvalumab monotherapy from the second cycle onward. Tumor marker levels continued to increase after five cycles. Because extrahepatic disease remained undetectable and the residual hepatic lesion was the only radiographically identifiable lesion, partial hepatic resection was considered feasible despite impaired liver function (Figure *2C*).

Approximately four years after the initial diagnosis, conversion surgery was performed. Intraoperatively, the segment 2 lesion protruded from the liver surface (Figure *3A*), and two white nodules suspicious for peritoneal dissemination or lymph node metastases were identified in the adjacent omentum (Figure *3B*). Robot-assisted partial hepatectomy of segment 2 and resection of the omental nodules were performed using the saline-linked coagulation monopolar scissors (SLiC-Scissors) method [7]. The postoperative course was uneventful, and the patient was discharged on postoperative day 10. The entire resected segment 2 lesion was submitted for histological examination and showed complete tumor necrosis without viable cancer cells, confirming a pathological complete response in this lesion (Figure *3C*). No malignancy was found in the omental nodules (Figure *3D*). AFP did not decrease after hepatectomy, and bone scintigraphy and brain magnetic resonance imaging showed no metastatic disease. Because AFP levels remained elevated and residual HCC could not be excluded, seven additional cycles of durvalumab monotherapy were administered postoperatively, resulting in a total of 12 cycles of durvalumab-based therapy.

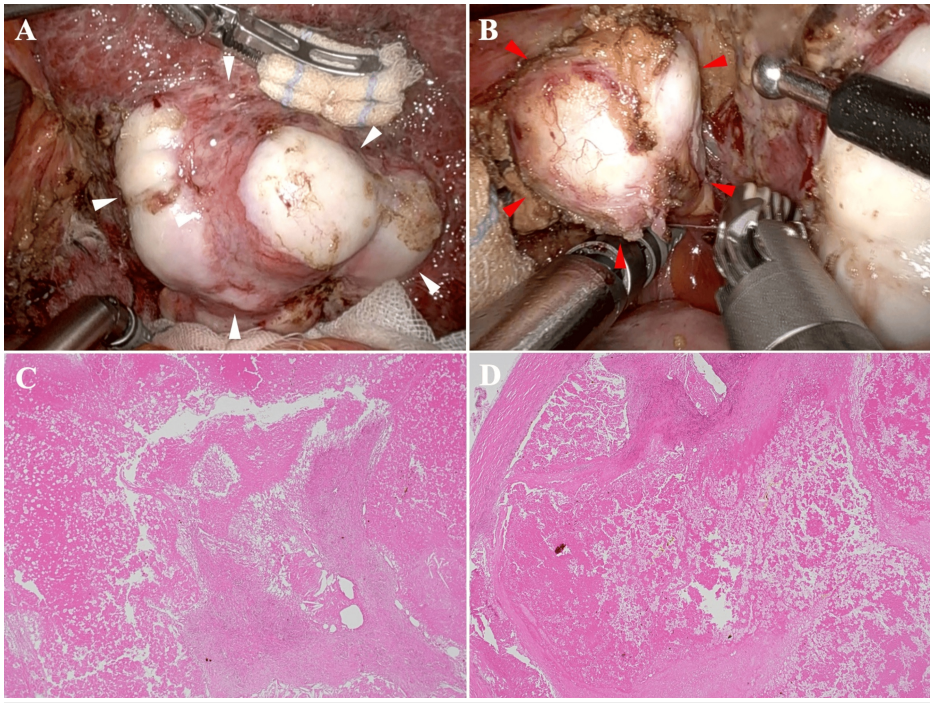

FIGURE 3: Intraoperative and histopathological findings at the first conversion surgery

(A) The segment 2 hepatic lesion protruded from the liver surface (white arrowheads). (B) One of the two white omental nodules suspicious for peritoneal dissemination or lymph node metastasis is shown (red arrowheads). (C) Histopathological examination of the hepatic lesion showed extensive necrosis without viable cancer cells, confirming a pathological complete response in the resected lesion (hematoxylin and eosin staining). (D) The omental nodules showed no evidence of malignancy (hematoxylin and eosin staining).

Approximately four years and five months after diagnosis, follow-up CT subsequently showed a new segment 4 hepatic lesion considered clinically to represent intrahepatic HCC recurrence, with no other definite viable HCC lesions (Figure *4A*). The same examination showed proximal jejunal wall thickening and enlarged mesenteric lymph nodes (Figures *4B* and 4C). Retrospective review of previous imaging studies showed no identifiable jejunal tumor before this lesion became apparent. Double-balloon enteroscopy revealed an ulcerated, infiltrative tumor in the proximal jejunum (Figure *4D*), and biopsy suggested poorly differentiated adenocarcinoma. Liver function was impaired, with Child-Pugh class B and an ICG retention rate at 15 minutes of 41.4%. Limited resection was selected to obtain a definitive diagnosis and local control of the hepatic lesion and to prevent future obstruction or bleeding from the jejunal tumor. Because of impaired liver function and the technically difficult location of the enlarged mesenteric lymph nodes near the mesenteric root, they were not resected to limit operative invasiveness.

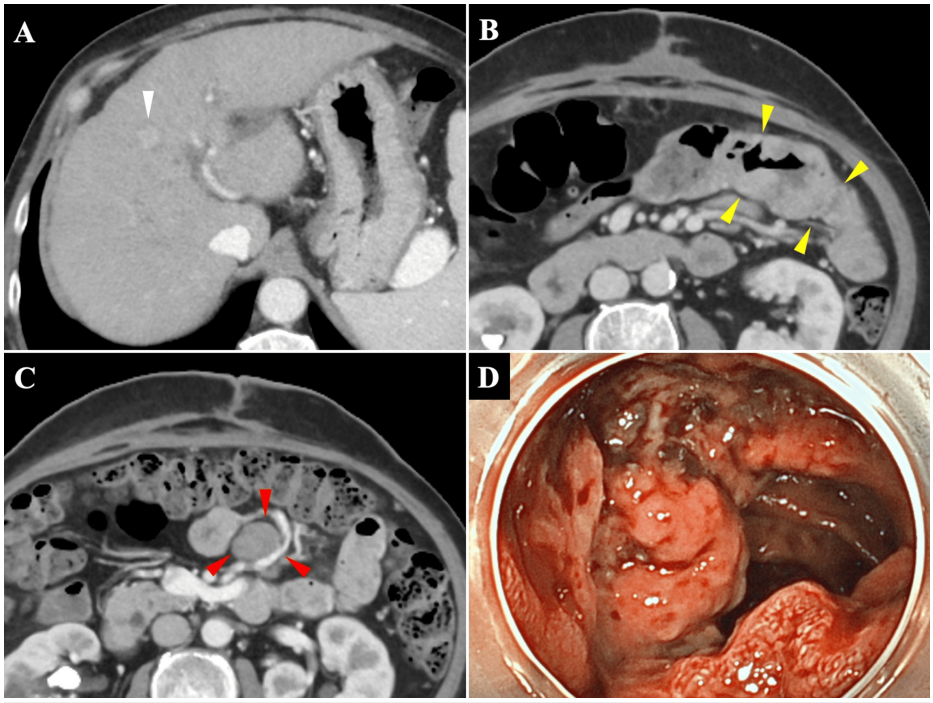

FIGURE 4: Follow-up CT and double-balloon enteroscopy findings after the first hepatectomy

(A) Follow-up CT showed a new segment 4 hepatic lesion considered clinically to represent recurrent HCC (white arrowhead), with no other definite viable HCC lesions. (B and C) CT showed proximal jejunal wall thickening (yellow arrowheads) and enlarged mesenteric lymph nodes (red arrowheads). (D) Double-balloon enteroscopy showed an ulcerated, infiltrative tumor in the proximal jejunum.

CT: computed tomography, HCC: hepatocellular carcinoma

Approximately four years and eight months after diagnosis, the patient underwent a second operation comprising robot-assisted partial hepatectomy of segment 4 followed by partial jejunal resection through a small laparotomy. The postoperative course was uneventful, and the patient was discharged on postoperative day 10. The segment 4 lesion was a well-to-moderately differentiated HCC (Figure *5A*). The jejunal tumor measured 88 × 17 mm and was diagnosed as adenocarcinoma with hepatoid differentiation (Figure *5B*), with invasion through the muscularis propria into the subserosa (pT3) and lymphatic and venous invasion. All resection margins were negative. The enlarged mesenteric lymph nodes were not resected and therefore were not pathologically assessed. Immunohistochemically, the jejunal tumor was positive for AE1/AE3, CAM5.2, AFP, and glypican-3, with focal SALL4 positivity and scattered hepatocyte marker positivity (Figures *5C*-*5F*). The jejunal tumor was morphologically distinct from the concurrently resected HCC, and its histological and immunohistochemical findings were considered compatible with adenocarcinoma with hepatoid differentiation.

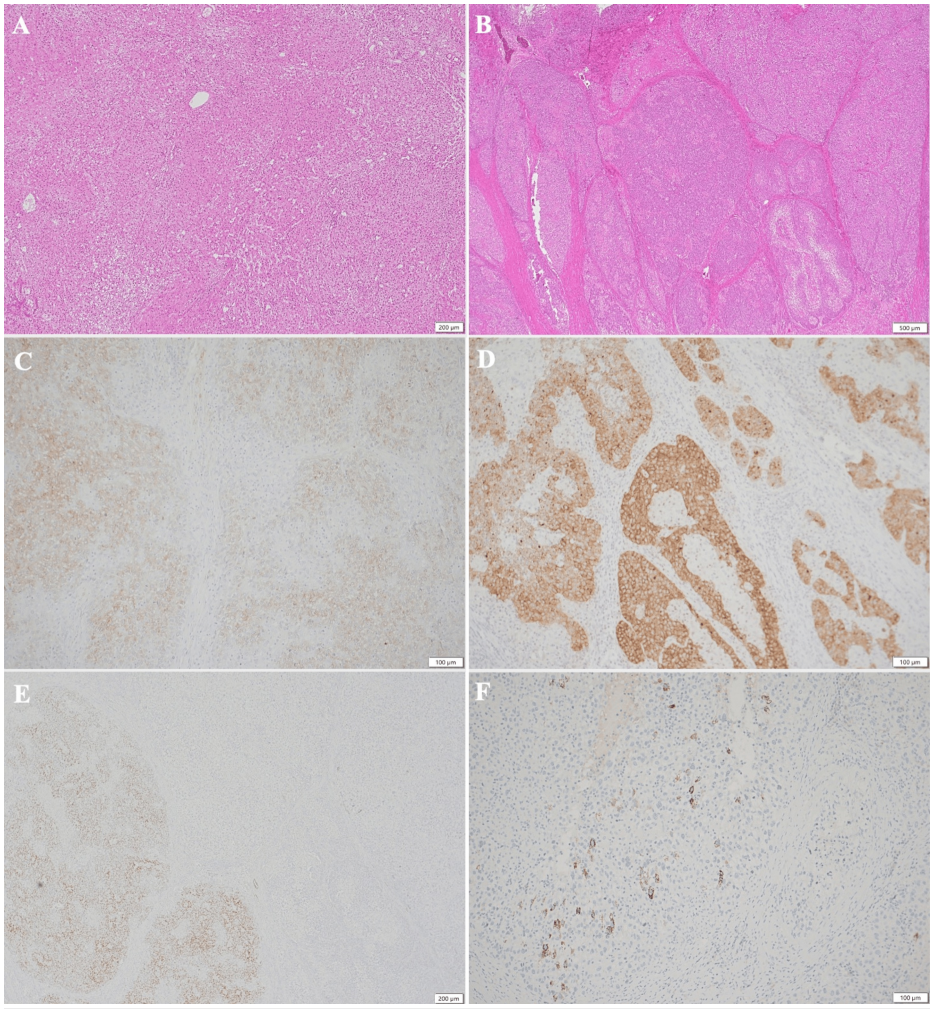

FIGURE 5: Histopathological and immunohistochemical findings of the segment 4 lesion and jejunal tumor

(A) The segment 4 hepatic lesion was a well-to-moderately differentiated HCC (hematoxylin and eosin staining). (B) The jejunal tumor showed adenocarcinoma with hepatoid differentiation (hematoxylin and eosin staining). (C) AFP immunostaining was positive in the jejunal tumor cells. (D) Glypican-3 immunostaining was positive in the jejunal tumor cells. (E) SALL4 immunostaining showed focal positivity in the jejunal tumor cells. (F) Hepatocyte marker immunostaining showed scattered positivity in the jejunal tumor cells.

Scale bars: A and E: 200 µm, B: 500 µm, C, D, and F: 100 µm

AFP: alpha-fetoprotein, HCC: hepatocellular carcinoma

No measurable HCC lesions remained after resection of the segment 4 lesion. The residual mesenteric lymph node lesions were not biopsied and were considered metastatic disease associated with the jejunal tumor based on radiological findings. Folinic acid (leucovorin), 5-fluorouracil, and oxaliplatin (FOLFOX) therapy was initiated for these lesions. After three cycles of FOLFOX, the lymph node lesions were no longer detectable on CT, AFP decreased markedly, and no recurrent HCC lesions were identified. FOLFOX was discontinued after three cycles because liver function worsened during treatment. At the latest follow-up, approximately seven months after the second operation and four months after the completion of FOLFOX, the patient remained without radiographic evidence of recurrence. Figure *6* summarizes the clinical course, including the progression of tumor markers, and Table *2* provides a chronological summary of the clinical course.

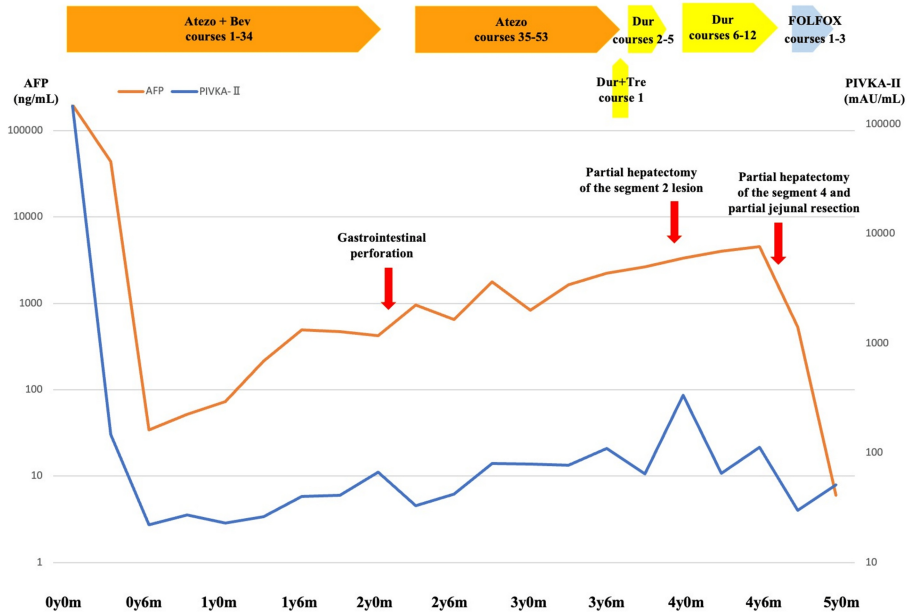

FIGURE 6: Changes in serum AFP and PIVKA-II levels during treatment

AFP and PIVKA-II are shown by the orange and blue lines, respectively. The y-axis is logarithmic. The timing of systemic treatments, bevacizumab discontinuation, the two operations, and FOLFOX should be indicated on the graph.

AFP: alpha-fetoprotein, Atezo: atezolizumab, Bev: bevacizumab, Dur: durvalumab, FOLFOX: folinic acid (leucovorin), 5-fluorouracil, and oxaliplatin, PIVKA-II: protein induced by vitamin K absence or antagonist-II, Tre: tremelimumab

Time from diagnosis	Treatment/event	Major clinical and imaging findings	AFP (ng/mL) / PIVKA-II (mAU/mL)	Pathological findings/outcome
At diagnosis	Initial presentation and diagnosis	10-cm hepatic tumor with portal vein tumor thrombus, multiple intrahepatic lesions, periduodenal lymph node, and lung and rib metastases	>200,000 / 145,311	Clinically diagnosed as advanced HCC
3 months	Atezolizumab + bevacizumab, 6 cycles	Marked regression of the primary hepatic tumor and metastatic lesions	563 / 25	-
2 years	Atezolizumab + bevacizumab through cycle 34; emergency surgery for jejunal perforation	Disease control maintained without new lesions; jejunal perforation occurred at a site separate from the later-detected jejunal tumor	-	No malignancy in the resected jejunal specimen; bevacizumab permanently discontinued
3 years and 7 months	Atezolizumab-based therapy, total 53 cycles	Disappearance of lung and rib metastases; a single residual hepatic lesion remained, with no abnormal uptake on PET-CT	2,238 / 109	-
3 years and 8 months	Durvalumab + tremelimumab, followed by durvalumab monotherapy	Rising tumor markers despite no new radiographic lesions	2,644 / 122	-
4 years	Conversion surgery	Residual segment 2 hepatic lesion and two suspicious omental nodules	3,361 / 336	Complete tumor necrosis without viable cancer cells in the resected hepatic lesion; omental nodules negative for malignancy
4 years and 5 months	Detection of a new hepatic lesion and a jejunal tumor	New segment 4 hepatic lesion and proximal jejunal tumor with mesenteric lymphadenopathy	5,956 / 124	Recurrent HCC was suspected; biopsy of the jejunal lesion suggested poorly differentiated adenocarcinoma
4 years and 8 months	Second surgery	No measurable HCC lesions remained after resection	3,430 / 79	Segment 4 lesion: well-to-moderately differentiated HCC; jejunal tumor: adenocarcinoma with hepatoid differentiation
4 years and 11 months	FOLFOX, 3 cycles	Mesenteric lymph node lesions no longer detectable on CT; no measurable HCC lesions	6 / 51	FOLFOX discontinued after three cycles because of worsening liver function

TABLE 2: Chronological summary of the clinical course

AFP: alpha-fetoprotein, CT: computed tomography, FOLFOX: folinic acid (leucovorin), 5-fluorouracil, and oxaliplatin, HCC: hepatocellular carcinoma, PET-CT: positron emission tomography-computed tomography, PIVKA-II: protein induced by vitamin K absence or antagonist-II

Discussion

This case has two clinically relevant features. First, prolonged immune-based systemic therapy enabled conversion surgery in a patient with initially uHCC characterized by portal vein tumor invasion and extrahepatic metastases, and the resected segment 2 lesion showed a pathological complete response. Second, persistent AFP elevation after a pathological complete response could not be attributed solely to HCC. The subsequent diagnosis of AFP-producing jejunal adenocarcinoma with hepatoid differentiation showed that tumor marker trends must be interpreted together with imaging, pathological findings, and the evolving clinical course when a single disease process does not adequately explain the findings.

Atezolizumab plus bevacizumab is a standard first-line systemic treatment for uHCC after demonstrating superior overall and progression-free survival compared with sorafenib in the IMbrave150 trial [1]. In the present case, serum AFP and PIVKA-II levels decreased rapidly after treatment initiation, and CT after six cycles showed marked regression of both the primary hepatic tumor and metastatic lesions. The lung and rib metastases subsequently disappeared on imaging, and disease control was maintained during continued

treatment. Bevacizumab was used cautiously because of suspected duodenal involvement with bleeding and was permanently discontinued after gastrointestinal perforation. Gastrointestinal perforation is a rare but serious adverse event associated with bevacizumab, and a fatal gastric ulcer perforation was reported in the IMbrave150 trial [1]. Atezolizumab monotherapy was continued because radiographic disease control had been maintained. Exploratory analyses have suggested that interruption of bevacizumab because of adverse events potentially associated with bevacizumab may not substantially compromise treatment efficacy in patients who have already received prolonged atezolizumab plus bevacizumab, although the nonrandomized nature of the analysis should be considered [8].

The optimal treatment sequence after failure or loss of response to an ICI-based regimen remains uncertain [9]. In clinical practice, tyrosine kinase inhibitors, ICI switching or rechallenge, and locoregional treatment are selected according to disease distribution and tempo, hepatic reserve, performance status, and prior adverse events. In the present case, increasing tumor marker levels in the absence of new radiographic lesions prompted a switch from atezolizumab-based therapy to durvalumab plus tremelimumab. This strategy introduced cytotoxic T-lymphocyte-associated antigen 4 (CTLA-4) inhibition while maintaining programmed cell death-ligand 1 (PD-L1) blockade. Small retrospective studies have reported disease control with durvalumab plus tremelimumab after atezolizumab plus bevacizumab, but treatment responses have varied, and the available evidence remains limited [10,11]. In retrospect, the rise in AFP may have reflected the subsequently detected jejunal adenocarcinoma with hepatoid differentiation, at least in part. Therefore, the clinical course in this patient cannot establish the efficacy of this treatment strategy but illustrates the individualized decision-making required when no standard subsequent regimen has been established.

The indications and optimal timing of conversion surgery after systemic therapy for initially uHCC remain undefined. Surgical resection may be considered when systemic therapy achieves a sustained response or durable disease control, extrahepatic disease is controlled or no longer detectable, adequate hepatic reserve can be preserved, and the remaining disease is technically resectable with expected oncological benefit [3,12-14]. There is no established waiting period between radiographic disappearance of extrahepatic metastases and conversion surgery. In the present case, surgery was not performed immediately after the lung and rib metastases disappeared; systemic therapy was continued while durable control of the extrahepatic disease was confirmed. Conversion surgery was considered when no extrahepatic disease remained detectable and the residual disease was confined to a single technically resectable hepatic lesion.

Persistent tumor marker elevation also indicated the need to determine whether the residual lesion remained biologically active. Pathological examination of the resected segment 2 lesion showed complete tumor necrosis without viable cancer cells, confirming a pathological complete response in this lesion. Thus, conversion surgery provided both local treatment and definitive pathological information that helped guide subsequent management.

A notable feature of this case was the persistent elevation of AFP after a pathological complete response had been confirmed in the resected segment 2 lesion. Although residual or recurrent HCC was initially suspected, the subsequent detection of a jejunal tumor with hepatoid differentiation provided another potential source of AFP production. Hepatoid adenocarcinoma is a rare extrahepatic adenocarcinoma that resembles HCC morphologically and immunohistochemically and may express hepatocellular markers such as AFP and glypican-3 [5,6]. Distinguishing an extrahepatic adenocarcinoma with hepatoid differentiation from metastatic HCC can therefore be challenging, particularly in patients with a history of HCC.

In the present case, the jejunal tumor was an adenocarcinoma with hepatoid differentiation and was positive for AFP and glypican-3, with focal SALL4 positivity and scattered hepatocyte marker expression. It was morphologically distinct from the concurrently resected HCC. However, histological material from the initial hepatic tumor was unavailable for direct comparison. In addition, a previous duodenal biopsy had shown findings considered compatible with HCC involvement, with AE1/AE3 positivity and focal hepatocyte marker expression. Taken together, the histological and immunohistochemical findings of the jejunal lesion were considered compatible with adenocarcinoma with hepatoid differentiation, although its exact origin could not be established with complete certainty.

AFP remained elevated after the resection of the segment 4 lesion and the jejunal tumor, while mesenteric lymph node lesions persisted. Following FOLFOX therapy, the mesenteric lymph node lesions were no longer detectable on imaging, and AFP levels decreased markedly in the absence of measurable HCC. This clinical course supported the interpretation that the jejunal tumor with hepatoid differentiation contributed substantially to AFP production and that AFP trends should be interpreted together with imaging and pathological findings rather than attributed to HCC alone.

Conclusions

Sequential immune-based systemic therapy enabled conversion surgery in a patient with initially unresectable HCC, with a pathological complete response confirmed in the resected segment 2 lesion. Persistent AFP elevation was later considered to reflect, at least in part, AFP production by the jejunal tumor with hepatoid differentiation. This case highlights the importance of interpreting AFP trends together with imaging, pathological findings, and the clinical course.

Additional Information

Author Contributions

All authors have reviewed the final version to be published and agreed to be accountable for all aspects of the work.

Concept and design: Takahisa Fujikawa, Keiji Nagata, Yusuke Uemoto, Yasusato Matsuda

Acquisition, analysis, or interpretation of data: Takahisa Fujikawa, Keiji Nagata

Critical review of the manuscript for important intellectual content: Takahisa Fujikawa, Yusuke Uemoto, Yasusato Matsuda

Drafting of the manuscript: Keiji Nagata

Disclosures

Human subjects: Informed consent for treatment and open access publication was obtained or waived by all participants in this study. **Conflicts of interest:** In compliance with the ICMJE uniform disclosure form, all authors declare the following: **Payment/services info:** All authors have declared that no financial support was received from any organization for the submitted work. **Financial relationships:** All authors have declared that they have no financial relationships at present or within the previous three years with any organizations that might have an interest in the submitted work. **Other relationships:** All authors have declared that there are no other relationships or activities that could appear to have influenced the submitted work.

References

1. Finn RS, Qin S, Ikeda M, et al.: Atezolizumab plus bevacizumab in unresectable hepatocellular carcinoma . N Engl J Med. 2020, 382:1894-905. 10.1056/NEJMoa1915745
2. Abou-Alfa GK, Lau G, Kudo M, et al.: Tremelimumab plus durvalumab in unresectable hepatocellular carcinoma. NEJM Evid. 2022, 1:EVIDoa2100070. 10.1056/EVIDoa2100070
3. Akahoshi K, Shindoh J, Tanabe M, et al.: Oncological resectability criteria for hepatocellular carcinoma in the era of novel systemic therapies: the Japan Liver Cancer Association and Japanese Society of Hepato-Biliary-Pancreatic Surgery expert consensus statement 2023. Liver Cancer. 2024, 13:0-10. 10.1159/000538627
4. Piao M, Li C, Huang Z, et al.: Conversion surgery after immune checkpoint inhibitor-based combination therapy for initially unresectable hepatocellular carcinoma: a retrospective cohort study. Liver Cancer. 2025, 14:456-73. 10.1159/000543994
5. Su JS, Chen YT, Wang RC, Wu CY, Lee SW, Lee TY: Clinicopathological characteristics in the differential diagnosis of hepatoid adenocarcinoma: a literature review. World J Gastroenterol. 2013, 19:321-7. 10.3748/wjg.v19.i3.321
6. Ushiku T, Shinozaki A, Shibahara J, Iwasaki Y, Tateishi Y, Funata N, Fukayama M: SALL4 represents fetal gut differentiation of gastric cancer, and is diagnostically useful in distinguishing hepatoid gastric carcinoma from hepatocellular carcinoma. Am J Surg Pathol. 2010, 34:533-40. 10.1097/PAS.0b013e3181d1dcdd
7. Fujikawa T, Uemoto Y, Matsuoka T, Kajiwara M: Novel liver parenchymal transection technique using saline-linked monopolar cautery scissors (SLIC-scissors) in robotic liver resection. Cureus. 2022, 14:e28118. 10.7759/cureus.28118
8. Kudo M, Tsuchiya K, Shao YY, et al.: Impact of bevacizumab being skipped due to adverse events of special interest for bevacizumab in patients with unresectable hepatocellular carcinoma treated with atezolizumab plus bevacizumab: an exploratory analysis of the phase III IMbrave150 study. Liver Cancer. 2024, 13:401-12. 10.1159/000535501
9. Hwang SY, Lee SL, Liu H, Lee SS: Second-line treatment after failure of immune checkpoint inhibitors in hepatocellular carcinoma: tyrosine kinase inhibitor, retrial of immunotherapy, or locoregional therapy?. Liver Cancer. 2024, 13:246-55. 10.1159/000534303
10. Miura R, Ono A, Yano S, et al.: Real-world efficacy and safety of durvalumab-tremelimumab as second-line systemic therapy after atezolizumab-bevacizumab in unresectable hepatocellular carcinoma. Medicine (Baltimore). 2024, 103:e39289. 10.1097/MD.0000000000039289
11. Mori N, Tamaki N, Takaki S, et al.: Treatment response to durvalumab plus tremelimumab after progression with previous immune checkpoint inhibitor in unresectable hepatocellular carcinoma. Invest New Drugs. 2024, 42:559-65. 10.1007/s10637-024-01470-y
12. Hidaka Y, Tomita M, Desaki R, Hamanoue M, Takao S, Kirishima M, Ohtsuka T: Conversion surgery for hepatocellular carcinoma with portal vein tumor thrombus after successful atezolizumab plus bevacizumab therapy: a case report. World J Surg Oncol. 2022, 20:228. 10.1186/s12957-022-02691-2
13. Fukunaga A, Takata K, Itoh S, et al.: Complete tumor necrosis confirmed by conversion hepatectomy after atezolizumab-bevacizumab treatment for advanced-stage hepatocellular carcinoma with lung metastasis. Clin J Gastroenterol. 2023, 16:224-8. 10.1007/s12328-022-01744-z
14. Okuno M, Ohama H, Nakamura I, et al.: A patient who underwent conversion surgery after atezolizumab plus bevacizumab for hepatocellular carcinoma with portal vein thrombosis and perihepatic lymph node metastases achieved a pathological complete response. Int Cancer Conf J. 2024, 13:306-12. 10.1007/s13691-

024-00683-5