Cureus
Part of SPRINGER NATURE

Open Access Case Report

UCLA Health
Published via Proceedings of the UCLA Department of Medicine

Metachronous Bladder Urothelial Carcinoma, Colorectal Adenocarcinoma, and Pancreatic Adenocarcinoma: A Case Report

Alanna W. Sugarman [1], Carolyn K. Kan [2], Sarah M. Chan [3], Christina W. Chung [3]

1. Internal Medicine, David Geffen School of Medicine - University of California, Los Angeles, Los Angeles, USA 2. Internal Medicine, West Los Angeles Veterans Affairs, Los Angeles, USA 3. Internal Medicine, University of California, Los Angeles, Los Angeles, USA

Corresponding author: Alanna W. Sugarman, asugarman@mednet.ucla.edu

Received 09/04/2026
Review began 09/26/2026
Review ended 11/11/2026
Published 11/23/2026

© Copyright 2026
Sugarman et al. This is an open access article distributed under the terms of the Creative Commons Attribution License CC-BY 4.0., which permits unrestricted use, distribution, and reproduction in any medium, provided the original author and source are credited.

DOI: 10.7759/cureus.120151

Abstract

Although the incidence of multiple primary malignancies is increasing, triple primary malignancies remain uncommon, and their etiology is incompletely understood. We report a case of a 77-year-old woman with a history of recurrent low-grade bladder urothelial carcinoma and colonic adenocarcinoma who presented with obstructive jaundice. She was found to have a pancreatic head mass, with a biopsy showing moderately differentiated adenocarcinoma favored to be a pancreatic primary. This case illustrates a rare metachronous combination of bladder, colorectal, and pancreatic malignancies. The tumor combination prompted consideration of hereditary cancer predisposition, including Lynch syndrome. However, molecular testing of the colorectal tumor revealed MLH1 promoter methylation, favoring sporadic mismatch repair deficiency without excluding an independent hereditary cancer predisposition. Metabolic risk factors, including severe obesity, type 2 diabetes mellitus, and metabolic dysfunction-associated steatohepatitis, may also have contributed to her cancer susceptibility. This report reinforces the importance of maintaining vigilance for new primary malignancies, particularly in survivors with substantial metabolic comorbidities. It also demonstrates the need for precise pathologic reconciliation when oncologic care spans multiple clinical sites.

Categories: Oncology, Internal Medicine, Gastroenterology
Keywords: bladder urothelial carcinoma, colorectal adenocarcinoma, hereditary cancer syndromes, metachronous primary malignancies, mismatch repair deficiency, multiple primary malignancies, pancreatic adenocarcinoma

Introduction

Multiple primary malignancies are defined as two or more distinct primary cancers occurring in a single patient, either synchronously or metachronously [1,2]. Triple primary malignancies remain uncommon. A 25-year retrospective study at a tertiary cancer center identified 117 patients with triple primary malignancies among 141,662 cancer patients (0.08%) [3]. In a separate single-institution cohort study of 2,894 patients referred for hereditary cancer screening, 33 patients had three or more primary malignancies. Among the 31 with available germline testing results, 11 (35.5%) had an identifiable hereditary cancer syndrome [4].

The development of multiple primary malignancies is associated with hereditary cancer predisposition, environmental or metabolic exposures, prior cancer-directed therapy, and increasing age [1,2]. Establishing separate primary malignancies requires evidence that each tumor represents an independent primary rather than a recurrence or metastasis. Under one common convention, primary cancers diagnosed within six months of one another are classified as synchronous, whereas those diagnosed more than six months apart are classified as metachronous [1]. Furthermore, distinguishing a new primary malignancy from cancer recurrence or metastasis is clinically important, as it guides staging, treatment, surveillance, and genetic counseling [1]. This distinction is especially relevant when the tumor combination includes multiple cancers linked with known hereditary cancer syndromes.

We report a rare case of three metachronous primary malignancies in a 77-year-old woman: bladder urothelial carcinoma, colonic adenocarcinoma, and adenocarcinoma of the pancreatic head, for which a pancreatic primary was favored. Prior reports have described overlapping tumor combinations involving colorectal, urinary tract, and pancreatic malignancies [5-7]. This combination is notable because these tumor types can occur in hereditary cancer syndromes, and because pancreatic adenocarcinoma itself is an indication for hereditary risk assessment and consideration of germline testing [8-10]. This case also illustrates the difficulty of reconstructing a cancer history across multiple institutions and distinguishing confirmed primary malignancies from provisional diagnoses.

Case Presentation

A 77-year-old woman with Child-Pugh class C cirrhosis secondary to metabolic dysfunction-associated

steatohepatitis, severe obesity (body mass index (BMI) of 45 kg/m^2), insulin-dependent type 2 diabetes mellitus, hypertension, chronic kidney disease, recurrent low-grade urothelial carcinoma, and previously treated colonic adenocarcinoma presented to the emergency department with six days of jaundice, three days of lethargy, and associated dark urine and abdominal discomfort. On presentation, she was afebrile and hemodynamically stable, with a temperature of 36.4℃, blood pressure of 135/65 mmHg, heart rate of 84 beats/min, respiratory rate of 18 breaths/min, and oxygen saturation of 96% on room air. Initial laboratory studies showed marked conjugated hyperbilirubinemia in a cholestatic pattern of liver injury, with a normal white blood cell count and thrombocytopenia (Table *1*). Magnetic resonance cholangiopancreatography showed acute cholecystitis, moderate intrahepatic and extrahepatic biliary dilation, and an abrupt cutoff of the mid-to-distal common bile duct without a definite obstructing stone or discrete pancreatic lesion.

Laboratory test	Patient value	Reference range
White blood cell count (x10^3/μL)	7.40	4.5-10.0
Hemoglobin (g/dL)	12.2	12.0-16.0
Platelet count (x10^3/μL)	130	150-400
Sodium (mmol/L)	131	135-145
Potassium (mmol/L)	4.0	3.5-5.1
Bicarbonate (mmol/L)	16	22-29
Blood urea nitrogen (mg/dL)	22	7-22
Creatinine (mg/dL)	1.41	0.5-1.3
Glucose (mg/dL)	189	65-99
Albumin (g/dL)	2.8	3.9-5.0
Aspartate aminotransferase (U/L)	125	13-62
Alanine aminotransferase (U/L)	48	8-70
Alkaline phosphatase (U/L)	318	37-113
Total bilirubin (mg/dL)	19.5	0.1-1.2
Direct bilirubin (mg/dL)	15.5	≤0.3
International normalized ratio	1.9	0.8-1.2

TABLE 1: Pertinent laboratory values at initial presentation

Given her advanced cirrhosis with a Model for End-Stage Liver Disease (MELD) 3.0 score of 32 (calculated from the laboratory values at presentation in Table *1*), severe obesity, and overall burden of comorbidities, including hypertension and diabetes, she was considered a high-risk surgical candidate. As a result, she underwent percutaneous cholecystostomy tube placement on hospital day (HD) 0 for acute cholecystitis. On HD 2, cholecystography demonstrated marked narrowing of the distal common bile duct near the ampulla, with contrast passing into the duodenum, consistent with incomplete biliary obstruction (Figure *1A*). On HD 3, endoscopic ultrasonography (EUS) showed an irregular hypoechoic mass measuring 1.8 × 1.7 cm in the pancreatic head (Figure *1B*). The mass obstructed the common bile duct and abutted the portal vein without definite vascular invasion. Endoscopic ultrasonography-guided core needle biopsy showed moderately differentiated adenocarcinoma. Concurrent cytology also showed adenocarcinoma, with malignant epithelial cells exhibiting enlarged nuclei, irregular nuclear borders, and prominent nucleoli. A pancreatic primary was favored clinically. Endoscopic retrograde cholangiopancreatography was deferred because the ampulla could not be visualized and scope positioning was unstable, with the patient's body habitus preventing prone positioning. Total bilirubin initially declined after cholecystostomy placement but subsequently rose despite continued drain output. A percutaneous internal-external biliary drain was placed on HD 8, but her hyperbilirubinemia continued to worsen. Serial bilirubin, creatinine, and international normalized ratio (INR) measurements before and after biliary drainage and during clinical deterioration are summarized in Table *2*.

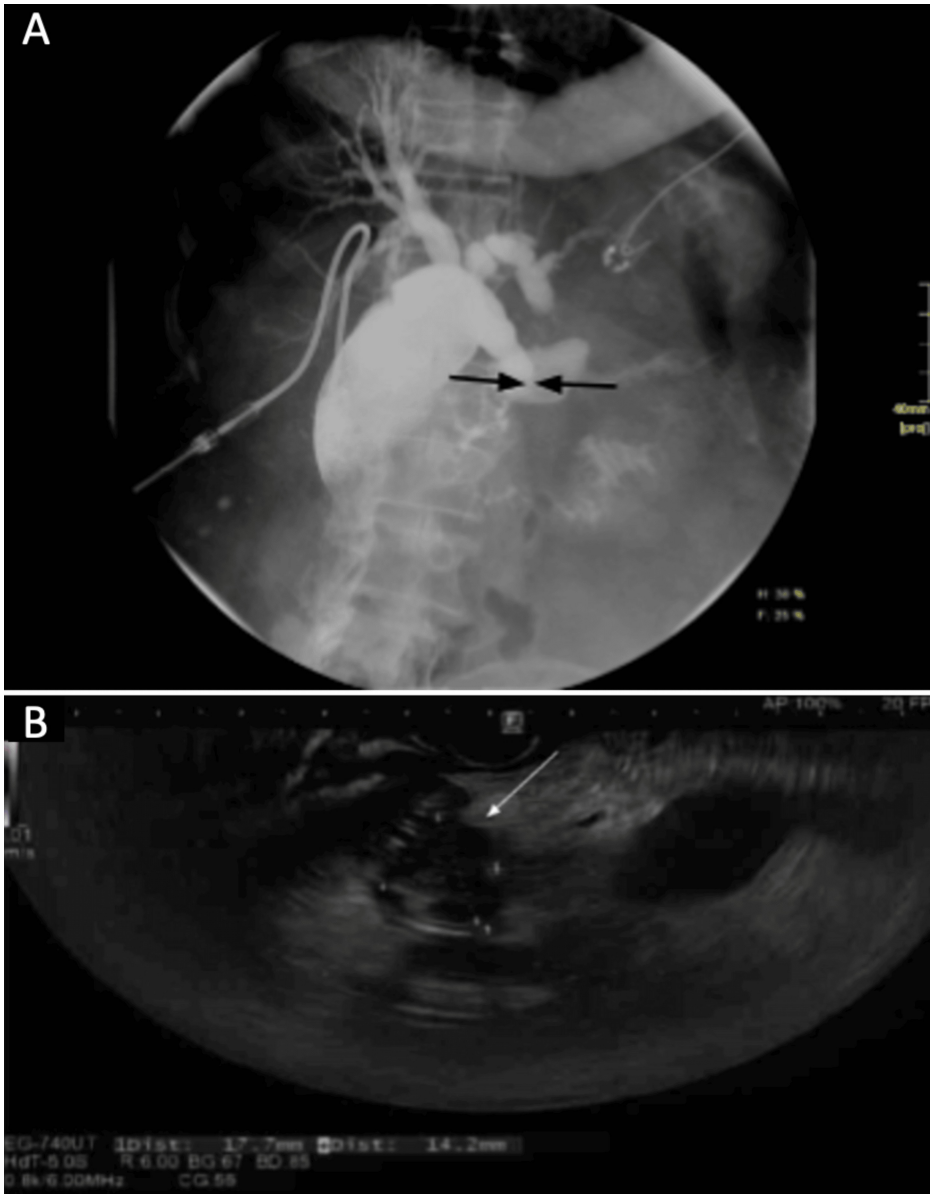

FIGURE 1: Imaging evaluation of malignant biliary obstruction

(A) Fluoroscopic cholecystogram performed through the percutaneous cholecystostomy tube demonstrates intrahepatic and extrahepatic biliary dilation with marked narrowing of the distal common bile duct near the ampulla (black arrow). Contrast passes into the duodenum, indicating incomplete obstruction. (B) EUS demonstrates an irregular hypoechoic pancreatic head mass (white arrow). EUS-guided tissue acquisition confirmed moderately differentiated adenocarcinoma.

EUS: endoscopic ultrasonography

Time point	Total bilirubin (mg/dL)	Creatinine (mg/dL)	INR
Initial presentation	19.5	1.41	1.9
HD 2	16.9	1.79	–
HD 7	22.7	1.08	1.7
HD 10	23.1	1.71	1.7
HD 15	32.3	2.10	2.7

TABLE 2: Serial laboratory values around biliary drainage and clinical deterioration

Cholecystostomy was performed on HD 0 (one day after initial presentation to the ED), and an internal-external biliary drain was placed on HD 8.

ED: emergency department, HD: hospital day, INR: international normalized ratio, –: no result available for that day

Her prior oncologic history was reconstructed from records spanning multiple institutions and later subspecialty notes. An outside hematology note documented a reported family history of ovarian cancer in her mother and two sisters without specifying ages at diagnosis, diagnostic confirmation, or genetic testing. Her first pathologically confirmed malignancy was low-grade bladder urothelial carcinoma, which subsequently recurred. A possible initial bladder tumor resection in 2017 was documented retrospectively, but the pathology was unavailable, and surveillance cystoscopies in 2018 and 2019 were reportedly negative. Pathology after transurethral resection in 2020 showed low-grade papillary urothelial carcinoma with no evidence of muscle invasion. Cystoscopy with biopsy in 2022 confirmed low-grade noninvasive urothelial carcinoma. Surveillance urine cytology and fluorescence in situ hybridization in 2025 showed no evidence of high-grade urothelial carcinoma.

Her second confirmed primary malignancy was colonic adenocarcinoma. Approximately three years after her first pathologically confirmed diagnosis of urothelial carcinoma, at age 74, she presented to a separate institution with abdominal pain, weight loss, and gastrointestinal bleeding. Colonoscopy showed a nonobstructing ulcerated right-sided colonic lesion. Biopsy of the lesion showed a scant atypical lymphoid infiltrate with CD20-positive large lymphocytes, CD10 and BCL6 positivity, and a high Ki-67 proliferation index, which raised concern for diffuse large B-cell lymphoma (DLBCL). However, the specimen was limited, and the biopsy was not diagnostic. Subsequent bone marrow biopsy and positron emission tomography/computed tomography (PET/CT) showed no evidence of lymphoma, and she received no lymphoma-directed treatment.

Repeat colonoscopy seven months later showed no persistent lesion corresponding to the earlier concern for lymphoma but revealed a separate distal transverse colon mass. Histopathology of the endoscopic mucosal resection specimen showed moderately differentiated adenocarcinoma arising in a tubular adenoma, with submucosal invasion and carcinoma extending to the inked polyp base. The available reports did not specify en bloc versus piecemeal resection, the depth of submucosal invasion, lymphovascular invasion status, or tumor budding. The endoscopist reported no visible residual lesion after snare coagulation of the remaining tissue in situ. Given the involved histologic margin, microscopic clearance after coagulation could not be confirmed. The tumor showed loss of expression of the mismatch repair proteins MLH1 and PMS2, with MLH1 promoter methylation, favoring sporadic mismatch repair deficiency rather than Lynch syndrome-associated mismatch repair deficiency. She was deemed a poor candidate for colorectal surgery due to a BMI greater than 50 kg/m^2 and cirrhosis with portal vein thrombosis at that time. She was managed with surveillance because of her surgical risk. Serial PET/CT examinations in October 2023, August 2024, and March 2025 showed no evidence of recurrent or metastatic disease. A circulating tumor DNA (ctDNA) assay in October 2024 detected no ctDNA. Surveillance colonoscopy in December 2023 showed a postpolypectomy scar in the transverse colon without visible residual cancer. No specimens were collected. Surveillance colonoscopy in April 2025 showed neither endoscopic nor histologic evidence of recurrent carcinoma. A 4-mm polyp at a prior transverse colon resection scar was removed by cold snare. Histopathology showed an inflammatory polyp without dysplasia.

In the context of this surveillance history, the pancreatic head mass was considered most consistent with a third primary malignancy rather than a metastasis from her prior colorectal cancer (Figure *2*). Staging CT on HD 7 showed no definite vascular involvement or metastatic disease, although abdominal assessment was limited by artifact. EUS had demonstrated portal vein abutment without definite invasion, while CT reported the portal vein and other major vessels as uninvolved. The radiology report classified the mass as surgically resectable per National Comprehensive Cancer Network criteria, while noting that resection feasibility required a multidisciplinary assessment. Outpatient surgical and medical oncology evaluation and multidisciplinary tumor board review were planned contingent on her remaining clinically stable. However,

her hospitalization was complicated by progressive hepatic, renal, and respiratory failure (Table 2). On HD 14, she required transfer to the intensive care unit for acute hypoxic respiratory failure. Blood cultures collected that day grew *Staphylococcus epidermidis* in two peripheral sets. She received piperacillin-tazobactam on HD 14 and vancomycin on HD 15. She was intubated on HD 15 for worsening mental status and respiratory failure and received continuous renal replacement therapy on HDs 15-16 for acute kidney injury and volume removal. By HD 16, she required norepinephrine and vasopressin for shock attributed to decompensated cirrhosis and bacteremia. After discussion with her family, care was transitioned to a comfort-focused approach. She underwent palliative extubation and died shortly thereafter on HD 16.

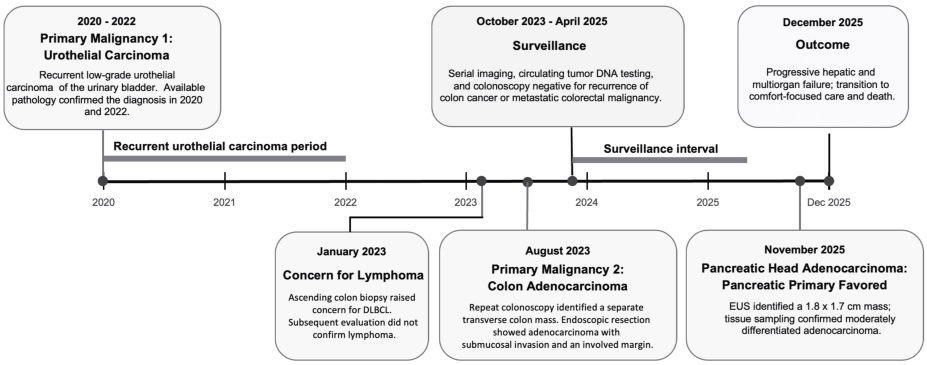

FIGURE 2: Timeline of malignancy diagnoses and key clinical events

The patient had recurrent low-grade non-muscle-invasive urothelial carcinoma, followed by transverse-colon adenocarcinoma treated endoscopically, and approximately two years later, pancreatic head adenocarcinoma for which a pancreatic primary was favored. A possible initial bladder tumor resection in 2017 was documented retrospectively, but the corresponding pathology was unavailable; therefore, the timeline begins with the first pathologically confirmed bladder malignancy in 2020.

DLBCL: diffuse large B-cell lymphoma, EUS: endoscopic ultrasonography

Discussion

This case adds to the literature on multiple primary malignancies by describing an unusual metachronous sequence of bladder urothelial carcinoma, colorectal adenocarcinoma, and pancreatic adenocarcinoma. Tissue sampling of the pancreatic head mass confirmed moderately differentiated adenocarcinoma. Its presentation as a discrete pancreatic head mass causing common bile duct obstruction, together with serial surveillance showing no other evidence of recurrent or metastatic colorectal cancer, favored a new pancreatic primary rather than colorectal metastasis. The combination could reflect hereditary cancer predisposition, shared metabolic or environmental risk factors, aging, or chance, but the available testing did not identify a unifying explanation.

Prior case reports have described overlapping tumor combinations. One report described synchronous colorectal and pancreatic adenocarcinomas [5]. Another report documented quadruple primary malignancies involving the small intestine, descending colon, renal pelvis, and pancreas [6]. A third report described six primary malignancies, including colonic adenocarcinoma, urinary bladder carcinoma, and pancreatic intraductal papillary mucinous carcinoma, the last of which the authors grouped among the patient's adenocarcinomas [7]. Another report included colorectal and bladder urothelial carcinomas among multiple metachronous primaries but did not include pancreatic adenocarcinoma [11]. This case illustrates the diagnostic challenges of evaluating a suspected pancreatic primary in a patient with prior bladder and colorectal cancers.

The patient's history of three malignancies made hereditary cancer predisposition an important consideration. One study found that germline pathogenic variants became more common as the number of primary cancers increased [12]. In a separate cohort study of patients referred for hereditary cancer screening, 35.5% of the subgroup with three or more primary cancers had an identifiable hereditary cancer syndrome, most of which were high-penetrance syndromes [4]. The presence of both colorectal and pancreatic cancers made hereditary cancer predisposition particularly relevant, as both tumor types were associated with a higher likelihood of a hereditary cancer syndrome in that cohort [4].

Multiple hereditary syndromes were relevant to the differential diagnosis in this patient. Lynch syndrome was considered given the patient's colorectal and pancreatic cancers and reported family history of ovarian cancer [8]. In this patient, molecular testing of the colorectal tumor showed loss of MLH1 and PMS2 expression with MLH1 promoter methylation, favoring sporadic MLH1 silencing rather than classic germline Lynch syndrome [8]. In general, Lynch syndrome is also more strongly associated with upper urinary tract urothelial carcinoma, whereas bladder cancer is a less established manifestation and appears particularly

associated with certain mismatch repair genotypes, especially MSH2 [8]. Additionally, MLH1 promoter methylation can favor a sporadic colorectal tumor but does not exclude a separate hereditary cancer predisposition in a patient with three malignancies and a strong family history of ovarian cancer [8]. Unfortunately, germline testing was not obtained because pancreatic adenocarcinoma was diagnosed during her final hospitalization, two weeks before her death. In similar patients with sufficient clinical stability, hereditary risk assessment and germline testing may help clarify cancer risk for patients and family members [9,10].

Metabolic risk factors may have contributed to this patient's cancer history. She had severe obesity, with a BMI documented as greater than 50 kg/m² during colorectal surgical evaluation and approximately 45 kg/m² during her final hospitalization, as well as insulin-dependent type 2 diabetes mellitus and metabolic dysfunction-associated steatohepatitis. Excess body fat is an established risk factor for colorectal and pancreatic cancer [13]. Among older survivors of nonmetastatic cancer, compared with a BMI of 18.5 to <25 kg/m², BMI categories of 25 to <30 kg/m² and ≥30 kg/m² were associated with adjusted hazard ratios of 1.15 and 1.34, respectively, for any second primary cancer. The corresponding adjusted hazard ratios for obesity-related second primary cancers as a group were 1.40 and 1.78 [14]. Obesity has also been associated with a modestly increased risk of bladder cancer, although this association is less established [15]. Treatment-related carcinogenesis was unlikely because she had not received chemotherapy or radiation for her earlier confirmed cancers. Overall, these factors may have contributed to the development of these malignancies but do not establish a single cause for this tumor combination.

The initial concern for DLBCL also illustrates the difficulty of reconstructing a multiple-cancer history when care occurs across several institutions. In this case, three disparate cancers were diagnosed in three separate health centers, each with distinct medical record systems. The original biopsy showed only scant atypical lymphoid tissue, and lymphoma was not confirmed by bone marrow biopsy, PET/CT, or repeat colonoscopy. She also received no lymphoma-directed treatment. For these reasons, lymphoma was not counted as a fourth primary malignancy.

This report is limited by the difficulty of reconstructing a complete oncologic history from records spanning multiple institutions, the absence of germline testing because the pancreatic cancer was diagnosed during her final hospitalization, and the lack of comprehensive molecular profiling across all three tumors. Because of limited medical records, further immunohistochemical details and documentation of a direct histologic comparison between the pancreatic and colorectal tumors were unavailable. The colorectal findings did not necessarily resolve the broader hereditary concern raised by three malignancies and the reported ovarian cancers in three first-degree relatives. The available records did not establish whether genetic counseling was considered before the final hospitalization or whether a genetics referral or discussion with the family occurred afterward. Even so, this case highlights the importance of distinguishing pathologically confirmed malignancies from provisional or retrospectively documented diagnoses when determining whether a patient has multiple primary cancers. It also underscores the need to maintain a low threshold for evaluating new or unexplained symptoms in cancer survivors with substantial metabolic risk factors such as severe obesity. Additional reports and molecular analyses of similar cases are needed to determine whether this combination represents a reproducible association and to identify any shared pathways involved.

Conclusions

This case describes a rare metachronous combination of malignancies: bladder urothelial carcinoma, colorectal adenocarcinoma, and a pancreatic head mass favored to be a pancreatic primary. The pattern raised concern for a hereditary cancer predisposition. Although MLH1 promoter methylation favored a sporadic colorectal tumor, hereditary cancer predisposition could not be excluded. The patient's substantial metabolic risk factors may also have contributed. Newly identified lesions in cancer survivors require careful evaluation to distinguish a new primary malignancy from recurrence or metastasis, particularly in patients with additional risk factors. Multiple primary cancers should also prompt hereditary risk assessment when feasible. When care spans multiple institutions, reviewing the original pathology and treatment records is essential to distinguish confirmed cancers from provisional diagnoses and guide subsequent care.

Additional Information

Author Contributions

All authors have reviewed the final version to be published and agreed to be accountable for all aspects of the work.

Concept and design: Alanna W. Sugarman, Christina W. Chung, Carolyn K. Kan, Sarah M. Chan

Acquisition, analysis, or interpretation of data: Alanna W. Sugarman

Drafting of the manuscript: Alanna W. Sugarman

Critical review of the manuscript for important intellectual content: Christina W. Chung, Carolyn K.

Kan, Sarah M. Chan

Supervision: Christina W. Chung

Disclosures

Human subjects: Informed consent for treatment and open access publication was obtained or waived by all participants in this study. **Conflicts of interest:** In compliance with the ICMJE uniform disclosure form, all authors declare the following: **Payment/services info:** All authors have declared that no financial support was received from any organization for the submitted work. **Financial relationships:** All authors have declared that they have no financial relationships at present or within the previous three years with any organizations that might have an interest in the submitted work. **Other relationships:** All authors have declared that there are no other relationships or activities that could appear to have influenced the submitted work.

References

1. Vogt A, Schmid S, Heinimann K, Frick H, Herrmann C, Cerny T, Omlin A: Multiple primary tumours: challenges and approaches, a review. ESMO Open. 2017, 2:000172. 10.1136/esmoopen-2017-000172
2. Pan SY, Huang CP, Chen WC: Synchronous/metachronous multiple primary malignancies: review of associated risk factors. Diagnostics (Basel). 2022, 12:1940. 10.3390/diagnostics12081940
3. Almasan I, Piciu D: Triple primary malignancies: tumor associations, survival, and clinicopathological analysis: a 25-year single-institution experience. Healthcare (Basel). 2023, 11:738. 10.3390/healthcare11050738
4. Borja NA, Silva-Smith R, Calfa C, Sussman DA, Tekin M: Triple primary cancers: an analysis of genetic and environmental factors. Cancer Prev Res (Phila). 2024, 17:209-15. 10.1158/1940-6207.CAPR-23-0395
5. Cao C, Parikh P, Moezardalan K, Anantharaman A, Azarm A, Lai J: Synchronous primary pancreatic ductal carcinoma and colonic adenocarcinoma present in a patient with history of skin squamous cell carcinoma. Anticancer Res. 2020, 40:4029-32. 10.21873/anticanres.14398
6. Jiao F, Hu H, Wang LW: Quadruple primary malignancy patient with survival time more than 20 years . World J Gastroenterol. 2013, 19:1498-501. 10.3748/wjg.v19.i9.1498
7. Muto Y, Suzuki K, Kato T, et al.: Multiple primary malignancies of six organs in a Japanese male patient: a case report. Mol Clin Oncol. 2019, 10:511-5. 10.3892/mco.2019.1819
8. Idos G, Valle L: Lynch syndrome. GeneReviews® [Internet]. Adam MP, Bick S, Mirzaa GM, et al. (ed): University of Washington, Seattle (WA); 2004.
9. Stoffel EM, McKernin SE, Brand R, et al.: Evaluating susceptibility to pancreatic cancer: ASCO provisional clinical opinion. J Clin Oncol. 2019, 37:153-64. 10.1200/JCO.18.01489
10. Tempero MA: NCCN guidelines updates: pancreatic cancer. J Natl Compr Canc Netw. 2019, 17:603-5.
11. Hisanaga E, Sano T, Yokoo H: Four metachronous cancers: mutation profiling can be used to distinguish multiple primary cancers from metastases. Intern Med. 2026, 65:183-6. 10.2169/internalmedicine.5301-25
12. Bychkovsky BL, Lo MT, Yussuf A, et al.: Prevalence and spectrum of pathogenic variants among patients with multiple primary cancers evaluated by clinical characteristics. Cancer. 2022, 128:1275-83. 10.1002/cncr.34056
13. Lauby-Secretan B, Scoccianti C, Loomis D, Grosse Y, Bianchini F, Straif K: Body fatness and cancer—viewpoint of the IARC Working Group. N Engl J Med. 2016, 375:794-8. 10.1056/NEJMsr1606602
14. Bodelon C, Sung H, Mitchell EL, et al.: Excess body weight and the risk of second primary cancers among cancer survivors. JAMA Netw Open. 2024, 7:2433132. 10.1001/jamanetworkopen.2024.33132
15. Sun JW, Zhao LG, Yang Y, Ma X, Wang YY, Xiang YB: Obesity and risk of bladder cancer: a dose-response meta-analysis of 15 cohort studies. PLoS One. 2015, 10:0119313. 10.1371/journal.pone.0119313